

Differences of Facial Infection with *Demodex* spp. Between Indian Students and Native Students in Jiamusi University

Huiming Zhang¹, Sheng Bi², Fangfang Wang³, Baocheng Zhang⁴, Juxiang Su¹, Yue Dai¹, Chunmin Wang⁵, Jiwei Du^{6,*}, Guang Chen¹,

¹Department of Parasitology, Basic Medical Science, Jiamusi University, Jiamusi, China

²The First Affiliated Hospital, Jiamusi University, Jiamusi, China

³Department of Pathophysiology, Basic Medical Science, Jiamusi University, Jiamusi, China

⁴Department of Ergology Laboratory, Basic Medical Science, Jiamusi University, Jiamusi, China

⁵Department of Microbiology, Basic Medical Science, Jiamusi University, Jiamusi, China

⁶Nursing department, Xiang'An Hospital, Xiamen University, Xiamen, China

Email address:

misschenguang75@163.com (Guang Chen), dujiwei1977@163.com (Jiwei Du)

*Corresponding author

To cite this article:

Huiming Zhang, Sheng Bi, Fangfang Wang, Baocheng Zhang, Juxiang Su, Yue Dai, Chunmin Wang, Jiwei Du, Guang Chen. Differences of Facial Infection with *Demodex* spp. Between Indian Students and Native Students in Jiamusi University. *American Journal of Biomedical and Life Sciences*. Vol. 6, No. 4, 2018, pp. 73-77. doi: 10.11648/j.ajbls.20180604.12

Received: July 4, 2018; **Accepted:** August 21, 2018; **Published:** September 19, 2018

Abstract: *Demodex* is an ancient pathogen with is a contributor to chronic diseases such as acne rosacea or marginal blepharitis. Recently people found that many kind of diseases correlate with *demodex* infection, it begin to attract wide interest. At present, we want to evaluate the prevalence of facial infection with *demodex* spp, among international and local students in Jiamusi University of China. Using skin scraping method to obtain secretions, and then put the secretions to the drop of glycerol on a glass slide. The sample was covered with a cover glass and examined for parasites by light microscopy at 10× and 40× objective. Results showed that the infection rate in foreign students and local students were 15.2% (57/375) and 34.5% (203/588) respectively. There was a statistically significant difference between international students and local students in *demodex* infection rate ($\chi^2 = 43.38, P < 0.05$). There was a dominance of *Demodex folliculorum* infection in male of international students and local students, which are 63.6% (28/44) and 69.6% (94/135); followed by *Demodex brevis* infection, which are 22.7% (10/44) and 22.2% (30/135); last one is mixed infection, which are 13.6% (6/44) and 8.1% (11/135). Interesting, the infection rate of mixed *demodex* from local female students was the highest in total students. In addition, *demodex* infected local students with facial symptoms (67.9%) were significantly higher than those showing healthy facial skin (21.5%) ($\chi^2 = 112.9, P < 0.05$). Thus, one can conclude that the probability of *Demodex* infection is comparable for foreign students and local students unlike, which is related to examination methods, examination season, temperature, living environment, human race possibility.

Keywords: International Student, Local Student, Demodex, Infection, Face

1. Introduction

Demodex was first identified over 150 years ago, [1] just belongs to the class of arachnids (Arachnida), the scab mites subdivision (Acarida) and the hair follicle mites family (Demodiacidae). These mites prevail all over the world and are characterized by a parasitic existence, and commonly

parasitised hair follicles, sebaceous glands and eyelid glands, which may evoke demodecosis in both human and animals, the course of which is chronic. [2-3] The 2 kinds of *demodex* mites that have been identified in human: *Demodex folliculorum* (*D.f*) and *D. brevis* (*D.b*), commonly appear in seborrheic areas of the facial skin (the forehead, chin, and around the eyes and mouth) that affect human skin. [4-5] In addition, they are also observed on the pileous skin of the head,

on hairy chest or in the genital area. [6-9] *D. f* live in hair follicles or sebaceous glands., and occur in concentrations and the disease progresses as the patient’s age increases. In turn, *D. b* is usually located in the meibomian glands, and is found to live individually and morbidity is not age dependent. [6] Patients generally have no symptoms, but it occasionally causes some skin diseases. [10-11]

Demodex occurs all over the world in almost all human races, including various ethnic groups such as aborigines and Eskimos. About 80-90% of the human population is infected with *demodex*; however, *D. folliculorum* is more often found in females than in males. [7] Recently, there are reports in the literature that the infection rate of *demodex* mites is high and the incidence increases with age. [2] Meanwhile, it is postulated that *demodex* mites become pathogenic when they multiply and cause or exacerbate ocular symptoms and eyelid margin changes. [12] The infection rate of population was observed to be 84% at age of 60 and 100% in people older than 70. [13] It is worth mentioning, the infection rate of *demodex* mite was reported from 27.0% to 100% in foreign countries and from 0.8% to 81.0% in China. The difference of *demodex* infection between foreign countries and China, may be closely related to various factors such as examination methods, time and environment. Therefore, the aim of the present study was to evaluate and compare the infection status of facial *demodex* in different ethnic groups, a survey was conducted in 2015-2017 grade local college students and 2013-2015 grade Indian students (hereinafter referred to as foreign students) as well as local college students (hereinafter referred to as local students) of Jiamusi University.

2. Material and Methods

2.1. Study Population

375 foreign students in Jiamusi University were detected, including 257 males and 116 females aged from 18 to 29. All foreign students come from India. They just communicated with local students since entering university. However, they don’t live and study at the same place with local students. 588 local students took part in this study, including 285 males and 303 females aged from 18 to 24. Meanwhile, 91% of local students come from Heilongjiang province and 9% of local students come from other provinces of China (including

Xinjiang and Tibet). Informed consent was obtained from all participants included in the study. The study was approved by the ethical committee of Jiamusi University.

2.2. Demodex Examination

The sampling and counting of *demodex* mites can be affected by personal and environmental conditions. Therefore, all measurements were made from the same region of the face (two side of nasolabial groove), in the same room of the parasitology laboratory to reduce any errors in the techniques and microscopic examinations.

In this study, skin scraping was used to identify the presence of *demodex* mites as a qualitative method. [14] Using scraper to obtain secretions, and then put the secretions to the drop of glycerol on a glass slide. The sample was covered with a cover glass and examined for parasites by light microscopy at 10× and 40× objective.

2.3. Statistical Analysis

The collected data were analyzed using graphpad prism 7 software. The infection rate was calculated for each population and the χ^2 test was used for comparison between groups. Inspection level $\alpha = 0.05$.

3. Results

3.1. Infection Status

Among the 963 students examined, 260 students were infected by *demodex*, which the rate of positive infection was 27%. In international students the rate of *demodex* infection was 15.2% (57/375); 17.1% (44/257) for male and 11.2% (13/116) for female; However, in local students the rate of *demodex* infection was 34.5% (203/588); 47.4% (135/286) for male and 22.4% (68/303) for female. There was a statistically significant difference to the rate of *demodex* infection between international male students and local male students ($\chi^2 = 55.9, P < 0.05$). In addition, there was no statistical difference to the prevalence of infection among international students ($\chi^2 = 2.159, P > 0.05$). However, there was a statistically significant difference to the prevalence of infection among local students ($\chi^2 = 40.37, P < 0.05$) (Table 1).

Table 1. Infection status in international students and local students.

Projects	Group	Foreign students			Local students		
		Total number	male	female	Total number	male	female
Sample size		375	257	116	588	285	303
Positive number		57	44	13	203	135	68
Infection rate (%)		15.2%	17.1%	1.2%	34.5%	47.4%	22.4%

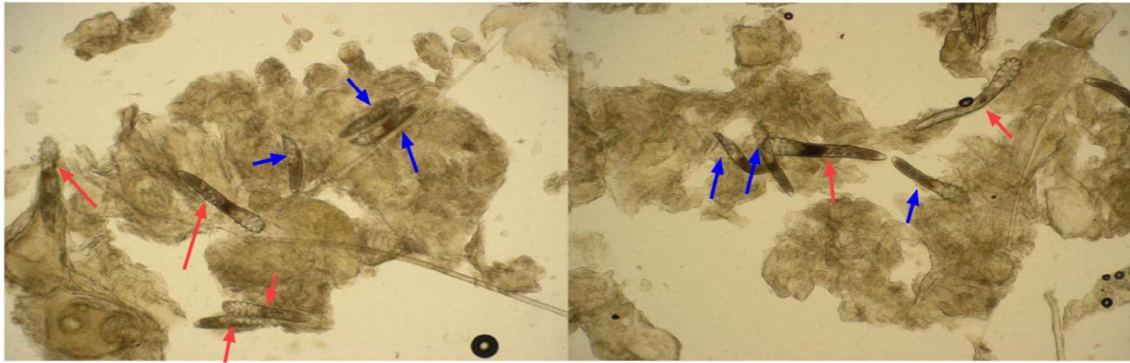
3.2. Infectious Species

The total infection rates of *D.f*, *D.b* and mixed infection were 61.9% (161/260), 25% (65/260) and 13.1% (34/260) respectively. Compared with local students, in foreign students the infection rate of *D.f* was the highest, accounting

for 63.2% (36/57), and has no statistically significant ($\chi^2 = 0.047, P > 0.05$), the infection rate of *D.b* was 22.8% (13/57), the lowest infection rate was mixed infection, accounting for 14% (8/57). However, in total students, local male students had the highest infection rate of *D.f*, accounting for 69.6% (94/135); while local female students had the highest

infection rate of mixed, accounting for 45.6% (15/68). It is worth to mentioning, we found 13 *demodex* mite in one slide

and were mixed infection (Figure 1).



Red arrow: Demodex folliculorum, Blue arrow: Demodex brevis

Figure 1. Two species of demodex in one slide (400×).

Table 2. Facial mite infections of international students and local students at Jiamusi University.

Subjects	Species of infectious mite						
	D.f		D.b		Mixed		
	Positive number	Positive rate/%	Positive number	Positive rate/%	Positive number	Positive rate/%	
International male	44	28	63.6	10	22.7	6	13.6
female	13	8	61.5	3	23	2	15.4
Local student male	135	94	69.6	30	22.2	11	8.1
female	68	31	45.6	22	32.4	15	22.1
Total	260	161	61.9	65	25	34	13.1

3.3. Facial Skin Condition and Infection Rate

Among the international students, there were 60 students, which have acne, folliculitis, rosacea or flushing on the facial skin. However, only 8 of 46 students were detected *demodex* mite infection. The infection rate of *demodex* was 13.3% (8/60). The rate of asymptomatic infection was 15.6%

(49/315). The difference was not statistically significant ($\chi^2 = 0.193, P > 0.05$). In local students, 88 students have facial skin symptoms, and 60 cases of them were detected *demodex* mite infection, accounting for 67.9% (112/165). In addition, the rate of asymptomatic infection was 21.5% (91/423). The difference was statistically significant ($\chi^2 = 112.9, P < 0.05$) (Table 3).

Table 3. Facial skin condition and infection rate.

subjects	Foreign student		Local student	
	Student for normal facial skin	Student for abnormal facial skin (Acne, folliculitis, rosacea, flushing)	Student for normal facial skin	Student for abnormal facial skin (Acne, folliculitis, rosacea, flushing)
Sample size	315	60	423	165
Positive number	49	8	91	112
Infection rate (%)	15.6	13.3	21.5	67.9

4. Discussion

Demodex are cosmopolitan mites occurring in many species of mammals, and was regard as the most common ectoparasite in humans. [15] Two morphologically distinct *demodex* species parasitize on humans: *Demodex folliculorum* (D.f; Simon, 1842) and *Demodex brevis* (D.b; Akbulatova, 1963). D.f and D.b are ectoparasites with a prevalence of 100% in patients aged 96 and older. [16-17] In people, *Demodex spp.* can be found mainly in the sebaceous glands of the skin (the forehead, chin, and around the eyes and mouth). They are also observed on the pileous skin of the head, on hairy chests or in the genital area. [18-21] Nevertheless, the infection rates of *demodex* in various

regions is different, the infection rate in adults ranged infection from 27% to 100%. [22] In this study, 375 foreign students were surveyed, 57 of whom were infected by *demodex mite*, the rate of positive infection was 15.2%. 588 local students also were surveyed at the same time, 203 of whom were infected by *demodex mite*, the rate of positive infection was 34.5%. Interestingly, we found that the infection rate of *demodex* is very different between foreign students and local students. In addition, it is obviously lower than that data reported in relevant papers in foreign students. Therefore, we have comprehensively analyzed the key point of differences in epidemiological surveys. Based on the performed analyses, it was determined that examination methods, examination season, temperature, living environment, human race have impact on *demodex* infection.

In addition, all students come from medical schools and possessed certain medical knowledge, since they know how to prevent *demodex* infection compared with ordinary students. *Demodex* positivity is affected by many factors, including season, temperature, light, insect species, human health and hygiene habits, human race, endocrine metabolism, cosmetics and drinking etc; which were the key factors in spreading the epidemic. [23-24] In addition, different examination methods also affect *demodex* positivity. Nowadays, there were many new methods to check *demodex* infection. The confocal microscope (CLSM) imaging technology has high diagnostic efficiency for facial *demodex* and it has advantages including being in-body, non-invasive painless, real-time and dynamic. However, it can not be used as a clinically universal diagnostic method because of its high price. [25] To be mentioned, researcher clarified that the infection rate of *D. folliculorum* in females is higher than that in males. [7] Inconformity, in this survey, results found that the infection rate of *D.f* in total male from foreign students and local students is higher than that in total female from foreign students and local students. However, at present we don't know what is the main reason for the infection difference between literature report and in this survey.

This survey found that *demodex* positivity in local students, not foreign students, correlated with skin status. *Demodex* positivity in symptomatic facial skin of local students is significantly higher than in asymptomatic individuals. However, there was no significant correlation between the infection rate of *demodex* and facial skin conditions in foreign students. To be mentioned, most of foreign students were dry skin without excessive secretion of sebum thus patients with rosacea, acne and seborrheic dermatitis were rare. Because *demodex* infection can induce appearance or aggravation of facial skin symptoms, patients with rosacea, acne and seborrheic dermatitis need detection and treatment early in order to reduce or avoid appearance or aggravation of facial skin symptoms.

5. Conclusion

Demodex positivity is affected by many factors. The race, living environment and facial skin conditions are the main reasons for the difference in *demodex* positivity between foreign students and local students. Although *demodex* infection is less harmful, there is no way to control the prevalence of *demodex* leading to damage of facial skin, including rosacea and acne-like skin rashes and so on. *Demodex* infection not only affecting the physical health, but also influencing mental health in young people. Therefore, detection, prevention and treatment during early stage of *demodex* infection is of the utmost importance.

Acknowledgements

The authors would like to acknowledge members of the

research group for helpful discussions on the related subject matter of this paper. This work was supported by grants from 2015 record project of heilongjiang education science "12th five-year plan" (NO. GJC1215067); innovation project of university students in education department of Heilongjiang province (201610222065); Youth fund project of Jiamusi University (Sq2013-020).

References

- [1] Rusiecka-Ziółkowska J, Nokiel M, Fleischer M. Demodex - an old pathogen or a new one? *Adv Clin Exp Med.* 2014; 23 (2):295-298.
- [2] Cheng AM, Sheha H, Tseng SC. Recent advances on ocular Demodex infestation. *Curr Opin Ophthalmol.* 2015; 26 (4):295-300.
- [3] Czepita D, Kuźnia-Grygiel W, Kosik-Bogacka D. badania nad występowaniem oraz rolą Demodex folliculorum i Demodex brevis w patogenezie przewlekłego zapalenia powiek *Klin Oczna* 2005, 107, 80–82.
- [4] Luo X, Li J, Chen C, Tseng S, Liang L. Ocular Demodicosis as a Potential Cause of Ocular Surface Inflammation. *Cornea.* 2017; 36 Suppl 1:S9-S14.
- [5] Mongi F, Laconte L, Casero RD. Demodex genus: colonizing parasites of healthy people or mites associated with ocular pathology? *Rev Argent Microbiol.* 2018; pii: S0325-7541 (17) 30179-7.
- [6] Bohdanowicz D, Raszeja-Kotelba B. Demodex w etiopatogenezie niektórych chorób skóry. *Post dermatol alergol.* 2001, 8, 51-58.
- [7] Raszeja-Kotelba B, Jenerowicz D, Izdebska JN, Bowszyc-Dmochowska M, Tomczak M, Dembińska M: Niektóre aspekty zakażenia skóry nużeńcem ludzkim. *Wiad Parazytol.* 2004, 50, 41-54.
- [8] Wesołowska M, Baran W, Szepietowski J, Hirschberg L, Jankowski S: demodekoza u ludzi jako aktualny problem w dermatologii. *Wiad Parazytol.* 2005, 51, 253-256.
- [9] Nath AK, Timshina DK, Thappa DM, Sinclair R: demodex in an aerobic environment on the eyelashes. *australasJ dermatol* 2012, 53, 159-160.
- [10] Yuan C, Zheng SL, Ma YF, Philippe J, Philippe H. Cleanser use could decrease numbers of Demodex Folliculorum in mild to moderate acne patients. *Dermatoendocrinol.* 2017; 9 (1):e1348444.
- [11] Ahn CS, Huang WW. Rosacea Pathogenesis. *Dermatol Clin.* 2018; 36 (2):81-86.
- [12] Liu J, Sheha H, Tseng SC. Pathogenic role of Demodex mites in blepharitis. *Curr Opin Allergy Clin Immunol.* 2010; 10:505–510.
- [13] Post CF, Juhlin E. Demodex folliculorum blepharitis. *Arch Dermatol* 1963; 88:298–302.
- [14] Pereira AV, Pereira SA, Gremião ID, Campos MP, Ferreira AM. Comparison of acetate tape impression with squeezing versus skin scraping for the diagnosis of canine demodicosis. *Aust Vet J.* 2012; 90 (11):448-50.

- [15] Myers P, Espinosa R, Parr CS, Jones T, Hammond GS, Dewey TA. Animal Diversity Web: *Demodex folliculorum*. University of Michigan; 2000. Available at: http://animaldiversity.ummz.umich.edu/accounts/Demodex_folliculorum/classification/. Accessed March 16, 2013.
- [16] Vargas-Arzola J, Reyes-Velasco L, Segura-Salvador A, Márquez-Navarro A, Díaz-Chiguer DL, Noguera-Torres B. Prevalence of *Demodex* mites in eyelashes among people of Oaxaca, Mexico. *Acta Microbiol Immunol Hung*. 2012; 59 (2): 257-262.
- [17] Litwin D, Chen W, Dzika E, Korycińska J. Iran J Parasitol. 2017 Jan-Mar; 12 (1):12-21. Human Permanent Ectoparasites; Recent Advances on Biology and Clinical Significance of *Demodex* Mites: Narrative Review Article. Iran J Parasitol. 2017 Jan-Mar; 12 (1):12-21.
- [18] Bohdanowicz D, Raszeja-Kotelba B: *Demodex* w etiopatogenezie niektórych chorób skóry. *Post dermatol alergol* 2001, 8, 51–58.
- [19] Raszeja-Kotelba B, Jenerowicz D, Izdebska JN, Bowszyc-Dmochowska M, Tomczak M, Dembińska M: Niektóre aspekty zakażenia skóry nużeńcem ludzkim. *Wiad Parazytol* 2004, 50, 41–54.
- [20] Wesołowska M, Baran W, Szepietowski J, Hirschberg L, Jankowski S: demodekoza u ludzi jako aktualny problem dermatologii. *Wiad Parazytol* 2005, 51, 253–256.
- [21] Nath AK, Timshina DK, Thappa DM, Sinclair R: demodex in an aerobic environment on the eyelashes. *australasJ dermatol* 2012, 53, 159–160.
- [22] Wu Guanling. *Human Parasitology* [M] . 3rd Edition. Beijing People's Medical Publishing House, 2005: 1034.
- [23] Ru-Juan Z, Xue-Rong Y, Ying Z, Yi-Ning P, Wen-Ting X, Ting-Ting H, Yan Y, Jin-Hong Z. Investigation on *Demodex* infection status and influencing factors in medical students in Wuhu City. *Zhongguo Xue Xi Chong Bing Fang Zhi Za Zhi*. 2017; 29 (3):358-362.
- [24] Litwin D, Chen W, Dzika E, Korycińska J. Human Permanent Ectoparasites; Recent Advances on Biology and Clinical Significance of *Demodex* Mites: Narrative Review Article. Iran J Parasitol. 2017; 12 (1):12-21.
- [25] Sattler EC, Maier T, Hoffmann VS, Hegyi J, Ruzicka T, Berking C. Noninvasive in vivo detection and quantification of *Demodex* mites by confocal laser scanning microscopy. *Br J Dermatol*. 2012; 167 (5):1042-1047.