

---

**Review Article**

# Imaging Features of COVID-19: A Review Article

**Daba Abdissa**

Institute of Health, School of Medical Sciences, Jimma University, Oromia, Ethiopia

**Email address:**

dhaabaa4@gmail.com, daba.abdissa@ju.edu.et

**To cite this article:**Daba Abdissa. Imaging Features of COVID-19: A Review Article. *American Journal of Clinical and Experimental Medicine*. Vol. 8, No. 5, 2020, pp. 96-100. doi: 10.11648/j.ajcem.20200805.13**Received:** October 9, 2020; **Accepted:** October 23, 2020; **Published:** November 23, 2020

---

**Abstract:** *Background:* COVID-19, which is predominantly transmitted by contact between people, turns out to be a public health emergency of international concern and it lacks specificity in both clinical manifestations and laboratory tests. It mainly causes inflammatory lesions in the lungs and can also cause injury to other major organs. Imaging methods have an important role in the diagnosis and evaluation of treatment strategies for COVID-19. Computed tomography plays an important role in the diagnosis and evaluation of the severity in compliment with the RT-PCR test. Comprehensive analysis of the patient's epidemiological history, clinical symptoms, laboratory test and imaging manifestations are necessary in order to early detection, early isolation, and early management. *Objective:* The purpose of this review was to summarize the radiographic, CT patterns and ultrasonographic features of COVID-19 pneumonia in order to help health professionals for reliable basis for early diagnosis and management of COVID-19. *Methods:* The literature search for this document was carried out comprehensively by accessing PubMed, Google scholar, Web-of-Science and other data bases. In addition helpful documents were added. *Result and conclusion:* The most common CT features of COVID-19 are peripherally distributed ground glass opacities, crazy paving pattern and patchy consolidation. Lung ultrasound has a key role in the clinical management of patients with COVID-19 associated lung injury.

**Keywords:** COVID-19, Chest CT, Chest X-ray

---

## 1. Introduction

Coronavirus Disease 2019 (COVID-19), which is mainly transmitted by contact between people, turns out to be a public health emergency of international concern. The COVID-19 pandemic brings to a huge burden on healthcare services, particularly in patients with comorbidities [1]. It lacks specificity in both clinical manifestations and laboratory tests. Common symptoms include cough, fever, myalgia and fatigue. A small number of patients can have headache or hemoptysis and even relatively asymptomatic [2]. Affected older men with comorbidities are more likely to have respiratory failure due to severe alveolar damage [3].

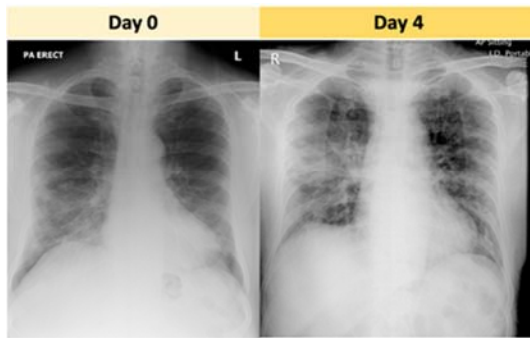
At present, the diagnosis of COVID-19 depends on reverse transcription-polymerase chain reaction (RT-PCR) or gene sequencing of throat swab, sputum or lower respiratory tract secretion [4, 5]. However, these methods are time-consuming, high false negative rate and do not allow assessing the disease severity. Imaging, in particular chest x-ray and computed

tomography (CT) are important in the detection of lung lesions, assessment of lesion size and density [2].

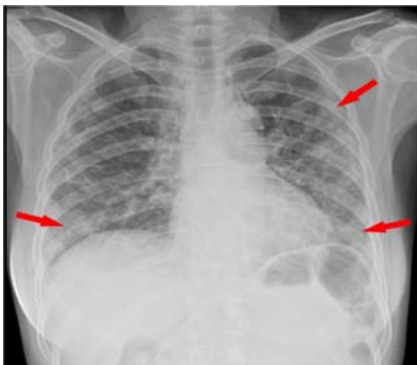
CT imaging can demonstrate typical features making the diagnosis of COVID-19 quite likely, which can help to rapidly screen patients, and to stratify the patients' severity to develop effective treatment strategies [6]. Imaging features differ in different individuals and stages of the COVID-19 pneumonia. Disease progression commonly occurs in 7-10 days, with increased density of ground glass opacity, and consolidated lesions with air bronchogram sign [7, 8]. Critical patients tend to have worse outcome and high mortality. The image changes essentially reflect the inflammatory pathological process of lung tissue-exudation and proliferation [9]. The imaging feature of COVID-19 has been relatively deficient and scattered. Thus in this review, I tried summarize the radiographic, CT patterns and ultrasonographic features of COVID-19 using available evidence pneumonia in order to help health professionals for reliable basis for early diagnosis and management of COVID-19.

## 2. Chest X-ray

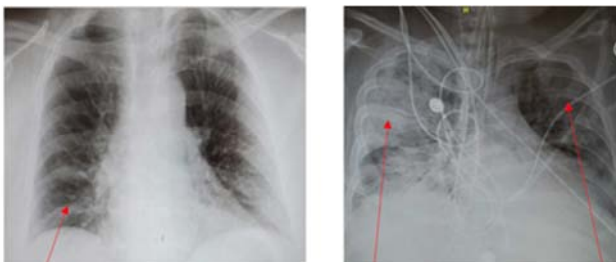
Chest imaging is used for diagnosis and document the extent of the lesions and enables accurate observations of changes in the affected area. However, it is not recommended for patients with early stage of disease, because the sensitivity and specificity for mild type patients are relatively low [10, 11]. It is suitable for primary hospitals which do not have CT machines and for the follow up of critically ill patients, but has lower sensitivity than Chest CT.



**Figure 1.** Chest radiographs of an elderly COVID-19 male patient. The consolidation in the right lower zone on day 0 persists into day 4 with new consolidative changes in the right mid-zone periphery and peri-hilar region [10].



**Figure 2.** Chest radiograph of COVID-19 pneumonia. Multifocal patchy opacities and multifocal consolidation were seen in both lungs (arrows) [18].



**Figure 3.** Early and late stage x-ray findings of COVID-19 A) Early stage chest radiography may be normal or show very small changes like ill-defined consolidation B) Late stage chest x-ray shows acute respiratory distress syndrome like multiple consolidations, disruption of lung architecture [19].

The typical radiological imaging of COVID-19 pneumonia showed lower lobe involvement, bilateral and peripheral distribution of opacities with destruction of the pulmonary parenchyma [4, 7, 12]. With the advance of the disease, it may

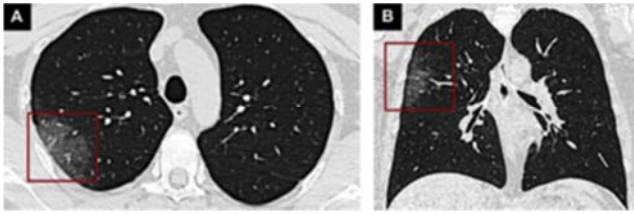
present as a patchy distribution or multiple consolidations [11, 13, 14]. In severe and critical type COVID-19 pneumonia, multifocal or diffuse consolidation can be seen in both lungs, forming white lung (Figures 1, 2) [4, 15, 16]. In early disease course it may be normal and tends to peak 10-12 days after onset of clinical manifestations (Figure 3) [17].

## 3. Chest CT Scan

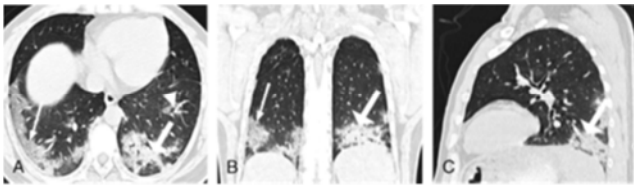
Chest CT plays an important role in diagnosis and management of patients with COVID-19. It helps in detecting important warning signals for patients with negative virus nucleic acid test, to monitor treatment outcome, for early detection of other complications and to assess disease severity [13, 20, 21]. It can demonstrate typical features making the diagnosis of COVID-19 quite likely, which can help to rapidly screen patients, and to stratify the patients' severity to quickly develop effective treatment strategies. Furthermore, it can demonstrate almost all abnormalities including early mild exudative lesions. It is the most valuable imaging tool for the clinical diagnosis of early stage COVID-19 pneumonia and can prompt larger public health surveillance and response systems [10, 22-24]. Thin slice chest CT functions more effectively in early detection and evaluation of this disease [2, 10].

The common chest CT findings of COVID-19 cases were multiple ground glass opacity (GGO), consolidation, bronchial wall thickening and interlobular septal thickening which are mostly seen under the pleura. Ground glass opacity is hazy areas with slightly increased density without blockade of bronchial vessels and vascular margins which are caused by the exudation of alveoli. Increasing numbers and density of GGOs indicates disease progression. Consolidation is when alveolar air being replaced by inflammatory exudation and manifested by obscuring the margins of underlying vessels and air way walls [25]. The main CT findings of COVID-19 pneumonia in the early phases were GGO and crazy paving and larger consolidations in the basal lung regions occurs later in the disease course [26]. Crazy paving pattern is thickening of interlobular septa and intralobular lines resembling irregular paving stones. Consolidation, air bronchogram, extensive distribution involved lung zones was more common features among mortality group. Air bronchogram is a pattern of air filled bronchi on background of opaque airless lung (Figures 4-8) [27].

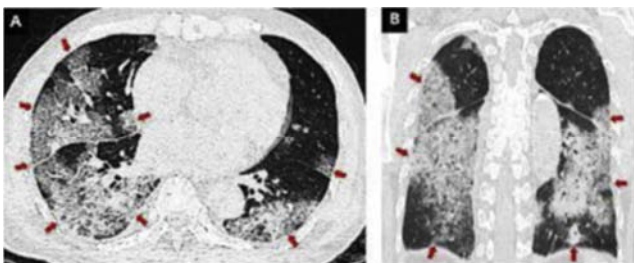
The type and size of CT abnormalities are related to disease severity. The regions most frequently affected are the right middle and lower lobes followed by the left upper lobe [28]. Less common findings include pleural effusion, stretch bronchiectasis, and thoracic lymphadenopathy [9, 21, 29, 30]. Furthermore, according to Liu K et al patchy GGO and large consolidation located in the peripheral part of both lungs are the typical CT manifestations of COVID-19 [6].



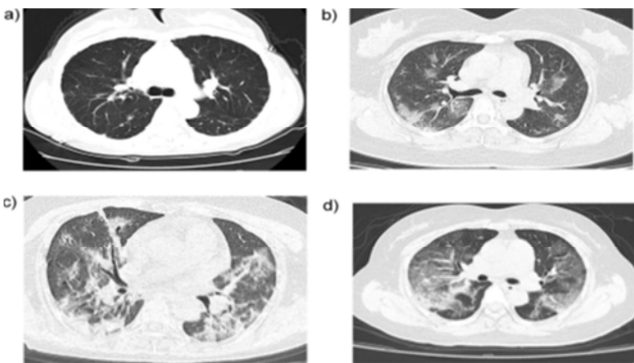
**Figure 4.** Chest CT findings of early-stage COVID-19 case shows a unilateral pure GGO lesion (red rectangles) in the posterior segment of the right upper lobe on axial (A) and coronal view (B) 9 [30].



**Figure 5.** Chest CT of COVID-19 patient. Ground glass opacity (GGO) (white triangle), consolidation (white thick arrow), and interlobular septal thickening (white thin arrow) distributed under the pleura [21].

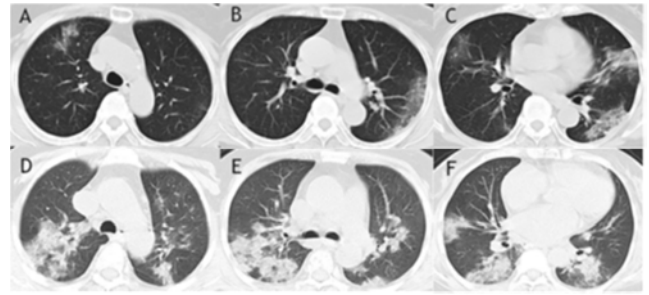


**Figure 6.** CT findings in critically ill COVID-19 patient. The axial (A) and coronal view (B) of unenhanced chest CT images show diffuse GGO with multiple consolidations in both lungs, giving the white lung appearance as indicated by red arrows [30].



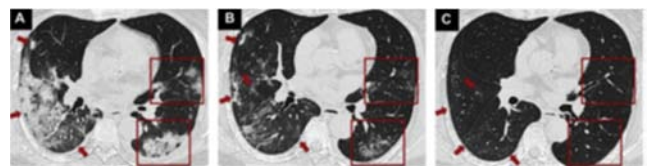
**Figure 7.** CT features of COVID-19 by disease severity. A) An axial CT image in a 33-year-female mild type patient (2 days from symptom onset to CT scan) shows thickening of lung texture. B). An axial CT image in a 37-year-male common type patient (6 days from symptom onset to CT scan) shows multiple GGO in both lungs. C) An axial CT image in a 56-year-female severe type patient shows extensive GGO and pulmonary consolidation, enlargement of bronchi and vessels. D) An axial CT image in a 47-year-female critical type patient (9 days from symptom onset to CT scan) shows extensive GGO in multiple lobes, forming white lung [6].

According to Huang P et al a 36 year old man in china who has suspected with COVID-19, but chest CT findings were suggestive for the disease from the beginning who was followed and finally positive on laboratory test [31].



**Figure 8.** Comparison of CT images between survival group and mortality group. CT images of a 76-year-old woman from survival group revealed pure GGO with predominant peripheral distribution in middle and lower lung zones (A-C). Air bronchogram, together with extensive of consolidations and GGO were found in the CT images of a 72-year-old woman from mortality group (D-F) [27].

Patients recovering from COVID-19 can be traced with CT to evaluate for long-term lung damage [4]. During repair and healing of chronic inflammation, fibrous components gradually replace the normal cellular components to form scars. Fibrous lesions can cause distracted bronchi or bronchiectasis and distorted travel. In recovery stage patients, the lesion area is reduced and absorbed, or only residual fibrous lesions were seen (Figure 9) (26, 32).



**Figure 9.** CT findings during the absorption period of COVID-19. Lung findings on chest CT were patchy GGO and mass consolidation in both lungs (A, red rectangles and arrows). Lung lesions gradually absorbed on the CT five days later (B, red rectangles and arrows). After ten days, a few ill-defined GGOs remained in both lungs (C, red rectangles and arrows) [30].

Furthermore, according to Guan CS et al. on 53 patients COVID-19 all showed GGO, 89.4% “crazy-paving pattern”, 63.8% consolidation, and 76.6% air bronchus sign on thin-section CT [33]. Air bronchus sign refers to the phenomenon of dendritic low-density shadowing of air containing bronchus in the consolidation of lung tissue, which is more common in the progress of the disease. The pathological basis is that the pathogen invades epithelial cells, causing inflammatory thickening and swelling of bronchial wall, but without obstructing the bronchioles [34].

### 4. Ultrasound Imaging

It plays an important role in the diagnosis and management of patients with COVID-19. It can detect changes in superficial lung parenchyma with greater accuracy [35]. Compared with other monitoring modalities such as chest radiograph it has high diagnostic accuracy and ergonomically favourable [36]. However, sonographic signs are nonspecific when considered alone, but observation of some aspects of vertical artifacts increase its diagnostic power. Combination of sonographic features with blood exams allows reliable

characterization of COVID-19 [37].

As it progresses is associated with the sonographic appearances of pleural line irregularities, increase in consolidations and B-line artefacts, which are caused by interstitial thickening due to inflammation (Figure 10-11). B lines are visualized in all their possible forms and COVID-19 pneumonia can be described as storm of clusters of B lines giving the appearance of shining white lung [38]. The use of six-zone scanning would provide a focused and rapid picture of involvement of key regions of the lung and experience is required for the operator to generate high-quality image [39]. The noncritical COVID-19 cases were characterized by large number of B lines and sub-pleural pulmonary consolidation [40].

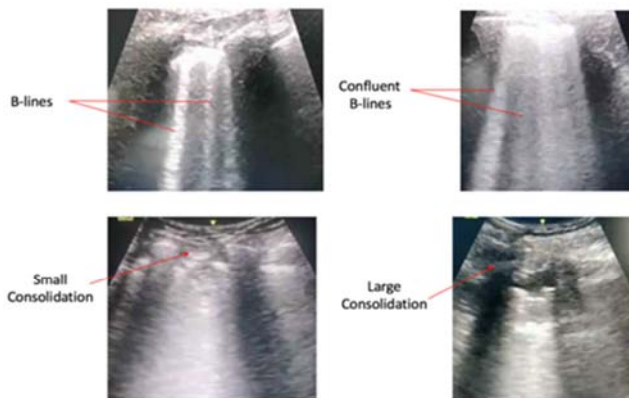


Figure 10. Lung ultrasound in patients with COVID-19 [19].

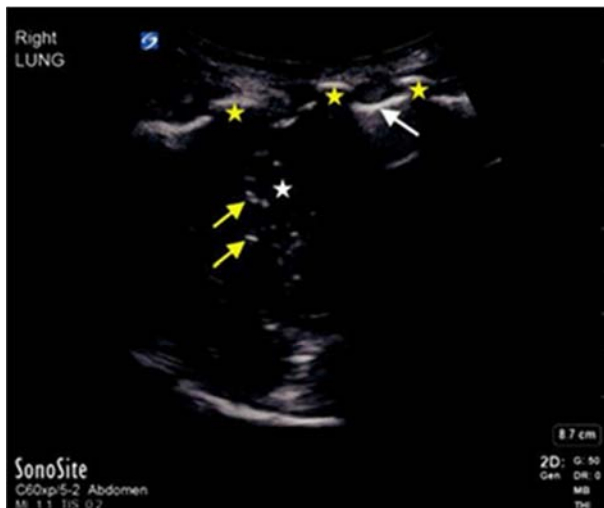

Figure 11. Ultrasound image showing right lung consolidation with hepatization (white star), air bronchograms (yellow arrows); pleural line (white arrow), ribs (yellow star) [41].

## 5. Conclusion

Combined imaging techniques, clinical symptoms, and laboratory tests facilitates the diagnosis of COVID-19. Imaging techniques are important in the detection of lung lesions, its size, density, and evolution. The common chest CT findings of COVID-19 cases are multiple GGO, consolidation

and bronchial wall thickening. The type and size of CT abnormalities are related to disease severity. Chest imaging can be used both for diagnosis and to document the extent of the lesions caused by COVID-19. The lung ultrasound has a key role to play in the clinical management of patients with COVID-19 associated lung injury.

## References

- [1] World Health Organization. Coronavirus disease 2019 (COVID-19): situation report, 52. World Health Organization (2020). <https://apps.who.int/iris/handle/10665/331476>.
- [2] Chan JF, Yuan S, Kok KH, To KK, Chu H, Yang J, Xing F, Liu J, Yip CC, Poon RW, Tsoi HW. A familial cluster of pneumonia associated with the 2019 novel coronavirus indicating person-to-person transmission: a study of a family cluster. *The Lancet*. 2020 Feb 15; 395 (10223): 514-23.
- [3] Chen N, Zhou M, Dong X, Qu J, Gong F, Han Y, Qiu Y, Wang J, Liu Y, Wei Y, Yu T. Epidemiological and clinical characteristics of 99 cases of 2019 novel coronavirus pneumonia in Wuhan, China: a descriptive study. *The Lancet*. 2020 Feb 15; 395 (10223): 507-13.
- [4] Corman VM, Landt O, Kaiser M, Molenkamp R, Meijer A, Chu DK, Bleicker T, Brünink S, Schneider J, Schmidt ML, Mulders DG. Detection of 2019 novel coronavirus (2019-nCoV) by real-time RT-PCR. *Eurosurveillance*. 2020 Jan 23; 25 (3): 2000045.
- [5] Li G, Fan Y, Lai Y, Han T, Li Z, Zhou P, Pan P, Wang W, Hu D, Liu X, Zhang Q. Coronavirus infections and immune responses. *Journal of medical virology*. 2020 Apr; 92 (4): 424-32.
- [6] Liu KC, Xu P, Lv WF, Qiu XH, Yao JL, Jin-Feng G. CT manifestations of coronavirus disease-2019: a retrospective analysis of 73 cases by disease severity. *European journal of radiology*. 2020 Mar 12: 108941.
- [7] Chung M, Bernheim A, Mei X, Zhang N, Huang M, Zeng X, Cui J, Xu W, Yang Y, Fayad ZA, Jacobi A. CT imaging features of 2019 novel coronavirus (2019-nCoV). *Radiology*. 2020 Apr; 295 (1): 202-7.
- [8] W. Kong, P. P. Agarwal, Chest imaging appearance of COVID-19 infection, *Radiology: Cardiothoracic Imaging*. (2020) e200028.
- [9] Koo HJ, Lim S, Choe J, Choi SH, Sung H, Do KH. Radiographic and CT features of viral pneumonia. *Radiographics*. 2018 May; 38 (3): 719-39.
- [10] Ng MY, Lee EY, Yang J, Yang F, Li X, Wang H, Lui MM, Lo CS, Leung B, Khong PL, Hui CK. Imaging profile of the COVID-19 infection: radiologic findings and literature review. *Radiology: Cardiothoracic Imaging*. 2020 Feb 13; 2 (1): e200034.
- [11] Guan WJ, Ni ZY, Hu Y, Liang WH, Ou CQ, He JX, Liu L, Shan H, Lei CL, Hui DS, Du B. Clinical characteristics of coronavirus disease 2019 in China. *New England journal of medicine*. 2020 Apr 30; 382 (18): 1708-20.
- [12] Huang C, Wang Y, Li X, Ren L, Zhao J, Hu Y, Zhang L, Fan G, Xu J, Gu X, Cheng Z. Clinical features of patients infected with 2019 novel coronavirus in Wuhan, China. *The lancet*. 2020 Feb 15; 395 (10223): 497-506.

- [13] Tian S, Xiong Y, Liu H, Niu L, Guo J, Liao M. Pathological study of the 2019 novel coronavirus disease (COVID-19) through postmortem core biopsies. *Mod Pathol* 2020.
- [14] Xu XW, Wu XX, Jiang XG, Xu KJ, Ying LJ, Ma CL, Li SB, Wang HY, Zhang S, Gao HN, Sheng JF. Clinical findings in a group of patients infected with the 2019 novel coronavirus (SARS-Cov-2) outside of Wuhan, China: retrospective case series. *bmj*. 2020 Feb 19; 368.
- [15] Yang X, Yu Y, Xu J, Shu H, Liu H, Wu Y, Zhang L, Yu Z, Fang M, Yu T, Wang Y. Clinical course and outcomes of critically ill patients with SARS-CoV-2 pneumonia in Wuhan, China: a single-centered, retrospective, observational study. *The Lancet Respiratory Medicine*. 2020 Feb 24.
- [16] Salehi S, Abedi A, Balakrishnan S, Gholamrezanezhad A. Coronavirus disease 2019 (COVID-19): a systematic review of imaging findings in 919 patients. *American Journal of Roentgenology*. 2020 Mar 14: 1-7.
- [17] Wong HYF, Lam HYS, Fong AH et al Frequency and distribution of chest radiographic findings in COVID-19 positive patients *Radiology* 2020.
- [18] Zu ZY, Jiang MD, Xu PP, Chen W, Ni QQ, Lu GM, Zhang LJ. Coronavirus disease 2019 (COVID-19): a perspective from China. *Radiology*. 2020 Feb 21: 200490.
- [19] Fatima S, Ratnani I, Husain M, Surani S. Radiological Findings in Patients with COVID-19. *Cureus*. 2020 Apr; 12 (4).
- [20] Ren LL, Wang YM, Wu ZQ, Xiang ZC, Guo L, Xu T, Jiang YZ, Xiong Y, Li YJ, Li XW, Li H. Identification of a novel coronavirus causing severe pneumonia in human: a descriptive study. *Chinese medical journal*. 2020 Feb 11.
- [21] Wu J, Wu X, Zeng W, Guo D, Fang Z, Chen L, Huang H, Li C. Chest CT findings in patients with coronavirus disease 2019 and its relationship with clinical features. *Investigative radiology*. 2020 May 1; 55 (5): 257-61.
- [22] Kanne JP. Chest CT findings in 2019 novel coronavirus (2019-nCoV) infections from Wuhan, China: key points for the radiologist.
- [23] Pan Y, Guan H, Zhou S, Wang Y, Li Q, Zhu T, Hu Q, Xia L. Initial CT findings and temporal changes in patients with the novel coronavirus pneumonia (2019-nCoV): a study of 63 patients in Wuhan, China. *European radiology*. 2020 Feb 13: 1-4.
- [24] Xiong Y, Sun D, Liu Y, Fan Y, Zhao L, Li X, Zhu W. Clinical and high-resolution CT features of the COVID-19 infection: comparison of the initial and follow-up changes. *Investigative radiology*. 2020.
- [25] Hansell DM, Bankier AA, MacMahon H, McLoud TC, Muller NL, Remy J. Fleischner Society: glossary of terms for thoracic imaging. *Radiology*. 2008 Mar; 246 (3): 697-722.
- [26] Pan F, Ye T, Sun P, Gui S, Liang B, Li L, Zheng D, Wang J, Hesketh RL, Yang L, Zheng C. Time course of lung changes on chest CT during recovery from 2019 novel coronavirus (COVID-19) pneumonia. *Radiology*. 2020 Feb 13: 200370.
- [27] Yuan M, Yin W, Tao Z, Tan W, Hu Y. Association of radiologic findings with mortality of patients infected with 2019 novel coronavirus in Wuhan, China. *Plos one*. 2020 Mar 19; 15 (3): e0230548.
- [28] Yoon SH, Lee KH, Kim JY, Lee YK, Ko H, Kim KH, Park CM, Kim YH. Chest radiographic and CT findings of the 2019 novel coronavirus disease (COVID-19): analysis of nine patients treated in Korea. *Korean journal of radiology*. 2020 Apr 1; 21 (4): 494-500.
- [29] Webb WR. Thin-section CT of the secondary pulmonary lobule: anatomy and the image the 2004 Fleischner lecture. *Radiology*. 2006 May; 239 (2): 322-38.
- [30] Yang Q, Liu Q, Xu H, Lu H, Liu S, Li H. Imaging of coronavirus disease 2019: A Chinese expert consensus statement. *European Journal of Radiology*. 2020 Apr 18: 109008.
- [31] Huang P, Liu T, Huang L, Liu H, Lei M, Xu W, Hu X, Chen J, Liu B. Use of chest CT in combination with negative RT-PCR assay for the 2019 novel coronavirus but high clinical suspicion. *Radiology*. 2020 Apr; 295 (1): 22-3.
- [32] Duan YN, Qin J. Pre-and posttreatment chest CT findings: 2019 novel coronavirus (2019-nCoV) pneumonia. *Radiology*. 2020 Apr; 295 (1): 21.
- [33] Guan CS, Lv ZB, Yan S, Du YN, Chen H, Wei LG, Xie RM, Chen BD. Imaging features of coronavirus disease 2019 (COVID-19): evaluation on thin-section CT. *Academic radiology*. 2020 Mar 20.
- [34] Li HJ, Liu SY, Xu HB, Cheng JL. Guideline for medical imaging in auxiliary diagnosis of coronavirus disease 2019. *Chin J Med Imaging Technol*. 2020; 36 (3): 321-31.
- [35] Soldati G, Smargiassi A, Inchingolo R, Buonsenso D, Perrone T, Briganti DF, Perlini S, Torri E, Mariani A, Mossolani EE, Tursi F. Is there a role for lung ultrasound during the COVID - 19 pandemic?. *Journal of Ultrasound in Medicine*. 2020 Mar 20.
- [36] Smith MJ, Hayward SA, Innes SM, Miller AS. Point - of - care lung ultrasound in patients with COVID - 19—a narrative review. *Anaesthesia*. 2020 Apr 10.
- [37] Volpicelli G, Gargani L. Sonographic signs and patterns of COVID-19 pneumonia. *The Ultrasound Journal*. 2020 Dec; 12 (1): 1-3.
- [38] Peng QY, Wang XT, Zhang LN, Chinese Critical Care Ultrasound Study Group. Findings of lung ultrasonography of novel corona virus pneumonia during the 2019–2020 epidemic. *Intensive care medicine*. 2020 Mar 12: 1.
- [39] Lichtenstein DA, Meziere GA. Relevance of lung ultrasound in the diagnosis of acute respiratory failure\*: the BLUE protocol. *Chest*. 2008 Jul 1; 134 (1): 117-25.
- [40] Yi Huang, Sihan Wang, Yue Liu et al. A preliminary study on the ultrasonic manifestations&nbsp; of peripulmonary lesions of non-critical novel coronavirus pneumonia (COVID-19) &nbsp; nbsp; 26 February 2020, PREPRINT.
- [41] Jackson K, Butler R, Aujayeb A. Lung ultrasound in the COVID-19 pandemic. *Postgraduate medical journal*. 2020 Sep 7.