

A patient with drug-induced hepatic injury caused by a switch to generic bezafibrate

Makoto Irie^{1,*}, Kaoru Iwata², Akira Anan¹, Naoaki Tsuchiya¹, Atsushi Fukunaga¹, Kazuhide Takata¹, Tanaka Takashi¹, Keiji Yokoyama¹, Daisuke Morihara¹, Yasuaki Takeyama¹, Satoshi Shakado¹, Tetsuro Sohda¹, Shotaro Sakisaka¹

¹Department of Gastroenterology and Medicine, Fukuoka University, Faculty of Medicine, Fukuoka, Japan

²Murakami Karindo Hospital, Fukuoka, Japan

Email address:

macirie@minf.med.fukuoka-u.ac.jp (M. Irie)

To cite this article:

Makoto Irie, Kaoru Iwata, Akira Anan, Naoaki Tsuchiya, Atsushi Fukunaga, Kazuhide Takata, Tanaka Takashi, Keiji Yokoyama, Daisuke Morihara, Yasuaki Takeyama, Satoshi Shakado, Tetsuro Sohda, Shotaro Sakisaka. A Patient with Drug-Induced Hepatic Injury Caused by a Switch to Generic Bezafibrate. *American Journal of Internal Medicine*. Vol. 2, No. 4, 2014, pp. 63-66.
doi: 10.11648/j.ajim.20140204.12

Abstract: A 76-year-old woman with primary biliary cirrhosis and hypertension had been treated with a combination of oral ursodeoxycholic acid, bezafibrate and benidipine hydrochloride. After switching from brand name to generic bezafibrate, her liver injury became exacerbated. Her lymphocytes reacted with generic bezafibrate on a drug-lymphocyte stimulation test (DLST), indicating that her liver injury was likely caused by the switch to generic bezafibrate. Treatment with this agent was stopped, improving her liver function. These findings indicate that all forms of bezafibrate are not equal, that this generic formulation caused liver injury to this patient, and that DLST was useful diagnostically.

Keywords: Drug-Induced Hepatic Injury, Bezafibrate, Fibrate, Drug-Lymphocyte Stimulation Test (DLST), Primary Biliary Cirrhosis (PBC)

1. Introduction

The introduction of numerous generic drugs has increased the number of drugs having two or more pharmaceutical formulations. Generic drugs may give rise to adverse effects not observed during treatment with equivalent brand-name drugs. Increasing numbers of patients are switching from brand-name drugs to low-cost generic alternatives, without the knowledge of their attending physicians. This has led to an increase in the number of patients experiencing drug-induced liver damage, but for which the causative drug cannot be identified. Draft diagnostic criteria for drug-induced liver damage are currently being formulated, primarily by the Japan Society of Hepatology [1-3], and it is recommended that patients be diagnosed based on these criteria.

Although about 80% of patients with hyperlipidemia are treated with statins, about 5% are treated with fibrates. Fibrates activate the intranuclear peroxisome-proliferator-activated receptor α (PPAR α),

resulting in anti-inflammatory and antithrombotic effects and improvements in vascular endothelial function [4], as well as positive effects on lipid metabolism. PPAR α activation also promotes β -oxidation, as well as inhibiting the synthesis of neutral lipids and very low-density lipoproteins. Bezafibrate-induced liver damage has been found to result in mild hepatic dysfunction in many patients. To our knowledge, however there have been no previous reports of drug-induced liver damage due to generic bezafibrates.

The present report describes a patient who developed drug-induced liver damage after switching from brand-name to a generic bezafibrate. Diagnosis was aided by questioning the patient in detail about the commercial names of the drugs used, and by performing a drug-lymphocyte stimulation test (DLST). The findings in this patient suggest the need for caution when prescribing generic in place of brand-name drugs.

2. Case Report

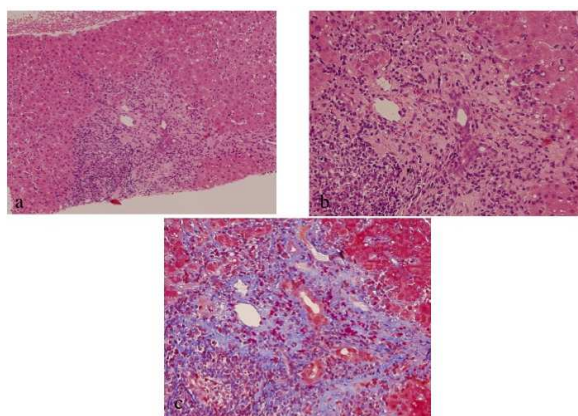


Figure 1. Histological findings of a liver biopsy sample (April 2002).

Liver tissue shows a moderate to severe chronic inflammatory infiltrate, including lymphocytes in the portal areas and hepatic lobules, with focal piecemeal necrosis and bridging phenomena. Chronic non-suppurative destructive cholangitis was also observed in portal areas.

a: Portal areas (HE×100). b: Portal areas (HE×200). c: Masson trichrome staining×200.

Beginning in 1994, a then 59-year-old woman began taking 4 mg oral benidipine hydrochloride for hypertension. In 2002, at age 67 years, she experienced an increase in hepatobiliary enzyme levels, but she was negative for markers of viruses that cause liver damage. In April 2002, she was admitted to our hospital with a diagnosis of liver dysfunction (Table 1). A liver biopsy sample was taken for a definitive diagnosis. Although her serum was negative for antimitochondrial antibodies, her biopsy results suggested a diagnosis of primary biliary cirrhosis (PBC) at Scheuer stage II (Fig. 1). She was started on 600 mg oral ursodeoxycholic acid (UDCA). The addition of bezafibrate 400 mg resulted in an improvement in hepatobiliary enzyme levels. However, mild transaminase increases were observed, beginning in January 2010, and liver function tests performed in November 2011 showed exacerbation of hepatic dysfunction. She has not taken other medicine before. The cause of the latter was not clear, so the patient was questioned in detail about the commercial names of the drugs used. Questioning revealed that she had switched from brand-name to a generic bezafibrate approximately one year earlier, in 2010. Although her serum concentrations of transaminases and γ -glutamyltranspeptidase (GGT) were increased (Table 2), abdominal ultrasonography showed no evidence of hepatomegaly or splenomegaly. Because we suspected that her liver damage was due to the generic bezafibrate, administration of this drug was discontinued, and she was switched back to brand-name bezafibrate that had been administered at the time of the initial diagnosis. Monitoring showed improvement, with aspartate transaminase (AST) concentrations decreasing from 75 to 27 IU/L, alanine transaminase (ALT) from 44 IU/L to 13 IU/L, and GGT from 90 to 50 IU/L (Fig. 2). According to the 2004 Japanese diagnostic scale for drug-induced hepatic injury,

her liver injury was classified as hepatocellular type and “highly possible” [2]. Additionally, DLSTs performed using the brand name and generic bezafibrates and benidipine hydrochloride yielded positive results only with the generic bezafibrate (Table 3). Additives to the formulations of brand name and generic bezafibrates differed somewhat. Lactose hydrate was included in the formulations of UDCA and benidipine hydrochloride; corn starch, polyvinylpyrrolidone, polyoxyethylene and crystalline cellulose were added to the formulation of UDCA; and hydroxypropylcellulose and carnaubalaw were added to benidipine hydrochloride (Table 4). Since some of the additives to generic bezafibrate were also added to UDCA and benidipine hydrochloride, the liver damage in this patient was likely not caused by the additives to the former. Rather, liver damage in this patient may have been caused by the interactions among additives. However, the causes of liver damage in this patient remained undetermined.

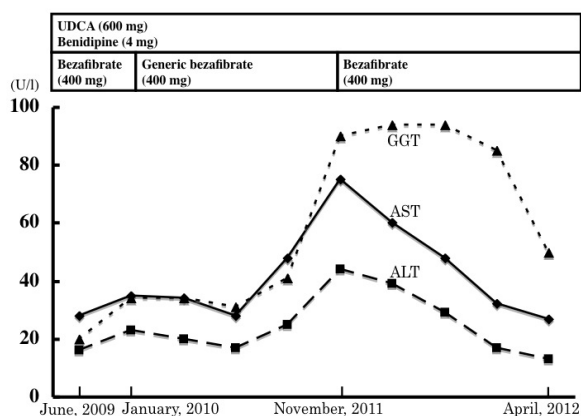


Figure 2. Clinical course of the patient.

Table 1. Laboratory data on admission (April 2002)

Hematology			
WBC	4900 / μ l	Ch-E	330 IU/l
Seg	70%	T Chol	250 mg/dl
Ly	26%	TG	114 mg/dl
Mono	3%	Glu	95 mg/dl
Eo	1%	BUN	9 mg/dl
RBC	437×10^4 / μ l	Cr	0.7 mg/dl
Hb	14.1 g/dl	Viral makers	
Ht	0.414	HA-IgM	(-)
Plt	23×10^4 / μ l	HBsAg	(-)
Blood Chemistry		HBcAb	(-)
TP	8.4 g/dl	HCV-Ab	(-)
Alb	4.1 g/dl	HCV-RNA	(-)
T-bil	1.0 mg/dl	Immunological test	
AST	80 IU/l	ANA	$\times 1280$
ALT	100 IU/l	Centromere	$\times 1280$
LDH	341 IU/l	AMA	(-)
ALP	674 IU/l	AMA-M2Ab	(-)
GGT	198 IU/l	IgM	230 mg/dl

Table 2. Laboratory data of the patient (November 2011).

Hematology		Blood Chemistry	
WBC	4800 / μ l	TP	7.9 g/dl
Seg	51%	Alb	3.9 g/dl
Ly	42%	T-bil	0.5 mg/dl
Mono	5%	AST	75 IU/l
Eo	2%	ALT	44 IU/l
RBC	372 x 10 ⁴ / μ l	LDH	214 IU/l
Hb	11.8 g/dl	ALP	312 IU/l
Ht	35.20%	GGT	90 IU/l
Plt	35.1 x 10 ⁴ / μ l	Ch-E	242 IU/l
		T Chol	190 mg/dl
Coagulation		TG	51 mg/dl
PT	100%	Glu	87 mg/dl
		BUN	20 mg/dl
		Cr	0.8 mg/dl
		CRP	0.2 mg/dl

Table 3. Drug-Lymphocyte Stimulation Test (DLST).

(Date: 2011.11.10)		
Generic bezafibrate	604 (214%)	positive
Benidipine	243 (86%)	negative
control (cpm)	28100%	
(Date: 2012.03.01)		
Bezafibrate	280 (91%)	negative
control (cpm)	304	

Table 4. Additive of Drug.

Generic bezafibrate	Bezafibrate	Benidipine	UDCA
Carnaubalaw	Lactose hydrate	Lactose hydrate	Lactose hydrate
Crystalline cellulose	Corn starch	Potato starch	Corn starch
Hydroxypropylcellulose	Polyvinylpyrrolidone	Hydroxypropylcellulose	Crystalline cellulose
Silicic anhydride	Polyoxyethylene	Povidone	Carmellose Calcium
Titanium oxide	Silicic anhydride	Polyvinyl alcohol	Polysorbate '80'
Magnesium stearate	Titanium oxide	Magnesium stearate	Povidone
Talc	Magnesium stearate	Hydroxypropylmethylcellulose	Magnesium stearate
Hydroxypropylmethylcellulose	Talc	Titanium oxide	
Polyethylene glycol	Hydroxypropylmethylcellulose	Polyethylene glycol	
	Polyethylene glycol	Carnaubalaw	

3. Discussion

The current first-line agents for the treatment of dyslipidemia, depending upon the target condition, include statins, nicotinic acid, and fibrates, whereas the first-line treatment for PBC is UDCA. UDCA inhibits cell apoptosis and is effective in improving tight junctions [5, 6]. If UDCA alone is ineffective, it may be combined with a fibrate, with

this combination shown to be effective [7].

Fibrates can be used to treat patients with PBC, especially if they also have hyperlipidemia [7]. Fibrates used to treat the latter have a low incidence of adverse effects, especially of liver damage, allowing their safe administration for extended periods of time. Nevertheless, the frequencies of liver damage resulting from treatment with different classes of antihyperlipidemic agents differ markedly. For example, liver damage has been observed in only about 1% of patients treated with statins, compared with about 25% of patients treated with fibrates. The mechanism by which fibrates induce liver damage has not been elucidated. However, single-nucleotide polymorphisms in the PPAR α gene may be associated with fibrate-induced liver damage [8]. One PPAR α gene polymorphism, A227, has been associated with increased GGT levels [9].

Our patient was treated with fibrates, which have been associated with a high frequency of liver damage. However, the frequency of liver damage and other adverse events depends on the particular agent used [10]. The lymphocytes of our patient reacted positively with generic but not brand name bezafibrate on DLSTs, suggesting an allergic mechanism for generic fibrate-induced liver damage in our patient. In general, the onset of allergic liver damage occurs a relatively short time, 1 to 5 weeks, after initiation of the relevant drug [11]. However, we previously described a patient who developed drug-induced liver damage after long-term administration [12], as did the present patient, who developed liver damage after long-term treatment with generic bezafibrate. The inert ingredients added to brand-name and generic bezafibrate showed certain differences (Table 4). Drugs such as *kanpōyaku*, an East Asian traditional medicine, are preparations containing multiple active components; these drugs have been reported to induce liver damage due to drug-drug interactions [13]. In the range that we searched, there is not the report of the hepatic dysfunction by generic bezafibrate. Although brand-name and generic bezafibrate had the same principal component, their additives differed, suggesting that one or more of the latter may have caused liver damage in our patient. It is unknown whether an additive drug was the cause of the hepatic dysfunction.

A diagnosis of drug-induced liver damage requires a history of drug use, clinical symptoms (fever, rash, and skin itchiness), peripheral eosinophil increase, and DLST results. However, the mechanisms underlying the onset and clinical progression of drug-induced liver damage have been found to be increasingly complicated. Additionally, identification of the causative drug is difficult. In many cases accurate determination is not possible, precluding a definitive diagnosis, even when the diagnostic criteria for drug-induced liver damage are met. In such situations, the patient should be questioned not only about drugs recently prescribed, but about that patient's detailed history of drug use, including the commercial names of all drugs. DLST should also be performed against all possible agents. Moreover, it is important to realize that brand name and

generic agents may differ in their ability to cause liver damage.

4. Conclusions

A patient developed drug-induced liver damage as a result of switching from brand-name to a generic bezafibrate. Detailed questioning about the commercial names of drugs, and DLST results, were found to be useful in diagnosis

References

- [1] Takikawa H, Takamori Y, Hisamochi A, *et al.* Draft new drug-induced liver damage diagnostic criteria: Revision of diagnostic criteria by the International Consensus Committee. *Kanzo* (in Japanese). 2003; 44: 176-9.
- [2] Takikawa H, Onji M, Takamori Y, Murata Y, Taniguchi H, Ito T, *et al.* DDW-J 2004 Workshop draft drug-induced liver damage diagnostic criteria. *Kanzo* (in Japanese). 2005; 46: 85-90.
- [3] Watanabe M, Shibuya A, Miura Y, Adachi S, Okuwaki Y, Ono K, *et al.* Validity study for the DDW-J 2004 Drug-Induced Liver Damage Workshop scoring system. *Kanzo* (in Japanese). 2007; 48: 219-226.
- [4] Yasuda T, Fukui T, Kawase Y, Okita M, Oyamada Y, Kawabata K. One rhabdomyolysis patient who developed acute kidney and liver failure due to bezafibrate administration. *Shojinkai Medical Journal*. 2012; 51: 127-131.
- [5] Koga H, Sakisaka S, Ohishi M, Ohishi M, Sata M, Tanikawa K. Nuclear DNA fragmentation and expression of Bcl-2 in primary biliary cirrhosis. *Hepatology*. 1997; 25: 1084-1997.
- [6] Sakisaka S, Kawaguchi T, Taniguchi E, Harada S, Sasatomi K, Koga H, *et al.* Alterations in tight junctions differ between primary biliary cirrhosis and primary sclerosing cholangitis. *Hepatology*. 2001; 33: 1460-1468.
- [7] Ishibashi T, Nakanuma Y, Ueno Y, Egawa H, Koike K, Komori A. *et al.* MHLW Refractory Disease Research Group on Diagnostic Guidelines for Primary Biliary Cirrhosis (2012): Refractory Hepatobiliary Disease Survey Group. *Kanzo* (in Japanese). 2012; 53: 633-686.
- [8] Nasu T. Molecular epidemiological research on PPAR α gene polymorphism and susceptibility to various types of hepatitis. *Research Reports of Uehara Memorial Foundation*. 2008; 22: 1-3.
- [9] Naito H, Kamijima M, Yamanoshita O, Nakahara A, Katoh T, Tanaka N, *et al.* Differential effects of aging, drinking and exercise on serum cholesterol levels dependent on the PPARA-V 227A polymorphism. *J Occup Health*. 2007; 49: 353-362.
- [10] Yamada Y, Tsuchihashi H. Comparison of efficacy, safety and economics of chestnut fibrates and bezafibrate. *Journal of Medicine and Pharmaceutical Science*. 2012; 67: 97-101.
- [11] Takikawa H. Drug-induced liver damage and the drug lymphocyte stimulation test. *Kanzo* (in Japanese). 2001; 42: 445-447.
- [12] Irie M, Yokoyama K, Sakurai K, Iwashita H, Ueda S, Morihara D, *et al.* One patient with drug-induced liver failure associated with severe jaundice due to long-term amlodipine and loxoprofen sodium administration. *Kanzo* (in Japanese). 2001; 51: 169-174.
- [13] Horowitz RS, Feldhaus K, Dart RC, Stermitz FR, Beck JJ. The clinical spectrum of Jin Bu Huan toxicity. *Arch Intern Med*. 1998; 156: 899-903.