



Case Report

Unusual Specific Lesion of Pleura as Result of Delay in Diagnosis of Chronic Pulmonary Aspergillosis: A Case Presentation

Iryna Liskina^{1,*}, Elena Rekalova², Ludmila Zagaba¹, Nataliia Grabchenko², Nicolay Bryansky³

¹Laboratory of Pathomorphology, National Institute of Phthisiology and Pulmonology Named After F. G. Yanovsky NAMS of Ukraine, Kiev, Ukraine

²Laboratory of Clinical Immunology, National Institute of Phthisiology and Pulmonology Named After F. G. Yanovsky NAMS of Ukraine, Kiev, Ukraine

³Department of Thoracic Surgery, National Institute of Phthisiology and Pulmonology Named After F. G. Yanovsky NAMS of Ukraine, Kiev, Ukraine

Email address:

liskina@ifp.kiev.ua (I. Liskina), pulmonol@ifp.kiev.ua (E. Rekalova), jrabchenko@ifp.kiev.ua (N. Grabchenko)

*Corresponding author

To cite this article:

Iryna Liskina, Elena Rekalova, Ludmila Zagaba, Nataliia Grabchenko, Nicolay Bryansky. Unusual Specific Lesion of Pleura as Result of Delay in Diagnosis of Chronic Pulmonary Aspergillosis: A Case Presentation. *American Journal of Internal Medicine*.

Vol. 5, No. 5, 2017, pp. 86-90. doi: 10.11648/j.ajim.20170505.15

Received: February 27, 2017; **Accepted:** March 18, 2017; **Published:** October 23, 2017

Abstract: The fungus *Aspergillus* spp. causes infections in immunocompromised hosts and produces a variety of clinical syndromes including lung tracheobronchial, chronic necrotizing or cavitary pulmonary and allergic bronchopulmonary manifestations, as well as aspergilloma, depending on the type of host-fungus relationship involved. Aspergilloma is usually colonized by *Aspergillus* spp. lesions in the bronchial tree, while invasive or semi-invasive forms are characterized by the presence of hyphae below its basement membrane. The objective of the present study was to describe the case of a patient with chronic pulmonary aspergillosis in the form of cavitary lesions of lung with infiltrates complicated by pleural empyema, including the clinical course, diagnostic approach and paraclinical care provided. The patient was a 28-year-old female with a history of thymoma who initially presented with febrile and pneumonia 12 years after surgical treatment of tumor. Traditional antibiotic treatment to pneumonia provided no improvement in the patient's condition and computed tomography of the thorax revealed cavities of destruction and pulmonary opacities. Later a bronchopleural fistula (BPF) was formed. A pleura lesion biopsy was performed after Video assisted thorascopic surgery (VATS) revision of pleural cavity showed a white exophytic lesion and pathological changes of pleura. Since pathologic examination revealed numerous septate fungal hyphae exhibiting 45° branching compatible with *Aspergillus* spp., the patient was treated with voriconazole. We emphasized on the reasons of delay of true diagnosis due to mistakes in management and treatment of clinical syndromes for a long time. In patients with tumor pathology in anamnesis who present with febrile and respiratory symptoms, it is essential to consider fungi as potential etiologic agents including *Aspergillus* spp., which is common and causes a variety of clinical syndromes.

Keywords: Chronic Progressive Pulmonary Aspergillosis, Cavities, Slight Immunodeficiency

1. Introduction

Aspergillus is a fungus which is commonly found in the soil, food, plant debris, and indoor environment. The spores are easily aerosolized and inhaled. In the respiratory mucosa, the

spores may germinate into hyphae, which in turn can invade the mucosa leading to beginning of pulmonary aspergillosis (PA). Both innate immune responses and inflammatory cells

limit fungal growth and prevent disease in the majority of individuals. Depending on host's immune status and specific immunodeficiencies, *Aspergillus* may lead to different pulmonary manifestations [1, 2].

The most common species being *A. fumigatus*, *A. flavus*, *A. niger* and *A. terreus*. Several clinical pulmonary forms have been described, the most important of which are invasive pulmonary aspergillosis (IPA), chronic aspergillosis, and aspergilloma. The type and severity of aspergillosis is determined by the characteristics of the patient [3].

The spectrum of aspergillosis encompasses a broad range of clinical entities, from noninvasive forms, such as allergic bronchopulmonary aspergillosis (ABPA) and chronic pulmonary aspergillosis syndromes, to invasive pulmonary aspergillosis (IPA) with possible widespread dissemination. Although most frequently affecting the lungs, aspergillosis can develop within virtually any organ system and disseminated disease is particularly common among patients with prolonged granulocytopenia following chemotherapy [4].

A new, simplified classification system encompassing all pulmonary *Aspergillus* spp. infections has been proposed as the following three entities: (1) simple aspergilloma, (2) chronic cavitary pulmonary aspergillosis (CCPA), as symptomatic complex aspergilloma or slowly progressive chronic necrotising pulmonary aspergillosis (CNPA) (>3 months in duration), occurring in patients with a previous history of bronchopulmonary disease, with pre-existing cavitary and with/without intracavitary fungal balls and (3) sub-acute IPA (rapidly progressive CNPA of <3 months in duration) [5].

Taken together, Izumikawa proposed the new term "chronic progressive pulmonary aspergillosis (CPPA)" for the clinical syndrome that includes both CNPA and CCPA [3], and this may reduce the confusion of the physicians seeing chronic pulmonary aspergillosis (CPA) patients [6].

Clinical and radiological descriptions of a large cohort of patients are required to better understand the significance of features of *Aspergillus* spp. infections in terms of prognosis and outcome [7].

The relevance of proper identification in treatment selection and outcomes remains a topic of debate because most clinical trials have not identified isolates with this degree of scrutiny and most subjects enrolled in clinical trials have only probable disease with a clinical picture, radiographic findings, and blood test or bronchoalveolar lavage (BAL) result (eg, galactomannan [GM]) suggesting IA without recovery of an actual isolate for definitive identification [4].

Diagnosis of IPA is challenging [8] as a diagnosis of CPPA. CPA is an uncommon and problematic pulmonary disease, complicating many other respiratory disorders, thought to affect ~240000 people in Europe. The most common form of CPA is chronic cavitary pulmonary aspergillosis (CCPA), which untreated may progress to chronic fibrosing pulmonary

aspergillosis [9]. Similarly, diagnosis of IPA is challenging [8] as a diagnosis of CPA.

In this paper, we present a case with no significant immunosuppression with chronic lung disease of unknown etiology, complicated by right limited empyema and later verification of the diagnosis.

2. Case Report

A 28-year-old woman was admitted to our hospital with complaints of fever, fatigue and cough with yellow sputum, severe weakness, sweating, chest pain, coughing, and hoarseness. Predisposing factors. 12 years ago she underwent a left upper lobectomy spliced with thymoma. Additionally, she had neoadjuvant and post operative courses of therapy, radiation therapy. And she was successfully treated.

At present, three months prior to admission, she complained dry cough. Her symptoms not passed and she presented to medical department at the place of residence, where she was diagnosed a chronic bronchitis and received appropriate treatment.

A month later from the first admission she underwent chest radiography and computed tomography (CT), destructive changes in the lungs were revealed. The physician suspected active tuberculosis or extensive bacterial pneumonia. Patient had at least three sputum smears with acid-fast bacilli (AFB) negative. No intensive therapy was prescribed due to unknown true diagnosis. She received antibiotic treatment of pneumonia according to medical protocol.

Two months later, the patient's condition deteriorated progressively because a sharp rise in body temperature of 38.0-38.8°C happened.

Consultation of oncologists was made; their conclusion was that data for recurrent disease is not present.

Physical examination on first admission showed the following. She had normal type of body, skin and mucous unremarkable, no swelling. Osteoarticular system was without pathology. Muscular system – residual effects of myasthenia gravis in the form of a nasal, blepharoptosis, periodic spasm pains on the lower extremities. Palpable somewhat reduced size of the thyroid gland. Peripheral lymph nodes were not increased. Hyperemia of the pharynx was revealed. Tongue was with a pronounced white-yellow coating. Auscultation of the heart - the heart sounds were muffled, rhythmic, and tachycardia was present (125 beats / min). The shape of the chest was asymmetric. It was 22 breaths per minute. Auscultation of the lungs - breathing hard, dry and creak sounds in right lung. Other organs and systems were without obvious pathology. Preliminary diagnosis was community acquired pneumonia with bilateral lesions look like cavities.

The results of laboratory blood tests are shown in Table 1. The results of HIV (human immunodeficiency virus), HBV (hepatitis B virus), sputum smear and cultures for mycobacteria were negative.

Table 1. Blood test results of the patient during the in-hospital treatment period.

| Parameter | First-time admission | | Second-time admission | | Third-time admission | |
|--|----------------------|-------------|-----------------------|------------------|----------------------|------------|
| Data of examination | 21.09. 2016 | 03.10. 2016 | 27.10. 2016 | 15.11. 2016 | 21.12.2016 | 11.01.2017 |
| WBS (10 ⁹ /l) | 18 ↑ | 14,3 ↑ | 12,5 ↑ | 12,8 ↑ | 14,4 ↑ | 12,2 ↑ |
| Granulocytes, % | 91,4 ↑ | 86,1 ↑ | 82,8 ↑ | 81 ↑ | 75,2 ↑ | 78,8 ↑ |
| Lymphocytes, % | 6,6 ↓ | 11,4 ↓ | 14,3 ↓ | 15,4 ↓ | 18,6 ↓ | 15,9 ↓ |
| Monocytes, % | 2 ↓ | 2,5 ↓ | 2,9 | 3,6 | 0,9 ↓ | 0,6 ↓ |
| Erythrocytes, 10 ¹² /l | 4,27 | 4,24 | 3,99 | 3,97 | 4,37 | 4,82 |
| Hb (g/l) | 126 | 122 | 115 | 114 | 123 | 139 |
| Hematocrit, % | 34,2 ↓ | 28,8 ↓ | 34,5 ↓ | 34,1 ↓ | 40,6 | 44,4 |
| PLT (× 10 ⁹ /l) | 337 | 346 | 406 | 388 | 325 | 208 |
| ESR, mm/h | 58 ↑ | 59 ↑ | 58 ↑ | 55 ↑ | 39 ↑ | 20 ↑ |
| Stab neutrophils, % | 28 ↑ | | | | | |
| Segmented neutrophils, % | 59 | | | | | |
| Total serum protein (g/l) | 72,6 | 78,2 | 75,9 | 72,2 | 74,3 | 70,6 |
| Serum alkaline phosphatase, U/l | 318,3 ↑ | 228 | 181,4 | 178,7 | 192,2 | 215,0 |
| Aspartate transaminase, U/l | 37,5 | 26,9 | 14,5 | 26,5 | 13,8 | 19,1 |
| Gamma-glutamyl transpeptidase (GGT), u/l | 68 ↑ | 35,4 | 25 | 43,7 ↑ | 32,6 | 35,1 |
| Alanin aminotransferase, U/l | 49,5 ↑ | 38,2 | 20,2 | 28,8 | 16,0 | 26,8 |
| Glucose (ummol/L) | 3,8 | 2,9 ↓ | 4,3 | 4,4 | 4,4 | 4,5 |
| Creatinin (mg/L) | 100,5 | 85 | 87,9 | 82,8 | 86,4 | 64,5 |
| BUN (mmol/L) | 3,67 | 3,31 | 3,38 | 2,42↓ (slightly) | 4,8 | 6,49 |
| Total serum bilirubin, mmol/L | 6,3 ↓ | 6,6 ↓ | 6,5 ↓ | 6,8 ↓ | 8,4 ↓ | 5,3 ↓ |
| Conjugated serum bilirubin, mmol/L | 3,8 | 3,4 | 3,3 | 3,1 | 3,4 | 3,4 |
| Indirect serum bilirubin, mmol/L | 2,5 ↓ | 3,2 ↓ | 3,2 ↓ | 3,7 | 5,0 | 1,9 ↓ |

Abbreviations: WBS, white blood count; Hb, Hemoglobin B; PLT, Platelets; ESR, erythrocyte sedimentation rate; BUN, Blood Urea Nitrogen; ↑: Increase (compared with normal data); ↓: Decrease (compared with normal data).

Initial high-resolution computer tomography (HRCT) scanning of the chest was made 22.09. 2016, conclusion: postoperative state from left upper lobe and mediastinum (2004). Dexter upper lobe reduces in size, in S1-3 peribronchial consolidation with traction bronchiectasis, cavity destruction, dimensions 34x26 mm 46x20 mm, with irregular inner edge and hyper density inclusions. In other right lobes nodular infiltrates were seen. The dome of the diaphragm is pulled up on the left. Conclusion: infiltrative-destructive changes in the upper right lobe with infiltration in both lungs. There is non-specific inflammatory process background on the underlying disease (Figure 1). Tuberculosis is unlikely.

During 2 months patient had an empirical treatment from atypical pneumonia but without obvious positive clinic dynamic. The antimicrobial drugs have been appointed in accordance with the results of microbiological studies. Nevertheless it were remained elevated ESR, levels of serum leucocytes, granulocytes. Clinic manifestation included fever, cough with purulent sputum.

In addition to therapeutic treatment, 5 times were performed endoscopic treatments with washing lasolvan of bronchi. Visually endoscopically it was diagnosed nonspecific bilateral bronchitis of 2-3 degrees of inflammation, biopsy was not performed.

Many times microbiological examination of sputum and bronchial washings were performed (Table 2). Some infections were revealed. Xpert MTB/ RIF test was negative. Since in sputum *Aspergillus* spp. once were found in small concentration they were not taken into account by physicians.

Repeated CT scan (a month after initial) showed only slight positive dynamics predominantly because reduction of

infiltrates in both lungs. Control chest X-ray revealed negative dynamics of fluid accumulation in the right lung cavity after half months of treatment. A patient was transferred to the surgical department with modified diagnosis: chronic abscess of upper right lobe, chronic limited right empyema, broncho-pulmonary fistula.

Additionally, intravenous linezolid was administered, which was established microbiologically sensitive bacterial microorganisms, but specific antifungal therapy was not assigned.

Repeated third HRCT (Figure 2) after two months (22. 11. 16) showed giant cavity with drainage in upper lobe, appearance of the peribronchial consolidation and single bronchiectasis with some fibrosis and nodule of infiltrate in lower lobe of right lung. Compared to the last prior HRCT it was seen increasing of the infiltration in the right lower lobe, size reducing of the cavity in the left upper lobe. No radiological improvement was seen. Precise diagnosis was absent.

After a week (28. 11. 16) another bronchoscopy was done with biopsy. Bronchoscopic examination revealed that the bronchial wall was covered by purulent exudates. A bronchoscopic biopsy specimen was obtained from the right upper lobar bronchus. Histopathological examination of the bronchoscopic biopsy specimen showed non-specific purulent inflammation without any fungal structures.

Patient's weakness, cough, and febrile temperature persisted.

At 06. 12. 16 patient underwent VATS to revise of limited right empyema with biopsy of parietal pleura. Histological examination revealed a tissue necrosis associated with infiltration of fungal hyphae (Figure 3a, b). The pleura cavity

contents were purulent and contained fungus balls of different sizes. In addition to this the calcium oxalate crystals were also evident in the pleura (Figure 4). Morphology of fungi was typical to *Aspergillus*.

Because we did not have the necessary equipment, we were not able to identify the proper species of fungi. The patient was started on oral itraconazole to treat the chronic fungal infection. Physician assigned the additional antifungal therapy: voriconazole (V-Fend®), gepatsef (cefoperazone and sulbactam) intravenous and analgesic drugs.

Significantly improvement was seen in patient after three weeks from antifungal therapy.

This case is of interest because CPA progressed over time to form a new adjacent pulmonary cavity and then to involve the pleura. Stability was achieved with long-term antifungal therapy.

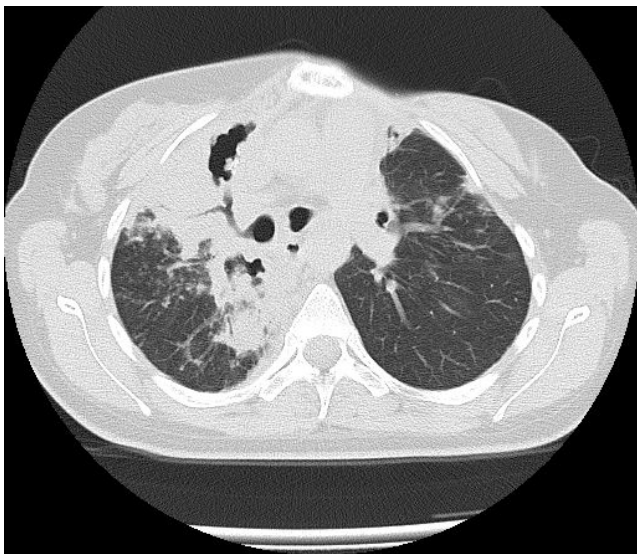


Figure 1. Computed tomography (CT) scans showed extensive peribronchial consolidation with bronchiectasis involving the subsegmental bronchus, and multiple centrilobular nodules and clusters of nodular at right lung. Cavities of destruction are seen filling by masses.

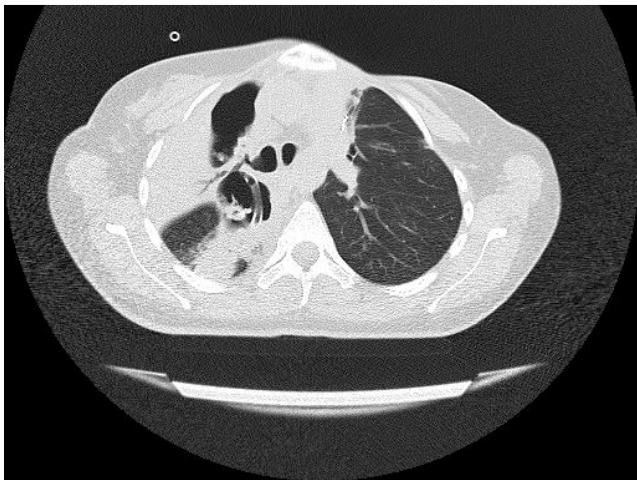


Figure 2. Computed tomography (CT) scans showed a large cavity in right upper lobe.

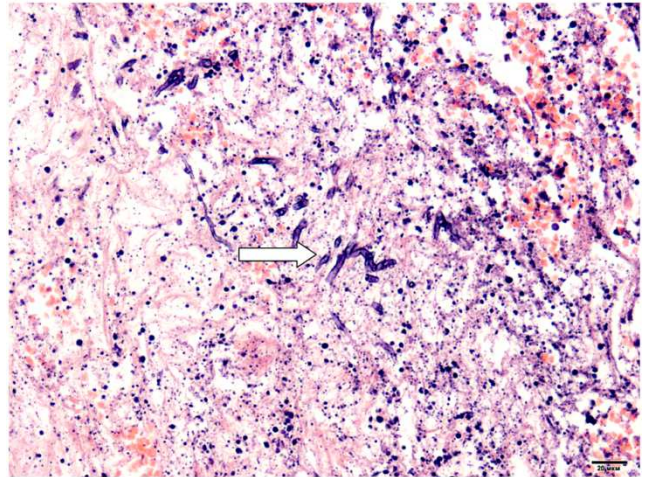


Figure 3a. Histopathological examination of the pleura biopsy specimen showed extensive tissue necrosis associated with infiltration of fungal hyphae (arrow) (hematoxylin & eosin staining x 200).

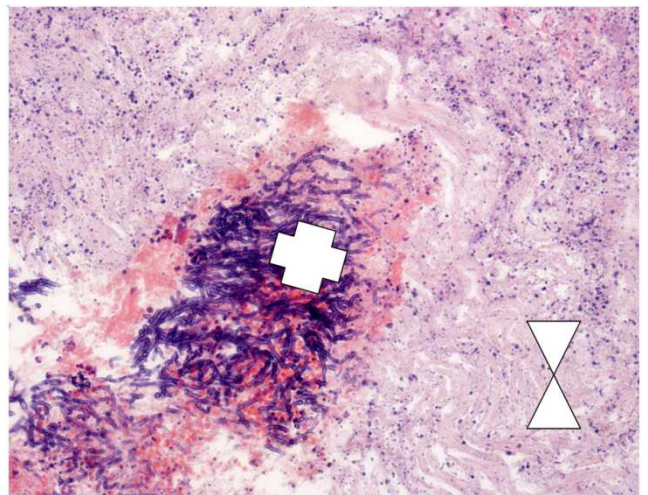


Figure 3b. Formation of fungus ball (+) in necrotic surrounded tissue (V) can be seen (hematoxylin and eosin staining x100).

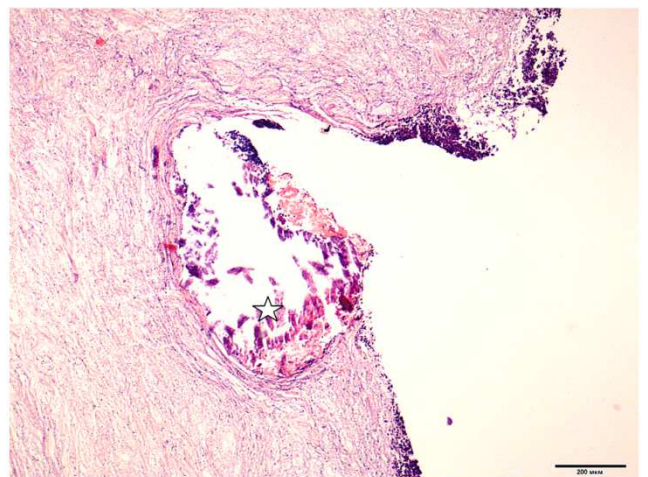


Figure 4. The calcium oxalate observed in tissue (★) (hematoxylin and eosin staining, x 40).

Table 2. Laboratory microbiological results.

| Diagnostic methods | First-time admission | Second-time admission | Third-time admission |
|---|--|--|--|
| | Result | Result | Result |
| GeneXpert MBT/RIF | Neg | Neg | |
| Direct sputum smear microscopy | | Neg (3 times) | Neg (3 times) |
| Bactec 960 (culture) | | Neg MBT (sputum, bronchial washings) | Neg MBT (sputum,) |
| Bacteriological examination of the non-specific flora | No microflora growth (2 times), 3 times – Candida 10 ^{x5} KYO/мл (sputum), Citrobacter spp. (sputum) 29.09.16 (sputum) Candida 10 ^{x5} KYO/мл, Aspergillus spp. 10 ^{x4} /ml, resistance to Amphotericin B | Citrobacter spp. 10 ^{x4} KYO/мл (sputum) Klebsiella spp., 10 ^{x4} KYO/мл (sputum) | 21.12.2016 (the contents of the pleural cavity) Pseudomonas aeruginosa, strain 1 10 ^{x7} KYO/мл Pseudomonas aeruginosa, strain 2 10 ^{x7} KYO/мл fungi of the genus Aspergillus spp. and other – no growth |

3. Discussion

IPA increasingly seen due to a rise in the number of patients undergoing SCT and solid organ transplants, and also due to increasing number of patients on chemotherapy [10]. Construction work in the vicinity of susceptible patients may increase spore aerosolization and is an independent risk factor [11].

Now CPA tends to affect middle-aged patients who are not immunosuppressed. It has an indolent progressive course, which can last for years. The usual clinical signs and constitutional symptoms include fever, malaise, fatigue, and weight loss. In addition, patients may exhibit non-specific respiratory symptoms such as chronic productive cough and haemoptysis. Pleural thickening and Aspergillus empyema can complicate the course of some forms of CPA.

In almost all cases, it develops as a result of an underlying pulmonary pathology, which may be responsible for the presence of a residual bronchopulmonary or, less frequently, pleural cavity [5].

The patient in our case was at risk for classic status. Nevertheless physician didn't pay special attention to opportunistic infections probably due to non adequate information about clinical spectrum of pulmonary aspergillosis.

We experienced a rare case of an immunocompetent (with slight immunodeficiency) patient with chronic pulmonary aspergillosis that was suspected on the basis of the microbiologic examination and CT findings and was confirmed on the basis of the videothoracoscopic pleura biopsy examination.

4. Conclusion

Although classic risk factors for CPA were present in our patient, but CPA was not high on the differential diagnosis for a long time. Initially, in our patient, nonspecific microflora was diagnosed a few times and appropriate therapy was done. Only histopathological examination led to final diagnosis.

Conflict of interests and funding.

The authors have not received any funding or benefits from the industry or elsewhere to conduct this study.

References

- [1] Ashutossh Naaraayan, Ronak Kavian, Jeffrey Lederman, Prasanta Basak, and Stephen Jesmajian. Invasive pulmonary aspergillosis – case report and review of literature. *J Community Hosp Intern Med Perspect* 2015, 5: 26322 - <http://dx.doi.org/10.3402/jchimp.v5.26322>.
- [2] Omar S. Zmeili, Ayman O. Soubani. Pulmonary aspergillosis: A clinical update. *Q J Med*, vol. 100, No. 6, pp 317-334.
- [3] José Curbelo, José María Galván, Javier Aspa. Updates on Aspergillus, Pneumocystis and Other Opportunistic Pulmonary Mycoses. *Arch Bronconeumol*. 2015; 51 (12): 647–653.
- [4] Jose Cadena, George R. Thompson, Thomas F. Patterson. Invasive Aspergillosis: Current Strategies for Diagnosis and Management. *Infectious Disease Clinics of North America*, 2016 Mar 1; 30 (1): 125-142. DOI: 10.1016/j.idc.2015.10.015.
- [5] Cendrine Godet, Bruno Philippe, François Laurent, Jacques Cadranel. Chronic Pulmonary Aspergillosis: An Update on Diagnosis and Treatment *Respiration* 2014; 88: 162–174 doi 10.1159/000362674.
- [6] Koichi Izumikawa. Recent advances in chronic pulmonary aspergillosis. *Respir Investig*. 2016 Mar; 54 (2): 85-91 doi: 10.1016/j.resinv.2015.10.003.
- [7] Bruno Philippe, Patrick Germaud: Aspergillus in the immunocompetent patient. Towards a new classification? *Rev Mal Respir* 2005; 22: 711-714.
- [8] Ana I. Aller-García et al. Case Series Study of Invasive Pulmonary Aspergillosis. *Mycopathologia* 2016, pp. 1-11 doi 10.1007/s11046-016-0097-1.
- [9] David W. Denning, et al. (2015) Chronic pulmonary aspergillosis: rationale and clinical guidelines for diagnosis and management *Eur Respir J* 2016; 47: 45–68 DOI: 10.
- [10] Pranatharthi Chandrasekar. Invasive mold infections: Recent advances in management approaches. *Leuk Lymphoma* 2009; 50 (5): 703-715.
- [11] Gabriella Pini, Elisabetta Faggi, Rosa Donato, Cristiana Sacco, Rosa Fanci. Invasive pulmonary aspergillosis in neutropenic patients and the influence of hospital renovation. *Mycoses* 2008; 51 (2): 117-122.