



**Review Article**

# **Kawasaki Disease with Rare Presentation Masquerading as Severe Infection in Children: A 10-year Retrospective Review in a Tertiary Hospital in Hong Kong SAR**

**Au Dennis Chi-yu<sup>\*</sup>, Fong Nai-chung, Kwan Yat-wah**

Department of Paediatrics & Adolescent Medicine, Princess Margaret Hospital, Hong Kong SAR, China

**Email address:**

acy340@gmail.com (Au DCY), fongnc@ha.org.hk (F. NC), kwanyw1@ha.org.hk (K. YW)

<sup>\*</sup>Corresponding author

**To cite this article:**

Au Dennis Chi-yu, Fong Nai-chung, Kwan Yat-wah. Kawasaki Disease with Rare Presentation Masquerading as Severe Infection in Children: A 10-year Retrospective Review in a Tertiary Hospital in Hong Kong SAR. *American Journal of Internal Medicine*. Vol. 7, No. 6, 2019, pp. 175-183. doi: 10.11648/j.ajim.20190706.17

**Received:** October 13, 2019; **Accepted:** December 19, 2019; **Published:** December 31, 2019

---

**Abstract:** Kawasaki disease (KD) with uncommon presentations can lead to diagnostic confusion mimicking severe infections: particularly KD shock syndrome (KDSS) mimicking toxic shock syndrome; and retropharyngeal edema (RPE) mimicking retropharyngeal neck abscess according to our local experience. High vigilance is needed for early diagnosis and timely treatment to minimize unnecessary operations and development of complications. A 10-year (2007-2016) retrospective review was performed for KD presented with features of KDSS/RPE. 120 KD cases were recruited. M:F was 1.2: 1, age 3.5 months to 12 years old. Sixteen had RPE mimicking neck abscess (13.3%) presenting as fever with neck complaints: swelling, pain or refusal to rotation/extension. None of them fulfilled sufficient diagnostic criteria for KD initially, some even with absent KD signs. They responded poorly to administration of antibiotics. Neck X-ray showed thickened retropharyngeal space suspicious of abscess. Computed tomography (CT) showed retropharyngeal fluid collection with no definite rim-enhancement. One case in doubt of early abscess underwent fine needle aspiration yielding 1.5ml necrotic material, sterile for bacterial culture. Signs of KD emerged as clinical course progressed, and all patients responded well to treatment with immunoglobulin (IVIG) and aspirin. Four presented as KDSS mimicking toxic shock (3.3%) with systolic hypotension requiring inotropic support and had ventricular dysfunction, mitral regurgitation on echocardiogram. Three had coronary ectasia on presentation. All were IVIG resistant and had severe hypoalbuminemia, probably contributing to shock. Two required pulse methylprednisolone and two responded to second dose IVIG.

**Keywords:** Kawasaki Disease, Incomplete Kawasaki Disease, Kawasaki Disease Shock Syndrome, Retropharyngeal Edema, Retropharyngeal Abscess, Pediatric Intensive Care

---

## **1. Introduction**

### **1.1. Background**

Kawasaki disease (KD) is a self-limiting condition primarily affecting infants and young children first described by Tomisaku Kawasaki from Japan in 1967. It is an acute febrile illness of unknown cause, with five principal clinical features: erythematous cracked lips and strawberry tongue, non-purulent conjunctivitis, polymorphic rash, pedal edema, and/or cervical lymphadenopathy. Prolonged fever  $\geq 5$  days

plus four principal features establish the diagnosis of KD. Intravenous immunoglobulin (IVIG) is the mainstay of treatment to reduce potential coronary complications such as aneurysm and thrombosis. Despite being commonly encountered by physicians nowadays and many are already familiar with its classical signs and diagnostic criteria, mystery remains in the full understanding of this unique entity. Increasingly, non-classical presentations of KD with incomplete diagnostic features as well as substantial overlap with many infectious diseases have been recognized.

**1.2. Recent Literature Review**

KD can present incompletely or atypically lacking some of the five principal diagnostic features. Such uncommon presentations may be misleading, resulting in misdiagnosis as other infections with KD being overlooked. *American Heart Association (AHA)* described a number of such examples in the latest 2017 Positional Statement on Kawasaki Disease by AHA, and their potential pitfalls in diagnosis [1]. Infants with KD may present with culture-negative pleocytosis of cerebrospinal fluid leading to the diagnosis of aseptic or partially-treated meningitis. Pyuria in young children can be mistaken as a urinary tract infection, with subsequent development of rash being attributed to an antibiotic reaction. Patients with prominent gastrointestinal symptoms may misdirect the presentation to a surgical unit as a mimic of acute abdomen, with KD signs being overlooked [1].

Recently, it is increasingly recognized that KD can masquerade as severe infections with shock or pyogenic abscess-like formation. Particularly, KD can manifest as hemodynamic disturbance with shock mimicking toxic shock syndrome, a rare entity known as Kawasaki disease shock syndrome (KDSS) [1-8]. It can also present with retropharyngeal edema (RPE) or neck swelling mimicking neck abscess [1, 9-11]. Our local experience is in coherence with such scattered reports in the recent literature, and therefore, we have reviewed a tertiary hospital in Hong Kong over a recent 10-year-period for any rare cases of uncommon presentations especially KDSS and RPE in all the established KD we encountered.

**2. Methods**

A database search was performed over a 10-year-period between 1<sup>st</sup> Jan 2007 to 31<sup>st</sup> Dec 2016 from the Clinical Management System in Princess Margaret Hospital, a tertiary pediatric referral center of Kowloon West Cluster, one of the largest amongst all seven hospital clusters managed under the governance by the Hong Kong Hospital Authority. Cases with the principle diagnosis of “Kawasaki Disease, ICD code 446.1

(ICD-9-CM)” were retrieved. Electronic patient records, discharge summaries, laboratory and radiological investigations, follow-up echocardiography findings were individually reviewed for each case.

**3. Results**

**3.1. Inclusions and Exclusions**

124 cases fulfilled the search criteria of “Kawasaki Disease” as their principle diagnosis. Four cases were excluded, of which two cases were incorrectly labelled as Kawasaki Disease and two cases actually presented before 2007 but were labelled as new KD upon follow-up assessment. Of the two cases incorrectly labelled, both did not fulfill the clinical diagnostic criteria of KD; both recovered without receiving immunoglobulin or aspirin; both did not have any occurrence of coronary complications upon long-term follow-up. Therefore, they were not regarded as actual KD. The remaining 120 cases were compatible with KD. 55% (66/120) were boys and 45% (54/120) were girls, with a male-to-female ratio of 1.2: 1. The median age of presentation was 3 years and 4.5 months old, ranging from 3.5 months to 11 years old.

**3.2. Incomplete KD, IVIG Resistance, Recurrent KD**

15.8% (19/120) had incomplete KD (or termed also as atypical KD), defined as fever and <4 KD criteria at the time of diagnosis and initiation of IVIG, with diagnosis established by other suggestive clinical findings of elevated alanine transaminase, hypoalbuminemia, grossly raised inflammatory markers, thrombocytosis after day 7 fever, normochromic normocytic anemia, and/or positive echocardiogram findings based on latest recommendations by AHA Positional Statement [1]. The incidence of intravenous immunoglobulin (IVIG) resistance, as defined by persistent or recrudescence fever at least 36 hours and <7 days after completion of first IVIG infusion [1], was 16.7% (20/120). The incidence of recurrent KD was 4.2% (5/120). Table 1 illustrated the incidence of incomplete KD and IVIG resistance across the 120 cases recruited.

*Table 1. Incidence of Incomplete KD and IVIG Resistance.*

	Incomplete KD		IVIG Resistance	
All KD (n=120)	15.8% (n=19)		16.7% (n=20)	
KD without PRE or KDSS (n=100)	9% (n=9)		13% (n=13)	
	50% (n=10)		35% (n=7)	
KD with RPE or KDSS (n=16+4)	PRE	KDSS	RPE	KDSS
	50% (n=8)	50% (n=2)	18.8% (n=3)	100% (n=4)

**3.3. KD with RPE & KDSS**

16 cases of KD (13.3%) had pyogenic-infection-like presentation, many of which showed retropharyngeal edema on contrast CT scan mimicking abscess formation. The age of presentation ranged from 9 months old to 7 years old. 11 were boys and 5 were girls. Despite half of them being incomplete KD, their diagnosis was established on grounds of other supportive laboratory findings such as echocardiography,

grossly raised inflammatory markers, hypoalbuminemia, thrombocytosis, and exclusion of other infective causes as well as unresponsiveness to antibiotics. Satisfactory response to IVIG further confirmed the diagnosis of KD, as all 16 cases responded well to IVIG, of which three cases were IVIG resistant requiring further doses of IVIG.

Four cases of KD (3.3%) were found to have shock, a unique entity called Kawasaki Disease Shock Syndrome defined as KD features plus systolic hypotension or clinical

signs of poor perfusion [1]. The age of presentation ranged from 17 month to 7 years old. Two were boys and two were girls. All of them required inotropic support; all had echocardiographic evidence of coronary ectasia or dilatation upon presentation; all were IVIG resistant.

The two tables in the subsequent page following this section (Table 4: RPE; Table 5: KDSS) summarize the clinical course of the 20 KDs with uncommon presentations of KDSS and RPE, investigations underwent, treatments given, salient laboratory and echocardiography findings, as well as long-term coronary complications if any. Details of their clinical course were described in subsequent discussions.

Amongst the above 20 cases of uncommon presentations (i.e. KD with RPE/KDSS), the incidence of incomplete KD

was 50% (10/20) at diagnosis and treatment of 1<sup>st</sup> IVIG, which was higher than the general incidence amongst other KD cases with statistical significance (table 2). The incidence of IVIG resistance was 18.8% in RPE cases (3/16) and 100% in all of the KDSS cases, which were both higher than the general incidence amongst other KD cases with statistical significance (table 3). The recurrence rate in these uncommon presentations was 5% (1/20), which was comparable to that of all the KD cases (4.2%, 5/120, as mentioned above). However, due to the limitation of small population study and subsequent statistical manipulation, a larger multicenter collaboration study is needed to consolidate these findings in our locality.

**Table 2.** Statistical Significance of the Incidence of Incomplete KD in KD with RPE or KDSS.

By chi-square test	Complete KD	Incomplete KD	
KD without RPE or KDSS (n=100)	91	9	
KD with RPE or KDSS (n=20)	10	10	p-value < 0.05
RPE (n=16)	8	8	p-value < 0.05
KDSS (n=4)	2	2	p-value=0.0546

**Table 3.** Statistical Significance of the Incidence of IVIG Resistance in KD with RPE or KDSS.

By chi-square test & Fisher exact test	IVIG Responsive	IVIG Resistance	
KD without RPE + KDSS (n=100)	87	13	
KD with RPE + KDSS (n=20)	13	7	p-value < 0.05
RPE (n=16)	13	3	p-value < 0.05
KDSS (n=4)	0	4	p-value < 0.05

**3.4. Concurrent Infections**

14% (17/120) of cases were also tested positive for concurrent infections, which included rhinovirus/enterovirus (by viral study for RNA in nasopharyngeal aspirate), adenovirus, respiratory syncytial virus, influenza A, parainfluenza, mycoplasma pneumoniae, vibrio parahaemolyticus, group A streptococcus, and infectious

mononucleosis (by Monospot test).

**3.5. Other Presentations**

In the literature, KD is also known to mimic other infectious entities such as aseptic meningitis in infants [1], prominent abdominal symptoms resembling acute abdomen [1], or refractory pneumonia [12]. From our database search, we did not identify any of such cases in the 10-year period.

**Table 4.** Clinical and Laboratory Characteristics of 16 Cases of Kawasaki Disease with Retropharyngeal Edema.

Age/Gen der	Presentation	Contrast CT neck findings	Echo cardiography	Day of 1 <sup>st</sup> IVIG	Additional Treatment	Long-term Complication
CLASSICAL KD (fever plus 4-5 diagnostic criteria fulfilled on 1 <sup>st</sup> IVIG)						
3y/M	Painful right neck swelling and erythema	Swollen tonsillar region with possible retropharyngeal extension. Multiple cervical LNs. Rim enhancement suspicious of abscess.	Normal	5	2 <sup>nd</sup> dose IVIG	Nil
5y/M	Bilateral painful neck swelling with erythema, torticollis	Retropharyngeal space with inflammatory changes or early abscess formation.	Normal	6		Nil
4y/M	Bilateral neck pain	Several enlarged LNs. No rim enhancement.	Normal	6		Nil
9m/F	Painful left neck swelling, thickened retropharyngeal space on C-spine XR	Large left retropharyngeal lesion suspicious for abscess (2.5 × 1.6 × 3.5cm).	Normal	6	FNA yielded necrotic material, culture -ve	Nil
3y/F	5cm painful left upper cervical LN 5cm, rash	Left cervical lymphadenopathy, no abscess.	Normal	5		Nil
5y/M	Painful left neck swelling, rash	Left cervical lymphadenopathy. No abscess detected.	Normal	5	2 <sup>nd</sup> dose IVIG	Nil
6y/M	Painful right neck swelling, odynophagia, dysphagia	No evidence of retropharyngeal abscess. Multiple reactive	Normal	7		Nil

Age/Gender	Presentation	Contrast CT neck findings	Echo cardiography	Day of 1 <sup>st</sup> IVIG	Additional Treatment	Long-term Complication
5y/F	Painful left neck swelling, torticollis	cervical LNs. Subcutaneous stranding with multiple enlarged LNs, non-rim enhancing retropharyngeal fluid collection suspicious of cellulitis with deep neck extension. Oropharyngeal airway is narrowed.	Echogenic LCA 2.3mm & RCA 2.6mm, rim of effusion	8		Nil
INCOMPLETE KD (fever plus $\leq 3$ diagnostic criteria, with other supportive clinical findings on 1 <sup>st</sup> IVIG)						
15m/M	Irritability, refusal to neck rotation and extension Developed rash, LN, conjunctivitis	Retropharyngeal edema with no definite rim enhancement. Multiple cervical lymph nodes.	Mild ectasia LCA 2.8mm RCA 2.8mm Mild MR	6		Nil
5y/M	Neck pain after minor injury Developed rash, conjunctivitis, mucosal changes Hypoalbuminemia Thrombocytosis Normochromic normocytic anemia Grossly elevated CRP	Non-specific retropharyngeal fluid. No definite rim enhancement.	Mild ectasia LCA 3mm RCA 4mm Trace MR	5	2 <sup>nd</sup> and 3 <sup>rd</sup> dose IVIG	Nil
18m/M	Left neck tender swelling, cracked lips, pedal edema Normochromic normocytic anemia	Multiple LNs. Central hypoenhancement in the largest LN can be early abscess or necrosis.	Normal	6		Nil
7y/F	Neck pain, torticollis unresponsive to antibiotic Developed LN, conjunctivitis Normochromic normocytic anemia Thrombocytosis Hypoalbuminemia Grossly elevated CRP, ESR Elevated ALT Painful right neck swelling	Extensive retropharyngeal edema due to early inflammation.	Aneurysmal LCA 6mm RCA 4mm	10		Giant LAD fusiform aneurysm 9.2 × 19.2mm
6y/M	Developed LN, conjunctivitis, mucosal changes Hypoalbuminemia Grossly elevated CRP 10x5cm painful right supraclavicular mass with indurated matted LNs	Enlarged level II LN, no abscess.	Normal	7		Nil
3y/M	Developed conjunctivitis, mucosal changes Normochromic normocytic anemia Thrombocytosis Hypoalbuminemia Painful right neck swelling, conjunctivitis, mucosal changes	Extensive cervical lymphadenopathy. No deep seated abscess detected.	Normal	8		Nil
3y/F	Normochromic normocytic anemia Thrombocytosis Hypoalbuminemia Painful 5.5cm left neck swelling, conjunctivitis	Tonsillitis with right cervical lymphadenopathy. No abscess.	Normal	9		Nil
6y/M	Developed rash Normochromic normocytic anemia Thrombocytosis	Multiple enlarged matted enhancing cervical LNs. No definite abscess. Trachea is mildly deviated to right side but patent.	Normal	9		Nil

(KD: Kawasaki disease; C-spine XR: cervical-spine X-ray; CT: computed tomography; LNs: lymph nodes; LCA: left coronary artery; RCA: right coronary artery; LAD: left anterior descending coronary artery; MR: mitral regurgitation; IVIG: intravenous immunoglobulin; FNA: fine needle aspiration; ENT: ear-nose-throat; CRP: C-reactive protein; ALT: alanine transaminase; ESR: erythrocyte sedimentation rate).

**Table 5.** Clinical and Laboratory Characteristics of 4 Cases of Kawasaki Disease Shock Syndrome.

	Case 1	Case 2	Case 3	Case 4
Age	7 years old	26 months	17 months	27 months
Gender/Ethnicity	Female/Chinese	Female/Chinese	Male/Chinese	Male/Chinese
Presentation	Cough and sore throat, managed with antibiotic.	Managed initially as chickenpox then scarlet fever.	Rash, conjunctival injection and cervical	Fever, vomiting and diarrhea managed as GE with antibiotic.

	Case 1	Case 2	Case 3	Case 4
	Hypotension on day 6, tachycardia and poor urine output. Only strawberry tongue and cracked lips.	Only confluent rash since day 2. Hypotension on day 6, then developed classical KD signs.	lymphadenopathy managed with antibiotic. Echocardiogram on day 4 showed mild left coronary artery dilatation 4mm with rim of pericardial effusion and mild pleural effusion.	Tender abdominal distension on day 6 with rash. Urgent CT: mesenteric adenitis, ascites and mild pleural effusion. SVT and hypotension on day 8 with severe hypoalbuminemia, impaired contractility and coronaries dilatation.
Incomplete KD	Yes	No	No	Yes
Febrile duration (days)	13	13	9	13
Highest temperature	39.7	40.2	39.2	41
Lowest BP (mmHg)	85/50	60/30	54/32	73/35
Inotropes (mcg/kg/min)	Noradrenaline up to 0.15	Noradrenaline up to 0.6	Dobutamine up to 10	Dobutamine up to 10
WBC count (x 10 <sup>9</sup> /L) ^	10.2	4.7	9.3	11.6
ANC (%total WBC) ^	9.2 × 10 <sup>9</sup> /L (90.1%)	3.8 × 10 <sup>9</sup> /L (79.5%)	75 × 10 <sup>9</sup> /L (80.4%)	105 × 10 <sup>9</sup> /L (90.4%)
Lowest Hb (mmol/L)	5.46	3.79	4.78	4.47
Platelet (× 10 <sup>9</sup> /L) ^	575	431	228	390
Lowest albumin (g/L)	18	17	15	17
ESR (mm/hr)	91 -> 31 -> 15	16 -> 4	7	41
Highest CRP (nmol/L)	2714	1724	2552	4029
Received IVIG dose	2	2	2	2
Day of 1 <sup>st</sup> IVIG	7	7	4	7
Steroid Required	Nil	Methylprednisolone	Methylprednisolone	Nil
Other treatments required	Nil	FFP for suspected DIC	Albumin infusion	ATP for SVT Albumin infusion Transfusion for anemia Pantoprazole for mild GI bleed
Coronary Dilatation	RCA 3.5mm	LCA 3.2mm	LCA 4mm RCA 4mm	LCA 3.2mm RCA 3.2mm
Coronary Aneurysm	LAD 6mm	Nil	Nil	Nil
Mitral regurgitation	Mild	Moderate	Mild	Moderate
Contractility	Normal	Normal	Impaired	Impaired
Pericardial effusion	Rim of effusion	Rim of effusion	Up to 3-4mm	Nil
Long-term Complications	LAD aneurysm 5mm	Nil	Nil	Nil

^ WBC and ANC taken as the first result on presentation; Platelet taken as the maximum level after day 7 of fever.

(KD: Kawasaki disease; WBC: white blood cells; ANC: absolute neutrophil count; Hb: hemoglobin; ESR: erythrocyte sedimentation rate; CRP: C-reactive protein; IVIG: intravenous immunoglobulin; RCA: right coronary artery; LCA: left coronary artery; LAD: left anterior descending coronary artery; FFP: fresh frozen plasma; DIC: disseminated intravascular coagulation; ATP: adenosine triphosphate; SVT: supraventricular tachycardia; GE: gastroenteritis; BP: blood pressure; GI: gastrointestinal; mcg/kg/min: microgram per kilogram per minute).

## 4. Discussions

### 4.1. Retropharyngeal Edema (PRE)

Amongst the 16 cases of RPE from our local data, none of them were able to fulfill the diagnostic criteria for KD on presentation, some even with absence of KD signs. None of them were reported to have stridor or other symptoms and signs of upper airway obstruction. All of them presented with a variety of neck complaints that were very much

indistinguishable from cervical lymphadenitis or deep neck abscesses, thus they were all managed initially with empirical antibiotic therapy but were all unresponsive to treatment. Microbiological work-up such as bacterial culture and viral studies were all negative. Ear-Nose-Throat (ENT) surgeon was consulted and computed tomography (CT) scans were done for all cases as suggested, which similarly showed long-segment retropharyngeal edema with no definite rim-enhancing collection. One case with a large left retropharyngeal lesion suspicious of early abscess eventually

underwent emergency fine needle aspiration which yielded only 1.5ml of necrotic material ultimately sterile for bacterial culture [13]. As fever persisted, and clinical course progressed, many subsequently developed more signs of KD. In the cases with incomplete presentations, KD was suspected based on other suggestive clinical findings such as grossly raised inflammatory markers (C-reactive protein, erythrocyte sedimentation rate), hypoalbuminemia, elevated alanine transaminase ALT, thrombocytosis, normochromic normocytic anemia and/or positive echocardiogram findings. Therefore, they were treated as KD with intravenous immunoglobulin (IVIG) and showed satisfactory response to further confirm the diagnosis. Thirteen cases responded well to only one dose of IVIG and three cases were IVIG resistant requiring 2<sup>nd</sup> dose. One case was found to have aneurysmal changes of coronary arteries, and unfortunately is still suffering from a giant left anterior descending fusiform aneurysm upon the latest follow-up. Three cases were found to have mild coronary ectasia at presentation, which all resolved upon serial follow-up scans.

Upon literature search, there are few but similar case reports or series describing this unique rare entity of RPE associated with KD [9-11, 14-17]. Cervical lymphadenopathy is reported to be the least common diagnostic criterion for KD. It is reported to be present in 42-65% of patients only [14-16]. Only 12% of KD present with fever and cervical lymph node [17], contributing to substantial diagnostic difficulty. In fact, 5% of KD presented with some forms of deep neck infection [17]. They could be in various forms, such as peritonsillar abscess, parapharyngeal or retropharyngeal abscess-like edema (RPE) or acute mastoiditis. These commonly lead to the presenting symptoms of painful gross neck swelling resembling lymphadenitis, restricted neck movements, torticollis, or trismus. In comparison, the incidence in the past 10 years in our Tertiary Hospital is 13.3%. The discrepancy in incidence could be accounted by the availability of radiological investigations in our center. CT scan is more readily available especially during non-office hours when operator-dependent ultrasonography (US) is not available, which may lead to earlier detection of retropharyngeal edema which is better identified on CT. The exact pathophysiology of RPE in KD is still unknown. Inflammation and edema are considered as the main mechanisms. It is proposed that the retropharyngeal space consists of loose connective tissue and therefore local edema could preferentially develop in the space under generalized inflammatory condition [18].

Similar to our experience, literature reported that the number of major KD signs increase as clinical course progresses, which implies close observation for development of new KD signs remains the most important key to diagnosis and timely IVIG treatment. CT scan may offer additional help in differentiating between KD with RPE from genuine retropharyngeal abscess (RPA), but limitations remain with low specificity especially with difficulty in differentiation

from early RPA without definite rim-enhancement. To date, there is no report of co-existence of KD and retropharyngeal abscess in the literature. One retrospective study from Japan attempting to differentiate KD from cervical lymphadenitis (CL) by US and CT concluded that ultrasound is mainly useful for excluding purulent lymphadenopathy while CT is a useful diagnostic tool for differentiating KD from CL, especially in patients with incomplete KD who present only with prominent cervical lymphadenopathy and other equivocal principal findings [19]. Apparently, RPA-like lesion without rim-enhancement on contrast CT is not an indication for invasive procedures such as fine needle aspiration or operative drainage [19]. Larger scale prospective study will be needed to establish the clear role and recommendation for the use of US and CT in differentiation of KD with RPE versus cervical lymphadenitis or genuine RPA.

High index of suspicion with close monitoring of emerging KD signs remains to be crucial in enabling early recognition, diagnosis, timely treatment, and therefore avoiding unnecessary invasive procedures for patients with KD with RPE.

#### 4.2. Kawasaki Disease Shock Syndrome (KDSS)

We also encountered four cases presenting with rare complication of KDSS, a unique entity defined as KD features with systolic hypotension for age, a sustained decrease in systolic blood pressure from baseline of  $\geq 20\%$  or clinical signs of poor perfusion (tachycardia, prolonged capillary refill time, cool extremities, diminished pulse volume, oliguria) requiring use of volume expansion, vasoactive agents, or transferal to an intensive care setting [1]. Two cases have previously been reported by our team in a case report already [20], and we have included the other two cases we came across in this review. They presented at the age of 17 month, 26 month, 27 month and 7 years old. All of them presented with significant systolic hypotension  $< 5^{\text{th}}$  centile for age, which all persisted despite fluid boluses and required inotropic support by dobutamine or noradrenaline. All of them showed signs of myocardial dysfunction with impaired contractility and mild to moderate mitral regurgitation. All of them were found to have IVIG resistance. Two of them required pulse methylprednisolone ultimately and two responded well to second dose IVIG. All of them had evidence of coronary ectasia during the acute phase of illness, with one of them still suffering from left anterior descending artery aneurysm upon the latest follow-up. One case was lost to follow-up as the family chose to continue management in the private sector. *Figure 1* illustrates the sequence of clinical course of the four cases of KDSS during their acute phase of illness. First dose IVIG for the third case was given in private hospital prior to transfer. All of them were treated with high-dose aspirin and stepped down to low-dose aspirin 36-48 hours after resolution of fever.

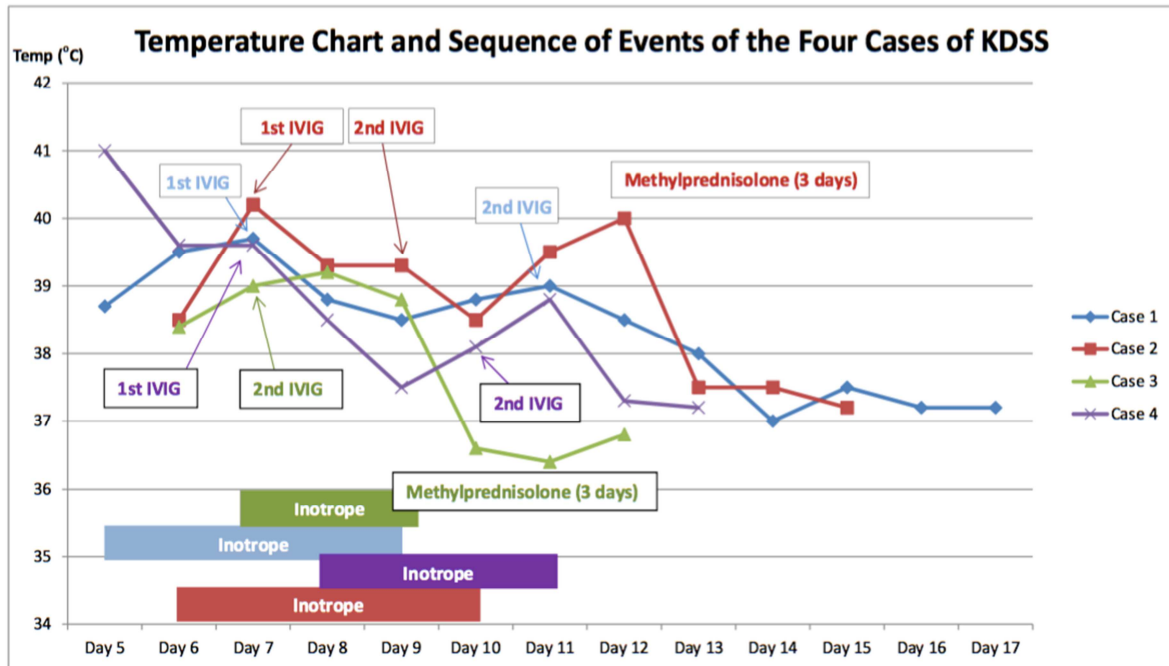


Figure 1. Temperature Chart and Sequence of Events of the Four KDSS Cases.

In the literature, the incidence of KDSS is estimated to be around 7% [1]. Children with shock presentation tend to have more incomplete KD, and appear to be at higher risk of IVIG resistance, coronary artery abnormalities, mitral regurgitation, and prolonged myocardial dysfunction [1], which is consistent with our experience with the 4 cases. They present as warm shock with decreased peripheral vascular resistance which could be easily confused with toxic shock syndrome (TSS) or bacterial sepsis. Thrombocytopenia, coagulopathy and raised cardiac troponins are also more common. Echocardiography, normochromic normocytic anemia and thrombocytosis are useful early differentiating features between KDSS and TSS. Various other clinical findings are also helpful such as gallbladder hydrops, aseptic pyuria, BCG scar induration and erythema, elevated inflammatory markers, elevated ALT, hypoalbuminemia etc [1]. The exact mechanism of shock in KD remains unclear, which presumably is likely multifactorial involving low peripheral vascular resistance with capillary leak, severe hypoalbuminemia and hypovolemia, myocardial dysfunction with or without ischemia. Superantigens may also play a role according to some literature [21-23]. In encountering IVIG resistance, a 2<sup>nd</sup> dose IVIG or pulse methylprednisolone may be considered [1].

#### 4.3. Concurrent Infections

Co-infection by other microbiological agents may further confound difficulty in the diagnosis of KD. In the literature, it is reported that concurrent infection may occur in up to 33% of KD patients [24], as compared to 14% from our local data in this study. Detection of common respiratory viruses does not exclude the diagnosis of KD if clinical features are compatible, especially in cases positive for adenovirus as the two illnesses have substantially similar clinical features [1, 25-28]. Understandably, the diagnostic challenge is even

greater when concurrent infection is present in incomplete KD cases in which the principal KD signs are equivocal.

#### 4.4. Limitations

The main limitation of this small population study is the sample size, which directly impacts subsequent strength of statistical manipulation. A larger multicenter collaboration study across Hong Kong is needed to consolidate these findings in our locality.

Secondly, cases of KD may have been missed due to incorrect diagnostic coding as the case recruitment was done retrospectively by electronic database search.

Thirdly, the lack of vigilance about the presentation of incomplete KD especially in the old days may result in misdiagnosis as other forms of infection. This may be the reason for not identifying any KD with presentation of aseptic meningitis, acute abdomen or refractory pneumonia as reported in the literature [1, 12]. A larger multicenter collaboration may help to identify a broader diversity of uncommon presentations of KD mimicking various forms of severe infections.

## 5. Conclusion

Kawasaki disease not only can present incompletely and subtly, they can be especially misleading in the presence of features masquerading severe infections. In particular with our local experience, KD with uncommon presentations such as retropharyngeal edema or shock appears to also have more incomplete presentation and IVIG resistance. High vigilance is required for KD with uncommon presentations to identify symptoms such as neck pain, neck swelling and to monitor for hypotension early in order to commence timely treatment and hopefully minimize unnecessary invasive interventions and

complications. In particular with KDSS, delay in recognition may lead to significant morbidity as they are commonly associated with greater risk of early coronary artery abnormalities and persistent myocardial dysfunction. They also have greater likelihood of IVIG resistance requiring additional anti-inflammatory treatment such as pulse methylprednisolone. Ancillary investigations by echocardiography, ultrasound abdomen for gallbladder hydrops, blood tests with thrombocytosis after day 7, normochromic normocytic anemia, elevated serum inflammatory markers, low serum albumin, elevated ALT etc. may help provide important supplementary clues to enable earlier establishment of diagnosis and therefore initiate timely treatment. With concurrent infection further adding up to the diagnostic confusion, KD should always be suspected if fever has persisted beyond the expected duration of viral illness, as well as in presumed bacterial infections unresponsive to prolonged antibiotic treatment. Uncommon presentations of KD can create significant diagnostic challenges to physicians, and high index of suspicion with close clinical observation for emerging KD signs remain as the key to diagnosis.

## Acknowledgements

There is no conflict of interest to declare. The study has been approved by local Research Ethics Committee regarding patient data handling and protection of patient privacy.

## References

- [1] *American Heart Association*. Diagnosis, Treatment, and Long-Term Management of Kawasaki Disease: A Scientific Statement for Health Professionals from the American Heart Association. *Circulation*. 2017; 135: 00–00.
- [2] *John T. Kanegaye, Matthew S. Wilder, Delaram Molkara, et al.* Recognition of a Kawasaki Disease Shock Syndrome. *Pediatrics* 2009; 123; e783.
- [3] *Deane Yim, James Ramsay, Darshan Kothari, David Burgner*. Coronary Artery Dilatation in Toxic Shock-Like Syndrome: The Kawasaki Disease Shock Syndrome. *Paediatric Cardiol* (2010) 31: 1232-1235.
- [4] *Thabet F1, Bafaqih H, Al-Mohaimeed S, et al.* Shock: an unusual presentation of Kawasaki disease. *Eur J Pediatr*. 2011 Jul; 170 (7): 941-3.
- [5] *İşgüder R1, Doksöz Ö, Bağ Ö, et al.* Kawasaki disease shock syndrome: a severe form of Kawasaki disease. *Turk J Pediatr*. 2013 May-Jun; 55 (3): 319-21.
- [6] *Gatterre P, Oualha M, DupicL, et al.* Kawasaki disease: an unexpected etiology of shock and multiple organ dysfunction syndrome. *Intensive Care Med* 2012; 38: 872-8.
- [7] *Lin YJ, Cheng MC, Lo MH, Chien SJ, et al.* Early Differentiation of Kawasaki Disease Shock Syndrome and Toxic Shock Syndrome in a Pediatric Intensive Care Unit. *Pediatr Infect Dis J*. 2015 Nov; 34 (11): 1163-7.
- [8] *Pei-Shin Chen, Hsin Chi, Fu-Yuan Huang, et al.* Clinical manifestations of Kawasaki disease shock syndrome: A case-control study. *J Microbiol. Immunol.* (2015) 48, 43e50.
- [9] *Hyun Ah Kim, Young Eun Moon, Jae Gwuang Oh, et al.* Kawasaki Disease Presenting as Cervical Lymphadenitis and Retropharyngeal Abscess. *Korean J Otorhinolaryngol-Head Neck Surg* 2010; 53: 552-6.
- [10] *Yuuichi Nomura, Michiko Arata, Chihaya Koriyama, et al.* A Severe Form of Kawasaki Disease Presenting with Only Fever and Cervical Lymphadenopathy at Admission. *J Pediatr*. 2010 May; 156 (5): 786-91.
- [11] *Kanegaye JT, Van Cott E, Tremoulet AH, et al.* Lymph-node-first presentation of Kawasaki disease compared with bacterial cervical adenitis and typical Kawasaki disease. *J Pediatr*. 2013; 162: 1259–1263.e2.
- [12] *Y Uziel, P J Hashkes, E Kassem, et al.* “Unresolving pneumonia” as the main manifestation of atypical Kawasaki disease. *Curr. Pediatr. Res.* (2017) Vol. 21, Issue 2.
- [13] *Carline Koh, Eric Kin Cheong Yau, Fong Nai Chung, Hui Yim Wo.* Kawasaki disease mimicking retropharyngeal abscess in an infant. *Pediatr Infect Dis J* 5 (2010) 1-2.
- [14] *Ayusawa M, Sonobe T, Uemura S, et al.* Revision of diagnostic guidelines for Kawasaki disease (the 5th revised edn). *Pediatr Int* 2005; 47: 232–4.
- [15] *Burns JC, Mason WH, Glode MP, et al.* Clinical and epidemiologic characteristics of patients for evaluation of possible Kawasaki disease. *J. Pediatr*. 1991; 118: 680–86.
- [16] *American Heart Association*. Diagnosis, treatment, and long-term management of Kawasaki disease: A statement for health professionals from the committee on rheumatic fever, endocarditis, and Kawasaki disease, council on cardiovascular disease in the young, American Heart Association. *Circulation* 2004; 114: 1708–33.
- [17] *Yoskovitch A, Tewfik TL, Duffy CM, et al.* Head and neck manifestations of Kawasaki disease. *Int J Pediatr Otorhinolaryngol* 2000; 52 (2): 123–9.
- [18] *Li-Ching Fang, Shyh-Dar Shyur, Chun-Chih Peng, et al.* Unusual manifestations of Kawasaki disease with retropharyngeal edema and shock syndrome in a Taiwanese child. *J Microbiol. Immunol.* (2014) 47, 152-157.
- [19] *Taiki Nozaki, Yuka Morita, Diasuke Hasegawa, et al.* Cervical Ultrasound and Computed Tomography of Kawasaki Disease: Comparison with Lymphadenitis. *Pediatr. Int.* (2016) 58, 1146-1152.
- [20] *SWY To, CLS Yan, NC Fong, CW Leung.* Two Cases of Kawasaki Disease Shock Syndrome. *HK J Paediatr (New Series)* 2016; 21: 197-200.
- [21] *Suenaga T, Suzuki H, Shibuta S, et al.* Detection of multiple superantigen genes in stools of patients with Kawasaki disease. *J Pediatr*. 2009; 155: 266–270.
- [22] *N Curtis, R Zheng, J R Lamb, M Levin.* Evidence for a superantigen mediated process in Kawasaki disease. *Arch Dis Child*. 1995 Apr; 72 (4): 308–311.
- [23] *Nagata S, Yamashiro Y, Ohtsuka Y, et al.* Heat shock proteins and superantigenic properties of bacteria from the gastrointestinal tract of patients with Kawasaki disease. *Immunology*. 2009; 128: 511–20.



- [24] *Benseler SM, McCrindle BW, Silverman ED, et al.* Infections and Kawasaki Disease: Implications for coronary artery outcome. *Pediatrics* 2005; 116: e760-e766.
- [25] *Kim JH, Yu JJ, Lee J, et al.* Detection rate and clinical impact of respiratory viruses in children with Kawasaki disease. *Korean J Pediatr.* 2012; 55: 470–473.
- [26] *Turnier JL, Anderson MS, Heizer HR, et al.* Concurrent respiratory viruses and Kawasaki disease. *Pediatrics.* 2015; 136: e609–e614.
- [27] *Jaggi P, Kajon AE, Mejias A, et al.* Human adenovirus infection in Kawasaki disease: a confounding bystander? *Clin Infect Dis.* 2013; 56: 58–64.
- [28] *Song E, Kajon AE, Wang H, et al.* Clinical and virologic characteristics may aid distinction of acute adenovirus disease from Kawasaki disease with incidental adenovirus detection. *J Pediatr.* 2016; 170: 325–330.