

Expression of O⁶ methyl guanine methyl transferase (mgmt) in oral squamous cell carcinoma patients in Alexandria, Egypt (smokers and non-smokers)

Hend Mohamed Helmy¹, Taissir Ali Omar¹, Sahar Mohamed ElSheikh¹, Ahmed Serag Habib²

¹Department of Oral Pathology, Faculty of Dentistry, Alexandria University, Egypt

²Department of Cranio Maxillofacial and Plastic Surgery, Faculty of Dentistry, Alexandria University, Egypt

Email address:

hendsadec@gmail.com (H. M. Helmy), taissir.omar@dent.alex.edu.eg (T. A. Omar), sahar.Elsheikh@dent.alex.edu.eg (S.M. Elsheikh), seragito@gmail.com (A. S. Habib)

To cite this article:

Hend Mohamed Helmy, Taissir Ali Omar, Sahar Mohamed ElSheikh, Ahmed Serag Habib. Expression of O⁶ Methyl Guanine Methyl Transferase (Mgmt) in Oral Squamous Cell Carcinoma Patients in Alexandria, Egypt (Smokers and Non-Smokers). *American Journal of Life Sciences*. Vol. 2, No. 4, 2014, pp. 217-223. doi: 10.11648/j.ajls.20140204.15

Abstract: Objectives: O⁶-methylguanine-DNA methyltransferase (MGMT) removes mutagenic, carcinogenic, and cytotoxic adducts from O⁶-methylguanine in DNA through a direct reversal mechanism. Decreased expression of MGMT has been reported in a variety of human malignant tumors. The purpose of this study was to clarify the correlation of MGMT expression levels in oral squamous cell carcinoma (OSCC) and cigarette smoking. Study Design: MGMT protein expression in 22 cases of oral squamous cell carcinoma by immunohistochemistry was investigated. Correlation with detailed tobacco history was then tested by statistical analysis. Results: All the non smoker OSCC cases showed positive immunoexpression. However 3 cases of the smoker patient revealed a weak positive immunostaining with only sporadic cells at the periphery. Conclusion: The results suggest that the absence of MGMT expression is related strongly to tobacco smoking and, thus, might be a significant event in oral carcinogenesis.

Keywords: O⁶-Methylguanine-DNA Methyltransferase, Tobacco, Oral Squamous Cell Carcinoma

1. Introduction

Oral squamous cell carcinoma (OSCC) is the sixth most common malignancy worldwide with an estimated 211,500 new cases per year (2.6% of all cancers) and over 120,000 deaths every year.(1) The etiology of oral cancer is multifactorial, with multiple carcinogenic agents affecting the oral mucosa.(2) Tobacco smoke is a complex mixture of at least 50 compounds including polycyclic aromatic hydrocarbons, nitrosamines, aldehydes and aromatic amines. Enzymatic bio-activation of this pro-carcinogens present in tobacco contributes to DNA damage and genotoxicity.(3) Disorders of DNA repair system, which protects against alkylating mutagens, are known to play an important role in carcinogenesis. The DNA repair protein O⁶-methylguanine-DNA-methyltransferase (MGMT) removes alkylating groups at the position O⁶ of guanine, conferring an important role in maintaining normal cell physiology and genomic stability.(4) MGMT removes only alkyl groups at only the O⁶ position of guanine, transferring

them from the oxygen of the amino acid to MGMT in a stoichiometric reaction that subsequently causes ubiquitination and degradation of MGMT. This requires cells to continually manufacture more MGMT to help to maintain DNA integrity.(5, 6) Loss of expression of this protein is associated with increased carcinogenic risk and increased sensitivity to methylating agents.(7)

Since each molecule of MGMT reacts only once as it is a suicide enzyme and cofactors are not needed, the capacity for repair of O⁶- alkylguanine depends clearly on the amount of MGMT molecules per cell. MGMT expression rests mainly on the methylation status of the MGMT promoter region, and several polymorphic forms are known, which differ in their biological activity. Regulation by different transcription factors has also been reported.(7, 8)

The expression of MGMT has been demonstrated in a variety of malignancies, including breast, esophagus, gliomas, and malignant thyroid lesions.(9-12) However,

loss of expression of MGMT in OSCC has received relatively little attention. In fact, only few researches have reported the effect of tobacco smoking on the expression of MGMT in oral squamous cell carcinoma patients.(13-15)

The aim of the present work was to study the possible difference in the cellular expression of the DNA repair MGMT in case of squamous cell carcinoma in smoker (according to the duration and intensity of smoking) and non-smoker patients (in relation to ex-smoker and never smoker patients).

2. Materials and Methods

2.1. Tissue Samples

Twenty two patients clinically diagnosed with OSCC were selected from the Cranio-Maxillofacial and Plastic Surgery Department at the Faculty of Dentistry, Alexandria University. Eleven patients were smokers and eleven were non-smokers. Detailed smoking history (from the smoker group) including: number of cigarettes per day, the duration of smoking, and cessation date for the ex-smoker (from the non smoker group). Five surgical specimens were taken from squamous cell papilloma, serving as negative control.

2.2. Methods

Biopsies were taken from the tumor tissue and fixed in 10% neutral buffered formalin, processed and embedded in paraffin wax using the conventional procedures. Serial sections of 3-4 μ m thick were placed on glass slides and stained using hematoxylin and eosin (H&E) for routine histopathological examination. This was followed by histological grading of the tumor into well, moderate and poorly differentiated SCC.

2.3. Immunohistochemical Interpretation

Immunohistochemical marker of mouse monoclonal antibody MGMT Ab-1 (Clone MT 3.1). Cat. #MS-470-R7 (7.0ml) (Thermo Fisher Scientific, CA, USA) was used. Strept-Avidin Biotin-peroxidase complex method (LSAB) was used (Lab vision corporation). Serial sections 4-5 μ m thick were taken from the previously used paraffin blocks for H&E. The slide will be mounted on poly-L-lysine coated glass slides. Two sections will be obtained for the positive test slides and third one for the negative control by omitting the primary antibody. The tissue sections were deparaffinized in xylene, rehydrated in graded ethanol and incubated in 0.3% hydrogen peroxide solution to block the endogenous peroxidase. The specimens were washed with an appropriately characterized, diluted and were incubated with the primary antibody of MGMT. Exposure to biotinylated link antibody and labeled streptavidin-biotin-peroxidase complex was done to bind the primary antibody. Staining was completed by incubation in substrate-chromogen solution and hematoxylin counter stain. Immuno-expression of MGMT will be evaluated by using image analyzer to evaluate both mean area percent and

mean optical density. The results were recorded and statistically analyzed using student t- test.

3. Results

3.1. Clinical Results

In the present work, a total of 22 patients with OSCC were included. The patients' age ranged between 40 and 80 with a mean of 58 ± 13 years. Clinical data of both smoker and non-smoker patients are represented in tables (1&2). Sixteen cases (72.7%) out of the studied 22 were ulcerative lesions. Six cases (27.3%) were exophytic forming fungating masses with irregular papillary surfaces, red or white in color. (Figure 1)

Clinical data regarding the site and detailed smoking history is presented in the table(1& 2)

Table (1). The Clinical Data of Oral Squamous Cell Carcinoma in Non-Smoker Patients.

Site	Percent	Number
Tongue	36.3%	4
Alveolar ridge	27.3%	3
Buccal mucosa	27.3%	3
Palatal mucosa	9.1%	1
Smoking history		
Never smoker	81.81%	9
Ex-smoker (stop the habit since 10 years)	18.18%	2

Table (2). The Clinical Data of Oral Squamous Cell Carcinoma in Smoker Patients.

	Percent	Number
Site		
Tongue	45.4%	5
Alveolar ridge	45.4%	5
Buccal mucosa	9.1%	1
Duration of smoking		
short duration (less than 15 years)	36.36%	4
long duration (more than 15 years)	63.63%	7
Number of cigarettes per day		
Less than one pack	18.18%	2
More than one pack	72.72%	8
Other types of tobacco used		
Water pipes	9.1%	1
Others	9.1%	1

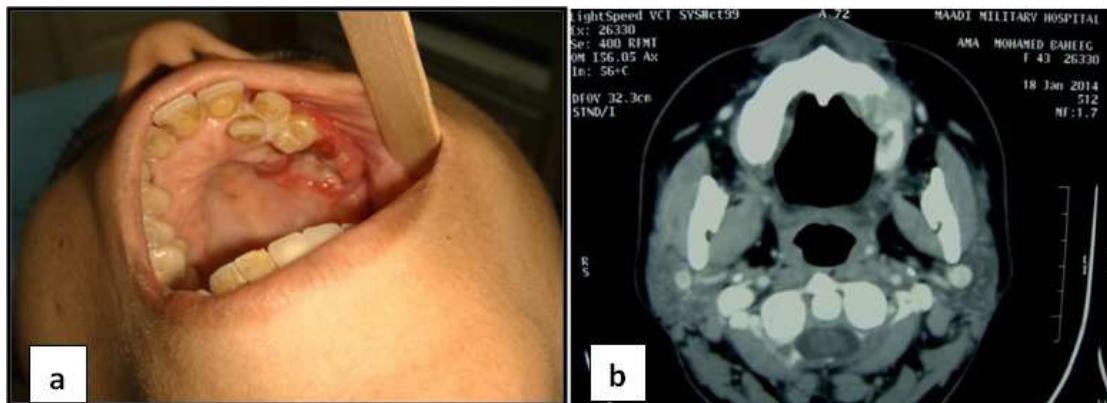


Figure (1). (a) Alveolar OSCC of the left posterior maxillary ridge extending to the palate. (b) Axial CT revealing the tumor implicating the left posterior maxillary ridge with buccolingual invasion and bone destruction. The ipsilateral cervical lymphadenopathy is inflammatory (non-specific).

3.2. Histopathological Results

The microscopical examination revealed that 8 cases (36.3%) were of the well differentiated type, 12 cases (54.5%) were moderately differentiated, and 2 cases (9.1%)

were of the poorly differentiated type. One case only (4.5 %) was associated with metastatic lymph node and was of the moderately differentiated type.

3.3. Immunohistochemical Results

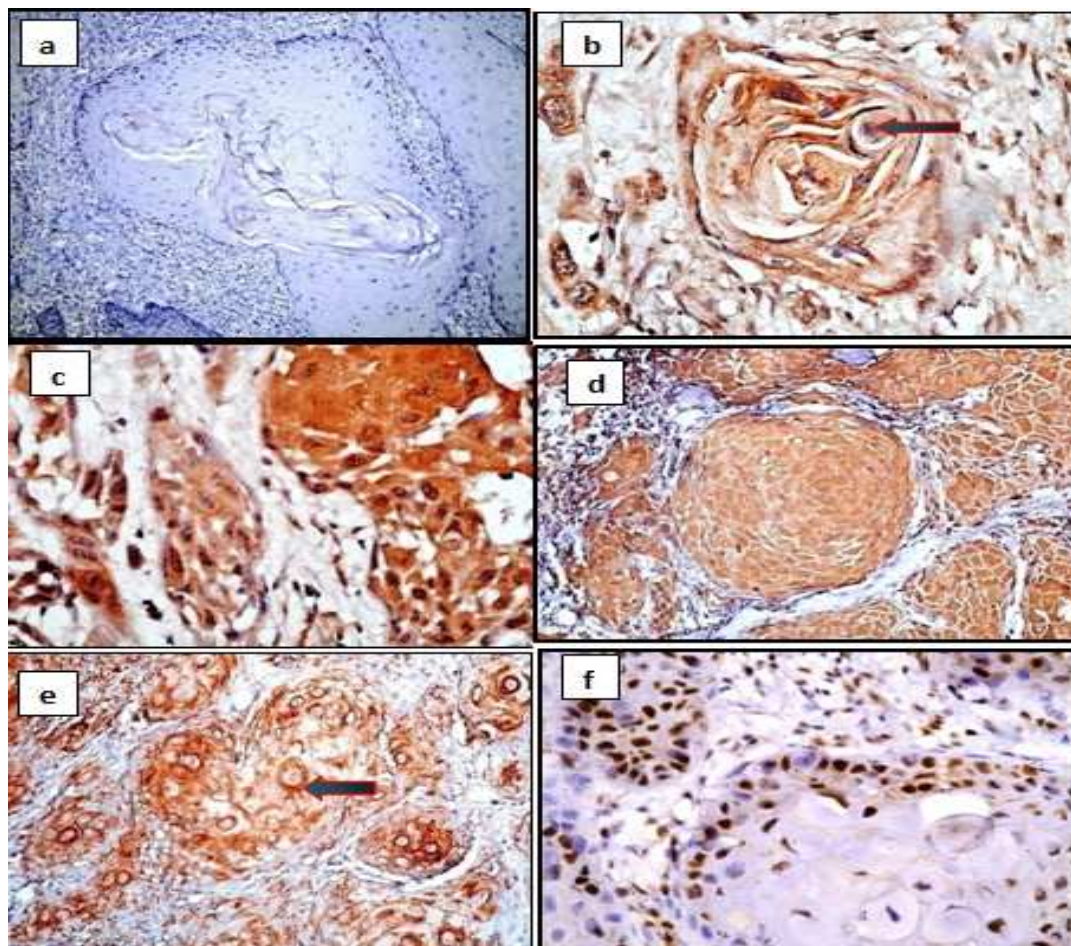


Figure (2). a) Well differentiated OSCC in a smoker patient showing negative immune reactivity of MGMT, few sporadic cells at the periphery are reactive (x 100). b) Well differentiated OSCC revealing intense cytoplasmic reaction of MGMT in the malignant epithelial cells forming the keratin pearl (x 400) arrow. c) Moderately differentiated OSCC showing evident positive reaction of MGMT in almost all malignant cell nests (x 200). d) Cell nests in a moderately differentiated OSCC exhibiting a strong reaction of MGMT in both the nuclei and cytoplasm (x 200). e) Moderately differentiated OSCC showing positive reaction of MGMT with uneven intensities (x 200) arrow. f) Moderately differentiated OSCC showing intense brownish nuclear reaction of MGMT mainly at the peripheral malignant cells of the nest (x 400).

The entire non-smoker group (11 cases) showed positive immunoreaction to MGMT. Concerning the smoker group (no=11), 8 cases (72.7%) were immunonegative. Three cases only (27.3%) exhibited positive immunoreaction to the DNA repair gene MGMT. The non-smokers group revealed diffuse positive cytoplasmic immunosignaling of MGMT in cases of well differentiated OSCC in the cells forming the keratin pearls, while the nuclei were free from any reaction. The moderately differentiated OSCC cases demonstrate diffuse total cell reactivity to MGMT. One case exhibited positive reaction of MGMT with uneven intensities. Some cases revealed positive nuclear immunosignaling without any cytoplasmic reaction of the DNA repair gene MGMT. It was observed that the intense staining was mainly seen in the peripheral neoplastic areas of the tumor cell nests. In the poorly differentiated type of OSCC, the intense MGMT immunopositivity was detected in the highly malignant epithelial cells. It showed different patterns of nuclear expression. The metastatic lymph node of the moderately differentiated OSCC revealed positive immunoreactivity to MGMT in both the cytoplasm and the nuclei. All the smokers group of OSCC cases showed negative immunoreactivity to MGMT. However, 3 cases revealed a weak positive immunostaining. The reaction was limited only to sporadic peripheral cells. figure (2)

All oral squamous cell papillomas (control group) showed positive immunoreactivity for MGMT. It appears as total cell reactivity in the form of diffuse brownish nuclear and cytoplasmic reactions.

3.4. MGMT Expression in Correlation with Smoking Habit in OSCC

Both mean area percent and mean optical density of MGMT in all OSCC cases were correlated with their corresponding smoking history using the image analyzer computer system. The difference in mean MGMT area percent and optical density between the smoker and non smoker groups using student t- test revealed high significant difference, (p<0.05) Table (3).

Table (3). Difference in Mean MGMT Area Percent and Optical Density between Different Groups

	Non smoker	Smoker	t	P
Area percent				
Mean ± SD	60.61 ± 17.08	5.46 ± 4.84	10.264*	<0.001*
	Non smoker	Smoker	t	P
Optical density				
Mean ± SD	75.02 ± 8.90	36.79 ± 10.13	9.403*	<0.001*

t: Student t-test for comparing smoker and non smoker groups

*: Statistically significant at p ≤ 0.05

In the non smoker group: the difference in mean MGMT area percent and optical density between the patients with no previous history of smoking to the ex smoker patient using student t- test revealed no significant difference. Table (4)

In the smoker group: the difference in mean MGMT area percent as well as optical density in the smoker group according to the duration of the habit and the number of cigarettes per day using student t- test revealed no significant difference. Table (5)

Table (4). Difference in Mean MGMT Area Percent and Optical Density between Different Categories in the Non Smoker Group.

	Never smoked (n = 9)	Ex-smoker (n = 2)	t	P
Area percent				
Mean ± SD	59.99 ± 18.64	63.40 ± 10.85	0.243	0.813
Optical density				
Mean ± SD	76.81 ± 8.69	67.0 ± 5.63	1.493	0.170

t: Student t-test to compare between the group who never smoked and the group who stopped smoking since 10 years

Table (5). Difference in Mean MGMT Area Percent and Optical Density between Different Categories in The Smoker Group

	Long duration(n = 7)	Short duration (n = 4)	t**	P
Area percent				
Mean ± SD	3.87 ± 5.17	7.86 ± 3.64	1.327	0.221
Optical density				
Mean ± SD	33.30 ± 8.82	42.91 ± 10.39	1.557	0.175
	More than one pack (n = 8)	Less than one pack (n = 2)	Water pipes (n = 1)	
Area percent				
Mean ± SD	4.31 ± 4.86	10.66 ± 0.91	3.12 ± -	
p ₁		0.123	0.826	
p ₂			0.093	
Optical density				
Mean ± SD	35.27 ± 9.89	47.48 ± 3.13	27.60 ± -	
p ₁		0.136	0.488	
p ₂			0.121	

t**: Student t-test to compare between long and short duration of smoking.

p₁: p value for Student t-test to compare between more than one back with less and water pipes

p₂: p value for Student t-test to compare between less than one back and water pipes

4. Discussion

It is certainly well established that inherited or acquired deficiencies in DNA repair proteins may lead to deleterious mutation rates, genomic instability and cell death associated with development, differentiation and progression of cancer. Alterations in the expression levels and the methylation status of proteins participating in the DNA repair process, such as MGMT has been described in several types of head and neck neoplasia, including mainly oral and esophageal SCC. It is also correlated with the clinicopathological parameters crucial for patients' management and prognosis.(16, 17)

In this research, 72.7% of the smoker OSCC patients showed loss of MGMT expression. This indicates deactivation of the DNA repair gene due to reduced MGMT activity or exhaustion of MGMT during O⁶-methylguanine elevation induced by environmental methylating products from the tobacco. This goes with the results of Sawhney *et al.*(13). They reported that (63%) of the tobacco consumer patients presented with OSCC revealed loss of MGMT immunoreactivity. On the other hand, Zuo *et al.*(18). found that only 18.8% of the OSCC smoker patients have no immunosignaling to MGMT.

In Contradiction to that results, Nozoe *et al.*(10) in their work on esophageal SCC, reported that the smoking habits and the amount of tobacco consumption of their patients were significantly correlated with MGMT expression. This finding suggested that smoking could stimulate MGMT expression which might have a defensive role against smoking correlated with carcinogenesis in case of SCC of the esophagus.(10) On the other hand, Chen *et al.*(19) found that 60% of their examined cases of esophageal SCC, completely lacked MGMT activity. This supports the results of the present work. It seems likely that the expression of MGMT in smoking-related esophageal SCC might be reduced because of its consumption while protecting the cells and repairing the damaged DNA by the carcinogens.(19)

In the current investigation a significant higher expression of MGMT in all non-smoker OSCC patients in relation to the smoker ones was found. This was explained by Rodri'guez *et al.*(20) They reported evident relationship between loss of MGMT expression and smoking habit in their work on precancerous lesions and OSCC. However, the results of Huang *et al.*(14) showed no significant correlation between alterations in MGMT expression and smoking habit only. They found that loss of MGMT protein expression was in parallel with combined cigarette smoking and betel quid chewing. They hypothesized that this discrepancy may be related to the low number of non-smokers in their study. Other possibility could be attributed to the different oral habits in each country, such as the way that tobacco is chewed and/or smoked.(14) Furthermore, the results of Lee *et al.*(15) revealed that MGMT expression was significantly higher in the group who only chew areca quid than in the group who both chew areca

quid and smoke tobacco. Unfortunately, in this study there were no smokeless tobacco patients as only 2.6% of adults aged 15 years and over used smokeless tobacco in Egypt.(21) The diversity of these results in MGMT expression in areca quid chewing-associated OSCCs and tobacco smoking might be explained as follows, MGMT is a specific DNA repair protein, which acts as the principal human factor that removes carcinogenic and cytotoxic O⁶-alkylguanine adducts from DNA.(22) Smokeless tobacco inhibits the growth, attachment, and matrix protein synthesis of cultured human gingival fibroblasts. Moreover, it has cytotoxic and genotoxic effects on oral mucosal fibroblasts and oral keratinocytes.(23)

In the present research, the non-smoker group of OSCC includes some patients who never smoked before and others who ceased the smoking habit since more than ten years. No significant difference was found in relation to the expression of MGMT. This is in accordance with Leffondre *et al.*(24) in their work on esophageal cancer. They concluded that there is no association between the duration of smoking cessation and different subtypes of esophageal cancer. On the other hand, some investigators showed that there is a correlation between cancer risk and past exposure to tobacco smoke in the order of twenty percent per ten years of cessation.(25, 26) One likely explanation for this important difference is that earlier studies included "never smokers" as the reference category for their tests.(24)

In the current work, the loss of MGMT expression was not significantly correlated to the duration as well as the amount of packs smoked per day in OSCC smoker patients. Similar results were obtained by Pandeya *et al.*(27) and Freedman *et al.*(28) They stated that the duration and intensity of smoking were both independently associated with different types of carcinomas affecting the esophagus such as esophageal SCC and adenocarcinomas.

The lack of MGMT expression is a negative prognostic marker, but a positive predictive marker. Prognostic markers suggest a difference in outcome that is independent of the treatment received including the possibility of no treatment at all. Predictive markers predict a response, and thereby survival differences are often, related to a specific form of therapy. Tumors that had lost MGMT expression would be more sensitive to the action of these alkylating agents because their DNA defects could not be repaired in cancer cell death.(29) Thus the lack of MGMT expression in the present work is considered as a positive predictive marker before chemotherapeutic drugs. This goes with the results of several studies done on hepatocellular carcinoma, gastric carcinoma, breast cancer,(30) as well as low-grade diffuse astrocytomas(31). They mentioned that loss of MGMT gene expression is predictive of poor survival in their patients.

5. Conclusions

Based on the immunohistochemical results of this study, the following conclusions were obtained:

1. Tobacco, which is significant risk factor for cancer, shows a significant association with inactivation of MGMT protein expression among Egyptian OSCC patients.
2. Apparent loss of MGMT protein expression could be a reliable and independent prognostic factor in OSCC.
3. The MGMT protein was detected in all the non-smoker cases of OSCC and in a small percentage of the smoker patients. Therefore it is reasonable to expect that continuous exposure to smoking may inhibit the function of the DNA repair enzyme MGMT.

Recommendations

1. Study of various types of tobacco, different duration and intensity are required to show the relation between the absence of MGMT protein in relation to cancer progression.
2. MGMT could be used clinically as a predictive marker for tumor processing, the potential for lymph node metastasis as well as advanced clinical stage.
3. Exploring MGMT alterations in the early stage of carcinogenesis would be informative and warrant investigation.

References

- [1] Jemal A, Siegel R, Ward E, Hao Y, Xu J, Thun MJ. Cancer statistics, 2009. *CA Cancer J Clin.* 2009 Jul-Aug;59(4):225-49.
- [2] Jones D, Rankin K. Oral Cancer and Associated Risk Factors. In: AA B, editor. *Prevention in Clinical Oral Health Care.* St Louis: Mosby Yearbook; 2008.
- [3] Chen KM, Guttenplan JB, Zhang SM, Aliaga C, Cooper TK, Sun YW, et al. Mechanisms of oral carcinogenesis induced by dibenzo[a,1]pyrene: an environmental pollutant and a tobacco smoke constituent. *Int J Cancer.* Sep 15;133(6):1300-9.
- [4] Gerson SL. MGMT: its role in cancer aetiology and cancer therapeutics. *Nat Rev Cancer.* 2004 Apr;4(4):296-307.
- [5] Kaina B, Christmann M, Naumann S, Roos WP. MGMT: key node in the battle against genotoxicity, carcinogenicity and apoptosis induced by alkylating agents. *DNA Repair (Amst).* 2007 Aug 1;6(8):1079-99.
- [6] Pegg AE, Fang Q, Loktionova NA. Human variants of O6-alkylguanine-DNA alkyltransferase. *DNA Repair (Amst).* 2007 Aug 1;6(8):1071-8.
- [7] Soejima H, Zhao W, Mukai T. Epigenetic silencing of the MGMT gene in cancer. *Biochem Cell Biol.* 2005 Aug;83(4):429-37.
- [8] Christmann M, Kaina B. O(6)-methylguanine-DNA methyltransferase (MGMT): impact on cancer risk in response to tobacco smoke. *Mutat Res.* Aug 1;736(1-2):64-74.
- [9] Neto JC, Ikoma MM, Carvalho KC, Vassallo J, De Brot M, Gobbi H, et al. MGMT and PTEN as potential prognostic markers in breast cancer. *Exp Mol Pathol.* Feb;92(1):20-6.
- [10] Nozoe T, Korenaga D, Kabashima A, Sugimachi K. Smoking-related increase of O(6)-methylguanine-DNA methyltransferase expression in squamous cell carcinoma of the esophagus. *Cancer Lett.* 2002 Oct 8;184(1):49-55.
- [11] Kreth S, Thon N, Eigenbrod S, Lutz J, Ledderose C, Egensperger R, et al. O-methylguanine-DNA methyltransferase (MGMT) mRNA expression predicts outcome in malignant glioma independent of MGMT promoter methylation. *PLoS One.* 6(2):e17156.
- [12] Giaginis C, Michailidi C, Stolakis V, Alexandrou P, Tsourouflis G, Kljianienko J, et al. Expression of DNA repair proteins MSH2, MLH1 and MGMT in human benign and malignant thyroid lesions: an immunohistochemical study. *Med Sci Monit.* Feb 25;17(3):BR81-90.
- [13] Sawhney M, Rohatgi N, Kaur J, Gupta SD, Deo SV, Shukla NK, et al. MGMT expression in oral precancerous and cancerous lesions: correlation with progression, nodal metastasis and poor prognosis. *Oral Oncol.* 2007 May;43(5):515-22.
- [14] Huang SH, Lee HS, Mar K, Ji DD, Huang MS, Hsia KT. Loss expression of O6-methylguanine DNA methyltransferase by promoter hypermethylation and its relationship to betel quid chewing in oral squamous cell carcinoma. *Oral Surg Oral Med Oral Pathol Oral Radiol Endod.* Jun;109(6):883-9.
- [15] Lee SS, Tsai CH, Yu CC, Ho YC, Hsu HI, Chang YC. The expression of O(6)-methylguanine-DNA methyltransferase in human oral keratinocytes stimulated with arecoline. *J Oral Pathol Med.* Sep;42(8):600-5.
- [16] Peterson CL, Cote J. Cellular machineries for chromosomal DNA repair. *Genes Dev.* 2004 Mar 15;18(6):602-16.
- [17] Hsieh P. Molecular mechanisms of DNA mismatch repair. *Mutat Res.* 2001 Jul 12;486(2):71-87.
- [18] Zuo C, Ai L, Ratliff P, Suen JY, Hanna E, Brent TP, et al. O6-methylguanine-DNA methyltransferase gene: epigenetic silencing and prognostic value in head and neck squamous cell carcinoma. *Cancer Epidemiol Biomarkers Prev.* 2004 Jun;13(6):967-75.
- [19] Chen JM, Zhang YP, Wang C, Sun Y, Fujimoto J, Ikenaga M. O6-methylguanine-DNA methyltransferase activity in human tumors. *Carcinogenesis.* 1992 Sep;13(9):1503-7.
- [20] Rodriguez MJ, Acha A, Ruesga MT, Rodriguez C, Rivera JM, Aguirre JM. Loss of expression of DNA repair enzyme MGMT in oral leukoplakia and early oral squamous cell carcinoma. A prognostic tool? *Cancer Lett.* 2007 Jan 8;245(1-2):263-8.
- [21] 2009 WHOROfEM. Global Adult Tobacco Survey: Egypt Country Report. egypt: WHO; 2012 may Contract No.: Document Number].
- [22] Mitra S. MGMT: a personal perspective. *DNA Repair (Amst).* 2007 Aug 1;6(8):1064-70.
- [23] Betel-quid and areca-nut chewing and some areca-nut derived nitrosamines. IARC Monogr Eval Carcinog Risks Hum. 2004;85:1-334.

- [24] Leffondre K, Abrahamowicz M, Siemiatycki J, Rachet B. Modeling smoking history: a comparison of different approaches. *Am J Epidemiol.* 2002 Nov 1;156(9):813-23.
- [25] Lagergren J, Bergstrom R, Lindgren A, Nyren O. The role of tobacco, snuff and alcohol use in the aetiology of cancer of the oesophagus and gastric cardia. *Int J Cancer.* 2000 Feb 1;85(3):340-6.
- [26] Wu AH, Wan P, Bernstein L. A multiethnic population-based study of smoking, alcohol and body size and risk of adenocarcinomas of the stomach and esophagus (United States). *Cancer Causes Control.* 2001 Oct;12(8):721-32.
- [27] Pandeya N, Williams GM, Sadhegi S, Green AC, Webb PM, Whiteman DC. Associations of duration, intensity, and quantity of smoking with adenocarcinoma and squamous cell carcinoma of the esophagus. *Am J Epidemiol.* 2008 Jul 1;168(1):105-14.
- [28] Freedman ND, Abnet CC, Leitzmann MF, Mouw T, Subar AF, Hollenbeck AR, et al. A prospective study of tobacco, alcohol, and the risk of esophageal and gastric cancer subtypes. *Am J Epidemiol.* 2007 Jun 15;165(12):1424-33.
- [29] Esteller M. Aberrant DNA methylation as a cancer-inducing mechanism. *Annu Rev Pharmacol Toxicol.* 2005;45:629-56.
- [30] Matsukura S, Miyazaki K, Yakushiji H, Ogawa A, Harimaya K, Nakabeppu Y, et al. Expression and prognostic significance of O6-methylguanine-DNA methyltransferase in hepatocellular, gastric, and breast cancers. *Ann Surg Oncol.* 2001 Dec;8(10):807-16.
- [31] Komine C, Watanabe T, Katayama Y, Yoshino A, Yokoyama T, Fukushima T. Promoter hypermethylation of the DNA repair gene O6-methylguanine-DNA methyltransferase is an independent predictor of shortened progression free survival in patients with low-grade diffuse astrocytomas. *Brain Pathol.* 2003 Apr;13(2):176-84.