
Nursing Intervention of Nonstop Minimally Invasive Tricuspid Valve Forming with Simultaneous Atrial Flutter After Secondary Cardiac Surgery: A Case Report

Zhilian Huang¹, Yuxiu Qian^{1,*}, Lihuan Hou¹, Xiaoshen Zhang², Chengfeng Huang², Hailing Huang³

¹The Operating Room, The First Affiliated Hospital, Jinan University, Guangzhou, China

²Department of Cardiac Surgery, The First Affiliated Hospital, Jinan University, Guangzhou, China

³Plastic Surgery Department, The First Affiliated Hospital, Jinan University, Guangzhou, China

Email address:

735112625@qq.com (Zhilian Huang), 458886185@qq.com (Yuxiu Qian), 1054831862@qq.com (Lihuan Hou),

xshchang@outlook.com (Xiaoshen Zhang), drhuang_hqyy@163.com (Chengfeng Huang), hunaghailing2301@126.com (Hailing Huang)

*Corresponding author

To cite this article:

Zhilian Huang, Yuxiu Qian, Lihuan Hou, Xiaoshen Zhang, Chengfeng Huang, Hailing Huang. Nursing Intervention of Nonstop Minimally Invasive Tricuspid Valve Forming with Simultaneous Atrial Flutter After Secondary Cardiac Surgery: A Case Report. *American Journal of Nursing Science*. Vol. 9, No. 4, 2020, pp. 286-289. doi: 10.11648/j.ajns.20200904.30

Received: July 6, 2020; **Accepted:** July 17, 2020; **Published:** July 28, 2020

Abstract: We discuss the nursing intervention of nonstop minimally invasive tricuspid valve forming with simultaneous atrial flutter after secondary cardiac surgery. Patient is a 50-years-old male who undergoing repair of atrial septal defect by central thoracotomy with extracorporeal circulation as atrial septal defect in the 30 years ago require repair of atrial septal defect by central thoracotomy with extracorporeal circulation again as residual shunt after repair. In patient checking report of January 2019, it indicated that in the case of no obvious inducement patients appear palpitation, palpitation, is persistent. Base on admission dynamic electrocardiogram, it indicated: (1) Persistent atrial flutter (2) second degree atrioventricular block with junctional escape (3) severe tricuspid regurgitation. In result of operation, we successfully completed the operation, and the patient had no complications after the operation. The surgical procedure was to perform electrophysiological mapping of the right atrium, establish extracorporeal circulation, surgical bipolar radiofrequency ablation, and tricuspid valve formation. Base on result of this operation, effective implementation of prospective nursing interventions can reduce the risk of surgery. In addition, in operation process, as the operation involves a large number of instruments and equipment and surgical personnel, the position of equipment and the rationality of personnel station will influence the result of operation.

Keywords: Cardiac Surgery, Nursing, Surgery

1. Introduction

Although the technical advances in interventional cardiology, cardiac surgery play an important role in the treatment of patients with coronary or valve diseases. Base on American's report, every year more than 300,000 coronary artery bypass grafting are performed in the United States [1-3]. In addition, some patients after cardiac surgery had aggravated valve regurgitation due to various reasons and repeated clinical symptoms, which required reoperation or multiple cardiac operations. It has been reported in the literature that

the risk and mortality of multiple operations is significantly higher than that of the initial operation [4, 5]. The doctors often use continuous extracorporeal circulation video-assisted tricuspid valvuloplasty surgical method to treat the patients who have severe tricuspid regurgitation after cardiac surgery without severe pleural adhesion [6, 7].

In recent report, almost 300,000 cardiac surgery procedures are performed each year in the United States [8]. But surgical mortality remains around 2%, even for the lowest-risk procedures, such as isolated coronary artery bypass graft or isolated aortic valve replacement [9, 10]. In the last decades, the mortality rate was reduced as people improve surgical

techniques and perioperative care, but cardiac surgery is still considered a high-risk procedure [11, 12].

2. Case Report

A 50-years-old male who undergoing repair of atrial septal defect by central thoracotomy with extracorporeal circulation as atrial septal defect in the 30 years ago require repair of atrial septal defect by central thoracotomy with extracorporeal circulation again as residual shunt after repair. In patient checking report of January 2019, it indicated that in the case of no obvious inducement patients appear palpitation, palpitation, is persistent. Base on admission dynamic electrocardiogram, it indicated: (1) Persistent atrial flutter (2) second degree atrioventricular block with junctional escape (3) severe tricuspid regurgitation.

2.1. Before Operation

In DSA hybrid operating room, the operation was performed with three-dimensional mapping using ensite-NAVx system and assisted by complete thoracoscopy (Figure 1). Base on patient situation, we use mechanical ventilation with double-lumen endotracheal intubation, three-dimensional echocardiography probe was placed through esophagus after general anesthesia for monitoring. In addition, the patient's lying position was the supine position, with the silicone cushion 20~30° above the chest, and the two upper limbs were placed on both sides of the body.

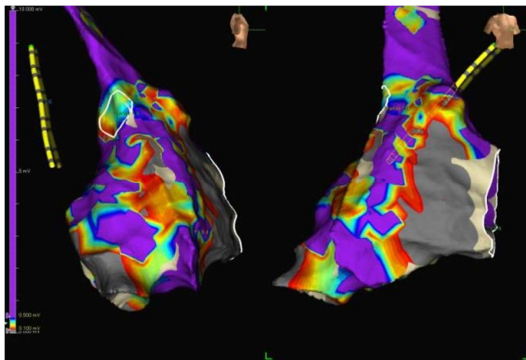


Figure 1. Three-dimensional echocardiography.

2.2. Operation Result

We successfully completed the operation, which lasted for 3h, the extracorporeal circulation time was 96min, and the blood loss was 100ml. We were removed from the ventilator 2 days after the operation, and there were no complications. The electrocardiogram showed sinus rhythm. According to the postoperative follow-up report, palpitation symptoms disappeared completely and there was no recurrent atrial flutter.

2.3. Cluster Nursing Interventions

Cluster care interventions include: patients psychological counseling, the preparation before surgery, configured in advance all kinds of drugs, skilled cooperate with surgery,

ventricular fibrillation prevention and treatment, bleeding, hypothermia, infection of incision, preventive measures, such as implementation after the handover.

2.3.1. Psychological Counseling for Patients

We make the communication that is order to avoid excessive tension and anxiety in patients after anesthesia. Surgical nurses participate in preoperative discussion, visit patients to understand their medical history and psychological state, inform patients with appropriate language and tone of matters related to cooperation before anesthesia operation, and establish a relationship of trust with patients. On the day of the operation, the patient was warmly received and actively cared for.

2.3.2. Improve the Preparation of Equipment and Instruments Before the Operation

Clean DSA hybrid operating room with room temperature of 22~24° and humidity of 50~60%. (2) EnSite-NavX 3D mapping system, 6F vascular sheath, mapping catheter, electrode. (3) Examination of surgical instruments, the surgical instruments contain thoracoscopic minimally invasive instrument, eyepiece and optical fiber, soft tissue retractor, pacemaker, bipolar radiofrequency pen, tricuspid ring detector, various types of forming rings, conventional thoracotomy instrument, swing saw.

2.3.3. Prepare All Kinds of Drugs in Advance

Conventional drugs for extracorporeal circulation, rescue drugs (epinephrine, deoxyepinephrine, magnesium sulfate, calcium gluconate, lidocaine, sodium bicarbonate, potassium chloride) and cardiac arrest fluid. (2) Heparin sodium, the dosage of which is 1:1 based on body weight, is different from the conventional body circulation dosage; Heparin, it is based on body weight 1:3.5 (Figure 2). (3) Protamine neutralizes heparin sodium, and its dosage should be 1.5:1; (4) electrophysiological mapping was used to induce ventricular fibrillation (0.25mg isoproterenol plus 250ml normal saline).

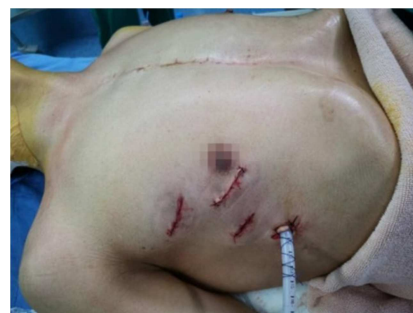

Figure 2. Puncture of the right femoral vein.

2.3.4. Assisting the Application of Esophageal Echocardiography

It contains 3 parts application. Before surgery, patients were evaluated for esophageal tumors, varicose veins and other contraindications. After anesthesia, assist the patient to tilt back the head to make the mouth, pharynx and esophagus close to the straight line, lubricate the probe with lubricant

fully, adjust the instrument setting well, and send the ultrasonic probe into the esophagus for examination. During operation, vital signs should be closely observed to deal with possible arrhythmias. The ultrasonic probe of the esophagus ensures sterilization by one use to avoid cross infection.

2.3.5. 3D Electrophysiological Mapping Modeling Management

Three pairs of electrodes were attached to the upper chest, back, left axil, right axil, posterior neck and left inner thigh. Check and evaluate skin integrity before and after pasting. Electrophysiological mapping modeling was completed. The surgical nurse immediately connected the endoscopic equipment and radiofrequency ablation pen. The radiofrequency ablation pedal was placed on the operator's right foot, with a set frequency of 460Khz and an energy of 28.5W. In addition, nurses cooperate with doctors to use isoproterenol and other drugs to observe whether patients have decreased blood pressure, increased heart rate, alert the possibility of cardiac plug and other complications.

2.3.6. Intraoperative Coordination

After radiofrequency ablation of atrial flutter, the surgical nurse provided the valve forming suture line to cooperate with tricuspid valve forming. The nurse is responsible for the preparation of ring detectors and artificial rings before surgery. Before opening the artificial valve ring of high-value consumables, the surgeon, instrument nurse and circuit nurse shall jointly check the model, brand and validity period. 36-37°C normal saline 1000ml-1500ml was prepared to test the tricuspid valve forming effect after completion of the forming operation (Figure 3).

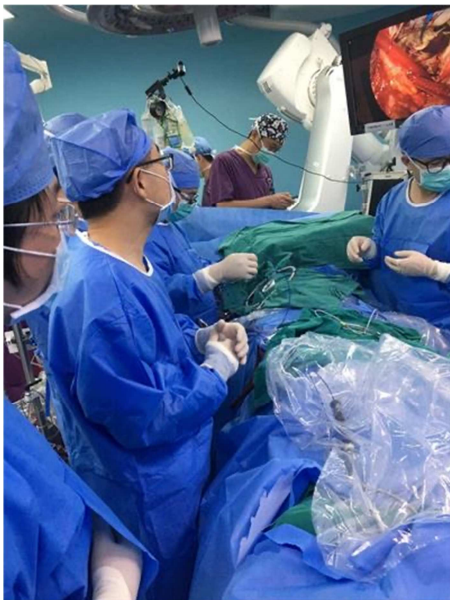

Figure 3. Cardiac surgery.

2.3.7. Prevention and Treatment of Ventricular Fibrillation

In the act of avoid hypothermia ventricular fibrillation, we will remain above 32°C temperature in operation, the advance will be before the transfer of liquid heat up to 32-34°C or so,

control the room temperature 24°C. Before surgery, automatic external defibrillation electrodes were pasted to the right shoulder blade and the left 5th intercostal axillary midline to prepare for emergency electrical defibrillation.

2.3.8. Post-operative Handover

During the handover between the operating room and the ward, the nurse paid attention to the dynamic changes of the patient's heart rate, heart rate and blood pressure, the amount and nature of the drainage fluid in the thoracic drainage bottle, the presence of extravasation and hematoma at the femoral arteriovenous puncture site, the skin color of lower limbs and the pulse of the foot arteries.

3. Discussion

We successfully completed the operation, and the patient had no complications after the operation. The surgical procedure was to perform electrophysiological mapping of the right atrium, establish extracorporeal circulation, surgical bipolar radiofrequency ablation, and tricuspid valve formation. Base on result of this operation, effective implementation of prospective nursing interventions can reduce the risk of surgery. As the operation involves a large number of instruments and equipment and surgical personnel, the position of equipment and the rationality of personnel station will influence the result of operation. Additionally, equipment debugging and patient monitoring also are important part in the operation process. Although the nursing details are still to be improved, prospective nursing interventions played a key role in this case's surgery. In similar report, the same operation uses common nursing intervention, that the nursing intervention is different for our operation. The two operation have different outcome that patient of the similar operation had a few complications after operation and it takes longer to recover than our patients [13].

4. Conclusion

In conclusion, we successfully completed the operation with nursing intervention, that the nursing intervention provide effect to the outcome of this operation. It speeds up the procedure, improves the safety and increases the success rate. In addition, according to the postoperative follow-up report, palpitation symptoms disappeared completely and there was no recurrent atrial flutter.

Acknowledgements

The research study was financially supported by the funding as awarded by the Guangdong Provincial Scientific Research Fund project in 2020 (Item no.: B2020028).

References

- [1] Benjamin EJ, Virani SS, Callaway CW, et al. Heart Disease and Stroke Statistics-2018 Update: A Report From the American Heart Association. *Circulation*. 2018; 137: e67-e492.

- [2] Tang H, Shrager JB. The Signaling Network Resulting in Ventilator-induced Diaphragm Dysfunction. *Am J Respir Cell Mol Biol.* 2018; 59: 417-427.
- [3] Lerolle N, Guerot E, Dimassi S, et al. Ultrasonographic diagnostic criterion for severe diaphragmatic dysfunction after cardiac surgery. *Chest.* 2019; 135: 401-407.
- [4] Ren YP, Xie Q, LU CQ, Ou-Yang SY, Chen JM, DENG CY. Intraoperative risk and nursing of reoperation of heart. *Ling Nan Journal of Cardiovascular Disease,* 2018; 3 (24): 230-231.
- [5] Zambon M, Greco M, Bocchino S, et al.: Assessment of diaphragmatic dysfunction in the critically ill patient with ultrasound: a systematic review. *Intensive Care Med.* 2017; 43: 29-38.
- [6] Liu J, Zhang XS, Guo HM, Liu J, et al. Complete thoracoscopic tricuspid valve replacement in 1 case. *Chinese journal of thoracic and cardiovascular surgery,* 2016; 30 (6): 379.
- [7] Moury PH, Cuisinier A, Durand M, et al. Diaphragm thickening in cardiac surgery: a perioperative prospective ultrasound study. *Ann Intensive Care.* 2019; 9: 50.
- [8] D'Agostino RS, Jacobs JP, Badhwar V, et al. The Society of Thoracic Surgeons Adult Cardiac Surgery Database: 2019 update on outcomes and quality. *Ann Thorac Surg* 2019; 107: 24-23.
- [9] Landoni G, Lomivorotov V, Silveti S, et al. Nonsurgical strategies to reduce mortality in patients undergoing cardiac surgery: An updated consensus process. *J Cardiothorac Vasc Anesth* 2018; 32: 225-235.
- [10] Lazam S, Vanoverschelde J-L, Tribouilloy C, et al. Twenty-year outcome after mitral repair versus replacement for severe degenerative mitral regurgitation. Analysis of a large, prospective, multicenter international registry. *Circulation.* 2017; 135: 410-422.
- [11] Pieri M, Belletti A, Monaco F, et al. Outcome of cardiac surgery in patients with low preoperative ejection fraction. *BMC Anesthesiol.* 2016; 16: 97.
- [12] Motohiro SK, Okada, H, Funaoka, S, Sato, T, Ichinomiya, Ushio Higashijima, S, Matsumoto, O, Yoshitomi, K, Eishi, TH. Association between Enterocyte Injury and Mortality in Patients on Hemodialysis Who Underwent Cardiac Surgery: An Exploratory Study. *Journal of Surgical Research.* 2020; 255.
- [13] Pianpian Y, Xijie W, Feifei C, Yongcong C, Yiting H, Gang L, Keke L. Efficacy and safety of sugammadex in anesthesia of cardiac surgery: A retrospective study. *Journal of Clinical Anesthesia.* 2020; 65.