

Case Report

Difuse Infantile Hemangiomas with Consumptive Hypothyroidism in an Infant: A Case Report

Ziad Albahri^{1, *}, Antonín Lukes²

¹Department of Pediatrics, Faculty Hospital, Charles University, Hradec Kralove, Czech Republic

²Department of Pediatric Cardiology, Faculty Hospital, Charles University, Hradec Kralove, Czech Republic

Email address:

marziadmar@seznam.cz (Z. Albahri)

*Corresponding author

To cite this article:

Ziad Albahri, Antonín Lukes. Difuse Infantile Hemangiomas with Consumptive Hypothyroidism in an Infant: A Case Report. *American Journal of Pediatrics*. Vol. 2, No. 1, 2016, pp. 1-3. doi: 10.11648/j.ajp.20160201.11

Received: February 7, 2016; **Accepted:** February 17, 2016; **Published:** March 11, 2016

Abstract: We report a case of a male newborn who was evaluated due to persistent jaundice. Evaluation showed hypothyroidism associated with infantile hemangioma of the liver. Euthyroidism and regression of the hepatic hemangiomas were obtained with L-thyroxin and Propranolol treatment. This case emphasizes the importance of screening for hypothyroidism in patients with neonatal hemangiomas.

Keywords: Hepatic Hemangioendotheliomas, Jaundice, Hypothyroidism

1. Introduction

Hemangiomas are the most common tumors of infancy; characterized by rapid proliferation during infancy followed by slow involution over the next 1 to 5 years with continued improvement up to 10 years [1]. Difuse neonatal hemangiomas (DNH) was first described by Lister [2], multiple congenital hemangiomas are dividend into benign when hemangiomas are found only on the skin and DNH when in addition to masthose of the skin, various internal organs are affected. Liver is affected in 64-100%, CNS in 52%. The association between consumptive hypothyroidism and hepatic hemangioendothelioma (HHE) was first reported by Huang SA [3].

2. Case Report

A 45-day-old male patient was referred to our clinic with a diagnosis of infantile hemangiomas (IH) and jaundice (Fig. 1), his family history was negative. He was born at 37 g.w, birth weight was 3370g, His newborn thyroid screening studies were reported to be normal. He was discharged home with mild hyperbilirubinemia (total bilirubin 278 $\mu\text{mol/l}$), in routine screening for hyperbilirubinemia a massive hepatic

hemangioendothelioma and abnormal values of TG was reported, he was referred to our hospital for further evaluation. Abdominal ultrasound (US), were consistent with multinodular hepatic hemangioendothelioma (HHE) (Fig. 2 A), Echocardiography showed Foram ovale apertum, cardiomegaly with *hyperkinetic circulation*, brain US with normal findings. Investigations showed sub-clinical hypothyroidism: TSH 10 mIU/l, (0.58-5.57); fT4: 23.77 pmol/l (12.8-44.3); T4: 177.89 nmol/l (77.9-235.1); T3: 1.11 nmol/l (0.39-4.0); TG: 53.57 $\mu\text{g/l}$ (7.4 - 48.7).

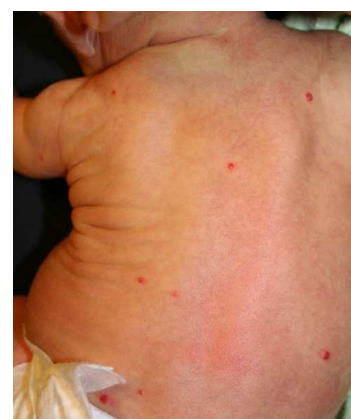

Fig. 1. Cutaneous manifestations of multiple hemangiomas in our patient.

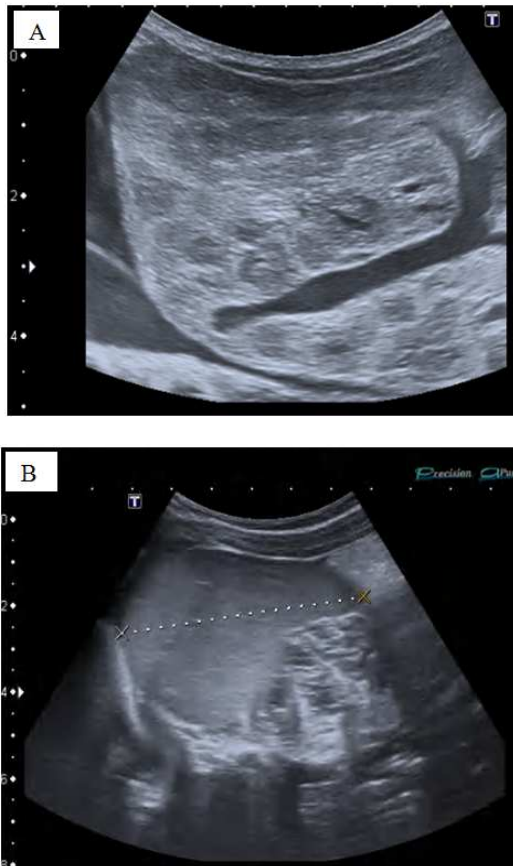


Fig. 2. Liver ultrasound, A: before treatment, and B: after 3 months treatment with Propranolol.

Because of the presence of HHE, *hyperkinetic circulation* and hypothyroidism in our patient, he was treated with Propranolol, starting dose was 1.3mg/kg/day increased gradually to 2mg/kg/day, and L-thyroxin 11µg/kg/day, decreased to 5µg/kg/day, after 3 months of treatment, a 80% regression of the hepatic hemangiomas was reported by abdominal US (Fig. 2 b). Propranolol was discontinued with L-thyroxin after 6 months. No complications during treatment were noted, his growth and development have been normal.

3. Discussion

Hepatic hemangiomas are congenital vascular malformations, considered the most common benign mesenchymal hepatic tumors; It is a developmental anomaly of hemogenic endothelium derived from primitive mesoderm with a neural crest-cell phenotype, composed of masses of blood vessels that are atypical or irregular in arrangement and size. There is a tendency for female predominance in gender distribution with a ratio varying from 1.3:1 to 2:1 [4]. Usually present in the infant with hepatomegaly, high output congestive heart failure and cutaneous hemangiomas. The majority of hemangiomas is small and requires no therapy.

Patients with HHE usually have an excellent prognosis, especially because the rates of spontaneous regression after the first year of life and long-term survival are about 70%.

Fork and Dens [5, 6] reported that most cases of HHE are asymptomatic with spontaneous regression. Although children with asymptomatic lesions may experience spontaneous regression within a year, those with symptomatic lesions require aggressive management due to the risk of death once symptoms commence.

HHE may be associated with morbidity and mortality, and traditional therapies may be associated with significant side effects.

Extensive arteriovenous shunting may be detected within these lesions, resulting in decreased peripheral vascular resistance. The maintenance of vascular bed perfusion may require increases in blood volume and cardiac output, which may lead to high cardiac output and congestive heart failure, observed in up to 50 to 60% of patients with HHE [6-8]. Other complications associated with this disease include high cardiac output congestive heart failure, consumptive coagulopathy, and thrombocytopenia.

Among the medical treatments for these tumors are corticosteroids, cytotoxic agents, INF- α , and irradiation. Patients who do not respond to medical treatment may undergo radical interventions, such as hepatic artery ligation, transcatheter hepatic artery embolization, surgical resection, and even liver transplantation [9]. Propranolol was discovered serendipitously in 2008 to induce accelerated involution of a large problematic facial proliferating IH; A limited number of case reports and case series have confirmed this biological effect of propranolol on proliferating HHE. Multicenter clinical trials are currently underway to confirm the safety and efficacy of Propranolol in the treatment of HHE, which may broaden its indications for the treatment of proliferating HHE [10]. The side effects of β -blockers in the treatment of HHE include hypotension, bradycardia, hypoglycemia, bronchospasm, hyperkalemia, nightmares, and gastrointestinal upsets [11]. Propranolol, at 1.5–2 mg/kg/day, administered in divided doses is effective for treating proliferating HHE with minor complications. Treatment needs to continue to an average age of 14.2 months to avoid rebound growth [12].

Studies presented evidence that this hemo-genic endothelium is governed by the renin-angiotensin system. The renin-angiotensin system can account for both the action of β -blockers and the process of spontaneous involution of HHE [12], the possibility of using inhibitors of angiotensin-converting enzyme (ACE) and that of angiotensin II receptor 2 as potential alternative therapy have been reported [13, 14].

This case documents the cure of a child with liver hemangioendothelioma and subclinical hypothyroidism. HHE contain increased type-3 deiodinase mRNA and elevated type-3 deiodinase enzyme activity. Type-3 deiodinase is the enzyme that is primarily responsible for the inactivation of thyroxine (T4) and triiodothyronine (T3). The increased tumoral enzyme activity leads to rapid degradation of thyroid hormones, resulting in consumptive hypothyroidism [3]. Hypothyroidism due to HHE may not be detected on newborn screening as the lesions usually appear

around the 4th to 6th weeks of life. Severe symptoms of hypothyroidism may be masked by HHE complications. Ayling et al [4] have speculated that HHE may secrete TSH-like factors that can interact with TSH receptors and may be responsible for the thyroid dysfunction.

Thyroid gland defects accounts for 75% of all cases of congenital hypothyroidism (CH), disorders of thyroid hormone metabolism (10%), hypothalamic or pituitary dysfunction (5%) of cases of CH. Pituitary hypothyroidism usually occurs with other disorders of pituitary dysfunction - eg, lack of growth hormone. Transient hypothyroidism (10%) is usually related to either maternal medications (eg, Carbimazole) or to maternal antibodies. In maternal thyroid disease, IgG auto-antibodies can cross the placenta and block thyroid function in utero; this improves after delivery. A number of genetic defects have been associated with CH. This includes mutations in the 'paired box gene 8' (PAX8) and the 'dual oxidase 2 gene' (DUOX2) [15, 16].

In our patient, the hypothyroid state was detected by evaluation at days 45 of age due to persistent jaundice. Propranolol treatment caused 80% regression of the hepatic hemangiomas after 3 months of treatment. Propranolol and L-thyroxin were discontinued after 6 months. The HHE in our case resolved with the 6-months, there was no recurrence in the first 2 years following treatment discontinuation.

Neonatal screening tests in our patient were *normal*. Thyroid gland showed a normal uniform echo texture on US. The mother of the baby was without thyroid dysfunction, and no-pharmacological management was taken by mother, during pregnancy.

4. Conclusion

The most IH are solitary; however, presence of more than five is unusual. Current recommendations are to screen for hepatic hemangiomas if five or more cutaneous IH are present. Oral Propranolol is a safe, efficacious treatment for problematic HHE. Thyroid function should be assessed periodically in a baby with HHE, especially if symptoms of hypothyroidism appear. L-thyroxine may be needed to achieve euthyroidism during the infancy.

References

- [1] Tan ST, Velickovic M, Ruger BM, Davis PF. Cellular and extracellular markers of hem-angioma. *Plast Reconstr Surg.* 2000; 106(3): 529–537.
- [2] Lister, WA. The natural history of the strawberry nevi. *Lancet.* 1938; 1: 1429.
- [3] Huang SA, Tu HM, Harney JW, Venihaki M, Butte AJ, Kozakewich HP, Fisman SJ, Larsen PR. Severe hypothyroidism caused by type 3 iodothyronine deiodinase in infantile hemangiomas. *N Engl J Med.* 2000; 343: 185–189.
- [4] Ayling RM, Davenport M, Hadzic N, Metcalfe R, Buchanan CR, Howard ER, Mieli-Vergani G. Hepatic hemangioendothelioma associated with production of humoral thyrotropin-like factor. *J Pediatr.* 2001; 138: 932–935.
- [5] Dena M, Selby J, Thomas Stocker, Myron A, Waclawiw, Chales L, Hitchcock, Kamal G, Ishak. Infantile hemangioendothelioma of the liver. *Hepatology* 1994; 20: 39-45.
- [6] Fok TF, Chan MS, Metreweli C, Ng PC, Yeung CK, Li AK. Hepatic haemangioendothelioma presenting with early heart failure in a newborn: treatment with hepatic artery embolization and interferon. *Acta Paediatr* 1996; 85: 1373-5.
- [7] Lu CC, Ko SF, Liang CD, Kuo HW, Tiao MM. Infantile hepatic hemangioendothelioma presenting as early heart failure: report of two cases. *Chang Gung Med J.* 2002; 25: 405–410.
- [8] Riley MR, Garcia MG, Cox KL, Berquist WE, Kerner JA., Jr Hepatic infantile hemangioendothelioma with unusual manifestations. *J Pediatr Gastroenterol Nutr.* 2006; 42: 109–113.
- [9] Selby DM, Stocker JT, Waclawiw MA, Hitchcock CL, Ishak KG. Infantile hemangioendothelioma of the liver. *Hepatology.* 1994; 20 (1 Pt 1): 39–45.
- [10] Siegfried EC, Keenan WJ, Al-Jureidini S, Leaute-Labreze C, de la Roque ED, Taieb A. More on propranolol for hemangiomas of infancy. *N Engl J Med.* 2008; 359(26): 2846–2847.
- [11] Itinteang T, Withers A, Leadbitter P, Day D, Tan S. Pharmacologic therapies for infantile hemangioma: is there a rational basis? *Plast Reconstr Surg.* 2011; 128: 499–507.
- [12] Itinteang T, Withers AH, Davis PF, Tan ST. Biology of infantile hemangioma. *Front Surg.* 2014; 1: 38.
- [13] Tan ST, Itinteang T, Day DJ, O'Donnell C, Mathy JA, Leadbitter P.. Treatment of infantile haemangioma with captopril. *Br J Dermatol.* 2012; 167: 619–24.
- [14] Christou EM, Wargon O.. Effect of captopril on infantile haemangiomas: a retrospective case series. *Aust J Dermatol.* 2012; 53: 216–8.
- [15] Park SM, Chatterjee VK; Genetics of congenital hypothyroidism. *J Med Genet.* 2005; 42(5): 379-89.
- [16] Rastogi MV, LaFranchi SH; Congenital hypothyroidism. *Orphanet J Rare Dis.* 2010; 5: 17.