

Case Report

Necrotizing Enterocolitis Complicating Sepsis in a Late Preterm Cameroonian Infant

Georges Pius Kamsu Moyo^{*}, Manuela Nguedjam, Lynda Miaffo

Department of Paediatrics, Faculty of Medicine and Biomedical Sciences, University of Yaoundé I, Cameroon

Email address:

kamsuzicfried@yahoo.fr (G. P. K. Moyo)

^{*}Corresponding author**To cite this article:**Georges Pius Kamsu Moyo, Manuela Nguedjam, Lynda Miaffo. Necrotizing Enterocolitis Complicating Sepsis in a Late Preterm Cameroonian Infant. *American Journal of Pediatrics*. Vol. 6, No. 2, 2020, pp. 83-86. doi: 10.11648/j.ajp.20200602.12**Received:** February 7, 2020; **Accepted:** February 19, 2020; **Published:** March 6, 2020

Abstract: Background: Necrotizing enterocolitis (NEC) is a leading cause of death from gastrointestinal disease in premature infants. It has been recognized for decades as the most common life-threatening medico-surgical intestinal emergency in newborns. The overall incidence of NEC has been reducing steadily during the past few years and has become even less common in late preterm and in term infants. However, accumulating evidence over the years suggest that NEC should be considered in a broader set including these subpopulations with risk factors. The disease might be associated with short and long-term complications, prolong hospitalization, and be cost worthy. Medical treatment alone may be done with considerable success, when diagnosed early enough with mild or moderate severity. In most cases, a multidisciplinary approach is recommended as much as possible. Nevertheless, primary prevention by breastfeeding promotion and standardized formula replacement when indispensable is pertinent. Method: We present and discuss based on current reviews, a case of early onset NEC complicating sepsis in a late preterm. Results: It appears that medical management alone which is indicated for moderate NEC may be quite successful when based on broad spectrum antibiotics that cover gram negative bacteria and anaerobes, together with intensive and supportive cares. Conclusion: NEC may occur precociously in late preterm. The prompt diagnosis may be made easier by radiological exams. A multidisciplinary approach for the management of stage II or moderate NEC may be more efficient. Breastfeeding remains an effective prevention against NEC.

Keywords: Necrotizing Enterocolitis, Prematurity, Preterm, Cameroon

1. Background

NEC is the most occurring and deadly gastrointestinal disease of the preterm infant [1]. It is a medico-surgical emergency with close to 15 million preterm infants affected by this condition each year, with about 11% live birth infants affected by this condition worldwide [1, 2]. In North America, an incidence close to 1-3 per 1000 births per year has been reported [1, 2]. NEC is associated with considerable mortality which could reach up to 20-30% and morbidity rate as high as 50% [3, 4]. There exists an inverse relationship between gestational age (GA) and the onset of NEC, as well as its severity [5, 6]. Though NEC seems to result from a combination of factors, the most admitted pathogenic hypothesis is described by an increased expression of the

Toll-Like Receptor 4 (TLR 4), which is a ligand to gram negative lipopolysaccharides [7]. TLR 4 in the premature gut under normal circumstances participates to the regulation of intestinal development [7]. However, during the “cross-switching phenomenon”, TLR 4 hyperactivity occurs in response to bowel colonization by microorganisms in the postnatal period [7]. This leads to deleterious effects including enhanced pro inflammatory cytokine release, mesenteric ischemia, impaired mucosal healing, necrosis and enterocyte apoptosis [8]. Furthermore, there is reduced goblet cell secretion of mucus and altered Paneth cells, which is responsible for reduced bowel protection [7]. The various risk factors of NEC reported in the literature include prematurity, very low birth weight <1.500 g, low Apgar score at 5 minutes, congenital heart and gastro intestinal defects, mechanical

ventilation, formula milk feeding, indomethacin, histamine H₂ receptor antagonists, empirical antibiotic use ≥ 5 days and anemia, which are factors related to the neonate [5, 7]. On the other hand, maternal factors include HIV-positive status, illicit drug abuse (as opiates, cannabinoids and cocaine), chorioamnionitis, vaginal delivery [5, 7]. The typical manifestation of NEC corresponds to a thriving preterm infant who suddenly presents with feeding intolerance, abdominal distension, bloody stool and signs of sepsis [3, 4]. Common paraclinical findings may be thrombocytopenia, leucopenia, intramural or peritoneal gas known as pneumatosis [7]. The management could be medical by broad spectrum antibiotic therapy and supportive care mainly, indicated for mild and moderate forms (according to stage I or II of Bell's classification), while surgical treatment by laparotomy and drainage or section of the affected intestinal portion may be envisaged for stage III or severe NEC [7].

2. Case Summary

This is the case of a late preterm male infant of 36 weeks of GA, weighing 2200g, who was transferred from the delivery room within his 1st hour of life for risks of neonatal sepsis and HIV exposure, from maternal fever and known maternal HIV infection under treatment. The neonate was delivered by emergency caesarean section indicated for maternal eclampsia. The pregnancy was poorly followed-up; Apgar score was 8/10 at the 1st minute; the neonate was feverish at 38.5°C; the rest of physical examination was otherwise normal. The diagnosis of sepsis was posed and complementary exams were asked for. The child was put on triple antibiotic therapy including Cefotaxim: 100mg/kg/12h, Ampicillin: 100mg/kg/12hr, Gentamicin: 5mg/kg/24hr. Nevirapin: 2mg/kg/24h, intravenous line with 10% dextrose at 60cc/kg/24h to be increased by 20cc/kg every 24h, and formula milk for preterm, starting with 20cc/kg the first day, and to be increased by 20cc/kg as well were initiated. Between the 3rd and 4th day, the neonate had developed severe respiratory distress with Silverman's score: 8/10, SPO₂: 85%, tachycardia: 160 beats/min, polypnea: 64 cycles/min, temperature: 36.8 °C, rectorrhagia and later on, abdominal distension and vomiting. Contributive overall work-up showed lymphocytosis: 14500/mm³, moderate normocytic-normochromic anemia: 12.5g/dl, elevated C-Reactive Protein (CRP): 48mg/l and a plain abdominal radiography which showed pneumatosis intestinalis in favor of stage II or moderate NEC complicating sepsis (image II).

Feeding was momentarily stopped, a siphoning nasogastric tube and oxygen were placed, Antibiotic therapy was switched to Imipenem: 60mg/kg/24h twice daily, Amikacin: 15mg/kg/24h and Metronidazol: 30mg/kg/24h thrice daily. Vitamin K1 was administered at 1mg/kg/24h for 3 days. Caloric needs were estimated at 120kcal/kg/24h, with amino acids: 3g/kg/24h = 154 Kcal, lipids 3g/kg/24h, Dextrose 12.5%: 18g/kg/24h + Ions = 130 Kcal. Gastric protection was by Omeprazole 1mg/kg/24h. Vital parameters, gastric secretion, diuresis and stool were followed-up.

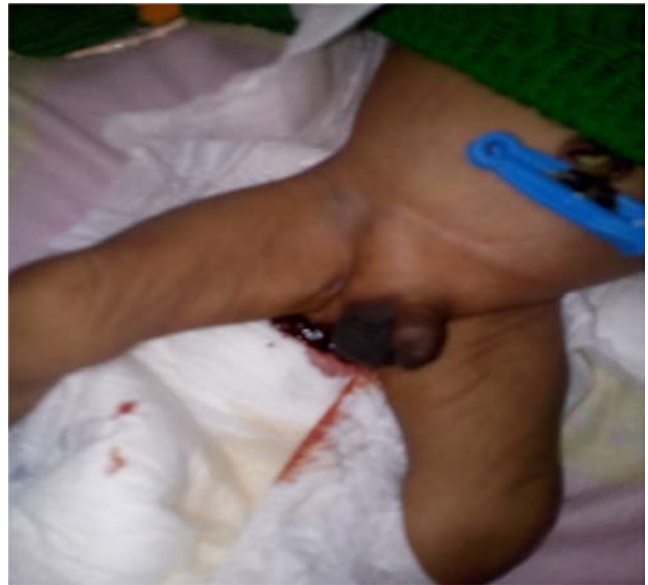

Figure 1. Rectorrhagia.

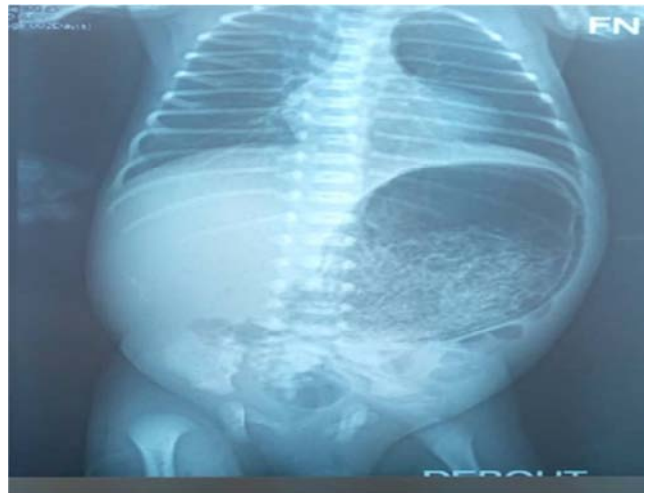


Figure 2. Pneumatosis.

The evolution was favorable after 16 days of hospitalization and the neonate was discharged with a weight of 2150g. Multivitamins ADEK were prescribed for 6 months: 0,33ml/day, Iron sirop: 3mg/kg/24h for 3 months, Nevirapin: 2mg/kg/24h for 12 weeks and counselling for good breastfeeding practices was done.

3. Discussion

Although the majority of NEC occur among preterm infants between 27 and 34 weeks of GA, with high incidence in neonates weighing ≤ 1500 g, there exist a small subset of cases among neonates ≥ 35 weeks of GA [1, 5, 7]. The disease is quite prevalent among male neonates of African American origins, probably related to higher rates of prematurity in this populations which could be as high as 13.23% [9]. While neonates born at 27 weeks GA develop NEC within 4-5 weeks after birth in average, those born at GA close to 37 weeks develop the disease within 2 weeks in average [10]. This has

been explained by delayed bowel microbial colonization in extremely and very preterm infants who are late-fed and may be on antibiotics for sometimes, leading to distorted gut microbiota establishment [7]. In the case presented, the onset of NEC was precocious within 4 days after birth. Among the various risk factors of NEC, the most predominant appear to be prematurity, bacterial colonization of the gut and formula milk feeding, which were all present in this case [5, 11]. The earliest sign of NEC is generally feeding intolerance which may be characterized by vomiting, abdominal distension and/or important gastric residuals $\geq 50\%$ or $\geq 2\text{ml/kg}$, though measurements may be variable in time and methods used [11, 12]. Our patient contrarily presented rectorrhagia as first sign. Concerning paraclinical examinations that aid in the diagnosis of such moderate NEC, the most common finding is pneumatosis intestinalis on a plain abdominal radiography [7]. Nevertheless, ultrasound might better reveal pneumoperitonium in severe NEC, but is less effective than x-ray in diagnosing intramural trapped gas [13, 14]. Occasionally, thrombocytopenia due to platelets involvement or consumption, and leucopenia may be present, but this was not the case with our patient though bleeding by rectorrhagia occurred [7]. Our patient rather had lymphocytosis perhaps associated with the underlying sepsis. The biomarker CRP was elevated but other acute phase reactants such as TNF- α , IL-6 and IL-8 recommended were not sampled [11, 15]. However, none of the pro inflammatory cytokines apart from the promising intestinal fatty-acid binding protein from enterocyte damage is specific to NEC [16]. Furthermore, it is described that the identification of specific pathogen as main etiological factor remains elusive, perhaps justifying the fact that all cultures performed were negative [17]. The effective management of mild to moderate NEC relies on prompt and accurate initiation of a holistic therapy based on broad spectrum antibiotics, covering essentially gram negative bacteria and anaerobes [7]. Nevertheless, specific abnormal bacteria incrimination in causing as opposed to favoring or being a consequence of NEC is yet to be demonstrated [6, 11, 17]. Switching to stronger antibiotics was done in the present case because the patient had already been on first line antibiotics for a number of days before the onset of NEC. Intensive and supportive cares with keen patient monitoring is equally recommended in such cases while surgical interventions are reserved for severe NEC [7]. Breastmilk feeding is encouraged as soon as digestive intolerance resolves, as it favors weight gain. In effect, several reliable studies have shown that breast milk statistically and significantly reduces the incidence of NEC due to its variety content of bioactive factors among which some are speculated to reduce glycogen synthase kinase 3β activity with TLR 4 inhibition [18].

4. Conclusion

Although the majority of NEC occur in preterm infants between 27 and 34 weeks of GA, with high incidence in neonates weighing $\leq 1500\text{g}$, there exist a small subset of cases among

neonates ≥ 35 weeks of GA for which the onset could be rapid. The diagnosis appears to be easy, based on evident gastrointestinal tract manifestations and radiological findings. Medical management alone which is indicated for mild and moderate NEC may be quite successful when based on broad spectrum antibiotics covering especially gram negative bacteria and anaerobes. Intensive and supportive cares, with multidisciplinary approach should be provided as much as possible in order to improve the outcome. However, prevention by breastmilk feeding when possible appears to be most relevant.

Funding

Private.

Conflict of Interest

The authors declare that they have no competing interest.

Ethical Approval

The study was approved by the Institutional Ethics Committee.

Acknowledgements

Hospitals authorities, all collaborators to this project.

References

- [1] Stoll BJ, Hansen NI, Bell EF, Walsh MC, Carlo WA, Shankaran S et al. Trends in care practices, morbidity, and mortality of extremely preterm neonates, 1993–2012. *JAMA*. 2015; 314: 1039–1051.
- [2] Papillon S, Castle SL, Gayer CP, Ford HR. Necrotizing enterocolitis: contemporary management and outcomes. *Adv Pediatr*. 2013; 60: 263–279.
- [3] Neu J, Walker WA. Necrotizing enterocolitis. *N Engl J Med*. 2011; 364: 255–264.
- [4] Fitzgibbons SC, Ching Y, Yu D, Carpena J, Kenny M, Weldon C et al. Mortality of necrotizing enterocolitis expressed by birth weight categories. *J Pediatr Surg*. 2009; 44 (6): 1072–5; discussion 1075–6.
- [5] Rose AT, Patel RM. A critical analysis of risk factors for necrotizing enterocolitis. *Semin Fetal Neonatal Med*. 2018; 23 (6): 374–9.
- [6] Battersby C, Santhalingam T, Costeloe K, Modi M. Incidence of neonatal necrotising enterocolitis in high-income countries: a systematic review. *Arch Dis Child Fetal Neonatal Ed*. 2018; 103 (2): F182–F189.
- [7] Niño DF, Sodhi CP, Hackam DJ. Necrotizing enterocolitis: new insights into pathogenesis and mechanisms. *Nat Rev Gastroenterol Hepatol*. 2016; 13 (10): 590–600.
- [8] Molteni M, Gemma S, Rossetti C. The Role of Toll-Like Receptor 4 in Infectious and Noninfectious Inflammation. *Mediators Inflamm*. 2016; 2016: 6978936.

- [9] Hamilton BE, Martin JA, Osterman MJK, Curtain SC. Births: preliminary data for 2014. *Natl Vital Stat Rep.* 2015; 64: 1–19.
- [10] Yee WH, Sonraisham AS, Shah VS, Aziz K, Yoon W, Lee SK. Incidence and timing of presentation of necrotizing enterocolitis in preterm infants. *Pediatrics.* 2012; 129: e298–e304.
- [11] Alganabi M, Lee C, Bindi E, Li Bo, Pierro A. Recent advances in understanding necrotizing enterocolitis [version 1; referees: 2 approved] *F1000Research* 2019, 8 (F1000 Faculty Rev): 107 (<https://doi.org/10.12688/f1000research.17228.1>).
- [12] I YF, Lin HC, Torazza RM, Parker L, Talaga E, Neu J. Gastric residual evaluation in preterm neonates: a useful monitoring technique or a hindrance? *Pediatr Neonatol.* 2014; 55: 335–340.
- [13] Janssen Lok M, Miyake H, Hock A, Daneman A, Pierro A, Offringa M. Value of abdominal ultrasound in management of necrotizing enterocolitis: a systematic review and metaanalysis. *Pediatr Surg Int.* 2018; 34 (6): 589–612.
- [14] Yikilmaz A, Hall NJ, Daneman A, Gerstle JT, Navaro OM, Monnedin R, et al. Prospective evaluation of the impact of sonography on the management and surgical intervention of neonates with necrotizing enterocolitis. *Pediatr Surg Int.* 2014; 30: 1231–1240.
- [15] Niemarkt HJ, De Meij TGJ, Van de Velde ME, Van der Schee MP, Van Goudoever JB, Kramer BW et al. Necrotizing enterocolitis: a clinical review on diagnostic biomarkers and the role of the intestinal microbiota. *Inflamm Bowel Dis.* 2015; 21: 436–444. [PubMed: 25268636].
- [16] Heida FH, Hulsher JBF, Schunrink M, Timmer A, Kooi EMW, Bos AF et al. Intestinal fatty acid-binding protein levels in Necrotizing Enterocolitis correlate with extent of necrotic bowel: results from a multicenter study. *J Pediatr Surg.* 2015; 50: 1115–1118.
- [17] Coggins SA, Wynn JL, Weitkamp JH. Infectious causes of necrotizing enterocolitis. *Clin Perinatol.* 2015; 42: 133–154. ix. [PubMed: 25678001].
- [18] Good M, Sodhi CP, Egan CE, Afrazi A, Jia H, Yamaguchi Y et al. Breast milk protects against the development of necrotizing enterocolitis through inhibition of Toll-like receptor 4 in the intestinal epithelium via activation of the epidermal growth factor receptor. *Mucosal Immunol.* 2015; 8: 1166–1179.