

Duplication Cysts in Caecum in Three Months Old Girl

Denis Fiolita^{1,*}, I Putu Gede Karyana¹, I Gusti Ngurah Sanjaya Putra¹,
Ni Nyoman Metriani Nesa¹, Made Darmajaya², Kadek Deddy Ariyanta²

¹Department of Child Health, Medical Faculty of Udayana University, Sanglah Hospital, Denpasar, Indonesia

²Pediatric Surgery Division of Surgery Department, Medical Faculty of Udayana University, Sanglah Hospital, Denpasar, Indonesia

Email address:

denismeregawa@gmail.com (D. Fiolita)

*Corresponding author

To cite this article:

Denis Fiolita, I Putu Gede Karyana, I Gusti Ngurah Sanjaya Putra, Ni Nyoman Metriani Nesa, Made Darmajaya, Kadek Deddy Ariyanta.

Duplication Cysts in Caecum in Three Months Old Girl. *American Journal of Pediatrics*. Vol. 6, No. 2, 2020, pp. 105-108.

doi: 10.11648/j.ajp.20200602.17

Received: February 12, 2020; **Accepted:** February 25, 2020; **Published:** March 10, 2020

Abstract: Gastrointestinal duplication cysts are rare congenital anomalies. It can occur in any part of the alimentary tract but they are rare in the caecum. The reported incidence is 1:4.500 births. The exact etiology is unknown. There is no common clinical pattern of signs and symptoms of duplications. The perioperative diagnosis duplication of cysts are often inaccurate. Histopathological examination enables us to confirm the diagnosis. Resection is the treatment of choice with an excellent outcome. The aim of this case report was to describe the clinical presentation and treatment of duplication cysts. A three months old girl had abdominal distention since 7 days before admitted to the hospital. This complaint was accompanied with fever and vomiting. She couldn't have defecation and had history of black greenish feces. Physical examination revealed distended abdomen and decreased of bowel sound. Laboratory investigation showed normal features, abdominal X-Ray found enlargement of the intestine with increasing of the gas distribution and ground glass appearance. We diagnosed the patient with observation of abdominal distention caused by suspect ileus paralysis with different diagnosis hirschsprung disease. After the diagnosis, laparotomy exploration were performed. During surgical procedure, the surgeon found duplication cysts in the caecum area, then they performed resection with end to end anastomose and took the tissue for biopsy. The biopsy result was duplication cysts. Nine days after surgery, the patient was discharged in good condition. A high index of suspicion for diagnosis duplication cysts was required and the result of surgical treatment was good.

Keywords: Caecum, Gastrointestinal Duplication Cysts, Surgical Excision

1. Introduction

Gastrointestinal duplication cysts are rare congenital anomalies. It can occur in any part of the alimentary tract. The most common site is in the ileum, followed by esophagus, large bowel, jejunum, stomach and duodenum but they are rare in the caecum. The reported incidence is 1:4.500 births, about 60-70% detected in antenatally or within first two years of life. In the most cases there is no sex predilection. No familial or racial association has been reported [1].

There is no common clinical pattern of signs and symptoms of duplications. They present with a variety of symptoms or sometimes as masses found incidentally during

routine examinations or investigations, or they are encountered during an operation for other problems. The clinical presentation also varies according to the age of the patient, location of duplication, type of mucosal lining, duration of disease, and presence of complications. Infants and neonates present with abdominal pain, nausea, vomiting, bleeding, abdominal distention, abdominal mass, obstruction and intussusception [2, 3].

Diagnosis is confirmed with histopathological examination. Resection is the treatment of choice with an excellent outcome. Good sectioning of the cyst wall with attached bowel help in ruling out the malignant changes [4].

The objective of this case report was to describe clinical presentation and treatment of duplication cyst.

2. Case Illustration

A three months old girl, were brought to emergency room (ER) Sanglah hospital. Patient was referred from a private hospital with observation of abdominal distention suspect hirschsprung disease. Patient had abdominal distention since 7 days before admitted. This complaint was accompanied with fever and vomiting. Patient had vomiting after drinking milk. The vomit consisted of meal which she consumed. The body fever was fluctuated, it decreased after consumption of medicine. The highest temperature of fever was 38°C. She couldn't have defecation since 2 days before admitted. She had history of black greenish feces since 11 days before admitted. After arrived in ER Sanglah hospital, the surgeon had done rectal washing, but the stool couldn't be found.

Patient was the first child in the family, no history of gastrointestinal congenital anomalies in both parents. She was born vigorously with body weight of 3200 grams, and term in gestational age. No illnesses history during the pregnancy period were noted, no history of consuming any traditional medicine. There were no abnormality during pregnancy or delivery reported. There were no abnormality in ultrasound examination.

The head was normal in shape, the hair was black in colour, the fontanel was flat. There were no sunken eyes, jaundice on sclera, neither conjunctiva injection and anemia. The pupils light reflect was normal. The ears, nose, and throat examination were in normal limit. It was no lymph nodes enlargement found on the neck. The chest was symmetrical both on rest and movement. Breath sound was vesicular without rales or wheezing, the first and second heart sound were normal, regular and no murmur in auscultation. There were no lymph nodes enlargement found on both of axilla. Abdomen was distended with difficulty to evaluate liver and spleen. Bowel sound was decreased when auscultated. Anal and genital examination was normal. Rectal toucher examination found normal rectal toucher, no palpable mass and no flushed feces. The yellowish feces with no blood on the hand gloves was found.

Abdominal X-Ray showed an enlargement of the intestine with increasing of the gas distributions and ground glass appearance in lower abdominal area (mostly found in a half sitting position) (Figure 1). Laboratory results such as complete blood count, electrolytes count, liver and kidney functions were within normal limit.

Based on the clinical and adjunctive examination, the patient was diagnosed with observation of abdominal distention caused by suspect ileus paralysis with different diagnosis hirschsprung disease. Patient has been given antibiotic (ceftriaxone), gaster decompression with nasogastric tube, temporary fasting with parenteral nutrition and prepared for laparotomy exploration.

During surgical procedure, the surgeon found duplication cysts in the caecum area, then they performed resection with end to end anastomose and took the tissue for biopsy (pathology anatomy examination) (Figure 2). The result was cysts duplication (compatible with the clinical examination),

chronic colitis, with 2 reactive lymph nodes.

Patient was admitted to the intermediate ward (IW) after surgery. The patient was given antibiotic therapy of intravenous cefoperazone sulbactam, amikacin, metronidazole, and total parenteral nutrition. Three days after surgery, tropic feeding from the feeding tube was given. On the seventh day after the surgery, the patient was full fed and could to ward. Two days after moving to ward, the patient was discharged in good condition.

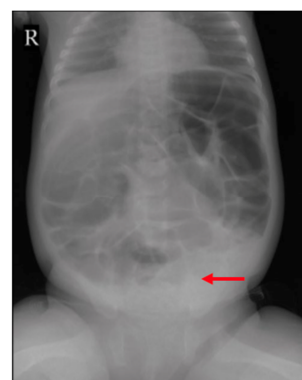


Figure 1. Abdomen X-Ray.

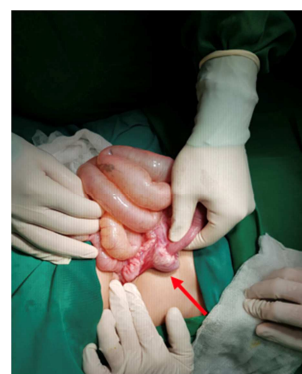

Figure 2. Duplication cysts in caecum (during surgery).

3. Discussion

Gastrointestinal duplication cyst are rare congenital anomalies, originating anywhere along alimentary tract from the tongue to the anus. The reported incidence is 1:4.500 births, most duplications are detected in children (antenatally or within first two years of life) and fewer than 30% of all duplications are diagnosed in adults. In the most cases, there is no sex predilection. No familial or racial association has been reported [1]. In this case, patient was a girl, three months old, without history of gastrointestinal congenital anomalies in both parents.

The exact etiology is unknown, several theories have been proposed. They are many theories on embryology of gastrointestinal duplication. None of these theories, however is able to explain all types of duplication. These embryological theories include the following [5, 6]:

1. Split notochord syndrome: gastrointestinal duplication is related to the development of neuroenteric canals, which

is related to the thoracic duplications that have associated abnormalities of the cervical and thoracic vertebrae.

2. Abnormalities of recanalization of the solid stage: it is only some part of the foregut that undergoes recanalization, and this process occurs on both the mesenteric and antimesenteric sides of the bowel, whereas duplications are found only on mesenteric side.
3. Remnant of embryologic diverticula: this may explain the higher frequency of gastrointestinal duplication found in the terminal ileum because there are usually numerous diverticula found during development. These presence of heterotopic mucosa, the mesenteric location of gastrointestinal duplication and presence of tubular duplications.
4. Partial twinning: this can explain duplications of the hindgut. These usually associated with malformations of the genitourinary tract.
5. Environmental factors such as trauma or hypoxia: in early fetal development, environmental factors may lead to duplications and duplications may, in fact, be a part of the spectrum of intestinal atresia.

In this case, no illnesses history during the pregnancy period were noted, nor history of consuming any traditional medicine. There were no abnormality during pregnancy or delivery reported.

There is no common clinical pattern of signs and symptoms of duplications. They present with a variety of symptoms or sometimes as masses found incidentally during routine examinations or investigations, they are encountered during an operation for other problems. The clinical presentation also varies according to the age of the patient, location of duplication, type of mucosal lining, duration of disease and presence of complications. The clinical presentation may be due to the pressure effect of the duplication. Duplications in the abdomen commonly present with pain, vomiting, abdominal distention and abdominal mass. The clinical presentation may also be secondary to complications of the duplications. These include intussusception, volvulus, perforation, bleeding, peptic esophageal stricture and malignant transformation, as seen in adults [7, 8]. In this case, patient had abdominal distention, accompanied with fever and vomiting. Patient had vomiting after drinking milk and vomit consisted of meal she consumed. She couldn't have defecation and had history of black greenish feces before admitted to the hospital.

The prenatal diagnostic of abdominal cyst lesions is relatively common. They may either represent a normal structural variant or pathological entity that may require surgical intervention after birth. In clinical practice, these lesions are most frequently detected at the time of routine morphology scan at 18-20 weeks of gestational age. However, gastrointestinal malformation does not become apparent until the third trimester. Additionally, some cysts may develop and then resolve during intrauterine life. The preoperative diagnostic duplication of cyst are often inaccurate. Diagnosis is usually done using imaging modalities such as plain X-Rays,

barium studies, ultrasonography, CT scan or MRI, technetium 99m pertechnetate scintigraphy scan and laparoscopy. Plain X-Rays may show evidence of intestinal obstruction. Barium studies demonstrate filling defect or rarely a communication between the cyst and normal bowel. Ultrasonography is the most common modality used and should be the first choice. It typically show a double layered wall (inner echogenic mucosa and outer sonoluscent muscular layer). When this double layered pattern is present on ultrasonography, a gastrointestinal duplication cyst is confirmed and there is no need for further radiologic evaluation. CT scan are more useful in demonstrating the precise anatomical relationship between cysts and surrounding structure. These cysts can manifest as smooth, rounded, fluid filled cysts or tubular structure with thin slightly enhancing wall on CT scan. MRI show intracystic fluid with heterogenous signal density. Technetium 99m pertechnetate scintigraphy scan indicates the definite existence of gastrointestinal duplication cyst when it contains ectopic gastric mucosa. This is especially useful in esophageal, duodenal and tubular small bowel duplication with a high incidence of heterotropic gastric mucosa. Laparoscopy with a high incidence of heterotropic gastric mucosa. However, all these modalities allow us only to suspect the presence of an abnormal lesion and diagnostic confirmation is possible only after resection [9, 10]. In this case, there were no abnormality in ultrasound examination during pregnancy. However, the abdominal X-Ray on admission showed an enlargement of the intestine with increasing of gas distribution and ground glass appearance in lower abdominal area.

Histopathological examination enables us to confirm the diagnosis. According to the definition of Ladd and Gross, the cyst must be adherent to some part of the gastrointestinal tract, contain smooth muscle in the wall and have an internal lining of alimentary epithelium. They are named according to the location and are generally cystic or tubular masses, in 10-15% cases the cysts are multiple [11, 12]. In this case, the surgeon took the tissue for biopsy (pathology anatomy examination). The result was duplication cysts (compatible with the clinical examination), chronic colitis, with 2 reactive lymph nodes.

Although many of the duplications are diagnosed incidentally, most patients present with a combination of pain and/or obstructive symptoms. These symptoms may be the direct effect of distention of duplication or caused by compression of adjacent organs (including their associated blood supplies) [13, 14]. Excision should be considered in all cases wherever possible. The surgical approach varies with location and type of the cysts. Resection and anastomosis may be required. However, gastrointestinal duplication cysts in children is a benign disease, and any treatment should not be more radical than to eliminate the patient complaints and prevent further recurrence. Important points to be considered in surgical of gastrointestinal duplication cysts include [14]:

1. The nature of the blood supply shared between the duplication and native bowel.
2. The presence of heterotopic gastric mucosa, which will negate internal drainage due to the risk of peptic

ulcerations.

3. The relationship with adjacent structure.

The long-term prognosis of enteric duplication cyst is excellent after surgical treatment. However, those with associated anomalies and the extent of the physiological disturbance caused by them [14, 15]. In this case, based on clinical and adjunctive examination the patient prepared for laparotomy exploration. On the surgical treatment, surgeon found cysts duplication in the caecum area, then did resection with end to end anastomose and took the tissue for biopsy (pathology anatomy examination). The patient was discharged in good condition.

4. Summary

A three months old girl, patient had abdominal distention since 7 days before admitted. This complaint was accompanied with fever and vomiting. She couldn't have defecation since 2 days before admitted. She had history of black greenish feces since 11 days before admitted. Physical examination revealed abdomen was distended with difficulty to evaluate liver and spleen. Bowel sound was decreased when auscultated. Laboratory investigation showed normal limit, abdominal X-Ray found enlargement of the intestine with increasing of gas distribution and ground glass appearance in lower abdominal area. We diagnosed the patient with observation of abdominal distention caused by suspect ileus paralysis with different diagnosis hirschsprung disease. After the diagnosis, laparotomy exploration were performed. During surgical procedure, surgeon was found cysts duplication in the caecum area, then they performed resection with end to end anastomose and took the tissue for biopsy (pathology anatomy examination). The result was cysts duplication (compatible with the clinical examination). Nine days after surgery, the patient was discharged in good condition.

Disclosure

The authors hereby declare no personal or professional conflicts of interest regarding any aspect of this case report.

References

- [1] Sharma S, Yadav AK, Mandal AK, Zaher S, Yadav DK, Samie A. Enteric Duplication Cysts in Children: a clinicopathological dilemma. *Journal of Clinical and Diagnostic Research*. Vol. 9, No. 8, 2015, pp. 8-11.
- [2] Zavras N, Christianakis E, Papakonstantinou D, Velaoras K, Tsilikas K, Ereikat K. Alimentary Tract Duplications in Infancy and Childhood: a 25-year experience with focus on rare types of the disease. *Open Journal of Pediatrics*. Vol. 3, No. 4, 2013, pp. 324-30.
- [3] Tiwari C, Shah H, Waghmare M, Makhija D, Khedkar K. Cysts of Gastrointestinal Origin in Children: varied presentation. *Pediatric Gastroenterology Hepatology & Nutrition*. Vol. 20, No. 2, 2017, pp. 94-99.
- [4] Liu R, Adler DG. Duplication Cysts: diagnosis, management, and role of endoscopic ultrasound. *Eusjournal*. Vol. 3, No. 3, 2014, pp. 152-8.
- [5] Elumalai G, Senguttuvan E. Intestinal duplication embryological and its clinical importance. *Elixir Embryology*. Vol. 103, 2017, pp. 45652-6.
- [6] Jeziorczak PM, Warner BW. Enteric Duplication. *Clinics in Colon and Rectal Surgery*. Vol. 31, No. 2, 2018, pp. 127-31.
- [7] Abdellaoui H, Mahmoudi A, Charki MT, Bouabdallah Y. Caecal Duplication Cyst: a rare cause of neonatal intestinal obstruction. *BMJ*. 2018, pp. 1-3.
- [8] Jehangir s, Ninan PJ, Jacob TJ, Eapen A, Mathai J, Thomas RJ, et al. Enteric Duplication in Children: experience from a tertiary center in south india. *Journal of Indian Association of Pediatric Surgeons*. Vol. 20, No. 4, 2015, pp. 174-8.
- [9] Nebot CS, Salvador RL, Palacios EC, Aliaga SP, Pradas VI. Enteric Duplication Cysts in Children: varied presentations, varied imaging findings. *Insights Into Imaging*. 2018, pp. 1-10.
- [10] Mayer JP, Bettoli M. Alimentary Tract Duplications in New Borns and Children: diagnostic aspects and the role of laparoscopic treatment. *World Journal of Gastroenterology*. Vol. 20, No. 39, 2014, pp. 14263-7.
- [11] Dombale V, Patil BV, Kerudi BH. Enteric Duplication Cyst of Caecum Presenting with Intestinal Obstruction – a Case Report. *Journal of Khrishna Institute of Medical Sciences University*. Vol. 1, No. 2, 2012, pp. 147-9.
- [12] Ozay O, Cengiz F, Ekinci N, Celik SC, Kamer KE. Undetected Duplication Cyst of The Cecum until Adulthood. *Journal of Clinical and Experimental Investigations*. Vol. 9, No. 3, 2018, pp. 137-9.
- [13] Singh VS, Shah PA, Roplekar PM, Sudhamani S, Desai P. Cecal Duplication Cyst: a rare case report with review literature. *International Journal of Health & Allied Sciences*. Vol. 5, No. 2, 2016, pp. 115-7.
- [14] Rasool N, Safdar CA, Ahmad A, Kanwal S. Enteric Duplication in Children: clinical presentation and outcome. *Singapore Medical Journal*. Vol. 54, No. 6, 2013, pp. 343-6.
- [15] Aggarwal H, Singh S, Patidar N. Multiple Intraabdominal Cysts Could be a Duplication of Intestine: a case report and treatment protocol. *The Internet Journal of Surgery*. Vol. 15, No. 2, 2007, pp. 1-4.