

**Case Report**

# Invasive Myofibromatosis with Visceral Involvement in a Term Newborn: A Case Report

Erica Ortiz<sup>1</sup>, Aaina Kochhar<sup>2</sup>, Indira Chandrasekar<sup>3,\*</sup><sup>1</sup>Department of Pediatrics, Pediatrics Resident, Valley Children's Helathcare, Madera, California, USA<sup>2</sup>Department of Genetics and Metabolism, Valley Children's Helathcare, Madera, California, USA<sup>3</sup>Department of Neonatology, Valley Children's Helathcare, Madera, California, USA**Email address:**

eortiz1@valleychildrens.org (E. Ortiz), akochar@valleychildrens.org (A. Kochhar), ichandrasekar@valleychildrens.org (I. Chandrasekar)

\*Corresponding author

**To cite this article:**Erica Ortiz, Aaina Kochhar, Indira Chandrasekar. Invasive Myofibromatosis with Visceral Involvement in a Term Newborn: A Case Report. *American Journal of Pediatrics*. Vol. 6, No. 2, 2020, pp. 173-177. doi: 10.11648/j.ajp.20200602.30Received: March 16, 2020; Accepted: April 2, 2020; Published: April 29, 2020

---

**Abstract:** Background: Infantile myofibromatosis is a rare disease characterized by solitary or multiple benign tumors. Aggressive myofibromatosis with extensive visceral involvement at birth is a very rare condition with poor prognosis. Case report: We report a term male infant born with multi-system myofibromatosis involving the skin, bone, brain, heart, lung, and GI tract. The patient received chemotherapy but had a protracted clinical course complicated by intestinal obstruction and perforation, and failure to thrive. Pathology of the tumor showed presence of spindle cells. Immunohistochemical analysis of this tissue was positive for vimentin, smooth muscle actin, and CD34 but negative for Muscle-Specific Actin (MSA) and desmin. Also, electron microscopic analysis detected the presence of subcellular myofibroblastic structures. Next generation sequencing analysis of the patient's blood and tumor tissues identified a germline mutation in *PDGFRB* gene p. R561C allele (c.1681C>T), as well as a second activating *PDGFRB* mutation (p. N666S) which was present in the tumor tissue only. Parental testing showed that the germline mutation was inherited from the father, who was asymptomatic. The second mutation is likely responsible for the aggressive nature of the condition in this patient. He eventually died due to cardiorespiratory failure. Conclusion: Early diagnosis by pathology and genetic analysis in patients' with extensive myofibromatosis will help to determine targeted chemotherapy and prognosis.

**Keywords:** Infantile Myofibromatosis, Germline Mutation, *PDGFRB* Mutation

---

## 1. Introduction

Infantile myofibromatosis (IM) is a mesenchymal neoplasm of infancy and early childhood caused by unchecked proliferation of myofibroblasts, cells that are mesenchymal in origin, with features of both smooth muscle and fibroblasts. First described by Stout in 1954, various terms such as congenital multiple fibromatosis, diffuse congenital fibromatosis, multiple mesenchymal hamartomas, multiple vascular leiomyomas of the newborn, benign mesenchymomas, and generalized hamartomatosis were initially used to describe this condition. [1, 2] Subsequently Chung and Enzinger coined the term IM after careful review of 61 cases [3].

IM can be noted at birth or during infancy, with the vast majority of cases being diagnosed before two years of age. The disease can present as single or multicentric nodular masses in various soft tissues, bones, or visceral organs, including the orbital bone, lip, oral cavity, central nervous system, gastrointestinal tract, lungs, myocardium, liver, and biliary tree.<sup>4</sup> Approximately 50% of myofibromas occur in the head and neck, with 60% being congenital. [5, 6] These masses are typically not malignant and do not metastasize, but can damage surrounding tissues as they grow in size. Notably, soft tissue lesions can be multiple and regress, while visceral lesions are more aggressive and are associated with poorer prognoses. [4, 7] Although the incidence of this disease is extremely rare, IM is the most common fibrous tumor of

infancy.

## 2. Case Report

The patient was a term infant born via vaginal delivery to a 25-year-old G3P0SAB2 Hispanic female. The patient's mother had two previous spontaneous miscarriages at 6 and 8 weeks, however this pregnancy was uncomplicated, with prenatal care starting at 8 weeks gestation. The infant was small for his gestational age, with a birth weight of 2.45 kilograms, and multiple skin lesions were noted at birth. Specifically, lesions were present throughout his chest, abdomen, and lower extremities. Most of the lesions were 2–8 mm in diameter and bluish-purple in color, and some were erythematous. The patient also exhibited a soft cardiac murmur.

After delivery, a full sepsis workup was initiated and he was started on empiric antibiotics. CBC showed thrombocytopenia (platelet count of  $45,000/\text{mm}^3$ ) but no other abnormalities and the infant was transferred to our NICU for further management. While the initial workup for congenital infection was negative, a dilated eye exam showed multiple whitish retinal lesions (Figure 1). Upon follow-up examination, however, no new lesions or increases in lesion size were observed. Echocardiogram showed multiple small hyperechoic masses throughout the myocardium and on the interventricular septum, which were fixed. The tricuspid valve septal leaflet appeared tethered with limited mobility, and trivial mitral valve regurgitation was noted. Lastly, MRI of the head showed multiple enhancing vascular-type lesions of the cerebellar hemispheres and a large focus in the vermis behind the fourth ventricle. There were also brightly enhancing foci in the right frontal, right parietal, and posterior left hippocampal regions (Figure 2).

Feeds were initiated with expressed breast milk on second day of life. The following day, the patient developed abdominal distention, tenderness, and frank bloody stool, but was otherwise asymptomatic and showing hunger cues. At that time, plain abdominal radiography showed a nonspecific mild abnormal gas pattern. Rounded densities were incidentally visualized within the bowel on imaging and an abdominal ultrasound showed a significant amount of intraperitoneal fluid that exhibited echogenicity consistent with hemorrhage. At least three intraluminal masses were noted, one of which was slightly intussuscepted, and some of the bowel loops were dilated, indicating potential bowel obstruction.

The patient developed free air in his abdomen two days later and was taken to the operating room. During surgery, multiple hemangioma-like lesions were noted on the intestinal walls. The patient underwent resection of a 3-cm portion of proximal ileum, an ileostomy, and reduction of intussusception due to another, distal lesion (Figures 3, 4). An additional large lesion was left untouched near the ligament of Treitz. One to two vascular polypoid lesions were noted in every centimeter of the patient's bowel. He was started on feeds postoperatively and tolerated small amount of milk, with some dumping

resulting from short bowel syndrome. Due to the development of feeding intolerance, further imaging was conducted, showing small bowel-to-small bowel intussusception. This intussusception reduced spontaneously.

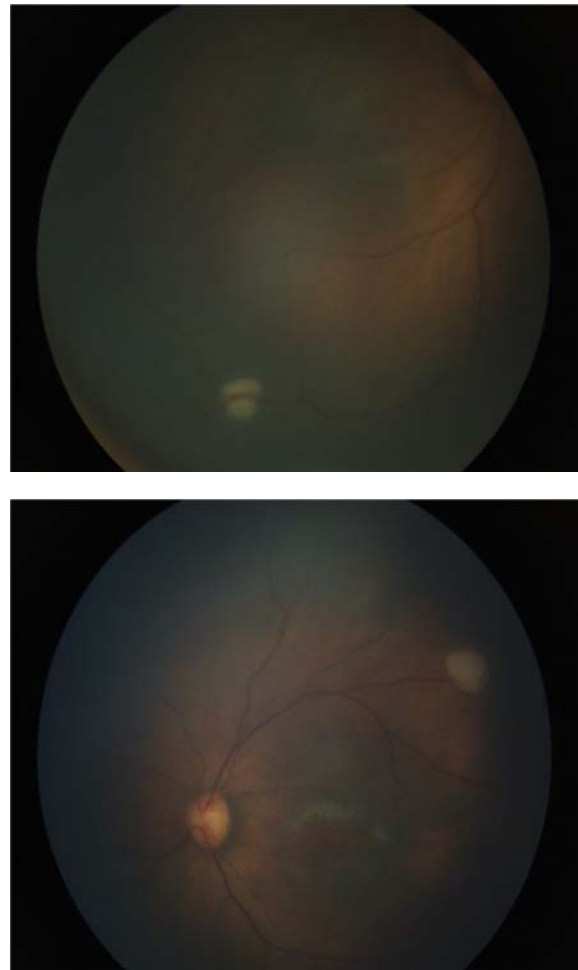


Figure 1. Photographic images depicting multiple retinal lesions observed in the patient.

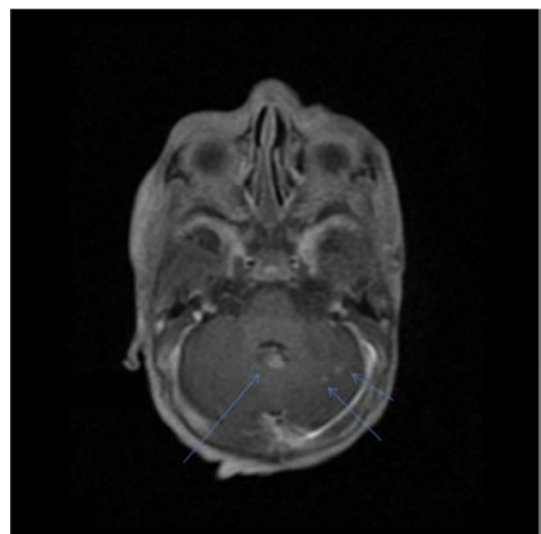
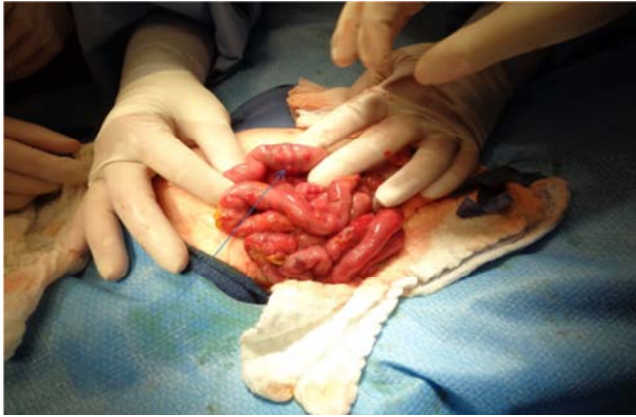
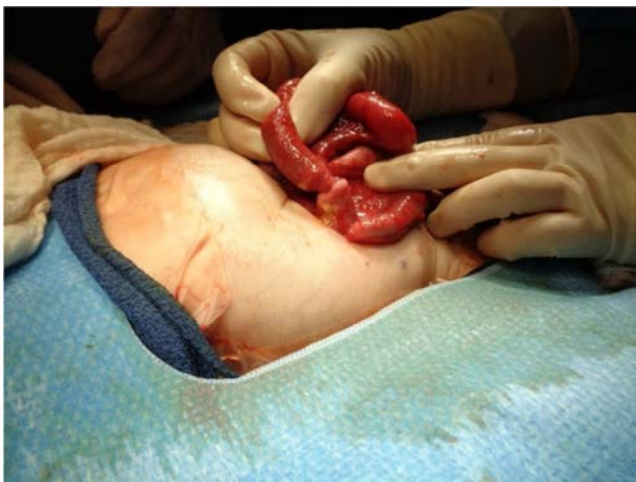

Figure 2. Post-contrast imaging of the brain revealing three enhancing lesions in the cerebellum of the patient.



**Figure 3.** Multiple myofibromatosis lesions in the small bowel seen during laparotomy.



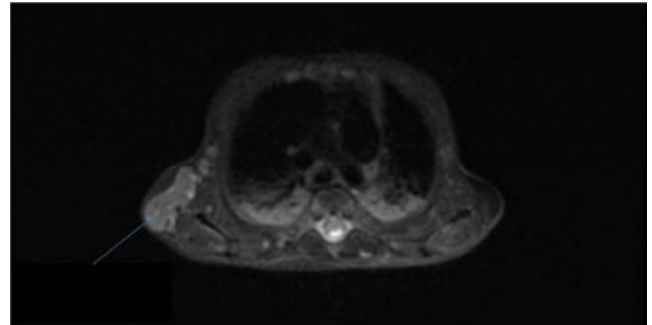
**Figure 4.** Intussusception caused by one of the lesions seen during laparotomy.

Histological analysis of a jejunal nodule biopsy showed a highly cellular lesion. At the periphery of this lesion, numerous blood filled vascular channels were found, some of which had a slight staghorn appearance. Adjacent to these areas, spindle cells were observed. The lesion extended into the mucosal surface in some areas and infiltrated through the muscularis propria into the serosal soft tissue. Immunohistochemical analysis of this tissue was positive for vimentin, smooth muscle actin, and CD34 but negative for Muscle-Specific Actin (MSA), desmin, factor VIII, epithelial membrane antigen (EMA), Erythroblast transformation specific related gene (ERG), caldesmon, SOX 10, and CD99. Also, electron microscopic analysis detected the presence of subcellular myofibroblastic structures. The growth pattern and absence of ERG and factor VIII excluded endothelial neoplasm such as hemangioendothelioma or lymphangiomatosis. Multifocality of the nodules with thrombocytopenia was compatible with a diagnosis of myofibromatosis with visceral involvement.

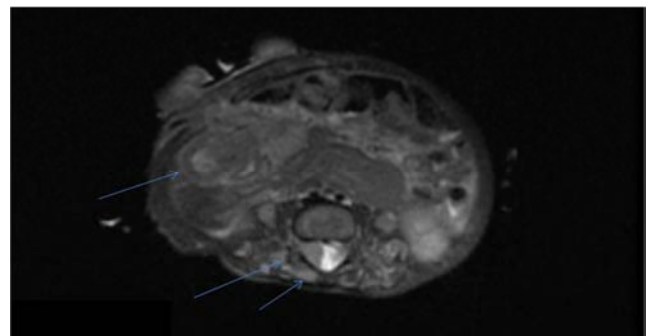
Next generation sequencing analysis of the patient's blood and tumor tissues identified a germline mutation in the platelet derived growth factor receptor Beta (*PDGFRB*) p.

R561C allele (c.1681C>T), as well as a second activating *PDGFRB* mutation (p. N666S) which was present in the tumor tissue only. Parental testing showed that the germline mutation was inherited from the father, who was asymptomatic. Given the known association between mutations in *PDGFRB* and IM, this finding, in addition to the skin and jejunal biopsy results, confirmed the diagnosis of myofibromatosis.

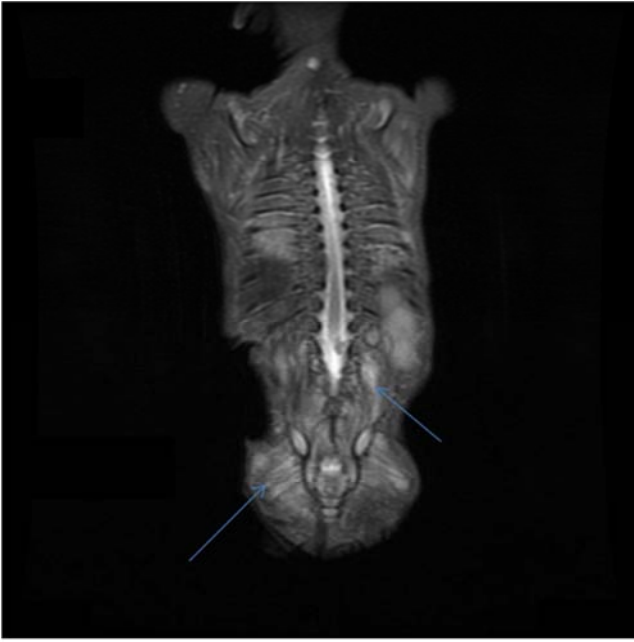
Therapy involved weekly vinblastine and methotrexate treatments. Methotrexate was held briefly due to increasing direct bilirubin. Due to neutropenia the patient was started on *Pneumocystis jirovecii* (previously known as *carinii*) pneumonia (PCP) prophylaxis, and granulocyte colony stimulating factor was given. The patient's initial two blood cultures were positive for *Candida albicans*, and he therefore underwent a 3-week course of fluconazole. He continued to exhibit elevated C-reactive protein, with negative blood cultures. Whole body MRI showed additional lesions in the muscles, bone, and lung parenchyma (Figures 5-8). He was started on triple antibiotics due to intestinal perforation but developed short bowel syndrome and failure to thrive. He was discharged home on parenteral nutrition via a central line and small amounts of feeds by mouth. Two weeks after discharge, the patient developed respiratory distress and decompensated. After resuscitation, he was admitted to the pediatric ICU; however, his cardiorespiratory status declined rapidly and support was withdrawn, per parental request.



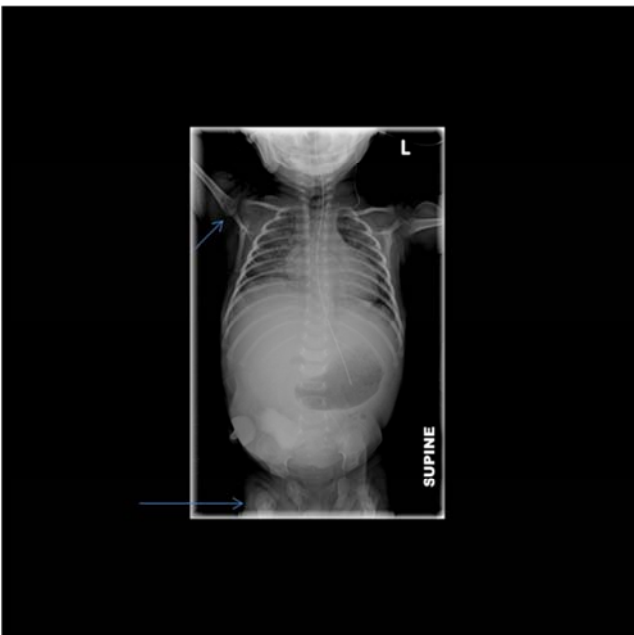
**Figure 5.** MRI imaging showing one large lesion in the soft tissues and muscles adjacent to the right scapula.



**Figure 6.** MRI imaging following ileostomy revealing a residual complex lesion of the bowel in the right lower quadrant of the abdomen. Additionally, there are paraspinous muscular lesions and one lesion in the right neuroforamina in the right lower lumbar area.



**Figure 7.** MRI imaging depicting diffuse paraspinous muscular lesions in the lumbar area.



**Figure 8.** Plain radiograph films with lesions of both proximal humeri and both proximal femurs.

### 3. Discussion

While myofibromatosis is a rare tumor of infancy, it is the most common fibrous tumor among this age group, [5] and is more common in males than females. [5, 6] There is currently no data available regarding incidences of neonatal presentation.

The etiology of IM is not always known. Autosomal dominant and recessive forms have been described, as well as chromosome 6q deletion. [8, 9] Mutations in the *PDGFRB* gene, located on chromosome 5q31-5q320, have been

identified as a cause of the familial autosomal dominant form of IM. *PDGFRB* promotes growth of mesenchymal cells, including blood vessels and smooth muscles. Meanwhile, a mutation in *NOTCH3*, located on chromosome 19p13.12, was suspected in one case, suggesting genetic heterogeneity.<sup>5</sup> Long arm and interstitial deletion of chromosome 6 (q12q15) and translocation between chromosome 9 and 16 also confirmed the genetic heterogeneity of IM. [10, 11]

Typical microscopic observations for IM include central hemangiopericytoma-like vascular proliferation surrounded by fascicles of spindle shaped cells with myofibroblastic features. Positive staining for vimentin and negative staining for desmin and S100 protein support myofibroblastic differentiation typical of infantile myofibromatosis. [1, 12]

Three clinical forms of IM have been described: solitary single lesions, multiple cutaneous nodules, and generalized IM with visceral involvement. [3, 8] In particular, visceral lesions are associated with poor prognoses due to the effects of the tumors on vital organs. Presentation with multiple bony lesions, which later underwent sarcomatous change, in neonates has also been reported. [13] Cutaneous lesions can present as bluish to purplish macules, while subcutaneous lesions are mobile, non-tender, and may be fixed. Sepsis, failure to thrive, and other systemic complications lead to high morbidity and mortality. In our patient, repeated intussusception was a major issue leading to short bowel syndrome and severe failure to thrive.

In 89% of cases, IM manifests prior to 2 years of age. Solitary or generalized myofibromas without visceral involvement usually regress within a few months. [3, 14] Mashiah *et al.* (2014) reported that the solitary form accounts for 50% of cases, while the multicentric and generalized forms comprise 39% and 11% of cases, respectively. Moreover, they reported that the generalized form is associated with a mortality rate of 33%.<sup>5</sup> Conversely, prognosis is excellent for the most common superficial and multicentric lesions, with some case reports showing positive response to surgical excision and even spontaneous regression.

Prognosis of IM with visceral involvement is poor due to the aggressiveness of this disease.<sup>13</sup> In such cases, cardiopulmonary and GI complications result in morbidity and mortality rates of approximately 75%.<sup>5</sup> The recurrence rates for solitary and multicentric lesions is roughly 10%.<sup>4</sup> Chemotherapy has a poor effect on benign tumors with low mitotic activities, and carries significant adverse effects; [15] however, low intensity chemotherapy with vincristin-actinomycin D, vinblastine-methotrexate, interferon-alfa, and tamoxifen has been reported to be effective in a few cases.<sup>16-18</sup>

The germline pathogenic missense mutation identified in our patient in *PDGFRB* (p. R561C, c.1681C>T) is located in the juxtamembrane domain. *PDGFRB* encodes a receptor tyrosine kinase expressed by mesenchyme-derived cells including fibroblasts and smooth muscle. The p. R561C variant is predicted to decrease autoinhibition of the juxtamembrane domain. [7, 19, 20] This mutation has been isolated in multiple families with familial IM and has variable

expression and reduced penetrance. [12] In our patient, the mutation was inherited from an asymptomatic father. However, the tumor tissues of our patient harbored a second pathogenic mutation in *PDGFRB*, p. N666S, leading to activation of kinase activity. We therefore speculate that this second mutation was responsible for the aggressive nature of our patient's IM, which led to multiple morbidities and eventually his death.

## 4. Conclusions

For neonates or infants who present with multiple myofibromas, consider testing for *PDGFRB* mutations. Solitary soft tissue lesions can regress spontaneously. Aggressive visceral lesions require chemotherapy and are associated with poor prognoses. Because this lesion can involve visceral organs, for patients presenting with solitary or multiple tumors a careful and complete evaluation is necessary.

## Acknowledgements

No financial assistance was received for the completion of this study.

## References

- [1] Weiss SW, Goldblum JR. Myofibroma and myofibromatosis. In: Weiss SW, Goldblum JR, eds. *Enzinger and Weiss's Soft Tissue Tumors*, fourth edition. St Louis: Mosby; 2001: 357–363.
- [2] Rubin BP, Bridge JA. Myofibroma/myofibromatosis. In: Fletcher CDM, Unni KK, Mertens F, eds. *World Health Organization Classification of Tumors: Pathology and Genetics of Tumors of Soft Tissue and Bone*, third edition. Lyon: IARC press; 2002: 59–61.
- [3] Chung EB, Enzinger FM. Infantile myofibromatosis. *Cancer* 1981; 48: 1807–1818.
- [4] Wiswell TE, Davis J, Cunningham BE, Solenberger R, Thomas PJ. Infantile myofibromatosis: the most common fibrous tumor of infancy. *J Pediatr Surg* 1988; 23: 315–318.
- [5] Mashiah J, Hadj-Rabia S, Domomartin A, *et al.* Infantile myofibromatosis: a series of 28 cases. *J Am Acad Dermatol* 2014; 71: 264–270.
- [6] Mynatt CJ, Feldman KA, Thompson LD. Orbital infantile myofibroma: a case report and clinicopathologic review of 24 cases from the literature. *Head Neck Pathol* 2011; 5: 205–215.
- [7] Arts FA, Sciot R, Brichard B, *et al.* *PDGFRB* gain-of-function mutations in sporadic infantile myofibromatosis. *Hum Mol Genet* 2017; 26: 1801–1810.
- [8] Zand DJ, Huff D, Everman D, *et al.* Autosomal dominant inheritance of infantile myofibromatosis. *Am J Med Genet A* 2004; 126A: 261–266.
- [9] Kulkarni K, Desai S, Grundy P, Sergi C. Infantile myofibromatosis: report on a family with autosomal dominant inheritance and variable penetrance. *J Pediatr Surg* 2012; 47: 2312–2315.
- [10] Sirvent N, Perrin C, Lacour JP, Maire G, Attias R, Pedeutour F. Monosomy 9q and trisomy 16q in a case of congenital solitary infantile myofibromatosis. *Virchows Arch* 2004; 445: 537–540.
- [11] Stenman G, Nadal N, Persson S, Guntenberg B, Angervall L. del (6)(q12q15) as the sole cytogenetic anomaly in a case of solitary infantile myofibromatosis. *Oncol Rep* 1999; 6: 1101–1104.
- [12] Ikediobi NI, Iyengar V, Hwang L, Collins WE, Metry DW. Infantile myofibromatosis: support for autosomal dominant inheritance. *J Am Acad Derm* 2003; 49: S148–S150.
- [13] Hazarey J, Hazare S, Moghe G. Unusually aggressive myofibromatosis in a neonate. *J Neonat Surg* 2012; 1: 35.
- [14] Kikuchi K, Abe R, Shinkuma S, *et al.* Spontaneous remission of solitary-type infantile myofibromatosis. *Case Rep Dermatol* 2011; 3: 181–185.
- [15] Wallace, W. H., *et al.* (2001). "Developing strategies for long term follow up of survivors of childhood cancer." *BMJ* 323 (7307): 271–274.
- [16] Auriti C, Kieran MW, Deb G, Devito R, Pasquini L, Danhaive O. Remission of infantile generalized myofibromatosis after interferon alpha therapy. *J Pediatr Hematol Oncol* 2008; 30: 179–181.
- [17] Gandhi MM, Nathan PC, Weitzman S, Levitt GA. Successful treatment of life-threatening generalized infantile myofibromatosis using low-dose chemotherapy. *J Pediatr Hematol Oncol* 2003; 25: 750–754.
- [18] Levine E, Fréneaux P, Schleiermacher, *et al.* Risk- adapted therapy for infantile myofibromatosis in children. *Pediatr Blood Cancer* 2012; 59: 115–120.
- [19] Cheung YH, Gayden T, Campeau PM, LeDuc CA Russo D, Nguyen VH, *et al.* A recurrent *PDGFRB* mutation causes familial infantile myofibromatosis. *Am J Hum Genet* 2013; 92: 996–1000.
- [20] Martignetti JA, Tian L, Li D, *et al.* Mutations in *PDGFRB* cause autosomal-dominant infantile myofibromatosis. *Am J Hum Genet* 2013; 92: 1001–1007.