
Suture anchors in orthopaedics—uses other than shoulder surgery

Ashish Anand*, Raviraj A, Manish Kumar, Rajendran Ravindran

Fortis Hospitals, Bangalore, India

Email address:

Ashishanandortho@yahoo.com(A. Anand)

To cite this article:

Ashish Anand, Raviraj A, Manish Kumar, Rajendran Ravindran. Suture Anchors in Orthopaedics—Uses other than Shoulder Surgery. *Advances in Surgical Sciences*. Vol. 1, No. 1, 2013, pp. 1-5. doi: 10.11648/j.ass.20130101.11

Abstract: The various types of suture anchors have become widely accepted in the orthopaedic shoulder surgery. The common uses being for Bankarts repair and rotator cuff repair. The use of suture anchors in orthopaedic surgery for indications other than shoulder surgery is sparsely reported in the literature. We report on our observations from a single centre following use of anchors outside the shoulder joint. We have successfully used the suture anchors for repair of the lateral collateral ligament, the insertional tear of the Tendo-Achilles, fractures of the lower pole of the patella, triceps insertional tear, for repair of quadriceps tendon following partial avulsion. This highlights the importance of this tiny device in the armamentarium of a sports medicine surgeon.

Keywords: Suture Anchors, Shoulder Surgery, Fracture, Muscle Tear, Tendo-Achilles Tear, Lateral Collateral Ligament, Bio-transfix, Bio-absorbable, Failure, Breakage

1. Introduction

Suture anchors are used commonly in Sports medicine surgeries for repair of ligaments and tendons. Suture Anchors act by attaching the soft tissue to an implant embedded in bone.

The first designed anchors were made of metal. The 2 commonest form of metallic anchors include stainless steel and titanium. Metal Anchors have the advantage that they can be used in Osteopenic bone and afford a rigid fixation but they have numerous disadvantages such as making post operative imaging like MRI and CT difficult because of scattering. Revision surgery is problematic because these might have to be removed before new anchors can be put in. Also they cause laceration of soft tissue grafts. The first reported use of polymer based implants was in 1960 in the form of resorbable suture called Dexon. Since then there used has increased tremendously. Depending on the order of packing of the underlying substance, structure might be semi-crystalline or amorphous, with semi crystalline having a superior tensile strength. Polymers are further classified as Bioabsorbable(eg polylactic acid), biostable (eg PEEK-polyetheretherketone) and biocomposite (eg PEEK-ceramic) implants.

Bioabsorbable implants do not have the disadvantages of metallic anchors which are mentioned above but there have

been reports of foreign body reactions(4-6), synovitis(6), osteolysis(6,7), intraosseous cyst formations(8,9-11), loose foreign bodies(12-15), local(16) and systemic inflammatory response(17). Biostable components have the same advantages (18-21) of polymers but do not cause the high incidence of side effects(22).

However the biggest disadvantage is poor osteointegration(22) which is attributed to its inertness and hydrophobicity(21,23-24). Biocomposite implants consist of two materials a bioactive ceramic and bioabsorbable polymer. Bioactive ceramics help in bone formation (25-28) and includes calcium carbonate, BetatricalciumPhosphate, Biphasic Calcium Phosphate and Hydroxyapatite. Thus a combination of macroporous architecture on a degradable polymer is created which enables bone formation. The underlying polymer is responsible for the same advantages as the bioabsorbable implants (29, 30).

We present our experience with different kind of anchors in different situations.

2. Methods

This was an IRB approved study and a total of eight patients who underwent repair of varying conditions using bone anchors were reviewed. Patients were contacted over

phone and were asked to come in for a physical examination. All the patients had a minimum follow up of 2 years. Patients were questioned for any symptoms such as loss of motion, weakness, instability.

Manual assessment of strength was done by a physical therapist. Patients who underwent a shoulder repair with anchors were excluded. Any patient with less than 2 years follow up was also excluded.

2.1. Repair of the Lateral Collateral Ligament

Two patients who had injury to the lateral collateral ligament of the knee, underwent repair of the lateral collateral ligament (one case), and repair and reconstruction using biceps femoris tendon (one case). Both the cases had bony avulsion of the lateral collateral ligament from the fibular head. Through the lateral approach to the knee, the torn collateral ligament was identified and a fibre was whip stitched through the torn end. A

Twin Fast 3.5 mm Ti (Smith and Nephew) was used to fix the free ends of the fibre wire into the lateral epicondyle of femur under adequate tension (fig 1). In the second case the lateral collateral ligament was repaired in the above mentioned fashion and it was reinforced by taking a portion of the biceps femoris with its distal attachment left intact. Patients were placed in a hinged knee for 4 weeks followed by gradual mobilization. Patients had complete recovery of range of motion and strength at 12 weeks post surgery. Patients were subsequently see at 6 months and then again at 2 years post surgery.

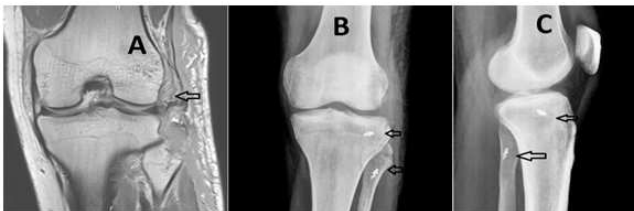

Fig 1. Traumatic avulsion of the lateral collateral ligament and capsule (A) of the knee as indicated by the arrow. The anteroposterior (B) and the lateral radiograph (C) of the knee showing the repair of the collateral ligament and reattachment of the cap.

2.2. Insertional Tear of the Tendoachilles

The insertional tear of tendoachilles was repaired in two patients using the anchors. A posteromedial approach was used in both the cases. As the tear had left no portion of the tendon on calcaneum, a Twin Fast 3.5 mm Ti (Smith and Nephew) anchor was buried in the calcaneum and the sutures were passed in the proximal tendoachilles in a locking loop configuration (Fig 2). The patients were kept on an above knee cast with ankle in equines for the first 4 weeks, followed by below knee neutral cast for four weeks. Patients were kept non weight bearing this eight weeks post operative period. Subsequently cast was removed and patients were put in supervised physical therapy. At 20 weeks post surgery both the patients had full range of

motion and strength comparable to the contra-lateral side. The tendoachilles healed in both the patients and at six months and subsequent 2 years follow up follow up both the patients had comparable push off in both their feet and were able to stand on their toes.

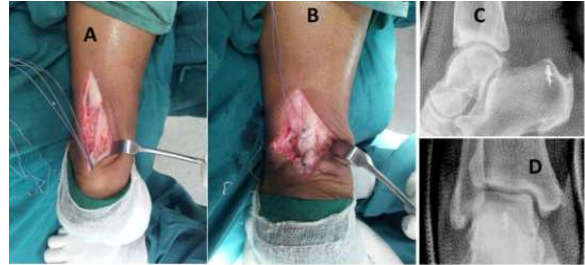


Fig 2. The insertional rupture of the tendoachillis (A) and the repair of the tendoachillis using an anchor (B). The lateral (C), anteroposterior (D) radiograph showing the anchor in situ.

2.3. Comminuted Fractures of the Lower Pole of the Patella

Two patients underwent excision of the comminuted inferior pole followed by repair of the extensor mechanism using Fast Fix Anchors (Smith-Nephew)-3.5mm titanium anchors (Fig 3).

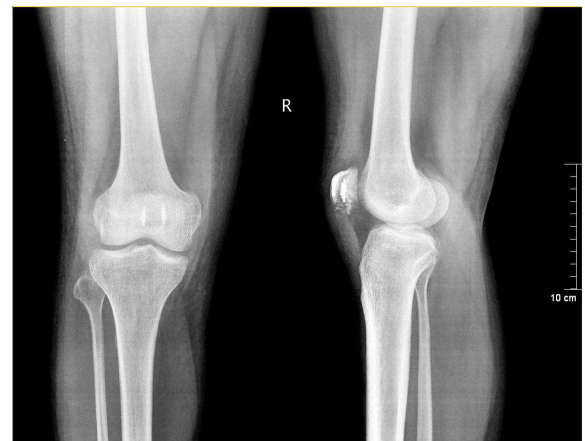

Fig 3. AP and lateral radiographs depicting the repair of patella to the patellar ligament with anchors

Patients also underwent a repair of the extensor retinaculum and were immobilized for 4 weeks followed by gradual mobilization. Patients had completely recovered there range of motion at 8 weeks post surgery. Quadriceps strength was comparable to contralateral side at 6 months and 2 years post surgery.

2.4. Triceps Insertional Tear

Patient presented to our office with sudden loss of elbow extension following lifting of a heavy weight. Examination revealed a palpable gap in the triceps insertion which was confirmed on MRI. The insertional tear was repaired by placing the 3.5 mm Titanium anchors (Fast Fix-Smith and Nephew) in the olecranon (fig 4) region. The free suture

limbs were then passed in the triceps tendon in a locking loop stitch configuration.

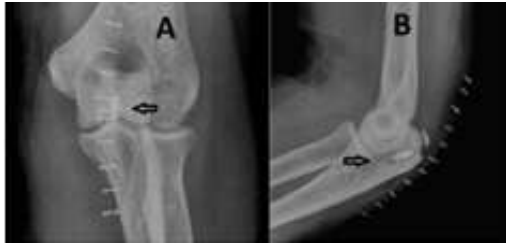

Fig 4. The post operative anteroposterior (A) and the lateral radiograph (B) of the elbow of the patient who underwent repair of the bony avulsion of the triceps. The triceps was repaired using the anchors (arrow head).

The placement of the anchor in the bone gives a good anchorage and makes the repair stronger. The operated limb was kept in an arm pouch for about three weeks and gentle mobilization of the elbow started. The patient achieved full range of motion and strength of the triceps at eight weeks and returned to his pre injury activity status. A 6 month follow up revealed a clinically stable elbow with maintained full range of motion and normal strength. This was maintained at 2 years follow up.

2.5. Repair of Medial Sleeve at Time of Revision Total Knee Replacement (TKR)

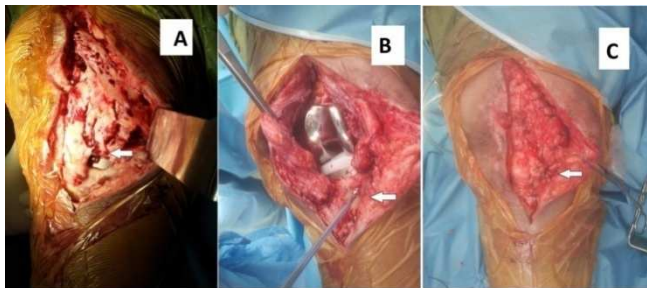


Fig 5. The intraoperative image of revision total knee replacement with loss of tissue at the medial arthrotomy (A) (shown by arrow head). The use of suture anchor (B) at the medial sleeve (arrow head) for the closure of the wound(C).

A 65 year old lady with history of infected TKR underwent a two stage reimplantation. At the time of reimplantation there was found to be deficient medial tissue sleeve at the level of proximal tibia which was not approximating to the corresponding edge laterally. To enable the closure Twin fix Ti 5.5 (Smith and Nephew) was inserted into the proximal tibia (fig 5) in the middle of the gap and the free ends of the suture limbs were then passed through the medial and lateral tissue sleeve to enable closure. Immediate mobilization was started in a CPM machine. Patient regained movement from 0 to 115 degree by 6 weeks. Knee was clinically stable at 3 month, 6 month and 2 years follow up.

2.6. After the Excision of a Symptomatic Bipartite Patella

A twenty five year old lady, had knee pain for the last six months and, was diagnosed to have a symptomatic bipartite

patella. The axial views showed the bipartite portion of the patella was rubbing the lateral femoral condyle, which was confirmed under arthroscopy.

She underwent arthroscopic excision of the symptomatic bipartite patella followed by open repair of the quadriceps. The arthroscopic removal of patella resulted in a deficiency of the attachment of quadriceps which was addressed by open means. The 3.5mm anchor was placed laterally (fig 6) in the upper portion of patella and the quadriceps was repaired with the help of free suture limbs. Patient was immobilized for 2 weeks followed by gradual mobilization. Patient had complete recovery of her range and strength by 8 weeks post surgery. This was maintained at 6 months and 2 years post surgery.

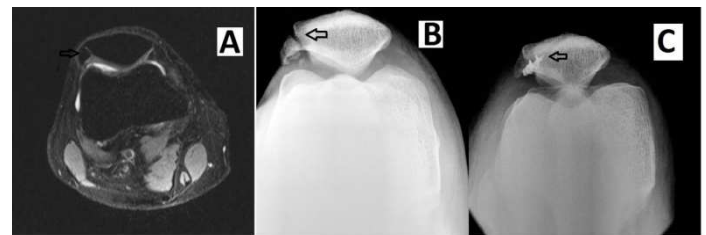

Fig 6. MRI image (A) and the axial radiograph of the knee (B) showing a symptomatic bipartite patella (arrow). The post operative axial radiograph of the knee (C), after the excision of the symptomatic bipartite patella and reattachment of the quadriceps.

3. Results

All patients were seen at 2 weeks post surgery for skin suture removal. They were again seen at 4 weeks, 8 weeks, 12 weeks and 6 months post surgery. They were called at a final follow up at 2 years post surgery. None of the patients had any loss of motion or strength at the final follow up of 2 years. There were no intra-operative/ post operative complications. Based on patients subjective feel as well as objective examination all eight patients had returned to their pre injury status.

4. Discussion

A total of 8 patients who had undergone repair at various anatomical sites using suture anchors were reviewed. All the patients had completely recovered their range of motion to pre-injury levels. None of the patients had any loss of strength. At the latest follow up of two years no complications had been reported and none of the patients had undergone a revision surgery. The senior author (AA) had previously reported (31) these observations on role of suture anchors in management of comminuted inferior pole fractures. This is a further extension of the use of suture anchors reported by the same group.

Initial anchors were made of metal but the current trend is towards bioabsorbable materials because of their better biocompatibility, less interference with postoperative imaging, no need for subsequent removal. The search for ideal material-one which provides sound mechanical

fixation, completely degrades inside the body and is replaced by bone, is still on. It is hoped that bio-composites will be the gold standard. Research studies are indicated to see if anchors can be used in cases where there is a gap with tendon loss supplemented with V-Y plasty.

Although a total of 8 patients is too small to judge the utility of any implant, one can see that suture anchor is a important tool in the armamentarium of a sports medicine surgeon and its indications are bound to increase. With the constant improvement in biomaterials one can expect the incidence of side effects to go down considerably.

References

- [1] Schroeder JA, Brown MK. Biocompatibility and degradation of collagen bone anchors in a rabbit model. *J Biomed Mater Res* 1999; 48: 309-314.
- [2] Zantop T, Weimann A, Schmidtke R, Herbolt M, Raschke MJ, Petersen W. Graft laceration and pullout strength of soft-tissue anterior cruciate ligament reconstruction: In vitro study comparing titanium, poly-d,l-lactide, and poly-d,l-lactide-tricalcium phosphate screws. *Arthroscopy* 2006; 22: 1204-1210.
- [3] Driscoll P. Biopolymers in orthopaedics. *Advanced Medical Technologies*. Available from: <http://mediligence.com/blog/2009/03/27/biopolymers-orthopedics>.
- [4] Bostman O, Hirvensalo E, Makinen J, Rokkanen P. Foreignbody reactions to fracture fixation implants of biodegradable synthetic polymers. *J Bone Joint Surg Br* 1990; 72: 592-596.
- [5] Rokkanen PU, Bostman O, Hirvensalo E, et al. Bioabsorbable fixation in orthopaedic surgery and traumatology. *Biomaterials* 2000; 21: 2607-2613.
- [6] Weiler A, Helling HJ, Kirch U, Zirbes TK, Rehm KE. Foreignbody reaction and the course of osteolysis after polyglycolide implants for fracture fixation: Experimental study in sheep. *J Bone Joint Surg Br* 1996; 78: 369-376.
- [7] Friden T, Rydholm U. Severe aseptic synovitis of the knee after biodegradable internal fixation. A case report. *Acta Orthop Scand* 1992; 63: 94-97.
- [8] Ma CB, Francis K, Towers J, Irrgang J, Fu FH, Harner CH. Hamstring anterior cruciate ligament reconstruction: A comparison of bioabsorbable interference screw and endobuttonpost fixation. *Arthroscopy* 2004; 20: 122-128.
- [9] Busfield BT, Anderson LJ. Sterile pretibial abscess after anterior cruciate reconstruction from bioabsorbable interference screws: A report of 2 cases. *Arthroscopy* 2007; 23: 911.
- [10] Martinek V, Friederich NF. Tibial and pretibial cyst formation after anterior cruciate ligament reconstruction with bioabsorbable interference screw fixation. *Arthroscopy* 1999; 15: 317-320.
- [11] Warden WH, Chooljian D, Jackson DW. Ten-year magnetic resonance imaging follow-up of bioabsorbable poly-L-lactic acid interference screws after anterior cruciate ligament reconstruction. *Arthroscopy* 2008; 24: 370.
- [12] Baums MH, Zelle BA, Schultz W, Ernstberger T, Klinger HM. Intraarticular migration of a broken biodegradable interference screw after anterior cruciate ligament reconstruction. *Knee Surg Sports Traumatol Arthrosc* 2006; 14: 865-868.
- [13] Bottoni CR, Deberardino TM, Fester EW, Mitchell D, Penrod BJ. An intra-articular bioabsorbable interference screw mimicking an acute meniscal tear 8 months after an anterior cruciate ligament reconstruction. *Arthroscopy* 2000; 16: 395-398.
- [14] Cossey AJ, Paterson RS. Loose intra-articular body following anterior cruciate ligament reconstruction. *Arthroscopy* 2005; 21:348-350.
- [15] Werner A, Wild A, Ilg A, Krauspe R. Secondary intra-articular dislocation of a broken bioabsorbable interference screw after anterior cruciate ligament reconstruction. *Knee Surg Sports Traumatol Arthrosc* 2002; 10: 30-32.
- [16] Kwak JH, Sim JA, Kim SH, Lee KC, Lee BK. Delayed intra-articular inflammatory reaction due to poly-L-lactide bioabsorbable interference screw used in anterior cruciate ligament reconstruction. *Arthroscopy* 2008; 24: 243-246.
- [17] Mastrokalos DS, Paessler HH. Allergic reaction to biodegradable interference poly-L-lactic acid screws after anterior cruciate ligament reconstruction with bone-patellar tendon-bone graft. *Arthroscopy* 2008; 24: 732-733.
- [18] Brantigan JW, McAfee PC, Cunningham BW, Wang H, Orbegoso CM. Interbody lumbar fusion using a carbon fiber cage implant versus allograft bone. An investigational study in the Spanish goat. *Spine (Phila Pa 1976)* 1994; 19: 1436-1444.
- [19] Brantigan JW, Steffee AD. A carbon fiber implant to aid interbody lumbar fusion. Two-year clinical results in the first 26 patients. *Spine (Phila Pa 1976)* 1993; 18: 2106-2107.
- [20] Brantigan JW, Steffee AD, Lewis ML, Quinn LM, Persenaire JM. Lumbar interbody fusion using the Brantigan I/F cage for posterior lumbar interbody fusion and the variable pedicle screw placement system: Two-year results from a Food and Drug Administration investigational device exemption clinical trial. *Spine (Phila Pa 1976)* 2000; 25: 1437-1446.
- [21] Kurtz SM, Devine JN. PEEK biomaterials in trauma, orthopedic, and spinal implants. *Biomaterials* 2007; 28: 4845-4869.
- [22] Toth JM, Wang M, Estes BT, Scifert JL, Seim HB III, Turner AS. Polyetheretherketone as a biomaterial for spinal applications. *Biomaterials* 2006; 27: 324-334.
- [23] Briem D, Strametz S, Schroder K, et al. Response of primary fibroblasts and osteoblasts to plasma treated polyetheretherketone (PEEK) surfaces. *J Mater Sci Mater Med* 2005; 16: 671-677.
- [24] Noiset O, Schneider YJ, Marchand-Brynaert J. Fibronectin adsorption or/and covalent grafting on chemically modified PEEK film surfaces. *J Biomater Sci Polym Ed* 1999; 10: 657-677.
- [25] Ambard AJ, Mueninghoff L. Calcium phosphate cement: Review of mechanical and biological properties. *J Prosthodont* 2006; 15: 321-328.

- [26] Ignjatovic N, Ajdukovic Z, Uskokovic D. New biocomposite [biphasic calcium phosphate/poly-DL-lactide-co-glycolide/biostimulative agent] filler for reconstruction of bone tissue changed by osteoporosis. *J Mater Sci Mater Med* 2005; 16: 621-626.
- [27] Ruhe PQ, Hedberg EL, Padron NT, Spauwen PH, Jansen JA, Mikos AG. Biocompatibility and degradation of poly(DLlactico-glycolic acid)/calcium phosphate cement composites. *J Biomed Mater Res A* 2005; 74: 533-544.
- [28] Kokubo T, Kim HM, Kawashita M. Novel bioactive materials with different mechanical properties. *Biomaterials* 2003; 24: 2161-2175.
- [29] Ozbaydar M, Elhassan B, Warner JJ. The use of anchors in shoulder surgery: A shift from metallic to bioabsorbable anchors. *Arthroscopy* 2007; 23: 1124-1126.
- [30] Macarini L, Milillo P, Mocci A, Vinci R, Ettorre GC. Poly-L-lactic acid– hydroxyapatite (PLLA-HA) bioabsorbable interference screws for tibial graft fixation in anterior cruciate ligament (ACL) reconstruction surgery: MR evaluation of osteointegration and degradation features. *Radiol Med* 2008; 113: 1185-1197.
- [31] Anand A, Kumar M, Kodikal G. Role of suture anchors in management of fractures of inferior pole of patella. *Indian J Orthop.* 2010 Jul; 44(3): 333-5.