
The morphometric values of the native duck and geese' heads: A computed tomography study

Mustafa Orhun Dayan^{1,*}, Yasin Demiraslan², Yalcin Akbulut³, Mahmut Duymus⁴,
Murat Sirri Akosman⁵

¹Department of Anatomy, Faculty of Veterinary Medicine, University of Selcuk, Konya, TURKEY

²Department of Anatomy, Faculty of Veterinary Medicine, University of Mehmet Akif Ersoy, Burdur, TURKEY

³Collage of Health, University of Kafkas, Kars, TURKEY

⁴Department of Radiology, Faculty of Medicine, University of Kafkas, Kars, TURKEY

⁵Department of Anatomy, Faculty of Veterinary Medicine, University of Afyon Kocatepe, Afyonkarahisar, TURKEY

Email address:

modayan@selcuk.edu.tr (M. O. Dayan), yasindemiraslan@hotmail.com (Y. Demiraslan), yalcinakbulut@kafkas.edu.tr (Y. Akbulut), mahmutduymush@yahoo.com (M. Duymus), akosmans@aku.edu.tr (M. S. Akosman)

To cite this article:

Mustafa Orhun Dayan, Yasin Demiraslan, Yalcin Akbulut, Mahmut Duymus, Murat Sirri Akosman. The Morphometric Values of the Native Duck and Geese' Heads: A Computed Tomography Study. *Animal and Veterinary Sciences*. Vol. 2, No. 6, 2014, pp. 175-178. doi: 10.11648/j.avs.20140206.13

Abstract: Computed tomography (CT) is used for anthropomorphometrical studies for creating macroscopic and microscopic models and revealing the phenotypic differences quickly in small animals. This study aimed to determine the morphometric differences of the head native duck and goose, and to presented measurements (length and volume) of their heads, using CT images. For this purpose, the heads of ten male geese and ducks were used. Moreover, nine different anatomic structures were measured on the CT images, and six indexes were calculated. Consequently, each parameter of duck and goose heads showed significant difference between each other, except head volume and greatest high ($p < 0.05$ or 0.01). Besides, it was settled that the calculated indexes had statistically differences among the native goose and ducks' head ($p < 0.05$ or 0.01). According to this result, it was concluded that the morphometric CT measurements would be used to difference of the native goose and ducks' head.

Keywords: Computed Tomography, Duck, Goose, Head, Morphometry

1. Introduction

In various regions of our country, native duck (*Anas platyrhynchos*) and goose (*Anser anser*) are raised to gain money from their meat, eggs and feathers by the farmers and larger businesses [1-4]. According to the Turkish Statistical Institute, in our country, there are 676.179 geese and 356.730 ducks, different race for 2012 year [5].

The morphometry is a method which description and statistical analyses of shape variation in among samples of organisms. The topics of the morphometry have a wide scale including geographic localities, developmental stages, genetic and environmental effects [6].

Computed tomography (CT) is used for anthropomorphometrical studies for creating macroscopic and microscopic models, and revealing the phenotypic differences quickly in small animals [7-11]. The comprehensive imaging

of structures that make up the skull and the minimum degree of overlapping images obtains excessive benefit to the CT when compared to other imaging methods. Moreover, CT may be applicate in the short-term, and it is accepted as an advantage. High quality images are obtained from cross-sections of head when CT is used, and hence anatomical or pathological data could be assessed [12-17].

In the literature review, it was seen that a few studies evaluated the head of the poultry using CT [18]. This study was aimed to determine the morphometric differences of the head native duck and goose, and to presented measurements (length and volume) of their heads, using CT images.

2. Materials and Methods

We used ten male geese and ducks' heads for this study. Geese and ducks were supplied from Avian Unit in the

Education, Research and Application Farm of Kafkas University. Animals were 66-68 weeks, average 2 – 2.35 kg (goose: 2.2±0.2 kg, duck: 2.1±0.15 kg) live weight and they were grown under the same live conditions (light intensity, feeding, water etc.). Animals were slaughtered and their heads were referred to the Research and Application Hospital Radiology Unit of Kafkas University to obtain CT images. All the heads were undergone to the CT (Aquilion 64®, Toshiba Medical Systems, 2011, Zoetermeer, Netherlands) device.

Nine different anatomic structures were measured on the CT images. These structures were head volume (HV), calvarial bone volume (CV), brain volume (BV), cranium greatest length (Fig 1 and 2. CGL between the protuberentia occipitalis externa to the apex premaxillaris), greatest height in the median plane (Fig 1. GH- from the basitemporale in the median plane to the highest and median point of the braincase), greatest breadth (Fig 2. GB- across the processus postfrontales), smallest breadth between the orbits on the dorsal side (Fig 2. SBO), mandible greatest length (Fig 1. MGL-apex to the most aboral point of the mandible) and length from the most aboral point of the facies articularis (Fig 1. LaF). The study was taken as reference [19] Duymuş *et al.* (2013) for volume parameters and [20] Driecsh (1976) for length parameters. Millimeter (mm) was used for length unit, mm³ was used for volumetric parameters. Aquarius iNtuition Edition ver. 4. 4. 6. software was used for measurements. Indexes were formed for the statistically importance parts of the obtained length measurements. These indexes were determined as GH/CGL, GB/CGL, SBO/CGL, MGL/CGL, LaF/CGL, Laf/MGL.

Bone landmarks were used to measure the lengths. To measure the mandible extents 8 mm MIP (maximum intensity projection) images and sagittal aspect were used.

Different tissues have different densities in CT. To calculate the CV 800-2000 Hounsfield unit (HU), HV from -250 to 2000 HU, BV from -100 to 500 HU ranges were set (20). Both 2D axial and coronal plane images were used to calculate all the volumes. In addition to 2D images, data were confirmed also on 3D volume rendered images. To calculate the BV region growing tool, CV and HV single click tool was used. Because BV is spread to area, but CBV and HV are not.

All the parameters were measured by seven-year experienced radiologist. In this study, Nomina Anatomica Avium [21] was referenced for terminology related to anatomy.

2.1. Statistical Analysis

Statistical analysis of the study was performed using Statistical Package for Social Sciences (SPSS) version 17.0 software package. Continuous variables were expressed as arithmetical mean ± standard deviation.

We used 1-Sample K test to see the distribution of the data, and all the data of goose and ducks were have normal distribution (p>0.05). And we used Mann-Whitney U test to compare the data. Moreover, the correlation of the values obtained from this study was analyzed (Pearson’s correlation test).

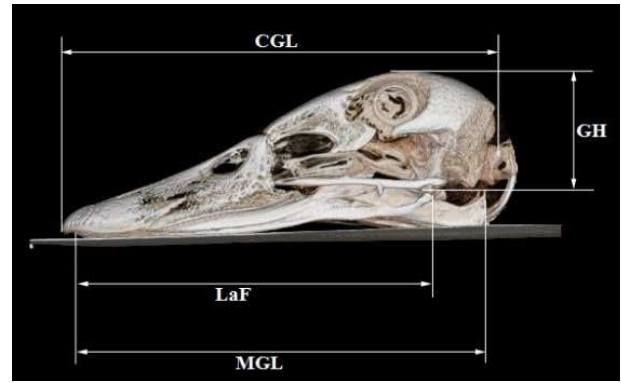


Figure 1. 3D lateral aspect image of length measurement of the goose head. CGL-Cranium Greatest Length, GH-Greatest Height, MGL- Mandible Greatest Length, LaF- Length from the most Aboral point of the Facies articularis.

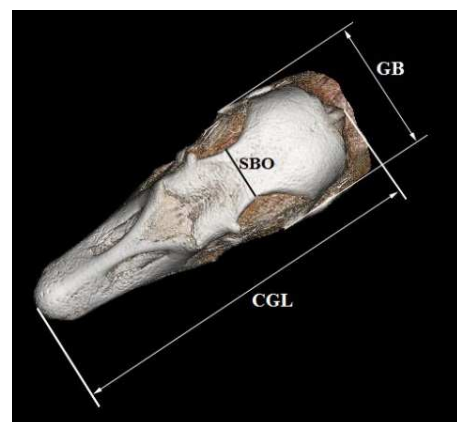


Figure 2. 3D dorso-ventral aspect image of length measurement of the goose head. CGL-Cranium Greatest Length, GB-Greatest Breadth, SBO- Smallest Breadth between the Orbits.

3. Results

Table 1. Shows the mean values of the data. HV: head volume, CV: calvarial bone volume, BV: brain volume, CGL-Cranium Greatest Length, GH-Greatest Height, GB-Greatest Breadth, SBO- Smallest Breadth between the Orbits, MGL- Mandible Greatest Length, LaF- Length from the most Aboral point of the Facies articularis. The unit of the mean values and the standard deviations are mm³. SD is standard deviation. * Means within a row are significantly different (P<0.05).

Parameters	Goose (Mean±SD)	Duck(Mean±SD)
HV	125.33±15.73	116.67±15.5
CV*	9.1±1.16	6.76±0.89
BV*	8.67±0.72	5.91±1.56
CGL*	115.83±5.46	129.67±5.71
GH	44.88±1.96	42.87±3.06
GB*	39.13±2.18	33.4±1.03
SBO*	15.2±1.77	12±1.03
MGL*	102.1±6.72	121.83±4.49
LaF*	88±7.17	105.67±3.93
GH/CGL*	0,39±0,03	0,33±0,02
GB/CGL*	0,34±0,02	0,26±0,01
SBO/CGL*	0,13±0,02	0,09±0,001
MGL/CGL*	0,88±0,03	0,94±0,02
Laf/CGL*	0,76±0,03	0,82±0,01
Laf/MGL	0,86±0,02	0,87±0,01

The findings of this study were shown at the *Table 1*. According to this, average values of the HV, CV and BV of the geese (n:10) were 125.33, 9.1 and 8.67 mm³, respectively. These values of the ducks were found as 116.67, 6.76 and 5.91 mm³, respectively. *Table 1* was indicated that each parameter of duck and goose heads showed significant difference between each other, except HV and GH (p<0.05). Besides, it was settled that the calculated indexes, except the Laf/MGL, were statistically different among the native goose and ducks' head (p<0.05 or 0.01).

The obtained correlation findings from this process were

Table 2. Shows the correlation values of the data. * Correlation is significant at the 0.05 level. ** Correlation is significant at the 0.01 level.

	Duck								
Goose	HV	CV	BV	CGL	GH	GB	SBO	MGL	Laf
HV		0,711	0,317	-0,451	-0,033	0,114	0,238	-0,328	-0,273
CV	-0,838*		0,591	0,046	0,379	0,61	0,492	0,121	0,052
BV	0,819*	-0,533		0,615	0,068	0,411	-0,13	0,521	0,619
CGL	-0,002	0,473	0,138		-0,144	0,574	-0,43	0,921**	0,942**
GH	-0,024	0,029	0,263	0,241		-0,068	0,773	-0,324	-0,439
GB	-0,327	0,482	-0,275	0,708	0,579		0,053	0,742	0,612
SBO	-0,187	0,625	0,098	0,955**	0,364	0,702		-0,355	-0,59
MGL	-0,076	0,387	-0,033	0,901*	0,474	0,922**	0,849*		0,947**
Laf	-0,015	0,425	-0,003	0,973**	0,177	0,763	0,886*	0,936**	

4. Discussion

In the study, some volumetric and length peculiarities of the native goose and ducks' head, from Anatidae family were evaluated by CT and the statistically specific results were reached. However, in the literature review, it was shown that there was no sufficient data about birds to compare the obtained findings. Nothing but, the gained volume results in the study were analogised with the volume outcomes of the quail study [19] Duymus et al. (2013), made before.

According to the findings of the study, average values of the HV, CV and BV of the geese were 125.33, 9.1 and 8.67 mm³, respectively. These values of the ducks were found as 116.67, 6.76 and 5.91 mm³, respectively. As things stand, in the native goose, BV was forming 6.92% of HV, and CV was forming 7.26% of HV. In the native duck, BV was forming %5.06 of HV, and CV was forming %5.79 of HV. So, the CV and BV values of the native geese are higher than the volume values of the native ducks. [19] Duymus et al. (2013) have reported as the values of the CV/HV and BV/HV in the quails are 29.07% and 6.47%, respectively. At this point, it could have been declared that the head bone volume of the quail, categorized under Phasianidae family has more than the goose and duck, Anatidae family.

In this study, in the light of literature [20] Driesch (1976), the some osteometric measurements of the skull and mandible of the native goose and duck were received by CT and these measurements were statistically evaluated. After all, it was determined that the gotten length measurements were significant among the geese and ducks, except GH (from the basitemporale in the median plane to the highest and median point of the braincase). The differences between the native

goose and duck based out of there calculated index values were found a significant. Accordingly, in the native goose GH/CGL, GB/CGL, SBO/CGL, MGL/CGL, LaF/CGL and Laf/MGL were as 0.39, 0.34, 0.13, 0.88, 0.76 and in the native duck as 0.86, 0.33, 0.26, 0.09, 0.94, 0.82, 0.87, respectively. As a result, it could claimed that the index values would used in differentiation of the native goose and ducks' heads.

Using PCR technology, DNA analysis is generally applied to define genetic family relationships amongst kinships [22]. In this study, the utility of CT has been tested discrimination of the kind for native duck and geese's skull. Ultimately, it has been concluded that CT could be used for kinship in these species.

The obtained statistical findings in the present study showed that the morphometric analysis made using CT could benefit in the differentiation of the male native goose and ducks' head. Even though Anatidae family was taken as a basis in the study, actually, this study forms a conviction that it may be contribute for combination of the CT with morphometry in the anatomic studies of the avian.

Furthermore, thanks to this study, it was presented that the morphometric CT measurements used to difference of the native goose and ducks' head.

References

- [1] Testik, A. 1995. The situation of ducks and geese production in Turkey. Proc. of 10th European Symposium on Waterfowl. 43-45 pp.
- [2] Demirsoy, A. 1992. Basic Rules of Life. Vertebrates (reptiles, birds and mammals) 1 Print Volume 3 Part 2 Meteksan Inc. Ankara.

- [3] Selcuk, E. and Akyurt, I. 1986. Breeding duck. Ministry of Agriculture and Forestry Publications, No: 8, Ankara.
- [4] Tilki, M. and Saatci, M. 2013. Goose Breeding Ground Up. 1th Ed., Salmat Publishing and Printing, Ankara, 15-40 pp.
- [5] Turkish Statistical Institute. http://www.tuik.gov.tr/PreTablo.do?alt_id=1002. Accessed:11.09.2013
- [6] Rohlf, F.J. and Marcus, L.F. 1993. A revolution in morphometrics. *Trends in Ecology and Evolution*, 8, 129-132.
- [7] Turner, C.H., Sun, Q., Schriefer, J., Pitner, N., Price, R., Boussein, M.L., Rosen, C.J., Donahue, L.R., Shultz, K.L. and Beamer, W.G. 2003. Congenic mice reveal sex-specific genetic regulation of femoral structure and strength. *Calcified Tissue International*, 73, 297-303.
- [8] Silha, J.V., Mishra, S., Rosen, C.J., Beamer, W.G., Turner, R.T., Powell, D.R. and Murphy, L.J. 2003. Perturbations in bone formation and resorption in insulin-like growth factor binding protein-3 transgenic mice. *Journal of Bone and Mineral Research*, 18, 1834-1841.
- [9] Moverare, S., Venken, K., Eriksson, A.L., Andersson, N., Skrtic, S., Wergedal, J., Mohan, S., Salmon, P., Bouillon, R., Gustafsson, J.A., Vanderschueren, D. and Ohlsson, C. 2003. Differential effects on bone of estrogen receptor alpha and androgen receptor activation in orchidectomized adult male mice. *Proceedings of the National Academy of Sciences*, 100, 13573-13578.
- [10] Paulus, M.J., Gleason, S.S., Easterly, M.E. and Foltz, C.J. 2001. A review of high-resolution X-ray computed tomography and other imaging modalities for small animal research. *Laboratory Animals*, 30, 36-45.
- [11] Kindlmann, G.L., Weinstein, D.M., Jones, G.M., Johnson, C.R., Capecchi, M.R. and Keller, C. 2005. Practical vessel imaging by computed tomography in live transgenic mouse models for human tumors. *Molecular Imaging*, 4, 417-424.
- [12] Barbee, D.D., Allen, J.R. and Gavin, P.R. 1987. Computed tomography in horses: Technique. *Veterinary Radiology&Ultrasound*, 28, 144-151.
- [13] Gibbs, C. 1999. Dental imaging. In, Baker GJ, Easley J (Eds): *Equine Dentistry*. Philadelphia, WB Saund, 139-169.
- [14] Forbes, N.A. 2011. Advanced Imaging Diagnostics in Avian Veterinary Practice. *Parrots*, 34 -35.
- [15] Regedon, S., Franco, A., Garin, J.M., Robina, A. and Lignereux, Y. 1991. Computed tomographic determination of the cranial volume of the dog applied to racial and sexual differentiation. *Acta Anatomica*, 142, 347-350.
- [16] Regedon, S., Franco, A., Lignereux, Y., Garin, J.M., Robina, A. and Martin, A. 1992. Skull volume in Pekingese dogs. Tomodensitometry and sex-linked difference. *Revue de Medecine Veterinaire*, 143, 745-748.
- [17] Robina, A., Regedon, S., Guillen, M.T. and Lignereux, Y. 1991. Utilization of computed tomography for the determination of the volume of the cranial cavity of the Galgo hound. *Acta Anatomica*, 140, 108-111.
- [18] Onuk, B., Kabak, M., Sahin, B., Ince, N.G. and Selcuk, M.B. 2013. New method for estimating the volume and volume fractions of the nasal structures in the goose (*Anser anser domesticus*) using computed tomography images. *British Poultry Science*, 54, 441-446.
- [19] Duymus, M., Demiraslan, Y., Akbulut, Y., Orman, G., Aslan, K. and Ozcan, S. 2013. The Statistical Analysis of Some Volumetric Measurements in the Japanese Quails' Head with Different Feather Color: A Computed Tomography Study. *Journal of the Faculty of Veterinary Medicine Kafkas University*, 19, 681-686.
- [20] Driesch, Von Den A. 1976. A Guide to the measurement of animal bones from archaeological sites. Peabody Museum Bulletin I. Cambridge M.A. Harvard University. pp: 31-34.
- [21] Baumel, J.J., King, S.A., Breasile, J.E., Evans, H.E. and Berge, J.C.V. 1993. *Nomina Anatomica Avium*. 2nd edition, prepared by the international committee on avian anatomical nomenclature, A Committee of The World Association of Veterinary Anatomists. Nuttall Ornithological Club. Cambridge, Massachusetts.
- [22] Adams, J. 2008. *Paternity Testing: Blood Types and DNA*. Nature Education.