

Apitherapy of Septic Metacarpal and Metatarsal Wounds (An Experimental Study on Donkeys)

Sayed Mohammed Hamouda^{1, *}, Heba Mohammed Mohammed Kuraa²,
Mahmoud Abed Zaher Abd El-Samieh³, Magda Mahmoud Ali⁴, Haroun Ali Youssef⁴

¹Department of Microbiology, Animal Health Research Institute, Agriculture Research Center, Assiut, Egypt

²Vet. Surgery, General Organization of Vet. Med, Assiut Directory, Egypt

³Department of Pathology, Faculty of Veterinary Medicine, Assiut University, Assiut, Egypt

⁴Department of Surgery, Anesthesiology and Radiology, Faculty of Veterinary Medicine, Assiut University, Assiut, Egypt

Email address:

smhamuda60@gmail.com (S. M. Hamouda)

*Corresponding author

To cite this article:

Sayed Mohammed Hamouda, Heba Mohammed Mohammed Kuraa, Mahmoud Abed Zaher Abd El-Samieh, Magda Mahmoud Ali, Haroun Ali Youssef. Apitherapy of Septic Metacarpal and Metatarsal Wounds (An Experimental Study on Donkeys). *Clinical Medicine Research*. Vol. 8, No. 4, 2019, pp. 77-84. doi: 10.11648/j.cmr.20190804.12

Received: July 26, 2019; **Accepted:** August 22; **Published:** September 10, 2019

Abstract: Non-healed wounds are a significant problem in the healthcare system of the distal portions of the limbs. Nine types of honey were tested for wound healing judged by clinical gross healing parameters, rate of wound contraction and sings of epithelization histopathologically. Rounded full thickness skin wounds (1.5cm diameter) were performed at the distal portion of limbs. The wounds were infected by standard dose of MRSA (methicillin resistance *Staph. aureus*) for 72 hours. The tested types of honey were tested for MIC & MBC against clinical MRSA strain. Different types of honey were applied unprocessed as daily topical wound dressing for the infected wounds. Propolis with black seed honey followed by Hadramout sidr honey, then Egyptian sidr honey proved to have the most antimicrobial activity. Clinical healing appearance revealed that propolis with black seed honey, Egyptian sidr honey and Hadramout sidr honey showed the most preferable clinical parameters (gross appearance and rate of wound contraction), and histopathologically achieved the best healing epithelization 28 days after treatment. The study concluded that among different nine honey types retailed in Egyptian markets, all tested honey types had wound healing activities but with different potencies. Propolis with black seed, Egyptian sidr honey and Hadramout honey were the most potent with highly significance differences ($P < 0.01$), since achieving the most wound contraction rates, rapid epithelization post 28 days rather than the least MICs & MBCs values. While the marjoram and clover honey were the least effective.

Keywords: Wound Healing, Honey Apitherapy, MIC & MBC of Honeys, Histopathology of Wound Healing

1. Introduction

Honey is a traditional remedy in ancient folk medicine and owing to widespread multidrug resistant pathogens emerging, there is a renaissance in honey apitherapy nowadays [1] especially for wound healing either as it is [2-5] or pharmaceutically formulated pectin membrane [6, 7], chitosan hydrogel based [8] or burdock salve [9]. Horses often suffer cutaneous wounds on the distal portion of limbs difficulty to be closed primarily [10], associated with severe tissue avulsion and excessive contamination [11, 12].

Recently, the renewed wound healing activity of honey is widely documented [9, 13, 14], even with infected [3, 15], or non-healing wounds resulting in faster healing process, wound size reduction and lower pain intensity [16]. The present study aimed to investigate the potency of different types of honey as wound dressing for septic skin wounds at limb distal regions in donkeys. Healing was judged by infection clearance, healthy wound contraction or closure and histopathological repair post honey dressing as well as its synergistic activity with bee propolis.

2. Materials and Methods

Animals: Twenty four apparently healthy adult donkeys of (both sexes, 3-5 years of age weighing 150 – 200 Kg body weight) were used in the study. They were categorized randomly into six groups each of four donkeys. Seven days prior to surgery, the donkeys were preoperative treated with I/M administration of anti-tetanic serum oral anthelmintic (ivermectin) and housed in grass yards all over the study, feeder hay and green fodders with free access to water.

Honey Samples: Nine different types of honey collected from retail markets in Egypt; wild herbs, marjoram, blackseed, clover, citrus,, Egyptian sidr, Hadramout sidr, flowers honeys and 10% propolis in blackseed honey (Chinese propolis powder was added to honey as 10% weight to volume) were tried as a therapeutic dressing material of the standard induced septic wounds.

Wounds: Animals were tranquilized by Diazepam (Valpam, Amoun pharmaceutical Co., El-obour city, Cairo, Egypt) in a dose rate 0.2mg / kg body weight and anaesthetized by barbiturate Thiopental sodium (Egyptian Int. Pharmaceutical industries Co. 10th of Ramadan city Egypt.) intravenously in a dose rate of 1g / 90 kg body weight. Then local infiltration analgesia using lidocaine HCl* 2% (Debocaine, Sigma-Tec Pharmaceutical Indust. Co., Packed by Al-Debeky pharmaceutical industries Co., A. R. E.). A rounded 1.5 cm diameter full thickness skin wound was made at lateral distal part of both metacarpal and metatarsal regions. The full thickness skin was excised off and the hemorrhage was controlled by sterile gauze compresses [10].

Standard Bacterial Strain: A standard inoculum was prepared from overnight incubated nutrient broth of methicillin resistant Staphylococcus aureus (Field MRSA strain) originated from clinical septic cutaneous equine wounds which adjusted to 0.5 McFarland opacity standard and diluted up to 5×10^5 CFU/ml [17].

Determination of Minimal Inhibitory Concentration (MIC) & Minimal Bactericidal Concentration (MBC): All Honey Types Were Tested Against the Above Mentioned MRSA Standard Bacterial Strain to Determine both MICs & MBCs as follows; for MIC, tube serial dilution was freshly prepared from 50% up to 1.56% for each honey type where each tube received 0.1 ml from the previously mentioned standard bacterial strain which be incubated aerobically at 37°C for 24 hour. The least dilution showed no visible bacterial growth was the MIC value. For MBC, from the MIC incubated tubes and least dilutions up to 50% a loopful was inoculated onto nutrient agar plates to be overnight incubation. The least dilution showed no bacterial growth was the MBC value [17].

Induced Infection and Sepsis Developed: A sterile gauze piece was dipped in the standard inoculum broth to be full saturated and then it was fitted on the induced wound for 72 hours till sepsis developed exuding purulent exudates. The process was adopted daily on the induced wound. This was the time (0) and apitherapeutic application would begin as follows: each animal had three wounds which were dressed

using three different types of honey and the fourth one was left as control (saline dressed bandage).

Clinical findings were recorded at time (0), then on 7, 14, 21 and 28 post the 1st surgical dressing interference. The wounds were examined grossly for presence of swelling, odour, edema, marked accumulation of exudates, scab formation and exuberant granulation tissue as well as wound dimensions.

Histopathological Specimens: From the wounds treated with every honey type, two biopsy specimens were collected on the 14 & 28 days postoperatively. The specimens included the whole wound and 3 mm of the surrounding skin circumferentially and deeply to the subcutaneous tissue. The specimens were fixed in 10% neutral buffered formalin, dehydrated in a graded alcohol series, cleared in methyl benzoate and embedded in paraffin wax. Five-micron thick sections were cut and stained with hematoxylin and eosin [18].

3. Results & Discussion

Noteworthy is the use of honey as a wound-healing agent since it promotes a multifaceted and safe healing activity for all skin wounds [13]. Moreover, either ethanolic [19] or aqueous [20] extract of propolis accelerates wound healing and have synergistic action with honey [21, 22].

Since, honey potency and activity differ greatly according to botanical, geographical and seasonal conditions up to more than 100 fold in between different honeys [23], the present study tested the activity of different types of honey either *in vitro* to assess both MIC & MBC values or *in vivo* through the investigated different types of honey as unique septic wound dressing. The *in vitro* testing of different types of honey against MRSA revealed that all tested honey types had antimicrobial activity with different potencies where propolis with black seed honey followed by Hadramout honey showed the lowest MIC, Figure 1 and MBC values (the best activity) Figure 2, while both black seed and citrus honeys revealed the highest values (the lowest activity) as shown in Figure 1.

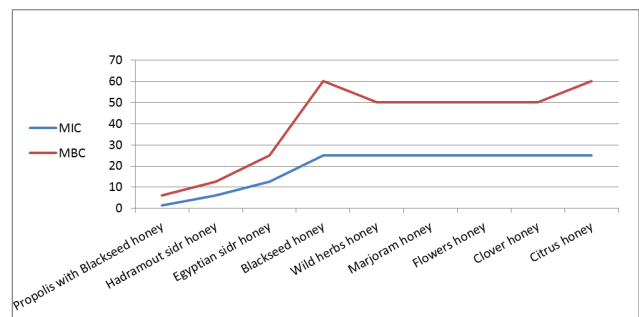


Figure 1. MIC and MBC values of different types of honeys and propolis against MRSA.

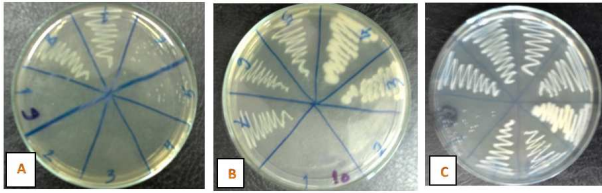


Figure 2. In vitro MBC of different honey types against MRSA: (A) Propolis with Blackseed honey (6.25%), (B) Egyptian sidr honey (25%), (C) Blackseed honey and Citrus honey (>50%).

It is widely documented that against MRSA, honey [24-31] or propolis [32-34] has potent antimicrobial activities with synergistic action of both together [28, 30, 35].

The referred activity of honey is attributed to its acidity (pH between 3.2 and 4.5), osmotic effect of its high sugar content [3], and also derived from H₂O₂ generated which is involved in oxidative damage causing bacterial growth inhibition by DNA degradation [36]. Although H₂O₂ is an important factor in the bacterial growth inhibition,

polyphenolic compounds and their interaction with H₂O₂ are the key factors responsible for honey high antibacterial activity [30].

There is great variety of nonperoxide factors of plant origin such flavonoids mainly Chrysin [37] and polyphenolic mainly caffeic acid [38]. Honey-induced extracellular Ca²⁺ entry results in wound healing due to H₂O₂ production and redox regulation which prefer utilization of the honey as a beneficial tool [39]. Propolis is rich in these flavonoids and phenolic components [40]. Honey antimicrobial action will be maximized and synergized by propolis [28, 30].

In the present study, clinical gross appearance of septic wounds revealed that topical application of all honey types cleared sepsis comparing with control group and enhanced for healing with different rates of wound closure, where black seed with propolis, Egyptian sidr and Hadramout sidr honeys showed the most accelerated healing appearance, while flowers honey and marjoram honey had low wound healing rates (Figure 3).

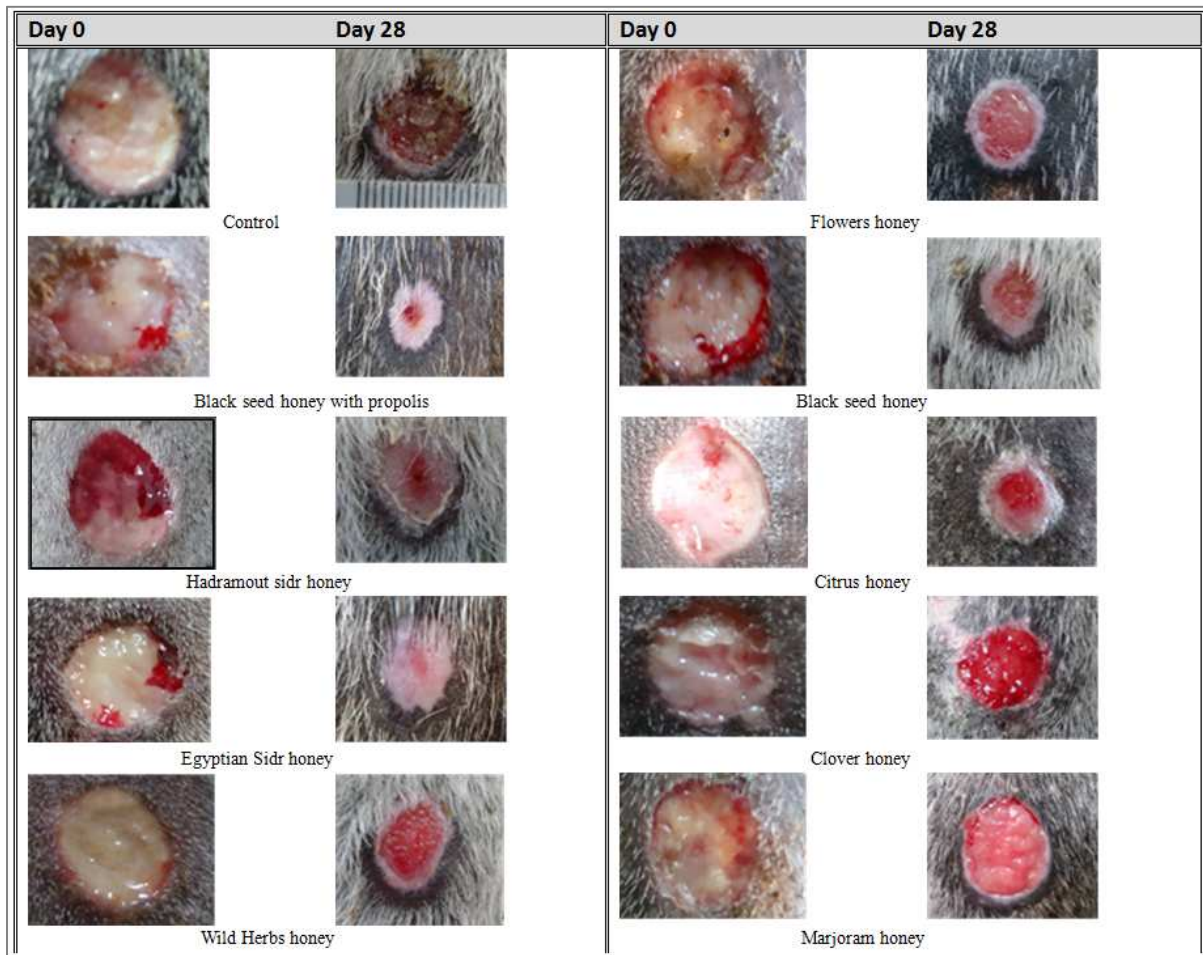
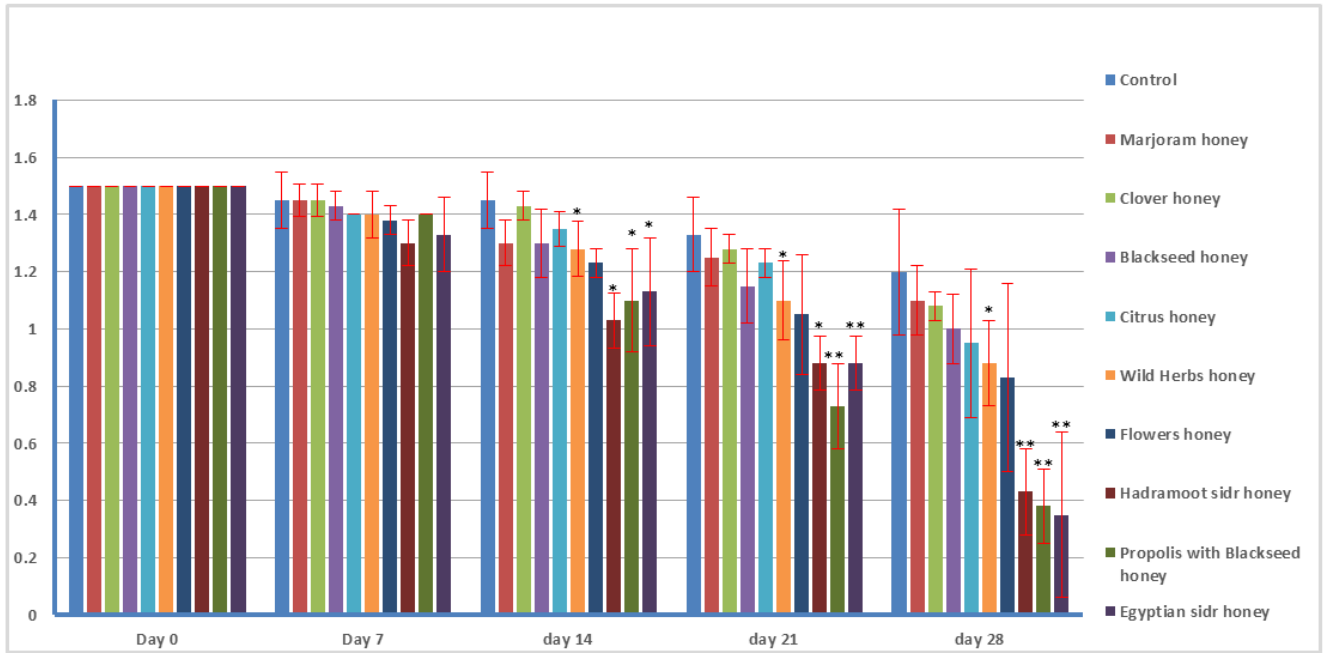


Figure 3. Clinical gross appearance of septic wound treated with topical application of different honey types.

Among the promising previously mentioned results, propolis with black seed honey and Egyptian sidr honey showed highly significant ($P < 0.01$) decrease of wound dimensions by the 21th day while Hadramout sidr honey reached to the same results by the 28th day post topical honey

application (Figure 4). These three honey types had high rates of wound contraction. The flowers honey followed by marjoram honey had the lowest wound contraction rates (Figure 4) 28 days post topical honey application.



* Significant at P < 0.05 ** Highly significant at P < 0.01

Figure 4. Rate of wound contraction treated with different honeys application.

Although the cutaneous wounds on the distal portion of horse’s limbs are difficult or impossible to be closed primarily and must heal by 2nd intention [10], the present study revealed good healing parameters by the day 28th post honey topical application. Wound area reduction up to complete healing (wound closure) was achieved with topical application of honey in surgical induced non septic wounds by the 10th day [41], 12th day [42], 14th day [43], 16th day [44], 21th day [45], 28th [46] or by the day 28th in clinical septic wounds [4, 30]. Also, topical application of propolis powder by the 21th day [47, 48], its ethyl extract by the 25th day [15], its ethyl extract in association with bacterial cellulose by the 14th day [49] or addition of its aqueous extract to rubber membrane by the 10th day [20].

Honey dressings improve wound healing as it makes it sterile in short duration and have good outcomes in terms of incidence of hypertrophic scars [50], since it significantly enhances wound closure and accelerates the rate of re-epithelialization [46], subsequently wound debridement [51].

The mechanism responsible for this positive final effect includes its ability to reduce free radical oxygen species (ROS) production and inflammation through suppression of pro-inflammatory cytokines production (tumor necrosis factor- α , interleukin-1, and interleukin-6) [52], from monocytes and macrophages [53] or epidermal keratinocyte [54] or by the action of apigenin and kaempferol, identified as honey flavonoids. Moreover, honey stimulates angiogenesis, promoting an efficacious skin-remodeling phase [13, 55] and tensile strength [56].

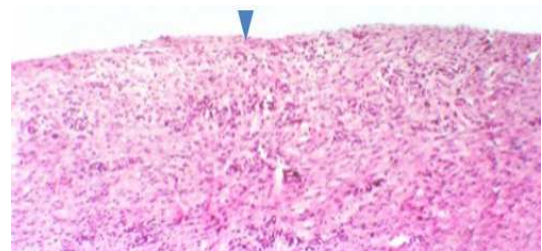


Figure 5. Control.

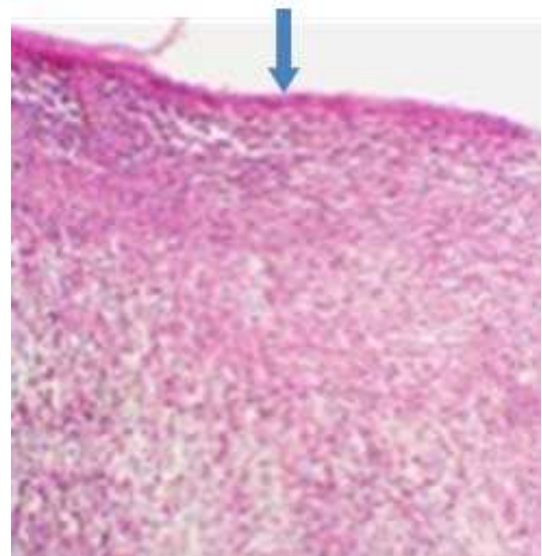


Figure 6. Black seed honey with propolis.

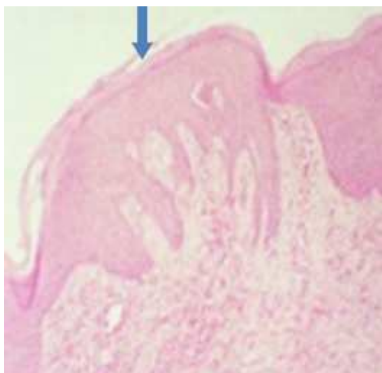


Figure 7. Hadramout Sidr honey.

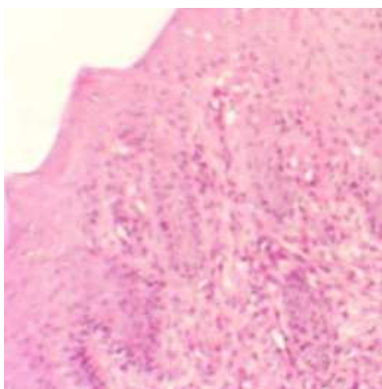


Figure 8. Egyptian sidr honey.

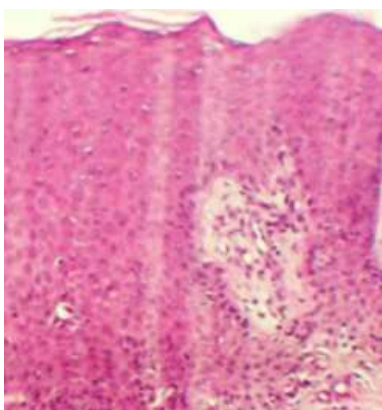


Figure 9. Wild Herbs honey.

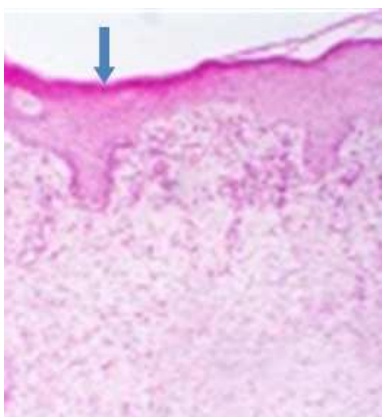


Figure 10. Flowers honey.

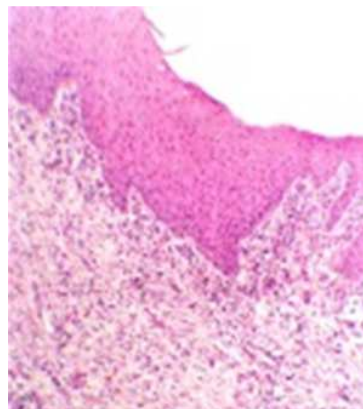


Figure 11. Black seed honey.

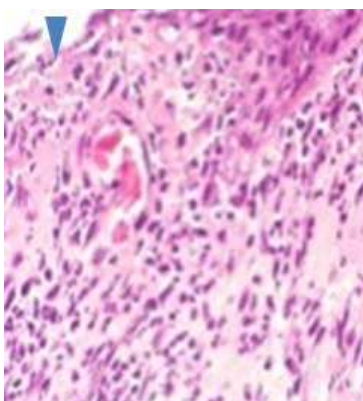


Figure 12. Citrus honey.

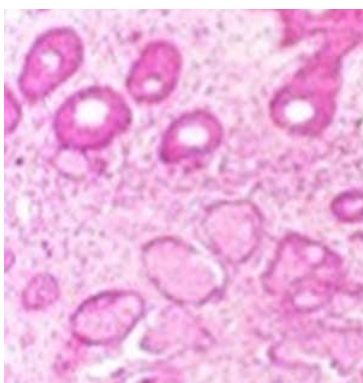


Figure 13. Clover honey.

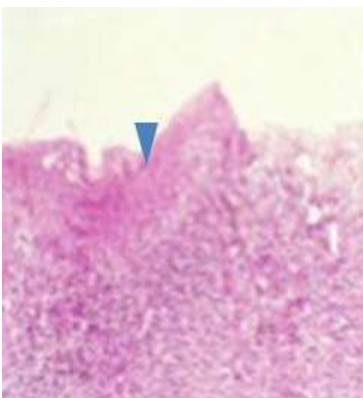


Figure 14. Marjoram honey.

Propolis induces wound healing with collagen production, angiogenesis, re-epithelization accelerating the healing process [49] and tissue repair without the curative switch [20]. Even in bone marrow mesenchymal stromal cells, propolis enhances cell proliferation and tissue regeneration [57].

The present histopathological results revealed that all honey treated septic wounds had different re-epithelization process indicating variant healing potencies (figures 5-14). Black seed honey with propolis, Egyptian sidr honey and Hadramout sidr honey (Figures 6, 8 & 7 respectively) induced the best re-epithelization degree, while citrus and marjoram honey show incomplete epithelization up to 28 days (Figures 12 & 14 respectively).

Wound healing is a complex and systematic process, in terms of histopathology it includes three phases including inflammation, proliferation, and remodeling [58]. Honey increases activity of fibroblasts [29] and collagen formation [20, 59]. Honey contains high levels of glycine, methionine, arginine, and proline, which are all necessary for collagen formation and fibroblast deposition, which are essential factors needed for healing [6].

Collagen films with propolis were able to improve wound healing by modulating the collagen deposition process and the inflammatory evolution [60] as it decreases the inflammatory severity, induces earlier replacement of type-III for type-I collagen, improving the epithelization rates and the myofibroblastic count which were significantly increased in 14 and 21 days [61]. As honey increases keratinocyte closure rate and fibroblast migration [62] and propolis stimulates the ability of keratinocytes to close the wound [29, 55], mixing both apitherapeutic products explain the synergistic activity of wound closure.

4. Conclusion

The study concluded that among different nine honey types retailed in Egyptian markets, all tested honey types had wound healing activities but with different potencies. Propolis with black seed, Egyptian sidr honey and Hadramout honey were the most potent with highly significance differences ($P < 0.01$), since achieving the most wound contraction rates, rapid epithelization post 28 days rather than the least MICs & MBCs values. While the marjoram and clover honey were the least effective.

5. Recommendations

It is highly recommended to manage the septic incurable equine wounds with propolis ethanolic extract solution combined with honey as the main dressing antimicrobial and anti-inflammatory agent. Further investigations must be adopted to examine the efficacy of the crude propolis powder combined with honey since the crude powder rather than it has the effective active principles, it aids for wound dryness with clean aseptic surface.

References

- [1] Molan, P. C. Potential of Honey in the Treatment of Wounds and Burns." *Am. J. Clin. Dermatol.* 2001; 2 (1): 13-19.
- [2] Jull AB, Cullum N, and Dumville JC. Honey as a topical treatment for wounds. Copyright © 2015 The Cochrane Collaboration. Published by John Wiley & Sons, Ltd.
- [3] Hussain MB. Role of Honey in Topical and Systemic Bacterial Infections. *J. Altern Complement Med* 2018 Jan; 24 (1): 15-24. doi: 10.1089/acm.2017.0017.
- [4] Ali MA, Saleh AS, Abdul-Hafeez MM and Koreim AM. Honey and medicinal plants in the management of certain surgical bovine clow affections. *International Journal of Complementary & Alternative Medicine* 2017; 9 (3): 00300.
- [5] Abdul-Hafeez MM. Testimony for veterinary apitherapy. *Int. J Complement Alt Med*; 2019; 2 (1): 15–22.
- [6] Giusto G, Vercelli C, Comino F, et al. A new, easy-to-make pectin-honey hydrogel enhances wound healing in rats. *BMC Complementary and Alternative Medicine* 2017; 17: 266
- [7] Giusto G, Beretta G, Vercelli C, et al. Pectin-honey hydrogel: Characterization, antimicrobial activity and biocompatibility. *Biomed Mater Eng.* 2018; 29 (3): 347-356. doi: 10.3233/BME-181730.
- [8] El-Kased Reham F, Reham IA, Dalia A, and Elmazar MM. Honey-based hydrogel: In vitro and comparative In vivo evaluation for burn wound healing. *Scientific Reports* 2017; 7: 9692 | DOI: 10.1038/s41598-017-08771-8.
- [9] Schell A, Jonathan C, Kath MB and Robert Wetzel. Honey-Based Salve and Burdock Leaf dressings as an alternative to surgical debridement of a traumatic wound eschar. *Advances in Wound Care* 2019; volume 8, number, 3, 101- 107.
- [10] Gomez JH, Schumacher J, Lauten SD, et al. Effects of 3 biologic dressings on healing of cutaneous wounds on the limbs of horses. *The Canadian J. of Vet Rese* 2004; 68: 49–55.
- [11] Theoret CL, Barber SM, Gordon JR. Temporal localization of immunoreactive transforming growth factor beta1 in normal equine skin and in full-thickness dermal wounds. *Vet. Surg.* 2002; 31: 274–280.
- [12] Theoret CL. The pathophysiology of wound repair. *Vet Clin North Am Equine Pract* 2005; 21: 1–13.
- [13] Governa P, Carullo G, Biagi M, et al. Evaluation of the in *Vitro* wound-healing activity of Calabrian honeys. *Antioxidants* 2019; 8: 36; doi: 10.3390.
- [14] Santos AMN, Ana Paula Duarte Moreira APD, Carvalho C WP, et al. Physically cross-linked gels of PVA with natural polymers as matrices for Manuka honey release in wound-care application. *Materials* 2019; 12, 559.
- [15] Al-Waili Noori. Mixing two different propolis samples potentiates their antimicrobial activity and wound healing property: A novel approach in wound healing and infection. *Veterinary World.* 2018; Vol. 11, 1188-1195.
- [16] Zeleníková, R, Vyhřídálová D. Applying honey dressings to non-healing wounds in elderly persons receiving home care. *J. Tissue Viability.* 2019 Apr 13. pii: S0965-206X (18)30137-2. doi: 10.1016/j.jtv.2019.04.002.

- [17] Quinn PJ, Carter ME, Markey B, et al. Bacteriology: Clinical veterinary microbiology. 6th Ed. Mosby Edinburgh London New York: Oxord Philadelphia St Louis Sydney Toronto; 2011.
- [18] Bancroft JD and Stevens A. Theory and practice of Histologic techniques. 3rd Ed. Long Man Group Limited; 1993.
- [19] Rosseto HC, Toledo LAS, Francisco LMB. Nanostructured lipid systems modified with waste material of propolis for wound healing: Design, in vitro and in vivo evaluation. Colloids Surf B Biointerfaces 2017; Oct 1; 158: 441-452.
- [20] Krupp T, Dos Santos BD, Gama LA, et al. Natural rubber - propolis membrane improves wound healing in second-degree burning model. Int. J Biol. Macromol 2019; 15; 131: 980-988.
- [21] Takzaree N, Hadjiakhondi A, Hassanzadeh G, et al. Synergistic effect of honey and propolis on cutaneous wound healing in rats. Acta Medica Iranica 2016; Vol. 54, No. 4: 233-239.
- [22] Sharaf S and El-Naggar ME. Wound dressing properties of cationized cotton fabric treated with carrageenan/cyclodextrin hydrogel loaded with honey bee propolis extract. Int J Biol Macromol 2019; Apr 18; 133: 583-591.
- [23] 23-Gül A and Pehlivan T. Antioxidant activities of some monofloral honey types produced across Turkey. Saudi Journal of Biological Sciences 2018; 25: 1056-1065
- [24] Firdose A, Nisar A, Dsouza MR. Evaluation of in vitro antimicrobial activity of Indian honey on burn wound isolates. J. of Chemical and Pharma Research. 2016; 8 (3): 1027-1034.
- [25] Patel A, Chauhan PB. Antimicrobial effect of honey on MRSA isolated from pus samples. Int J Drug Res Tech. 2016; 6 (2): 58-63.
- [26] Almasaudi SB, Al-Nahari AAM, Abd El-Ghany ESM, et al. Antimicrobial effect of different types of honey on *Staphylococcus aureus*. Saudi J Biol Sci. 2017; 24 (6): 1255-1261.
- [27] Poovelikunnel TT, Gethin G, Solanki D, et al. Randomized controlled trial of honey versus mupirocin to decolonize patients with nasal colonization of methicillin-resistant *Staphylococcus aureus*. J. Hosp Infect. 2017; 98 (2): 141-148.
- [28] Hamouda SM, Abd El Rahman MF, Abdul-Hafeez MM and Gerges AE. Egyptian fennel honey and/or propolis against MRSA harboring both *mecA* & *icaA* genes. Int. J. Complement Alt Med. 2018; 11 (3): 180-185.
- [29] Benjamin A, Minden-Birkenmaier and Gary L. Bowlin. Honey-based templates in wound healing and tissue engineering. Bioengineering; 2018, 5, 46.
- [30] Abdul-Hafeez MM. Testimony for veterinary apitherapy. Int. J. Complement. Alt. Med. 2019; 12 (1): 15-22.
- [31] Mama M, Teshome T, Detamo J. Antibacterial activity of honey against methicillin-resistant *Staphylococcus aureus*: A laboratory-based experimental study. Int J. Microbiol. 2019; Apr 3; 2019: 7686130. doi: 10.1155/2019/7686130.
- [32] Raghukumar R, Vali L, Watson D, Fearnley J and Seidel V. Antimethicillin-resistant *Staphylococcus aureus* (MRSA) activity of 'pacific propolis' and isolated prenylflavanones. Phytother Rese 2010; 24 (8): 1181-1187.
- [33] Bryan J, Redden P and Traba C. The mechanism of action of Russian propolis ethanol extracts against two antibiotic-resistant biofilm-forming bacteria. Lett. Appl. Microbiol (2016); 62 (2): 192-198.
- [34] Al-Ani I, Zimmermann S, Reichling J, et al. Antimicrobial activities of European propolis collected from various geographic origins alone and in combination with antibiotics. Medicines 2018; 5 (1): 2.
- [35] Al-Waili N, Al-Ghamdi A, Ansari MJ, et al. Synergistic effects of honey and propolis toward drug multi-resistant *Staphylococcus aureus*, *Escherichia coli* and *Candida albicans* isolates in single and polymicrobial cultures. Int J Med Sci. 2012; 9 (9): 793-800.
- [36] Živković L, Bajić V, Dekanski D, et al. Manuka honey attenuates oxidative damage induced by H₂O₂ in human whole blood in vitro. Food Chem Toxicol. 2018; 119: 61-65.
- [37] Mani R, Natesan V. Chrysin: Sources, beneficial pharmacological activities, and molecular mechanism of action. Phytochemistry 2018; 145: 187-196.
- [38] Cianciosi D, Forbes-Hernández TY, Afrin S, et al. Phenolic compounds in honey and their associated health benefits: A Review. Molecules. 2018; 23 (9): pii: E2322.
- [39] Martinotti S, Laforenza U, Patrone M, Francesco Moccia F, and Ranzato E. Honey-mediated wound healing: h₂O₂ entry through AQP3 determines extracellular Ca²⁺ influx. Int. J. Mol. Sci. 2019, 20, 764; doi: 10.3390/ijms 20030764.
- [40] Georgieva K, Milena Popova M, Dimitrova L, et al. Phytochemical analysis of Vietnamese propolis produced by the stingless bee *Lisotrigona cacciae*. journal. pone. 2019; 24, <https://doi.org/10.1371>
- [41] Ghaderi R, Afshar M, Akhbarie H, and Golalipour MJ. Comparison of the efficacy of honey and animal oil in accelerating healing of full thickness wound of mice skin. Int. J. Morphol., 2010; 28 (1): 193-198.
- [42] Imtara H, Al-Waili N, Bakour M, Al-Waili W, and Badiia Lyoussi B. Evaluation of antioxidant, diuretic, and wound healing effect of Tulkarm honey and its effect on kidney function in rats. Veterinary world.org/Vol.11/October-2018/21.
- [43] Haryanto RN MS, Tamae Urai RN MS, Kanae Mukai RN, MS, et al. Effectiveness of Indonesian honey on the acceleration of cutaneous wound healing: An experimental study in mice. Wounds 2012; 24 (4): 110-119.
- [44] Kotian S, Bhat K, Pai S, et al. The role of natural medicines on wound healing: a biomechanical, histological, biochemical and molecular study. Ethiop J. Health Sci. 2018; Vol. 28, No. 6.
- [45] Aderounmu AO, Omonisi AE, Akingbasote JA, et al. Wound-healing and potential anti-keloidal properties of the latex of *calotropis procera* (aiton) *asclepiadaceae* in rabbits. Afr J Tradit Complement Altern Med. 2013; 10 (3): 574-579.
- [46] Zohdi RM, Zuki ABZ, and Norimah Y, et al. Gelam (*Melaleuca* spp.) honey-based hydrogel as burn wound dressing. Evidence-Based Complementary and Alternative Medicine Volume 2012, Article ID 843025, 7 pages.
- [47] Abdel-Wahed RE, El-Kammar MH, Korittum AS and Edrees IR. Surgical and histological evaluation of the effectiveness of propolis on wound healing. Alexandria Journal of Veterinary Sciences 2013; 39: 52-63.

- [48] Rufatto LC, Denis Amilton dos Santos, Fl'ávio Marinho. Red propolis: Chemical composition and pharmacological activity. *Asian Pac. J. Trop. Biomed.*; 2017; 7 (7): 591–598.
- [49] Picolotto A, Pergher D, Guilherme Pacheco Pereira, et al. Bacterial cellulose membrane associated with red propolis as phytomodulator: Improved healing effects in experimental models of diabetes mellitus. *Biomedicine & Pharmacotherapy* 2019; 112; 108640.
- [50] Gupta SS, Singh O, Bhagel PS, et al. Honey dressing versus Silver Sulfadiazene dressing for wound healing in burn patients: A retrospective study. *Journal of Cutaneous and Aesthetic Surgery* 2018; Volume 4, Issue 3.
- [51] Pasupuleti VR, Sammugam L, Ramesh N, Siew Hua Gan SH. Honey, Propolis, and Royal Jelly: A comprehensive review of their biological actions and health benefits. *Oxidative Medicine and Cellular Longevity*, Volume 2017, Article ID 1259510, 21 pages.
- [52] Weiß KT, Fante M, Köhl G, et al. Proton-sensing G protein-coupled receptors as regulators of cell proliferation and migration during tumor growth and wound healing. *Experimental Dermatology* 2017; Volume 26 Issue 2, 127 -132.
- [53] Majtan J (2014): Honey: An immunomodulator in wound healing. *Wound Rep Reg* 2014; 22 187–192.
- [54] Majtan J, Jana Bohova, Rocio Garcia-Villalba, et al. Fir honeydew honey flavonoids inhibit TNF- α -induced MMP-9 expression in human keratinocytes: a new action of honey in wound healing. *Arch. Dermatol. Res.* 2013; 305: 619–627.
- [55] Martinotti S, Bucekova M, Majtan J, Ranzato E. Honey: An effective regenerative medicine product in wound management. *Curr. Med. Chem.* 2018; May 10.
- [56] Alizadeh AM, Sohanaki H, Mahmood Khaniki M, et al. The effect of Teucrium Polium honey on the wound healing and tensile strength in rat. *Iranian Journal of Basic Medical Sciences* 2011; Vol. 14, No. 6: 499-505.
- [57] Elkhenany Hoda, Nagwa El-Badri, Madhu Dhar. Green propolis extract promotes in vitro proliferation, differentiation, and migration of bone marrow stromal cells. *Biomedicine & Pharmacotherapy* 2019; 115 108861.
- [58] Takzaree Nasrin, Hassanzadeh G, Rouini MR, et al. Evaluation of the effects of local application of thyme honey in open cutaneous wound healing. *Iran J Public Health* 2017; Vol. 46, No. 4: 545-551.
- [59] Anjum SI, Ullah A, Khalid Ali Khan KA, et al. Composition and functional properties of propolis (bee glue): A review. *Saudi Journal of Biological Sciences* 2018; 08.013, doi.org/10.1016/j.sjbs.
- [60] Albuquerque-Júnior RLC, Barreto ALS, Pires AJ, Reis FP, Lima SO, et al. Effect of bovine type-I collagen-based films containing red propolis on dermal wound healing in rodent model. *Int J Morphol* 2009; 27: 1105-1110.
- [61] Almeida EB, Cardoso JC, Lima AK, Oliveira NL, et al. The incorporation of Brazilian propolis into collagen-based dressing films improves dermal burn healing. *J Ethnopharmacol* 2013; 147: 419-25.
- [62] Ranzato E, Martinotti S, Burlando B. Epithelial mesenchymal transition traits in honey-driven keratinocyte wound healing: Comparison among different honeys. *Wound Repair Regener.* 2012; 20, 778–785.