

Case Report

Rotational Atherectomy Before Stenting in the Body of a Saphenous Vein Graft

Paul Charbel¹, Joe Shaffu¹, Nadine Kaoukabani^{2, *}, Pierrette Habib¹

¹Cardiology Division, Department of Medicine, Saint George Hospital, UMC-University of Balamand, Faculty of Medical Sciences, Beirut, Lebanon

²Cardiothoracic Anesthesia Division, Anesthesia Department, Saint George Hospital, UMC-University of Balamand, Faculty of Medical Sciences, Beirut, Lebanon

Email address:

nadine_kaoukabani@yahoo.com (N. Kawkabani)

*Corresponding author

To cite this article:

Paul Charbel, Joe Shaffu, Nadine Kaoukabani, Pierrette Habib. Rotational Atherectomy Before Stenting in the Body of a Saphenous Vein Graft. *International Journal of Cardiovascular and Thoracic Surgery*. Vol. 5, No. 1, 2019, pp. 1-5. doi: 10.11648/j.ijcts.20190501.11

Received: January 20, 2019; Accepted: February 25, 2019; Published: March 16, 2019

Abstract: Management of stenosis of saphenous vein grafts in Coronary artery bypass graft (CABG) patients remains challenging despite the advance in interventional cardiology techniques. Rotational atherectomy is an adjunctive technique used in certain anatomical conditions in native coronary arteries; its use in saphenous vein graft is still contra-indicated by the manufacturer, and has only been reported in few cases in the literature. We report a case of a calcified, non-dilatable, distal saphenous vein graft to Circumflex lesion in a heart failure patient presenting with Non STEMI. The lesion was just proximal to the anastomosis and could not be crossed. Because of high surgical risk, and against manufacturer guidelines, rotational atherectomy of the lesion was performed and was successful with a very good angiographic result. Rotational atherectomy to facilitate percutaneous interventions in saphenous vein graft lesions is feasible, and could be attempted in experienced centers provided the absence of luminal thrombus or dissection.

Keywords: Rotational Atherectomy, Saphenous Vein Graft, Non STEMI, Percutaneous Coronary Intervention

1. Introduction

Management of stenotic lesions of saphenous vein grafts (SVG) remains challenging despite the major advances in revascularization techniques.

SVG, which are used in almost every CABG surgery, have a limited life expectancy as demonstrated in different studies: they have a patency rate at 10 years of 50-60%, while that of arterial conduits reaches 85-95%. [1]

Percutaneous intervention (PCI) for CABG patients is currently a common procedure, accounting for 10-15% of all interventions in the majority of catheterization laboratories. [2] Cardiovascular events following PCI are doubled in case of a SVG lesion compared to a native coronary lesion [3]. Balloon inflation at anastomotic sites is even more difficult because of the difference in size between the native artery and the SVG [4]. Current guidelines concerning PCI in SVG recommend

only the preferential use of drug eluting stents (DES) over bare metal stents (BMS), in view of lower restenosis, and target vessel revascularization rates. They also recommend the use of Embolic protection devices, when feasible, in PCI for SVG stenoses. [3] Since its first application in humans in 1988, rotational atherectomy has been used as an adjunctive therapeutic device to PCI, in case of calcified, difficult to dilate coronary artery lesions. Two major physical principles are the basis for the effectiveness of rotational atherectomy: first is differential cutting: the diamond-coated burr is capable of selectively ablating the inelastic plaque, pulverizing its content, while preserving the integrity of the elastic component which is the native vessel wall; the second principle is the orthogonal displacement of friction, by which, at high rotational speed, the device can be easily advanced and withdrawn without friction, through diseased and tortuous coronary arteries. [5] The latest 2011, ACC/AHA guidelines

limit the use of rotational atherectomy to fibrotic, calcified native coronary lesions that are difficult to cross, or to dilate with balloon angioplasty, and prohibit its routine use for de novo lesions, or in-stent restenosis. There is no mention about a possible application in SVG stenosis. [3] Because rotational atherectomy is most effective in fibrotic, inelastic lesions, and much less in soft, thrombus-containing stenoses, the manufacturer, (Boston Scientific), has restricted its indications to ostial, calcified, native vessel lesions, with specific anatomical characteristics; its use is contra-indicated in case of acute myocardial infarction, and in SVG lesions, where the risk of embolization of microparticles into the coronary microcirculation is high, with subsequent risk of no-reflow phenomenon and significant myocardial injury. It is also not recommended for use in patients with left ventricular ejection fraction (LVEF) less than 30% and in those at very high risk for coronary bypass grafting (CABG), for lack of scientific evidence [6].

Despite these restrictions, few papers in the literature have reported the use of rotablator in SVG lesions, more in ostial proximal than distal anastomoses and very rarely in the body of SVG. We, herein, describe a case of a 67 year-old male who presented to our hospital for acute decompensation of heart failure by a Non ST Elevation myocardial infarction (NSTEMI) and who benefitted from treatment with Rotablator of his SVG-Circumflex stenosis.

2. Case Presentation

2.1. Clinical Presentation

Mr D. was transferred from a hospital in Saudi Arabia where he was admitted for acute pulmonary edema preceded by acute chest pain. His past medical history is relevant for an ischemic heart disease (Coronary Artery Bypass Graft (CABG) in 2000) with a LVEF of 25% at the time of surgery. An echocardiogram done 18 months prior to his presentation showed an EF of 33%. He is known to have diabetes for about 10 years, and to be a current heavy smoker.

He was stable on medical therapy which included, in addition to a beta-blocker, an ACE inhibitor, Aspirin, Clopidogrel, and a statin, as well as Amiodarone for a not well documented arrhythmia. Upon admission, he was hemodynamically stable with a regular heart rate, an apical S3 gallop, and crackles at both lower lung fields; a bilateral carotid bruit, bilateral femoral bruit and weak pulses in the lower extremities were also found. His ECG showed a sinus rhythm with few premature ventricular and supraventricular beats, a complete right bundle branch block, Q waves in the inferior leads and non specific ST-T changes from C1-C6. Echocardiogram showed evidence of a large fibrotic scar involving the apex and the apical segments, akinesis of the inferior wall and of the basal septum with hypokinesis of the basal and mid lateral and anterior segments with an estimated left ventricular ejection fraction (LVEF) at 25%. Laboratory results were relevant for a positive serum Troponin, elevated CK and CK-MB, and a serum Creatinin of 1.4mg/dl. The

patient condition improved on treatment with IV diuretics and Low molecular weight heparin after dose adjustment for his estimated GFR. The dose of beta blockers, amiodarone, and ramipril were also adjusted according to his hemodynamic status and vital signs. During his stay, a continuous ECG telemetry documented 4 episodes of non-sustained ventricular tachycardia that were all, asymptomatic and with no hemodynamic repercussion. Coronary angiography performed on the third hospital day showed an anastomotic stenotic left main artery, proximally occluded left anterior descending artery (LAD), occluded Circumflex (Cx), and a right coronary artery (RCA) that was occluded at segment I.

As for the grafts: left internal Mammary artery (LIMA)-LAD was patent, a SVG-Ramus Intermedius was also patent, and another SVG-Circumflex showed a distal subtotal stenosis, just proximal to the anastomosis with the native vessel, which had also a mild stenosis distal to the anastomosis.

The case was discussed with the cardiothoracic team and the PCI option was chosen.

The patient was treated with GPIIb/IIIa, Heparin, and Aspirin and Clopidogrel in preparation for PCI, which took place 48 hours later.

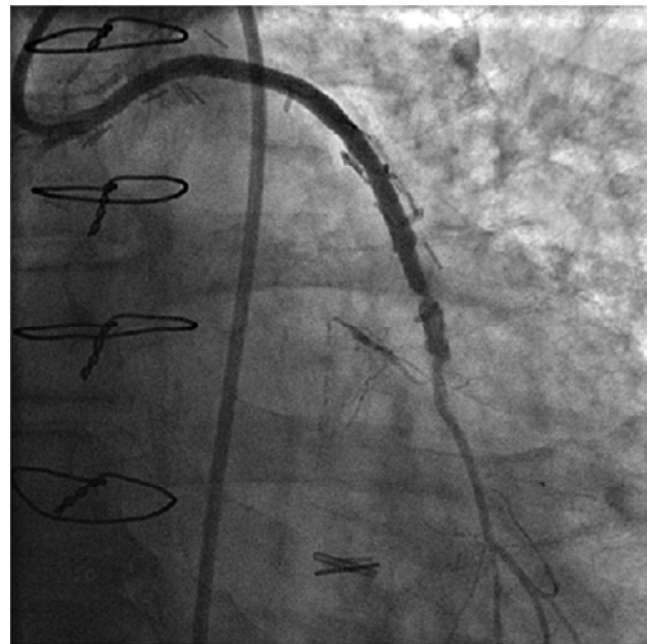


Figure 1. Tight stenosis at the SVG-left Cx Anastomosis.

2.2. Procedure

A 7 Fr sheath was placed in the right femoral artery using a modified Seldinger technique, through which a hockey-stick guiding catheter was introduced. Only two balloons (2 mm and 2.5mm) were able to cross the lesion which failed to yield. Bigger size balloons could not cross. A 0.014 BMW (Guidant Corp.) long wire was advanced to the distal left Cx; a microcatheter (1.8mm Terumo) was inserted, allowing an easy crossing of the 0.009 Floppy Rotawire (Boston Scientific); several passages of 1.5mm burr at 135000 rpm

allowed the crossing of 3mm, 3.5mm and 4mm balloons with yielding of the lesion; a (4mm/18mm) Xience Prime stent (Guidant Corp) was then successfully deployed, followed by a post-dilatation using a 4mm/12mm NC balloon (Trek, Abbott), with an excellent angiographic result.

The patient's course in hospital was unremarkable with no clinical symptoms, ECG or biomarker changes reported.

He also benefitted from the insertion of an implantable cardioverter defibrillator and was discharged home on medical therapy.

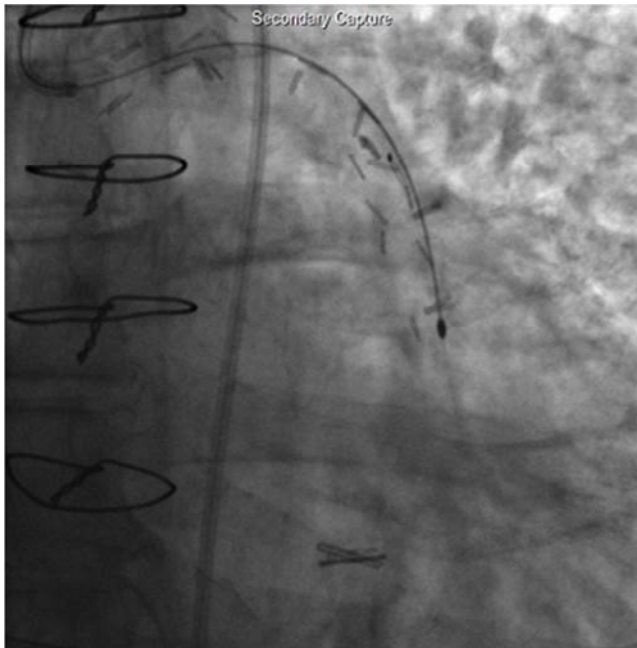


Figure 2. Rotablator therapy on the SVG lesion.

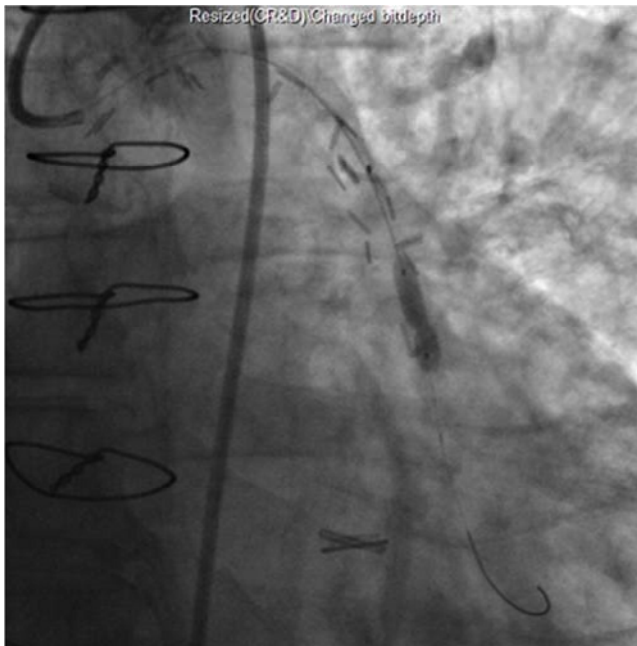


Figure 3. Stent implantation.

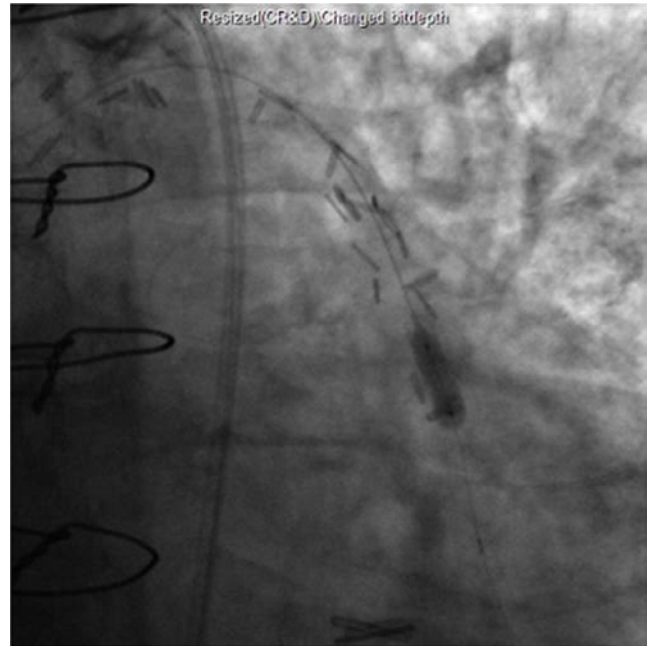

Figure 4. Post dilatation of the lesion.

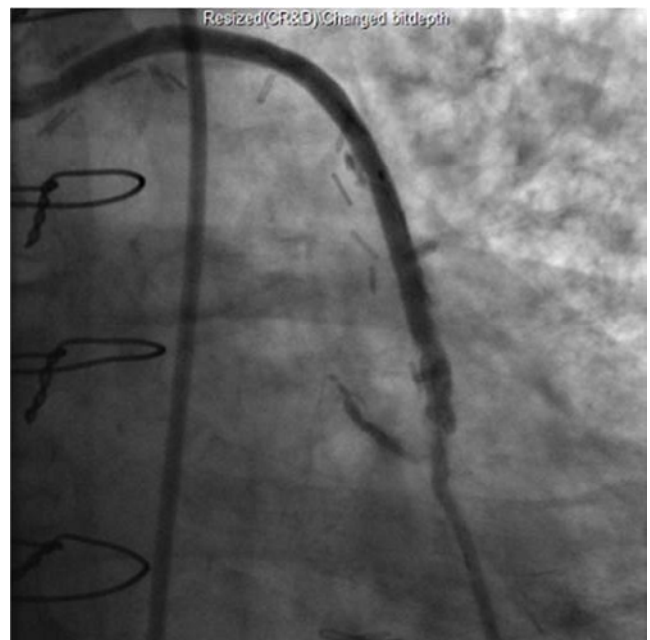


Figure 5. Final angiographic result.

3. Discussion

Vein graft stenosis is common after CABG. While the main mechanism, during the early post-operative period (one month) is acute thrombosis, and intimal hyperplasia is the etiology in the subacute phase (2 months to one year), atherosclerosis underlies graft failure that occurs after the first year.

Vein graft atheromas are usually more diffuse, more concentric and less calcified, with thinner or completely absent fibrous cap, compared to those of the native arteries. Thus, they are more prone to rupture and thrombus formation. [7] Two therapeutic options for vein graft failure are available: either percutaneous intervention (PCI) or repeat bypass. Redo

CABG carries an increased risk, and is technically much more difficult especially in case of a patent LIMA graft. So, PCI is currently the preferred therapeutic approach.

In our patient, the operative risk score is very high (Euroscore =15.24%; STS score for mortality=3.846%; mortality or morbidity: 25.57%).

Markedly calcified stenoses may be resistant to balloon dilatation even if non-compliant ones are inflated at high pressure; stenting would thus be impossible. In such cases, the use of plaque modification and debulking techniques, like atherectomy catheters, laser ablation, and cutting balloons, is very helpful. Because of the histological differences in the composition of SVG stenoses, the latter techniques are only used in case of severely calcified, non-dilatable lesions.

In CAVEAT II trial for SVG, when compared to angioplasty alone, directional atherectomy showed a better immediate angiographic result and same outcome at 6 months but with more periprocedural complications. [8]

Because of discouraging study results, the use of debulking techniques is declining in the blooming era of stents. Few data is present concerning the efficacy and safety of rotational atherectomy in SVG.

As early as 1992, J. Jackman et al reported one case of occluded SVG successfully treated with rotator, without complication. [9]

Further reports described cases of in-stent restenosis, anastomotic lesions or cases about the native vessel disease being treated via the graft. [10-13]

In 2000, W. J. Thomas et al reported a series of rotator used in 14 patients (17 lesions); these were primarily anastomotic sites, with one in-stent restenosis and one within the body of the graft.

No major complications were noted in this biggest series in the literature. [14]

Beside the one case in the above series, two more applications of rotational atherectomy on the body of a SVG were reported [15-16].

To our knowledge, the present case is the fourth case of successful rotator on the body of a SVG.

Distal embolization of pulverized material remains a major risk during rotational atherectomy; concomitant use of GpIIb/IIIa does not reduce the risk of distal embolization, [3] and embolic protection devices cannot be used simultaneously. IVUS would have been of a great help in visualizing possible thrombus but it wasn't available in our case. The manufacturer recommends avoiding rotator therapy in patients with a low LVEF, while it was the last resort in our patient with an LVEF of 25%.

4. Conclusion

Rotational atherectomy is feasible and effective in facilitating PCI on saphenous vein grafts provided the absence of intraluminal thrombus or vessel dissection. It should then be considered, in experienced centers, in order to increase the success rate of PCI, awaiting larger trials and further

procedural guidelines.

References

- [1] Goldman S, Zadina K, Moritz T, et al. Long term patency of saphenous veins and left internal mammary grafts after coronary artery bypass surgery: results of a department of Veterans Affairs Cooperative Study. *J Am Coll Cardiol.* 2004; 44: 2149-56.
- [2] Bain DS. Percutaneous treatment of saphenous vein graft disease: the ongoing challenge *JACC* 2003; 42: 1370-2.
- [3] 2011 ACCF/AHA/SCAI Guideline for Percutaneous Coronary Intervention: A Report of the American College of Cardiology Foundation/American Heart Association Task Force on Practice Guidelines and the Society for Cardiovascular Angiography and Interventions *Circulation.* 2011; 124: e574-e651.
- [4] J. R. Cardenas, R. K. Strumpf, and R. R. Heuser. Rotational Atherectomy in Restenotic Lesions at the Distal Saphenous Vein Graft Anastomosis *Catheterization and Cardiovascular Diagnosis* 3653-57 (1995).
- [5] E. Cavusoglu, A. S. Kini, J. D. Marmur, and S. K. Sharma. Current Status of Rotational Atherectomy Catheterization and Cardiovascular Interventions 62: 485-498 (2004).
- [6] http://www.bostonscientific.com/Device.bscli?page=ResourceDetail&navRelId=1000.1003&method=DevDetailHCP&id=10081831&resource_type_category_id=1&resource_type_id=91&pageDisclaimer=Disclaimer.ProductPag
- [7] S. Leal, R. Campante Teles, et al. Percutaneous revascularization strategies in saphenous vein graft lesions: Long-term results *Rev Port Cardiol.* 2012; 31 (1): 11-18.
- [8] Holmes DR Jr, Topol EJ, Califf RM, et al. A multicenter, randomized trial of coronary angioplasty versus directional atherectomy for patients with saphenous vein bypass graft lesions. CAVEAT-II Investigators. *Circulation* 1995; 91: 1966-1974.
- [9] Jackman J, Hermiller J, Sketch M, Davidson C, Tchong J, Phillips H, Stack R. Combined rotational and directional atherectomy guided by intravascular ultrasound in an occluded vein graft. *Am Heart J* 1992; 124: 214-216.
- [10] Baron S, Arthur A. Rotational atherectomy for resistant anastomotic saphenous vein bypass graft stenosis. *J Invas Cardiol* 1996; 8: 120-122.
- [11] Abhyankar A, Vaidya K, Bernstein L. Rotational atherectomy of calcified ostial saphenous vein graft lesion with long term follow-up: a case report. *Int J Cardiol* 1995; 52: 11-12.
- [12] Cardenas J, Strumpf R, Heuser R. Rotational atherectomy in restenotic lesions at the distal saphenous vein graft anastomosis. *Cathet Cardiovasc Diagn* 1995; 36: 53-57.
- [13] Coto H. Intravascular ultrasound-guided rotational atherectomy and stent implant in a previously undilatable saphenous vein graft lesion. *J Invasive Cardiol* 1998; 10: 451-453.
- [14] Thomas WJ, Cowley MJ, Vetrovec GW, Malloy W, Goudreau E. Effectiveness of rotational atherectomy in aortocoronary saphenous vein grafts. *Am J Cardiol* 2000; 86: 88-91.

- [15] J. BENREY, M. D., A. MESA, M. D., S. JAIN, M. D., and J. A. GARCIA-GREGORY, M. D Successful Rotational Atherectomy of Mid-Saphenous Vein Graft Lesions. *Interven Cardiol* 1999; 12: 205-208.
- [16] C. W. Don, MD, I. Palacios, MD, K. Rosenfield, MD Use of Rotational Atherectomy in the Body of a Saphenous Vein Coronary Graft *J INVASIVE CARDIOL* 2009; 21: E168–E170.