

Case Report

Medium-Chain Acyl-CoA Dehydrogenase Deficiency (MCADD): A Case of Recurrent Vomiting and Diarrhea

Dian Sulistya Ekaputri*, I. Gusti Lanang Sidiartha, I. Gusti Ayu Putu Eka Pratiwi

Department of Child Health, Medical Faculty, Udayana University, Denpasar, Indonesia

Email address:

lanangsidiartha@yahoo.com (I. G. L. Sidiartha)

*Corresponding author

To cite this article:

Dian Sulistya Ekaputri, I. Gusti Lanang Sidiartha, I. Gusti Ayu Putu Eka Pratiwi. Medium-Chain Acyl-CoA Dehydrogenase Deficiency (MCADD): A Case of Recurrent Vomiting and Diarrhea. *International Journal of Genetics and Genomics*. Vol. 8, No. 4, 2020, pp. 127-132. doi: 10.11648/j.ijgg.20200804.12

Received: September 26, 2020; **Accepted:** October 10, 2020; **Published:** October 20, 2020

Abstract: Medium chain acyl-CoA dehydrogenase deficiency (MCADD) is the commonest fatty acid oxidation disorder. Patients usually presented between the ages of 4 months and 4 years with acute hypoglycaemic encephalopathy and liver dysfunction; some deteriorated rapidly and died. Symptomatic presentation of MCADD is precipitated by fasting due to infection, characterized by metabolic crisis, includes lethargy, vomiting, hypoketotic hypoglycaemia, and encephalopathy, and could progress to coma and death. MCADD is not part of new-born screening in Indonesia; children are likely to be missed if routine hypoglycaemia screening is not instituted. This is a case of an otherwise healthy 8-month-old baby boy who presented with recurrent infection followed by severe hypoglycaemia and cow's milk protein allergy presentation with some initial diagnostic dilemma. This study was to describe the clinical manifestation, workup diagnostic, and management in children with MCADD disorder. An eight-months-old boy came with recurrent hypoglycaemia following infections. Blood gas analysis showed acidosis metabolic with increase anion gap. Patient was moderate malnutrition due to recurrent illness. There was no consanguineous in his parents. Laboratory test revealed leucocytosis, hypoglycaemia, and metabolic acidosis. No ketone on urine sample. Short chain fatty acid decrease. Ig-E total increase and benzidine test positive. Dried blood spots and urine spot by liquid chromatography-tandem mass spectrometry revealed of MCADD. Patient was given intravenous fluid containing dextrose, treated by antibiotics for infection, and recovered after few days hospitalization. Patient was also given amino-acid-based formula and he responds was good. Parent were educated for the illness and told to avoided fasting for long period. Children with MCADD should remain under follow-up with a specialist Metabolic Paediatrician Consultant and Dietician with regular reviews in early childhood. Parents should be allowed direct access to the local hospital's paediatric service so that lengthy waits in emergency departments are avoided.

Keywords: MCADD, Children, Hypoglycemia

1. Introduction

Fat is an important source of energy and, because of its high energy density, it is the body's principal fuel store [1]. Fatty acids are used by heart muscle in preference to glucose and are the main fuel for skeletal muscle during sustained exercise. During prolonged fasting, most tissues derive energy from fatty acids, allowing glucose to be spared for the brain. As well as releasing energy, hepatic fatty acid oxidation provides acetyl-CoA for ketone body synthesis. By

using ketone bodies, even the brain can derive energy indirectly from fatty acids [1].

Medium-chain acyl-CoA dehydrogenase deficiency (MCADD) is an autosomal recessive disorder resulting from a defect of mitochondrial β -oxidation of medium-chain fatty acids [2]. It is one of the most common inborn errors of metabolism with an incidence of 1:15.000 in 8.2 million newborn worldwide [2] Metabolic demands that require more energy than available from glycogen stores, such as prolonged fasting, physical exercise, and intercurrent acute

illness, may produce symptoms that if are unrecognized could potentially lead to metabolic crisis [2].

The clinical presentation of MCADD may vary from severe. Patients with MCAD deficiency only present clinically if exposed to an appropriate environmental stress [1, 3]. Clinical symptoms in a previously apparently healthy child with MCAD deficiency include hypoketotic hypoglycemia and vomiting that may progress to lethargy, seizures, and coma triggered by a common illness [1]. Hepatomegaly and liver disease are often present during an acute episode [1]. Children appear normal at birth and if not identified through newborn screening, typically present between age three and 24 months, although presentation even as late as adulthood is possible. Furthermore, approximately 25% of individuals who are undiagnosed will die during the first metabolic crisis while anywhere from 30 to 40% will have some form of intellectual disability or developmental delay [1, 3].

Diagnosis of MCADD requires the integrated interpretation of array of tests, also considering the clinical status of the affected individual (acutely symptomatic vs asymptomatic) at the time of sample collection [4]. Initial testing involves the hypoglycemic screen which includes acylcarnitine (Guthrie card), urine organic acids, urine acyl glycine analyses [4]. The gold standard for diagnosis of fatty acid oxidation disorders is plasma acylcarnitine profile analysis performed by tandem mass spectrometry [4]. Further confirmatory testing can be by genetic testing (ACADM) mutation analysis or measurement of MCAD enzyme activity in leukocytes, fibroblasts [5]. Most children are now diagnosed through newborn screening.

MCADD is not part of newborn screening in Indonesia; children are likely to be missed if routine hypoglycemia screening is not instituted. This is a case of an otherwise healthy 8-month-old baby boy who presented with recurrent infection and allergic manifestation followed by severe hypoglycemia with some initial diagnostic dilemma.

We report a case of MCADD who presented in infancy period as a recurrent hypoglycemia. The objective of this paper is to describe the clinical manifestation, workup diagnostic, and management in children with MCADD disorder.

2. Case Illustration

Patient was having three episodes of severe hypoglycemia and acidosis requiring emergency treatment in hospital. First episode, at age of 3 months (October 2018), patient brought into emergency room of Sanglah Hospital due to shortness of breath for 10 hours before admission (13th October 2018). Shortness of breath was characterized by fast breathing, mild retraction of the chest wall. Patient looked cyanotic but improved after given oxygen. There was sound of crackling, but no wheezing. Shortness of breath was not relieved by sitting position nor worsened by supine position. Patient got history of productive cough and running nose 2 days before admission. Patient also got fever for 5 days before admission,

didn't relieve by antipyretic. Patient was said of having prolong diarrhea and vomiting in the last 10 days before admission. Diarrhea with a liquid consistency and not mixed with blood nor mucous. The patient was being fed with breast milk and cow's milk from birth. the patient has tried different types of cow's milk, but he still had diarrhea.

Second episode, at four months old (November 2018), he brought into emergency room Sanglah Hospital again. Patient was referred from Sanjiwani hospital with persistent diarrhea, metabolic acidosis, hyperkalemia due to suspected inborn error of metabolism, and hypernatremia. Patient had 2-weeks history of being diarrhea. The frequency was 7 times, with volume of each diarrhea is approximately 5 cc, the consistency is liquid, there is no pulp, mucus, or blood. In the last 5 days before admission, stool frequency becomes more, up to 12 times a day with a volume of 5 cc each time diarrhea. The color of stool was yellow. He complained of fever for 7 days before admission. The highest temperature measured was 38.5°C. The fever pattern was intermittent, decline with medicine but then raised again. Patient also had vomiting along with diarrhea. He had non-bilious vomiting after meal approximately five times a day with volume ½ spoons every vomiting. The vomit consisted of meal which he consumed. There was no history of bloody vomiting. The body weight decreased 0.6 kilograms in 2 months.

Third episode, at 8 months old (February 2019), patient also complained of having 24-hour history of diarrhea and vomiting, with same manifestation as before, frequency of diarrhea reached 20 times a day. He complained of fever for 2 days before admission. The highest temperature measured was 39°C.

Patient was the first child in the family, no history of congenital anomalies in her family. There was no consanguineous in his parents. No history of illness nor consuming any medicine during pregnancy period were noted. There was no abnormality during pregnancy or delivery. Patient had normal growth and development before he was sick. Patient were given formulated milk since birth. There was no history of overfeeding. His prenatal, natal, and postnatal history was normal. Family history revealed that his mother was having asthma.

In physical examination of the last hospitalized (February 2019), vital sign found tachypnoea with kussmaul-type breathing, tachycardia, blood pressure within normal limit. Patient appeared irritable, looked thirsty, sunken anterior fontanelle (+), the head was normal in shape. There were sunken eyes (+), tears (+), no jaundice on sclera, nor conjunctiva injection, and anemia. The pupils light reflex was normal, and size were equal. Mouth was dry (+), the ears, nose, and throat examination were in normal limit. There were no lymph nodes enlargement on the neck or supraclavicular. The chest was symmetrical both on rest and movement. Breath sound was vesicular without rales or wheezing. The first and second heart sound were normal, regular and no murmur in auscultation. There were no lymph nodes enlargement on both of axilla. Abdomen wasn't distended. Peristaltic activity was increase on auscultation. There was no tenderness nor

palpable mass. Liver and spleen were no palpable. Skin turgor was poor. Extremities were cold, capillary refill was delayed. There was no oedema on extremities or lymph nodes enlargement on both of inguinal. Anal fissure and perianal erythema were found, genital examination was normal. Anthropometric status of patient was 74% (moderate protein-energy malnutrition) based on Waterlow.

Laboratory test revealed leukocytosis (17.38 $10^6/\mu\text{L}$); neutrophil 4.91 $\text{K}/\mu\text{L}$ (28.2%) lymphocyte 5.09 $\text{K}/\mu\text{L}$ (65.0%), hemoglobin 10.6 g/dL (MCV 89.8 fL; MCH 28.5 pg; MCHC 31.7 g/dL), hematocrit 33.4%, platelet 392 $\text{K}/\mu\text{L}$, procalcitonin 0.65. Sodium 153.55 mmol/L, potassium 2.67 mmol/L, chloride 118.96 mmol/L, and calcium 10.96 mmol/L. Blood gas analysis showed pH 7.085, pCO₂ 20.9 mmHg, pO₂ 144 mmHg, base excess -24 mmol/L, HCO₃⁻ 6.3 mmol/L, TCO₂ 7 mmol/L, SO₂c 98%. Anion gap 28.3 mmol/L. Blood glucose was 17 mg/dL, lactate serum was normal 2.04 mmol/L. Short chain fatty acid was decreased (1 mg/ml). On the three episodes of hospitalized, patient was consistently marked with hypoglycemia and acidosis. Urinalysis was showed ketone negative in every admission. Fecal Occult Blood Test (FOBT) test was positive. Blood culture on third admission was showed *Escherichia coli*. Fecal culture found no bacteria, total short-chain fatty acid was 1 mg/ml. Patient underwent dried blood spots and urine spot by liquid chromatography-tandem mass spectrometry. Sample was sent to Japan and revealed secretion of dicarboxylic acid (adipic suberic and sebacic acids) and decreasing acylcarnitine due to Medium-chain acyl-CoA dehydrogenase deficiency (MCADD) disorder. Measurement for determining the allergic condition was Ig-E total increase 53.3 (normal range less than 29), while the Ige panel was not detected.

Based on the clinical manifestation, physical finding, and workup diagnostic, the patient was diagnosed with Medium-chain acyl-CoA dehydrogenase deficiency (MCADD) presenting with recurrent diarrhea and vomiting and moderate protein-energy malnutrition. Emergency treatment to this patient was to treat the hypoglycemia and metabolic acidosis as fast as possible. The treatment of hypoglycemia in an emergency is through the intravenous route. This hypoglycemia also happened caused by the allergic condition to cow's milk. During hospitalization, maintaining euglycemia with intravenous fluids until oral feeding is optimally established and is the standard protocol. The rest of treatment given was based on the infection condition which caused the patient hospitalized. This patient was then treated with amino-acid-based formula to prevent diarrhea presence and the responds was good. The FOBT test also showed negative result. The main stay in the treatment of MCADD is avoidance of fasting and home care plan for caregivers in cases of illnesses. In this case, MCADD was precipitating by allergic disease so that the treatment of allergic disease should be the health care focus.

3. Discussion

The first MCADD patients were identified in 1982, and

between 1982 and 1994, more than 200 MCADD patients were identified [6]. Medium-chain acyl-CoA dehydrogenase deficiency (MCADD) is an autosomal recessive disorder of mitochondrial beta oxidation of medium chain length fatty acids. It is caused by mutations in the ACADM gene [6].

The disorder is pan-ethnic but more common in Caucasians with an incidence of 1 in 6000 to 10 000. 60-80% of symptomatic patients are homozygous for the c.985A > G missense mutation [6]. A further 15-20% are compound heterozygous for c.985A > G in combination with another mutation [6]. The prevalence of the common mutation likely reflects a founder effect and MCADD is thought to have originated in northwest Europe [6]. The genotypes in those detected by newborn screening are more diverse suggesting that some mutations are of less clinical significance. However, at present it is wise to assume that an individual with any mutation associated with persistent abnormal biochemistry is at risk from clinical illness caused by MCADD [6].

The numbers of MCADD cases observed have been consistently lower than the number expected [7]. Two hypotheses have been offered to explain this lower than expected number of cases [7]. First, symptomatic newborns may be misdiagnosed as having SIDS or Reye's syndrome or may die before MCADD is detected [7]. Second, a substantial number of people with MCADD may be asymptomatic and unidentified, suggesting a penetrance of <100% [7]. Although misdiagnosis and early deaths may account for some unidentified cases, they are not likely to account for all of them. In this case, patient was misdiagnosed as severe hypoglycemia due to low intake only. Patient was suspected of having MCADD at the third episode of hospitalization.

Clinically, MCAD deficiency can present as sudden death as the result of a mild, intercurrent illness, when the body is not able to effectively mobilize fatty acids in response to fasting [8, 9]. Patients with MCAD deficiency may be normal at birth and only present with the classic clinical features when exposed to periods of stress such as prolonged fasting or vomiting precipitated by active infection [4]. These typically present in the first 2 years of life with transient episodes of hypoglycemia and sometimes with seizures or coma during periods of acute decompensation related to changes in diet when weaning the infant off breastfeeding or off night-time feeds or during infections like upper respiratory tract infections or viral gastroenteritis [3, 4]. It also stated that between the ages of 3 and 24 months, the child experiences their first 'fast' associated with an intercurrent infection or being placed nil by mouth prior to a surgical procedure. Patients may also present with cardiomegaly (usually hypertrophic), arrhythmias or myopathy [3, 4]. The cardiac presentation typically occurs within weeks while myopathy typically occurs after infancy. In this case, patient deteriorates following respiratory infection and viral gastroenteritis. Due to infection, he just took small amount of breastfeed and milk formula especially in the night.

Precipitating factor for recurrent hypoglycemia in this patient was allergic condition. Cow's Milk Protein Allergy (CMPA) is the most common food allergy in infants and

young children, with a prevalence of 2% to 3% in the general population [10]. Allergic reactions to cow's milk may be categorized as Ig-E-mediated, non-Ig-E-mediated, and mixed types [10]. In infancy, there is no definitive means of differentiating Ig-E and non-Ig-E mediated CMPA, owing to significantly overlapping presentations; however, quick onset symptoms are almost always Ig-E mediated [10]. Symptoms and signs of CMPA usually involve skin, gastrointestinal and respiratory tracts. Gastrointestinal tract manifestations of CMPA are nonspecific and the only type that can be diagnosed in all age groups [10]. When diagnosis is delayed, the allergy may impair the growth and quality of life and even be life-threatening [10]. In this case, patient was on regular formula then presented with prolong diarrhea and dehydration. CMPA was diagnosed based on history, serum Ig-E test was

increase, and rapid response to amino-acid-based infant formula. It could be concluded this patient was having mixed type CMPA. The breast milk was not stopped, as the mother's diet was reconfigured as a cow's milk protein-free diet. Upon admission, our patient presented a moderate degree of protein energy malnutrition. At the last follow-up examination at 24 months, he was thriving on a regular diet, with normal growth.

Evaluation of persistent hypoglycemia should include thorough examination. First, we have to determine whether it followed by acidemia (pH levels below than 7.30, $pCO_2 < 30$ mmHg, $HCO_3^- < 15$ mmol/L) or not. After that, we need to evaluate lactate and ketone bodies in blood and/or urine. Then we can determine the type of inborn error of metabolism in the patient (Figure 1) [1].

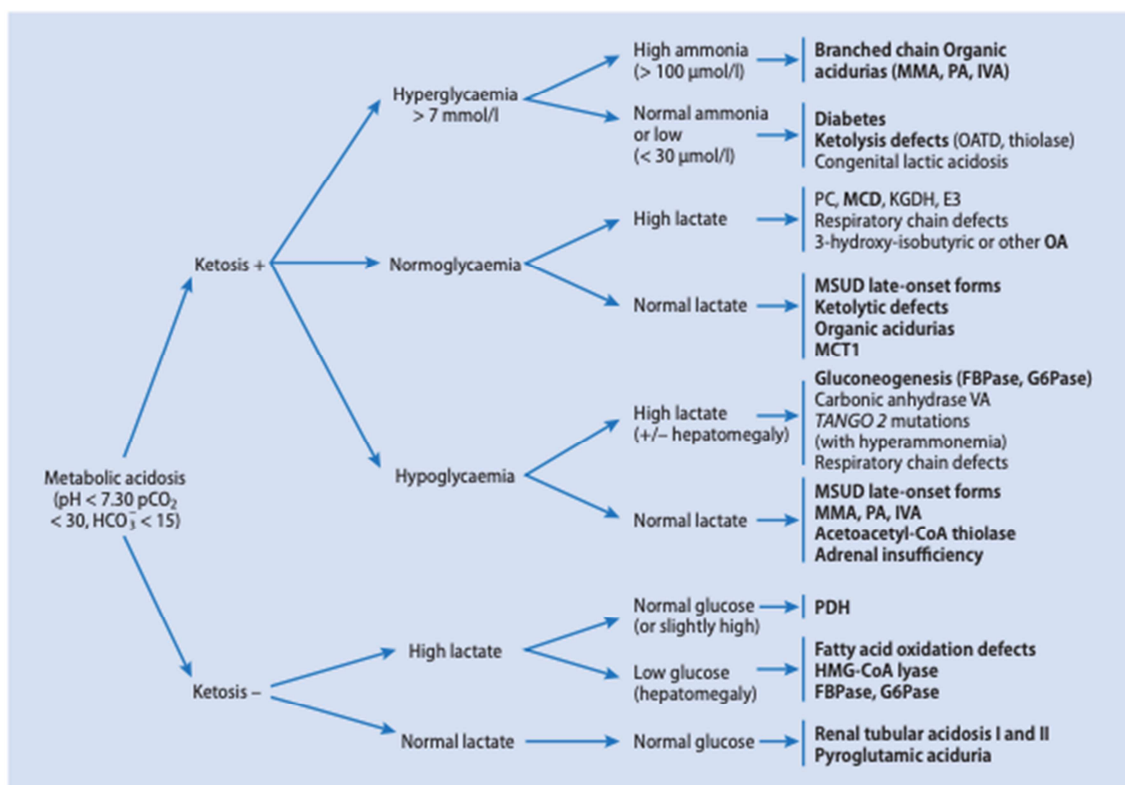


Figure 1. Metabolic acidosis. E3, lipoamido oxido reductase; FBP, fructose bisphosphatase; G6P, glucose-6-phosphatase; HMG-CoA, 3-hydroxy-3-methylglutaryl coenzyme A; IVA, isovaleric acidemia; KGDH, alpha-ketoglutarate dehydrogenase; MCD, multiple carboxylase deficiency; MCT1, monocarboxylate transporter1; MMA, methylmalonic aciduria; MSUD, maple syrup urine disease; OATD, oxoacid CoA trans-ferase; PA, propionic acidemia; PC, pyruvate carboxylase; PDH, pyruvate dehydrogenase; SCAD, short chain acyl-CoA dehydrogenase; bold face, treatable disorders.¹

In the case of MCADD, the classic laboratory presentation is hypoketotic hypoglycemia [1]. It is important to recognize that the child may have developed an acute encephalopathy prior to the fall in blood glucose, which can lead to diagnostic confusion [6]. Tests done at the time will show evidence of hepatocellular dysfunction, hypoglycemia, hypo ketosis (although the presence of ketones does not exclude the diagnosis) and mild-moderate hyperammonemia [1, 6]. In unscreened populations up to 25% of patients with MCADD have died in their first episode. Sudden unexpected death in infancy (SUDI) may be caused by undiagnosed MCADD but it is not a cause of true Sudden Infant Death Syndrome (SIDS);

generally, there is always a preceding illness associated with poor feeding [6]. In this case, patient was found with severe hypoglycemia in each episode of hospitalization, blood gas analysis showed acidosis in every episode of admission, complete blood count showed leukocytosis, short chain fatty acid was decrease (1 mg/ml), and urine examination showed no ketone bodies.

The main technologies available for detecting individuals with MCADD involve the detection of abnormal biochemical markers in the blood or urine [4]. Tandem mass spectrometry (MSIMS) detects abnormal metabolites mainly in blood samples. Although MSIMS is used as an initial screening

modality, confirmation of MCADD diagnosis is conducted with urine organic acid profile and/or DNA mutation analysis [4]. Dicarboxylic aciduria is an important diagnostic element and detection of urinary acylglycines (hexanoylglycine, phenylpropionylglycine, and suberylglycine) are traditional and accurate diagnostic methods for MCADD [4]. Confirmation of MCADD through blood samples and dried-blood spots can be conducted with DNA-PCR technology [4]. MS/MS is the most recent technology developed and the most suitable for large-scale population screening for MCADD [4]. MS/MS detects octanoylcarnitine and other acylcarnitine in blood and is currently the method used in a supplemental screening program offered by a private company that screens most newborns in Pennsylvania and eastern Ohio [4]. MS/MS is also the method of choice for North Carolina, California, and Massachusetts in their expanded newborn screening programs that will include screening for MCADD [4]. In this case, the patient was found with low level of short-chain fatty acid and underwent MS/MS from blood and urine sample revealed decrease acylcarnitine, due to MCADD disorder.

The goal would be to reverse hypoglycemia and to treat comorbidities. Major therapeutic goal is to reverse catabolism and sustain anabolism [6, 12]. The current treatment would include administering intravenous fluid bolus with 10% dextrose at 2 ml/kg in neonates or larger boluses in older children followed by D10% maintenance fluids. Some sources have used 12–15 mg/kg/min of glucose. It is important to not use intralipids in the acute presentation. In this case, patient was getting better after given dextrose intravenous maintenance and antibiotics for infection.

For long term therapy, the goal would be to stop fat catabolism by preventing further fatty acid oxidation. The initial steps would be the prevention of hypoglycemia in periods of catabolic stress by using frequent feeds and clinical supervision during periods of illnesses [4, 14, 15]. A low fat, high carbohydrate diet is recommended. Dietary fat restriction is not indicated in MCAD deficiency and mild long-chain FAODs recently identified by newborn screening [5]. Long chain fat, however, needs to be restricted in severe long chain FAODs and substituted by medium-chain triglycerides [5]. Hospital admission is recommended for procedures that would require the patients to take nothing orally for more than 8 hours, especially if less than 1 year of age [5]. Carnitine is undisputedly effective in patients with carnitine transporter deficiency [11, 14]. Liver transplantation may be the ultimate consideration if there is no evidence of neurological disease or other systemic involvement that may impair recovery and return to baseline function [10]. In this case, the patient had recurrent hypoglycemia due to undiagnosed the cause of hypoglycemia. The parent already told to avoid prolong fasting of more than 12 hours in order to prevent the recurrent hypoglycemia.

Frequent, regular feeds are recommended during the first year of life, but subsequently overnight fasting can be tolerated in most disorders [1]. In severe FAODs, overnight fasting is avoided until later in childhood, to reduce the risk of

cardiomyopathy and long-term complications [1]. These patients may be managed with continuous overnight tube feeding, with extra feeds during the night or, when older, with uncooked corn starch before bed. MCT is contraindicated in MCAD, ETF and ETFQO deficiencies because medium-chain fatty acids enter mitochondria rapidly, bypassing the normal regulation at CPT I, and cannot be oxidized [1]. Dietary fat restriction is unnecessary in MCAD deficiency and breast feeding should be allowed. In this case, the parent was told to give regular feeds and continue breastfeed.

Failure to thrive, seizure disorders, cerebral palsy, and Attention Deficit Disorder (ADD) have also been reported as long-term outcomes among MCADD patients. A strong correlation existed between seizure at onset and cerebral palsy. Patients with ADD were more likely to have had seizures, encephalopathy, and hyperammonemia at the time of onset, as well as more episodes of clinical illness before and after diagnosis. Patients are at risk of acute metabolic decompensation during times of physiological stress, such as prolonged fasting and viral illness, with high morbidity and risk of mortality [13-15]. Early diagnosis is critical because most adverse outcomes are preventable with long-term therapy [12]. In this case, the patient was not having neurologic problem but having moderate malnutrition. Long term follows up at outpatient clinic was needed in order to catch up the growth and development.

4. Conclusions

An eight-months-old boy came with recurrent hypoglycemia following infections and recurrent episodes of diarrhea. Blood gas analysis showed acidosis metabolic with increase anion gap. Patient was on moderate malnutrition due to recurrent illness. There was no consanguineous in his parents. Patient had normal growth and development before he was sick. Laboratory test revealed leukocytosis, hypoglycemia, normal lactate, and metabolic acidosis. No ketone on urine sample. Short chain fatty acid decrease. Dried blood spots and urine spot by liquid chromatography-tandem mass spectrometry revealed of Medium-chain acyl-CoA dehydrogenase deficiency (MCADD) disorder. IgE-total was increased and FOBT test was positive. Patient was given intravenous fluid containing dextrose, treated by antibiotics for infection, and recovered after few days' hospitalization. Patient was given amino-acid-based formula and continued the breast milk. Parent were educated for the illness and told to avoid fasting for long period. Children with MCADD should remain under follow-up with a specialist Metabolic Pediatricians Consultant and Dietician with regular reviews in early childhood. Once middle childhood is reached, yearly reviews are usually sufficient. Parents should be allowed direct access to the local hospital's pediatric service so that lengthy waits in emergency departments (where there may be little awareness of the necessity of rapid treatment) are avoided.

Acknowledgements

None declared.

References

- [1] Saudubray, J. M., Baumgartnes, M. R.. (2016). Inborn metabolic diseases. 6th ed. Berlin: Springer; p. 203-14.
- [2] Drendel, H. M., Pike, J. E., Schumacher, K., Ouyang, K., Wang, J., Stuy, M., et al. (2015). Intermediate MCAD deficiency associated with a novel mutation of the ACADM gene. *Case Rep Genet.* 532090.
- [3] Maduemem, K. E.. (2016). Medium-chain acyl-coenzyme A dehydrogenase deficiency (MCADD): a cause of severe hypoglycemia in an apparently well child. *BMJ Case Rep.* bcr2016217538.
- [4] Vishwanath, V. A. (2016). Fatty acid beta-oxidation disorders: a brief review. *Ann Neurosci.* 23 (1): 51-5.
- [5] Merritt, J. L, Norris, M., Kanungo, S. (2018). Fatty acid oxidation disorders. *Ann Transl Med.* 6 (24): 473-87.
- [6] Jameson, E and Walter, J. H. (2019). Medium-chain acyl-CoA dehydrogenase deficiency. *Ped and Child Health.* 29 (3): 123-6.
- [7] Prasad, C., Speechley, K. N., Dyack, S., Rupar, C. A., Chakraborty, P., Kronick, J. B. (2012). Incidence of medium-chain acyl-coa dehydrogenase deficiency in Canada using the Canadian Paediatric Surveillance Program: Role of newborn screening. *Paediatr Child Health.* 17 (4): 185-9.
- [8] Hall, P. L., Wittenauer, A., Hagar, A. (2014). Newborn screening for medium chain acyl-CoA dehydrogenase deficiency: performance improvement by monitoring a new ratio. *Mol Genet Metab.* 113 (4): 274-7.
- [9] Lau, N., Duran, M., Gibson, K. M., et al. (2014). *Physician's Guide to the Diagnosis, Treatment and Follow-Up of Inherited Metabolic Diseases.* Springer. p. 247–264.
- [10] Alharbi, A., Albelowi, A., Alsharif, A., Alsharif, E., Hasosah, M. (2018). Cow's Milk Protein Allergy Presented with Generalized Edema: Case Report and Review of the Literature. *J Gastroenterol Hepatol Endosc.* 3 (1): 1039-42.
- [11] Longo, N., Frigeni, M., Pasquali, M. (2016). Carnitine transport and fatty acid oxidation. *Biochim Biophys Acta.* 1863 (10): 2422-35.
- [12] Karaceper, M. D., Khangura, S. D., Wilson, K., Coyle, D., Brownell M., Davies, C. et al. (2019). Health services use among children diagnosed with medium-chain acyl-CoA dehydrogenase deficiency through newborn screening: a cohort study in Ontario, Canada. *Orphanet J Rare Dis.* 14 (1): 70-80.
- [13] Uleanya, N. D., Aniwada, E. C., Nwokoye, I. C., Ndu, I. K., Eke, C. B. Relationship between Glycemic Levels and Treatment Outcome among Critically Ill Children admitted into Emergency Room in Enugu. *BMC Pediatr.* 2017: 126-33.
- [14] Alfonso, C. S., Bennet, M. J., Ficicioglu C. (2016). Screening for medium-chain acyl CoA dehydrogenase deficiency: current perspectives. *Research and Reports in Neonatology.* 1 (1): 1-10.
- [15] Fox, A., Brown, T., Walsh, J., Venter, C., Meyer, R., Nowak-Węgrzyn, A., et al. (2019). An update to the Milk Allergy in Primary Care guideline. *Clinical and translational allergy.* 9 (40): 1-10.