
Modern methods of radiological diagnostics at the primary syndrome of the low back pain

Tatyana Tchernysheva

Orenburg Medical Academy, Orenburg, Russia

Email address:

zaitv@yandex.ru

To cite this article:

Tatyana Tchernysheva. Modern Methods of Radiological Diagnostics at the Primary Syndrome of the Low Back Pain. *International Journal of Medical Imaging*. Vol. 2, No. 3, 2014, pp. 69-76. doi: 10.11648/j.ijmi.20140203.15

Abstract: Radiological, ultrasonic methods of research and magnetic resonance tomography help estimate changes of internal structures of a lumbar department of a backbone at primary syndrome of the low back pain and compare importance of these methods. Materials and methods: 100 patients have been included in research from chronic and 100 patients with sharp vertebral low back pain (LBP) and group of comparison (100 persons). All patients have passed clinically - tool examination: radiography, MRI and ultrasound of a lumbar department of a backbone. 76 patients were carried out MPT. Ultrasound of a lumbar department of a backbone was appointed before treatment (in 3 weeks). Results: The surveyed patients according to ultrasound had changes of internal backbone structures most often as disk protrusion. The greatest quantity of protrusions was diagnosed in patients with chronic LBP that were asymptomatic. Sharp LBP was most often caused by a nervous radical compression with hernia. In a group of practically healthy persons the percent of diagnosed disk protrusions was small. A positive clinical change by the end of treatment in patients with sharp and chronic LBP was combined with the reduction of quantity and protrusion sizes. Restoration of epidural and paravertebral blood flow was a good prognostic criterion of treatment efficiency. Research has shown high importance of ultrasound of a lumbar department of a backbone that can act as a screening method of diagnostics of primary syndrome of low back pain at an out-patient - polyclinic stage. The received about 90 % concurrence with MPT data testifies to comparability of results and expediency of wider introduction of ultrasound of a backbone in practice of public health service.

Keywords: Pain in a Back, Ultrasound (US) of a Backbone, MRI, Radiography

1. Introduction

The lumbar pain (low back pain - LBP, lumbago) has the high medical and social importance both for patients and society. Not less than 60-80 % of the population, at least, once in a life feels a lumbar pain [2]. In the International Classification of Diseases X of LBP revision it is included in a section "Bone-muscular system illnesses" (XIII class), that testifies to reference of the given pathology to the competence of rheumatologist [9].

On etiological sign the causes of primary syndrome of LBP is divided into vertebral (degenerate - dystrophic processes in a backbone - an osteochondrosis, spondyloarthrosis, the congenital or got deformations - a scoliosis, displacement of bodies spondyle - spondylolisthesis) and non vertebrates (changes on the part of the muscular-copular device, a muscular-tonic syndrome) [13].

On duration of a painful syndrome sharp (till 3 weeks), sub acute (till 6 weeks), chronic (more than 6 weeks) LBP

syndromes are distinguished. Latter represents the delayed sequence of a sharp pain and in it, as a rule, there is vertebral muscular - tonic syndrome. This group of patients is characterized by an adverse prognosis for recovery and it takes up to 80 % of all expenses of public health service on LBP treatment [11, 12]. A serious obstacle for the approaches to the problem of pain physiopathology of lumbosacral localizations is the impossibility in most cases to establish precisely a source of painful impulse.

Diagnostics of the diseases which are included in a circle of primary syndrome LBP, is based on a clinical picture and additional methods of ray diagnostics the basic and more accessible from them remains roentgenography (Rg) [16, 24]. Radiographic manifestations of degenerate - dystrophic changes in lumbosacral department include:

- decrease in height of a disk;
- subchondral osteosclerosis;
- formation of osteophytes;
- arthrosis of intervertebral joints;

-change of the form of spondyles, displacement of spondyles;
 -a degree of a curvature of an axis of a backbone (scoliosis).

Roentgenography with functional tests allows revealing instability of separate segments [5]. Signs of osteochondrosis and spondylarthrosis on the data of roentgenography of a lumbosacral department of a backbone are found out almost in the half of middle-aged persons and in the majority of elderly patients. However it is known, that expressiveness of these changes does not correlate with a clinical picture and does not exclude other reasons of pains in a back (protrusion a disk - extrusion a fibrous ring for bodies contiguous spondyles, intervertebral hernias, narrowing of the spinal channel, epiduritis, liguamentitis a yellow sheaf) and cannot be a basis of the clinical diagnosis, and also determine medical and expert tactics [8, 11].

Progress of diagnostic technologies has allowed to plan last years transition from radiological methods of research of a backbone, to the techniques which are not carrying beam loading and considerably more effective in visualization chancroidal of structures. One of them is magnetic resonance tomography (MRT) [15, 22, 23].

MRT allows to reveal and effectively estimate:

A status, structure and a degree of dehydration of pulpous nucleus of intervertebral disk,

It is easy to reveal breaks and cracks of a fibrous ring,

Displacement pulpous nucleus even at small protrusion a disk,

Without effort to reveal small (up to 2 mm) hernias of disks,

To determine a degree of a hypostasis and venous of stasis in epidural and surrounding fat,

A degree of a compression radix's and dural a bag,

To make simultaneously a rating of a status of any segment of a backbone.

Secondary changes in bodies' spondyles and arcuate the joints, capable to call compressive a syndrome are accessible to her also. The method allows in dynamics, at a quantitative level, to estimate results of any conservative or surgical methods of treatment. At interpretation of data MRT a lumbosacral department high sensitivity of a method revealing a pathology disks is marked. Approximately at 50 % asymptomatic persons by results of MRT changes of disks come to light: dehydration, and hernias. At the same time, magnetic resonance tomography has high cost and the best among all modern tool diagnostic methods cost itself inspection [1, 15, 22, 23].

By one more tool method of diagnostics which are not carrying beam loading for the patient and which opportunity else completely are not exhausted in connection with occurrence Doppler technologies, is ultrasonic research of a backbone [5]. Sensitivity and specificity of echography a lumbar department to an attribute «the hernia of a disk » makes accordingly 90, 2 % and 93 %. The given method yet has not received a wide circulation and in the literature practically there are no jobs under the comparative analysis of results of ultrasonic of a backbone and other methods of

research. However there are data on concurrence of MRT and ultrasound results in diagnostics of intervertebral hernias which makes 87, 4 % [6].

Aim- with the help of radiological, ultrasonic methods of research and a magnetic resonance tomography to estimate changes of internal structures of a lumbar department of a backbone at initial syndrome of the low back pain and to compare importance these methods.

2. Materials and Methods

200 patients with the primary syndrome of LBP, addressed to polyclinic of the municipal clinical hospital № 5 of Orenburg. All patients had able-bodied age and on clinical displays have been divided into 2 groups on 100 person (таблица1): I group - patients with chronic LBP (average duration of an aggravation $4,04 \pm 1,74$ months); II group - patients with sharp vertebral LBP (average duration - $1,67 \pm 0,79$ weeks).

In I group patients of more advanced age have come. Groups have been comparable on a floor and in them women prevailed. Half of patients in each group did manual work a various degree of weight. The average experience of job was a little bit higher in I to group. In II group persons with spondylitic radiculopathy and bilateral lumbar ishialgia prevailed.

The majority of patients I and II groups had II Rg a stage of an osteochondrosis of a lumbar department of a backbone. The quantity of patients with spondylarthrosis and spondylolisthesis in each group was individual. 22%-29 % of patients had a scoliosis of a lumbar department of a backbone.

At clinical examination of each patient it was estimated on 9 symptoms (Shobera, Kushelevsky, Lasega, Bragara, Tomayera, Otto, Genclena, Patrick, Razdolsky). The average amount of positive symptoms was higher in II group. More expressed painful syndrome on VAS patients of this group also had.

To all patients of groups I and II: roentgenography survey in 2 projections, ultrasound of a lumbar department of a backbone in dynamics (prior to the beginning and in 21 day of treatment) were done. For exclusion of secondary syndrome of LBP all of them have also been done the ultrasound of bodies of abdominal cavity, consultations of the gynecologist and the neurologist have been carried out.

Ultrasound of a lumbar department of a backbone was spent on device "Diasonic" (USA) with use convex the electronic gauge with working frequency of 3,5 MHz. For a rating of speed of a blood-groove in epidural and juxtaspinal venous textures the gauge with frequency of 2,25 MHz with power Doppler the channel was used. Research was spent in 2 planes - longitudinal and horizontal by a technique described in the monography of A.J.Kinzerskogo with all. [5].

For exception of hyperdiagnostics of changes on the part of internal structures of a lumbar department of a backbone the method of ultrasonic surveys the group of comparison consisting of practically healthy 100 people, not having in

the anamnesis and complaints not showing at survey on LBP. women (table 1). This group was younger age, with an equal parity of men and

Table 1. The clinical characteristic of patients with the primary syndrome of the pain in the low back pain

Parameters	I group (n = 100)	II group (n = 100)	Group of comparison (n=100)
Middle age (M ± DS), years	49,67±11,14 *,**	44,94±10,31 *, ⁰	28,18±2,93 **, ⁰
A floor: men	25 per./ 25 %	27 per./ 27 %	49 per./ 49 %
Women	75 per./ 75 %	73 per./ 73 %	51 per./ 51 %
Average duration of an aggravation (M±DS)	4,04±1,74 month	1,67 ± 0,79 weeks	-
The clinical diagnosis			
<i>Lumbago</i>	23 per./ 23 %	2 per./2 %	-
<i>lumbar ishialgia</i>	60 per./ 60 %	67 per./67 %	-
<i>spondylarthrosi sradiculopathy</i>	17 per./ 17 %	31 per./31 %	-
A radiological stage of an osteochondrosis			
I	29 per./29 %	34 per./34 %	-
II	54 per./54 %	57 per./57 %	-
III	17 per./17 %	9 per./9 %	-
Quantity of patients with spondylarthrosis	9 per./9 %	3 per./3 %	-
Quantity of patients with a scoliosis (on x-ray)	25 per./25 %	22 per./22 %	-
Quantity of patients with spondylolisthesis (on x-ray)	6 per./6 %	8 per./8 %	-
<i>L₃ spondyle</i>	2 per./33,3 %	1 per./12,5 %	-
<i>L₄ spondyle</i>	2 per./33,3 %	3 per./37,5 %	-
<i>L₅ spondyle</i>	2 per./33,3 %	4 per./50 %	-
Average quantity of clinical symptoms (M±SD)	4,71 ± 1,21 *	7,09 ± 1,56 *	-
An average indice on VAS (M ± SD), sm	4,25 ± 1,32 *	6,99 ± 1,89 *	-

The note: *, **, 0 - authentic distinctions between parameters in groups (p <0, 05)

76 patients (36 persons from I groups, 40 persons from II group) it was spent MRT a lumbar department of a backbone on the device «MAGNETOM OPEN VIVA» firms «SIEMENS» (Germany).

Statistical processing of results of research is executed with the help of the program "STATISTICA" (Version 6.0).

3. Results and Discussion

According to ultrasonic of a lumbar department of a backbone practically at all patients I and II groups were determined protrusion a disk (table 2).

Table 2. Results of ultrasonic research of the lumbar department of the backbone at patients with the primary syndrome of the pain in the low back pain

Parameters	I group (n = 100)	II group (n = 100)	Group of comparison (n=100)
Quantity of patients with protrusions	99 per./99 %	98 per./98 %	28 per./28 %
<i>1 protrusion</i>	19 per./19,2 %	15 per./15,3 %	28 per./100 %
<i>2 protrusions</i>	34 per./34,2 %	66 per./67,3 %	-
<i>3 protrusions</i>	32 per./32,3 %	16 per./16,3 %	-
<i>4 protrusions</i>	11 per./11,1 %	1 per./1,1 %	-
<i>5 protrusions</i>	3 per./3,2 %	-	-
Localization protrusions			
<i>L₁ - L₂ a disk</i>	23 per./9,3 % *	13 per./6,7 % **	-
<i>L₂ - L₃ a disk</i>	33 per./13,4 % *	14 per./7,2 % **	-
<i>L₃ - L₄ a disk</i>	66 per./26,7 %	54 per./27,7 %	-
<i>L₄ - L₅ a disk</i>	62 per./25,1 %	60 per./30,7 %	-
<i>L₅ - S₁ a disk</i>	63 per./25,5 % *	54 per./27,7 % **	28 чел./100%*,**
Quantity of patients with hernias	20 per./20 %	33 per./33 %	-
<i>1 hernia</i>	19 per./95 %	31 per./93,9 %	-
<i>2 hernias</i>	1 per./5 %	2 чел./6,1 %	-
Localization of hernias			
<i>L₁ - L₂ a disk</i>	1 per./5 %	-	-
<i>L₂ - L₃ a disk</i>	4 per./20 %	-	-
<i>L₃ - L₄ a disk</i>	6 per./30 %	8 per./24,2 %	-
<i>L₄ - L₅ a disk</i>	6 per./30 %	11 per./33,3 %	-
<i>L₅ - S₁ a disk</i>	3 per./15 % *	14 per./42,5 % *	-
Quantity of the patients having a combination of hernias with protrusions	20 per./ 20 %	33 per./ 33 %	-
Quantity of patients with spondylolisthesis	11 per./11 %	8 per./8 %	-
<i>L₃ a disk</i>	2 per./18,2 %	1 per./12,5 %	-
<i>L₄ a disk</i>	4 per./36,4 %	4 per./50 %	-
<i>L₅ a disk</i>	7 per./45,4 %	3 per./37,5 %	-

The note: *, ** - authentic distinctions between parameters in groups (p <0, 05)

At patients of II group in 67,3 % of cases was present 2 protrusion a disk, at patients I of group - in 46,6 % of cases was more than 3 protrusion a disk. These changes were located at levels L4-L5, L5-S1 is more often. The average sizes protrusions were practically identical in all groups and authentically did not differ. The average quantity protrusion, falling 1-st patient, was higher in I to group. Intervertebral hernias in the greater percent of cases have been revealed at patients to II group where their more often localization level L5-S1 was. In this group there was no hernia on the top lumbar disks. In I to group patients had localizations of hernias at all levels, but in 60 % of cases it there were disks L3-4, L4-5. The average quantity of the hernias falling of 1-st patient was higher in II group. All patients of both groups had a combination of hernial educations with protrusion intervertebral disks at nearby levels of a lumbar department of a backbone. In connection with absence of the standard classification at a rating of the sizes hernial extrusion we counted their size up to 0,3 sm, as small, from 0,4 up to 0, 6 sm - average, more than 0, 7 sm - big.

According to ultrasonic of 11 % of patients I of group and 8 % of patients of II group had spondylolisthesis, that practically coincided (for II group) with results of Rg-inspection. In both groups there was a displacement of bodies позвонков L4 and L5 is more often.

At ultrasonic of a lumbar department of a backbone at persons of group of comparison in 28 % of cases (is more often at men) have been revealed median protrusion a disk up to 0,2 sm on L5-S1. As the given disk carries the greatest loading it is considered, that such small protrusion at this level at ultrasonic is not diagnostic significant [3]. Besides at such changes there is only a small narrowing of the spinal channel, and radicular channels remain intact. It is necessary to note, that despite lacking clinical attributes of an osteochondrosis, at ultrasonic 88 persons of group of comparison had structural changes of a fibrous ring as a small fragmentation on disk L5-S1, at 41 persons - on disk L4-5 that testified to early attributes of formation of this pathology

At a rating a velocity by results of ultrasonic at various pathological processes changes also are revealed. At protrusion disks of any localization and expressiveness at preservation of integrity of a fibrous ring epidural the velocity at a level of a disk did not change and on the average made $3,53 \pm 1,12$ sm/sec (norm of 3-5 sm/sec).

Parameters epidural a velocity at healthy persons are borrowed from the literature [4, 18].

At paramedian the hernias causing a compression nervous radicle, the venous velocity disappeared on the side of defeat and amplified at an overlying level. This phenomenon, probably, is caused by inflow of blood from collateral zones about what there are in the literature data [4, 5, 6, 7].

At research epidural a velocity at patients I of group at levels with it is long existing hernias at dopplerography the vessels growing into a disk through a hernias gate with expressed branching in a projection of break of a fibrous ring came to light. Also, at all patients having a significant fragmentation of a fibrous ring and reduction of the sizes of a disk, the vessels borrowing all projection pulpal of a nucleus, irrespective of presence in the anamnesis of a hernia of a disk were visualized. Apparently, it sonograph a marker of replacement of specific substance of a disk a fibrous fabric. Vessels thus can grow not only through a hernia gate, but also through microcracks of a fibrous ring without education of a hernia of a disk.

At a rating of a velocity on juxtaspinal to venous textures there were changes, as well as at research epidural vessels. So, at protrusion a disk irrespective of localization and expressiveness the velocity did not change and on the average for all levels made $12,36 \pm 2,14$ sm/sec (norm of 10-15 sm/sec) [4, 18]. At presence of a compression nervous radicle, more often paramedian a hernia of a disk, in a zone of defeat he was asymmetrically reduced up to $5,04 \pm 1,66$ sm/sec. With amplification at an overlying level.

Practically at all patients I and II groups past MPT, were diagnosed protrusion a disk (table 3). Were patients with 3-мя protrusion with their most often localization at levels L4-5, L5-S1 more. The average sizes protrusion considerably did not differ in groups and coincided with results of ultrasonic of a lumbar department of a backbone (table 4). On MPT patients by whom according to ultrasonic the diagnosis intervertebral hernias were exposed went without fail. However with help MPT in I to group 3 more patients, and in II group - 1 patient with similar changes have been revealed. At 2 patients from I groups and 5 patients of II group were present on 2 hernias that did not coincide with the given ultrasonics. At 1 patient of II group the diagnosis intervertebral the hernias, exposed by results of ultrasonic, at MPT-inspection has not proved to be true.

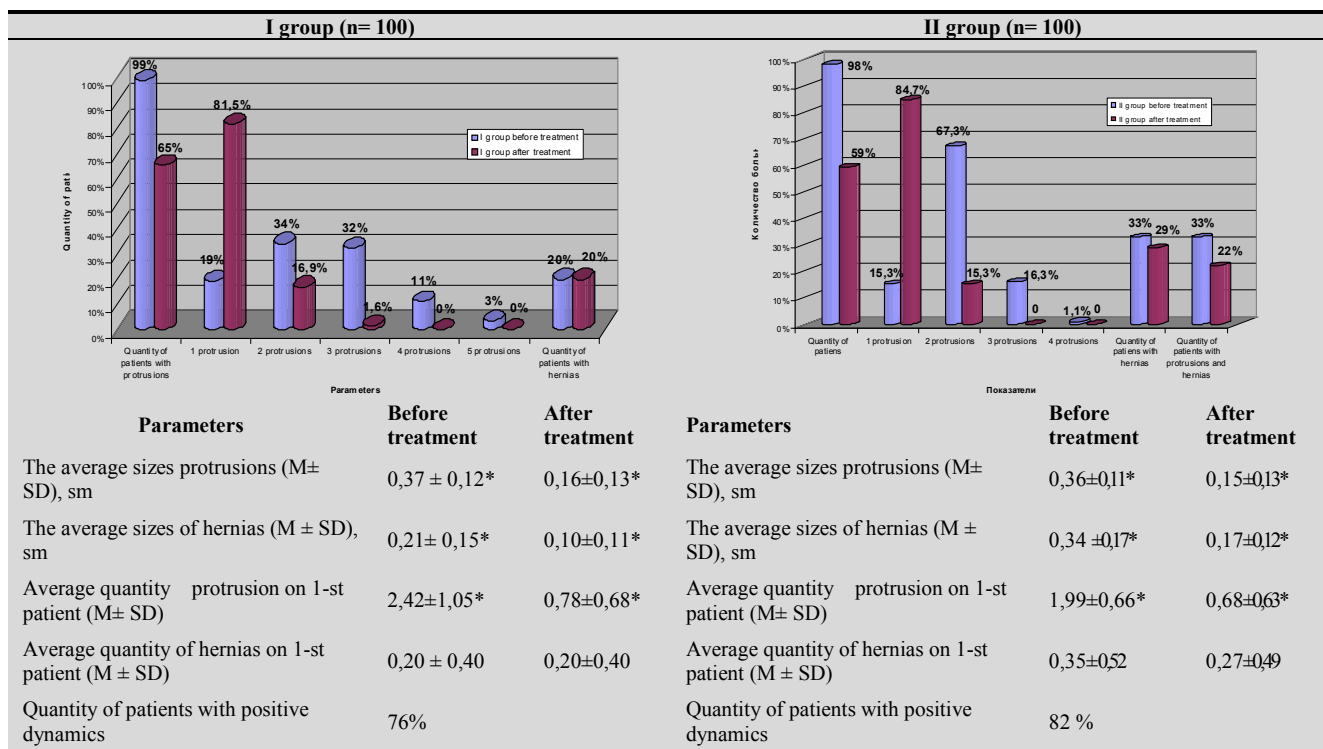
Table 3. Results of the magnetic-resonance tomography of the lumbar department of the backbone at patients with the primary syndrome of the pain in the low back pain

Parameters	I group (n=36)	II group (n = 40)
Quantity of patients with protrusions	35 per./97,2 %	37 per./92,5 %
1 protrusion	12 per./34,3 %	3 per./8,1 %
2 protrusions	8 per./22,8 %	13 per./35,1 %
3 protrusions	15 per./42,9 %	19 per./51,4 %
4 protrusions	-	2 per./5,4 %
Localization protrusions		
L ₁ - L ₂ a disk	2 per./5,7 %	2 per./5,4 %
L ₂ - L ₃ a disk	3 per./8,6 %	3 per./8,1 %
L ₃ - L ₄ a disk	5 per./14,3 % *	12 per./32,5 % *

Parameters	I group (n=36)	II group (n = 40)
L ₄ - L ₅ a disk	10 per./28,6 %	10 per./27 %
L ₅ - S ₁ a disk	15 per./42,8 % *	10 per./27 % *
The average sizes protrusions (M ± SD), sm	0,35 ± 0,11	0,38 ± 0,14
Quantity of patients with hernias	23 per./65,7 %	32 per./86,5 %
1 hernia	21 per./91,3 %	27 per./84,4 %
2 hernias	2 per./8,7 %	5 per./ 15,6 %
Localization of hernias		
L ₁ - L ₂ a disk	1 per./4,3 %	-
L ₂ - L ₃ a disk	3 per./13,1 %	-
L ₃ - L ₄ a disk	6 per./26,1 %	5 per./15,6 %
L ₄ - L ₅ a disk	8 per./34,8 %	12 per./37,5 %
L ₅ - S ₁ a disk	5 per./21,7 % *	15 per./ 46,9 %*
The average sizes of hernias (M ± SD), sm	0,17 ± 0,18 *	0,32 ± 0,19*
Quantity of the patients having a combination of hernias with protrusions	22 чел./61,1 %	32 чел./80 %
Concurrence of the given ultrasonic of a lumbar department of a backbone with MRT		
Absence	4 per./11,1 %	3 per./7,5 %
Full concurrence	32 per./88,9 %	37 per./ 92,5%

The note: * - authentic distinctions between parameters in groups (p < 0, 05)

Table 4. Dynamics of parameters of ultrasonic research of a backbone at patients with a primary syndrome of a pain in the low back pain



The note: * - authentic distinctions between parameters in groups (p < 0,05)

Intervertebral hernias at patients I of group was marked at all levels, but am more often on L3-4, L4-5, L5-S1. At patients of II group of a hernia were located only on 3 bottom disks, with the greater frequency on L5-S1. The average sizes of hernias by results of MPT coincided with the data received at ultrasonic of a lumbar department of a backbone. The greatest sizes of hernia educations had sick I groups. At all patients, with the diagnosed hernias, were marked protrusion disks at nearby levels. Concurrence of the given ultrasonics

and MPT a lumbar department of a backbone reached 88,9 % - 92,5 % accordingly in I and II groups that will be coordinated to the data of the literature [6].

In figure 1 data Rg, MPT and ultrasonic of a lumbar department of a backbone at patient T., 45 years are submitted. From these data it is visible, that the x-ray method gives performance about a status of the bone - articulate device of a backbone, ultrasonic - intraspinal structures (a fibrous ring, pulpal nucleus, a yellow sheaf,

spinal and radicular channels), not conceding in it MPT, and MPT allows to estimate all components of the abutment-impellent device simultaneously.

All patients past ultrasonic of a lumbar department of a backbone, had been appointed treatment: in I to group - not steroid anti-inflammatory means (NA) - diclofenac-retard or nize (nimisil) on 100 mg 2 times day per os in a combination with mydocalm on 150 mg 3 times day per os within 10 days; in II group - diclofenac-retard or nize in the same dozes, in a combination with intramuscular introduction ketorol on 30 mg 2 times day within 5 days. After medicamentous treatment at sick all groups within 10 more days the physiotherapy was spent: in I to group a magnetotherapy and diadynamic currents (DDC); in II group - phonophores about 1 % hidrocortizonum an ointment on lumbar area. Besides 31 patients from I groups and 34 patients from II group have in addition passed a 5-day's rate of manipulation. It was, basically, patients for whom hernias of a disk and

spondylolisthesis were diagnosed. Repeated ultrasonic of a lumbar department of a backbone was carried out at the end of all course of treatment (in 21 day).

The received results have shown (table 4), that the positive dynamics expressing in reduction of the sizes protrusion and hernias, was marked in both groups. Besides there was an authentic decrease in quantity protrusion at patients in each group. The quantity of patients with hernias has not decreased in I to group. In II group there was a small decrease in this parameter at the expense of 4 patients, for which were originally diagnosed small (up to 2,5 mm) hernias of disks. At these patients on a place before the revealed hernia small deformation of the spinal channel and restoration epidural and on juxtaspinal to veins of a velocity was determined. Last parameter is considered good prognostic an attribute for a rating of efficiency of conservative therapy of hernias.

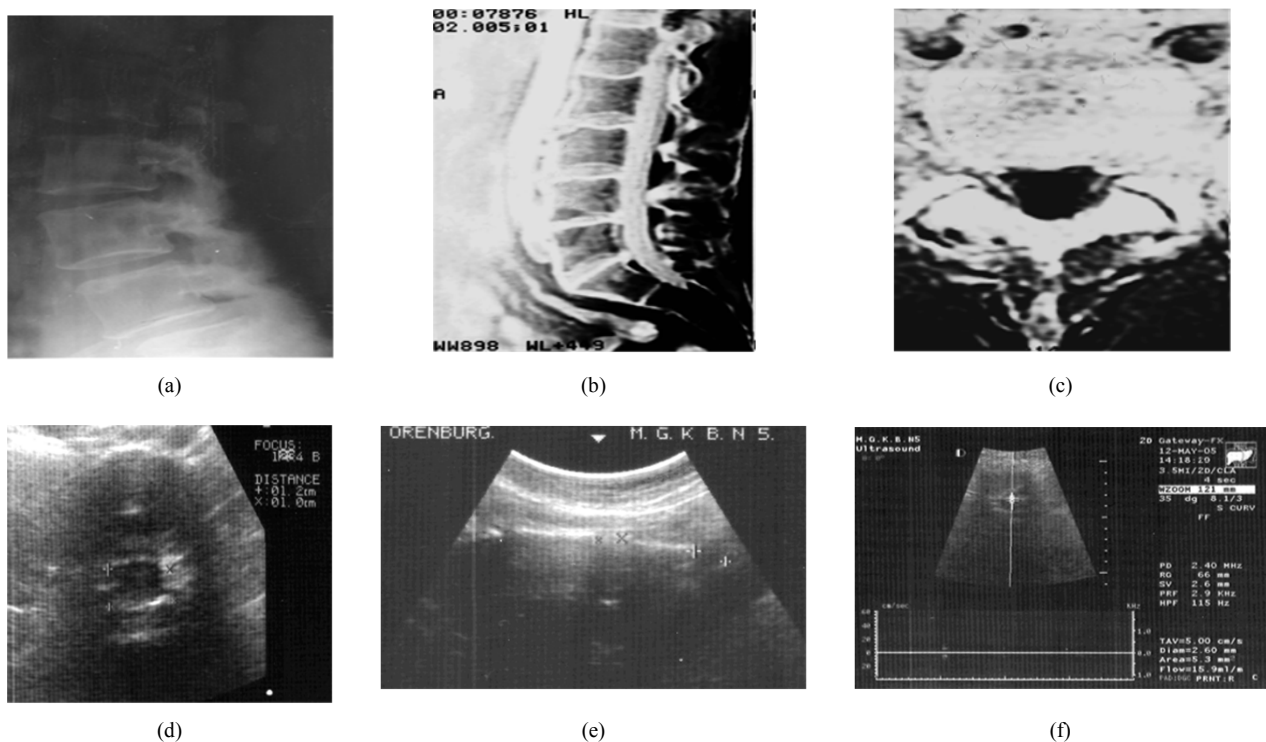


Figure 1. a - The roentgenogram of a lumbar department of a backbone of patient T., 45 years (II stage). The height of disk L4 - L5; b - MRT a lumbar department of a backbone of patient T., 45 years is reduced. The height of disk L4 - L5.; c - Ultrasonic of a lumbar department of a backbone of patient T., 45 years (longitudinal scan) is reduced. The height of disk L4 - L5 is reduced; d - MRT disk L4 - L5. of patient T., 45 years (the pointer designates paramedian to the left on 0,3 sm a hernia); e - Ultrasonic of disk L4 - L5. of patient T., 45 years (a horizontal cut - the pointer designates paramedian to the left on 0,2 sm a hernia); f - A rating of speed of a velocity on epidural vein on not changed disk L3 - L4 Despite lacking positive dynamics as reduction of quantity of patients with hernias of a disk, the number of effectively treated patients in I to group has made 76%, in II group - 82 %. It speaks that, that clinically radicular displays at successful therapy disappear earlier (usually on 3-4-oü to week), than ultrasonic registered reduction of the sizes of hernias. At the average and big sizes of hernias it comes to light only on 6-8 week.

4. The Conclusions

From all three methods of ray diagnostics the most informative is MPT. Taking into account small availability of this examination because of high cost and absence of expensive equipment in many treatment-and-prophylactic institutions, it is recommended to all patients with suspicion on a primary syndrome of a pain in the low part of a back,

first of all, following medico-economic standards to carry out x-ray examination of a lumbar department of a backbone with functional tests (pictures in position of bending and extension a backbone). When there is a clinic of irritation or compression of neural structures of vertebral segment, and roentgenography did not reveal significant deformation of bone elements of spondyles, performance of ultrasound is

necessary. Ultrasound plays an important role in dynamic supervision over patients. The opportunity of determination of a blood flow at a level of the impaired segment with the help of dopplerography allows expecting the prognosis for recovery of a patient. Such approach to the examination of patients with a primary syndrome of a pain in the low part of a back can not only decrease material expenses of medical institution and the patient for diagnostic process, but also optimize it, that will lead to the improvement of quality of treatment of patients.

1. Changes in intraspinal structures, most often as disk protrusions are revealed in the majority of patients (in 98-99 % of cases) with primary vertebral syndrome of pain in the low part of a back during ultrasound examination.

2. Changes on the part of internal structures of a lumbar department of a backbone are noted in a small number (28 % of cases) of practically healthy people at ultrasound examination that allows regarding the formation of protrusions and intervertebral hernias as a cause of sharp and chronic syndrome of pain in a low part of a back.

3. Clinical symptoms of a disease are less expressed in patients with a chronic pain in a low part of a back, than in patients with sharp vertebral pains, despite of a lot, revealed disk protrusions that are quite often asymptomatic.

4. Occurrence of sharp vertebral pains in a low part of a back is most often caused by a compression of nervous radicle by a hernia of a disk at the low levels of a lumbar department of a backbone and does not depend on quantity and expressiveness of disk protrusions.

5. Positive dynamics in patients with a primary syndrome of a pain in a low part of a back by the end of the 3-d week of treatment is expressed in reduction of quantity and the sizes of disk protrusions. Restoration of epidural and paravertebral venous blood flow can be considered to be a good prognostic sign.

References

- [1] О.В. Аблязов, Э.А. Шокиров, К.Т. Худойбердиев и соавт., «Оценка роли магнитно-резонансной томографии в диагностике локализации грыж межпозвонковых дисков при поясничном остеохондрозе», Неврологический вестник, 2003, вып.3-4, pp.79-80.
- [2] В.В. Алексеев, «Диагностика и лечение болей в пояснице», CONSILIUM medicum, 2002, 2, pp.96- 102.
- [3] А.Ю. Кинзерский, «Трансабдоминальная ультрасонография в диагностике поясничного межпозвонкового остеохондроза», Визуализация в клинике, 1995, 7, pp. 5-9.
- [4] А.Ю. Кинзерский, «Допплерография эпидуральных венозных сплетений в дифференциации причин компрессии корешков спинного мозга при межпозвонковом остеохондрозе», Визуализация в клинике, 1999, pp.44-46.
- [5] А.Ю. Кинзерский, Д.В. Медведев, А.Л. Бурулев, «Ультрасонография позвоночника», Челябинск, 2001, p.164.
- [6] А.Ю. Кинзерский, А.Л. Бурулев, «Роль ультразвукового метода исследования в диагностике остеохондроза поясничного отдела позвоночника. Современные технологии в ультразвуковой диагностике», 2002, p.55.
- [7] К.О.Кузьминов, «Ультразвуковая оценка состояния эпидурального пространства у больных с дискогенной болезнью поясничного отдела позвоночника», Мануальная терапия, 1999, 2, pp.12-15.
- [8] Г.И. Назаренко., А.М. Черкашов, А.В. Араблинский и соавт., «Современная комплексная диагностика дегенеративно-дистрофических изменений межпозвонковых дисков», Медицинская визуализация, 2002, 2, pp.38-43.
- [9] В.А. Насонова, Ш. Эрдес, «О всемирной декаде костно-суставных заболеваний 2000-2010», Научно-практическая ревматология, 2000, 4, pp.14- 16.
- [10] Ю.О. Новиков, «Боль в спине: клиника, дифференциальная диагностика, лечение», Вертеброневрология, 2001, 1-2, pp. 16-19.
- [11] Ю.А. Олюнин, «Острые и хронические боли в области позвоночника», Русский медицинский журнал, 2004, 12(6), pp.386-391.
- [12] Е.Ф. Подчуфарова, «Боль в пояснично-крестцовой области: диагностика, лечение», Русский медицинский журнал, 2004, 10, pp.1201-1208.
- [13] Н.А. Шостак, «Диагностика и лечение болей в нижней части спины», Научно-практическая ревматология, 2001, 4, pp. 55-61.
- [14] M. C.Battie, T. Hansson, S. Bigos et al., «B-scan ultrasonic measurement of the lumbar spinal canal as a predictor of industrial back pain complaints and extended work loss [see comments]», J. Occup. Med., 1993, 12, pp.1250-1255.
- [15] P. F. Beattie, and S.P. Meyers, «Magnetic resonance imaging in low back pain: general principles and clinical issues», Phys. Ther., 1998, 7, pp. 738-753.
- [16] R.A. Deyo, «Diagnostic Evaluation of LBP. Reaching a Specific Diagnosis is Often Impossible», Arch. Intern. Med., 2002, 162, pp. 1444-1447
- [17] F. Ebner, E. Tolly, and W. Kopp, «Sonographic demonstration of lumbar disc herniation», J. Ultrasound Med., 1986, 4, pp.193-196.
- [18] O. Hoffmann, M. Weih, von T. Munster et al., «Blood flow velocities in the vertebral veins of healthy: duplex sonographic study», J. Neuroimaging, 1999, Oct. 9 (4), pp.198-200.
- [19] K. Kamei, K. Hanai, and N. Metsui, «Ultrasonic level diagnosis of lumbar disc herniation. Spine», 1990,11, pp.1170-1174.
- [20] K. Kullmer, J.D. Rompe, A. Lowe et al., «Ultrasound image of the lumbar spine and lumbosacral transition. Ultrasound anatomy and possibilities for ultrasonically-controlled facet joint infiltration», Z. Orthop. the Grenzgeb., 1997, 4, pp.310-314.
- [21] U. Lebkowska, and W.J. Lebkowski, «Visualization of the model of human lumbosacral spine in ultrasound examination», Ann. Med. Univ. Bialyst. Pol., 1993, 1, pp.100-106.

- [22] C. Maureen Jensen, Michael N. Brant-Zawadzki, Nancy Obuchowski et al., «Magnetic Resonance Imaging of the Lumbar Spine in People without Back Pain», *N. Engl. J. Med.*, 1994, 331, pp.1525-1526.
- [23] A. Saifuddin, I. Braithwaite, J. White et al., «The value of lumbar spine magnetic resonance imaging in the demonstration of annular tears», *Spine*, 1998, 3, pp. 453-457.
- [24] M.E. Suarez-Almazor, E. Belseck, A.S. Russell et al., «Use of lumbar radiographs for the early diagnosis of low back pain. Proposed guidelines would increase utilization», *Arch. Fam. Med.*, 2000, 9, pp.10015-1021.