

Case Report

Tuberculosis: An Unusual Cause of Otitis Media and Mastoiditis in Children

Rim Bechraoui^{*}, Semia Meherzi, Sana Mahfoudhi, Houda Chahed, Azza Mediouni, Jihene Marrakchi, Mohamed Ben Amor, Najeh Beltaief, Rim Zainine, Ghazi Besbes

Department of Oto-Rhino-Laryngology and Cervico-Facial Surgery of 'Rabta' Hospital, Medicine Faculty, El Manar University, Tunis, Tunisia

Email address:

rbechraoui@yahoo.fr (R. Bechraoui)

^{*}Corresponding author

To cite this article:

Rim Bechraoui, Semia Meherzi, Sana Mahfoudhi, Houda Chahed, Azza Mediouni, Jihene Marrakchi, Mohamed Ben Amor, Najeh Beltaief, Rim Zainine, Ghazi Besbes. Tuberculosis: An Unusual Cause of Otitis Media and Mastoiditis in Children. *International Journal of Otorhinolaryngology*. Vol. 4, No. 1, 2018, pp. 11-12. doi: 10.11648/j.ijo.20180401.13

Received: December 2, 2017; **Accepted:** February 1, 2018; **Published:** March 8, 2018

Abstract: Tuberculous otitis media (TOM) is a rare cause of chronic suppurative infection of the middle ear. Clinical symptoms are nonspecific making delayed diagnosis. We present the case of an infant, aged 22 months, having immune deficiency, who was admitted for a left externalized otomastoiditis. The radiological assessment confirmed this diagnosis. The child had a surgical drainage of the collection with biopsy of granulation tissue whose histopathological examination found a caseo-follicular tuberculosis. Despite its rarity, TOM is associated with a high rate of complications. The diagnosis should be considered in any suppurative chronic otitis resistant to standard treatment.

Keywords: Tuberculous, Otitis Media, Mastoid, Otorrhea

1. Introduction

Tuberculosis is a chronic bacterial infection caused by *Mycobacterium tuberculosis*. Tuberculous otitis media (TOM) is rare, 3 to 5% of the cases of chronic suppurative otitis media were caused by tuberculosis [1, 2]. The signs and symptoms are variable and nonspecific and often differ from classic descriptions. Early treatment is a decisive factor in preventing possible complications. In most patients, tuberculostatic drugs drastically improve the prognosis [2]. We present a case of TOM as a rare cause of chronic suppurative infection of the middle ear.

2. Methods

We report a case of tuberculous otitis media treated in our department. It was an infant, aged 22 months, with immunoglobulin G deficiency. The temporal CT scan and temporal MRI was practiced. Histopathological examination of specimen have confirmed the diagnosis.

3. Results

It was an infant, aged 22 months, and who was followed in pediatric department for immunoglobulin G deficiency and a dragging pneumopathy. He was admitted for a fever with a left mastoid swelling. His mother reported episodes of otalgia and otorrhea, which did not improve with antibiotics and ear drops.

The otological examination found an inflammatory mastoid swelling, an auricle detachment, a fall of the posterior wall of the external auditory canal, and a complete and inflammatory tympanum. Audiometric tests showed moderately severe hearing loss in the left ear.

The temporal CT scan showed a bilateral filling of the cavities of the middle ear, and on the left side a lysis of the tympanic bone and the temporal scale with a spontaneous antrotomy (Figure 1).

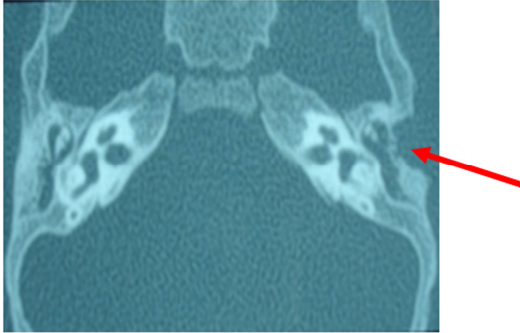

Figure 1. CT scan of temporal bones (axial view): filling of the left middle ear, lysis of the scale of the temporal, thickening of soft left temporal parts.

Temporal MRI showed bilateral inflammatory filling of the middle ear complicated with a collection of left external soft temporal parts (Figure 2).

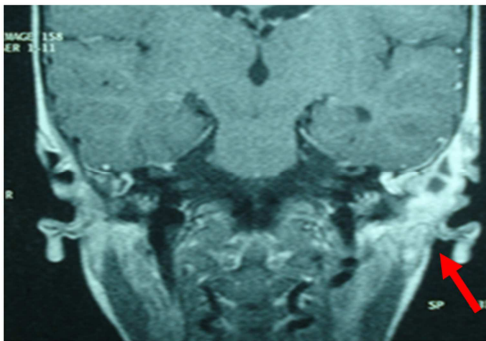


Figure 2. MRI of temporal bones (coronal view): inflammatory filling of the middle ear with collection of soft tissue.

The patient had a surgical drainage of the retro-auricular collection with a curettage of the osteitic lesions of the mastoid. The anatomopathological study concluded to a caseo-follicular tuberculosis.

Chest x-ray images showed fibronodular lesions. Pneumopathy were correlated to pulmonary tuberculosis despite a negative culture of the sputum. The patient received anti-tuberculosis drugs.

The development was marked by the appearance of a productive left retro-auricular fistula, which had disappeared progressively.

4. Discussion

Tuberculosis is one of the most common infectious diseases of developing countries. It rarely affects the middle ear [2, 3]. It is characterized by painless otorrhoea which fails to respond to the usual antimicrobial treatment [4, 5].

Clinical exam found multiple tympanic membrane perforations, abundant granulation tissue, bone necrosis, and preauricular lymph node enlargement. Loss of hearing is also found in patients with development of the diseases seen by the otoscopy [6]. Complications such as facial palsy, and periauricular fistulas are infrequently observed and can be avoided with early diagnosis and treatment [7]. Radiologic findings are nonspecific and include demineralization of the

bone and, less commonly, bony erosion [5, 8].

A high index of suspicion is required for diagnosis, which can only be achieved via tissue biopsy [6, 9]. The treatment consists of a multidrug regimen of antituberculous medications. Combination chemotherapy is prescribed [10]. Surgery may be required in some cases to remove sequestra and improve drainage [2, 10].

A high level of clinical suspicion is needed for early diagnosis and antitubercular therapy should be started as soon as possible to prevent the possible complication [2, 3, 11].

5. Conclusion

TOM, although rare, is associated with a high rate of complication. The clinical presentation is variable. The diagnosis should be considered in any chronic suppurative otitis resistant to standard treatment. TOM should be suspected after failure of current antibiotics or persistent effusion after tympanoplasty or mastoidectomy. Early diagnosis and antitubercular therapy should be started as soon as possible to prevent complications.

References

- [1] Lim PS, Goh BS, Saim L. Tuberculosis otitis media. *Brunei Int Med J.* 2013;9(5):329-33.
- [2] Touati MM, Darouassi Y, Chihani M, Lakouichmi M, Tourabi K, Ammar H. La tuberculose extra-ganglionnaire primitive de la sphère ORL: à propos de 15 cas. *Pan Afr Med J.* 2014;19.
- [3] Akkara SA, Singhania A, Akkara AG, Shah A, Adalja M, Chauhan N. A study of manifestations of extrapulmonary tuberculosis in the ENT region. *Indian J Otolaryngol Head Neck Surg.* 2014;66(1):46-50.
- [4] Abes FL, Abes G, Jamir J. The Variable Clinical Presentation of Tuberculosis Otitis Media and the Importance of Early Detection. *J Laryngol Otol.* 2016;130-90.
- [5] Ješić S, Stošić S, Milenković B, Nešić V, Dudvarski Z, Jotić A. Middle ear tuberculosis: diagnostic criteria. *Srp Arh Celok Lek.* 2009;137(7-8):346-50.
- [6] Hoca NT, Ogretensoy M, Dayioglu D, Akbas N. Tuberculous otitis media-A case report. *Turkish Respiratory Journal.* 2008;9(1):048-50.
- [7] Araújo MF, Pinheiro TG, Raymundo IT, Soares VYR, Araújo PIM, Melo Martins R. Tuberculous Otitis Media. *Int Adv Otol.* 2011;7:413-7.
- [8] Pitcher R, Thandar MA. Bilateral tuberculous mastoiditis and facial palsy. *South Afr Med J.* 2008;94(11):893.
- [9] Quaranta N, Petrone P, Michailidou A, Miragliotta L, Santantonio M, Del Prete R. Tuberculous Otitis Media with Facial Paralysis: A Clinical and Microbiological Diagnosis—A Case Report. *Case Rep Infect Dis.* 2011;2011.
- [10] Aremu S, Alabi B. Tuberculous otitis media: a case presentation and review of the literature. *BMJ Case Rep.* 2010.
- [11] Scorpecci A, Bozzola E, Villani A. Two new cases of chronic tuberculosis in children. *Acta Otorhinolaryngol Ital.* 2015; 35(2): 125-128.