



## Case Report

# Bilateral Metastases of Colorectal Cancer to the Choroid and Optic Disc

Caleb Roy Walker, David Alan Reichstein\*

Tennessee Retina, Nashville, USA

### Email address:

[dreichstein@tnretina.com](mailto:dreichstein@tnretina.com) (D. A. Reichstein)

\*Corresponding author

### To cite this article:

Caleb Roy Walker, David Alan Reichstein. Bilateral Metastases of Colorectal Cancer to the Choroid and Optic Disc. *International Journal of Ophthalmology & Visual Science*. Vol. 2, No. 3, 2017, pp. 65-68. doi: 10.11648/j.ijovs.20170203.11

**Received:** February 28, 2017; **Accepted:** April 22, 2017; **Published:** June 12, 2017

---

**Abstract:** Introduction: Metastatic colorectal cancer is highly fatal disease. While metastases are usually found in the thoracic cavity in colorectal cancer, the choroid has been shown to harbor metastases. The retrobulbar pathway, although rarely, has also demonstrated colorectal metastases. Case report: A 54-year-old male with a one-year history of disseminated colon cancer presented with vision loss in his right eye in October 2013. A choroidal metastasis was found extending from the optic disc toward the fovea, Initial treatment consisted of systemic chemotherapy, supplemented by External Beam Radiation Therapy to the right eye one year after diagnosis. Thirteen months later, the left eye was found to have a choroidal tumor surrounding the disc. The cancer progressed through both local and systemic treatment. Discussion: While the disease progressed through multiple rounds of chemotherapy, external beam radiation therapy was shown to be effective in regressing the tumors. Managing refractory metastatic disease presents unique challenges in properly prioritizing therapeutic routes.

**Keywords:** Colorectal Cancer, Ocular Metastases, External Beam Radiation Therapy, Optic Disc Tumor

---

## 1. Introduction

Colorectal cancer affects approximately 4.4 percent of individuals in the United States [1]. Of those diagnosed with metastatic colorectal cancer, roughly 10% survive to 5 years [2]. The sites of metastases of colorectal cancer are primarily thoracic, although they range from bone to the nervous system to the eye [3]. Though rarely harboring metastases, the choroid maintains a supportive site for secondary tumors, presumably due to its rich vasculature [4] Post-mortem studies have demonstrated that those who do have choroidal involvement tend to have lung involvement prior or co-morbidly [5]. In several independent trials, choroidal metastases from colorectal cancer were rare, although this type of cancer occurred in a significant portion of the study population [6-8]. The retrobulbar visual pathway also rarely demonstrates colorectal metastases. In one study involving 660 patients with intraocular metastasis, 4.5% of patients had intraocular metastases to the optic disc [9]. Patients with ocular metastatic disease typically present with decreased vision, diplopia, metamorphopsia, floaters, secondary

glaucoma, detached retina and its signs, ptosis, and blepharitis, among others. Here we present a case of bilateral metastatic colorectal adenocarcinoma to the choroid and optic nerve.

## 2. Case Report

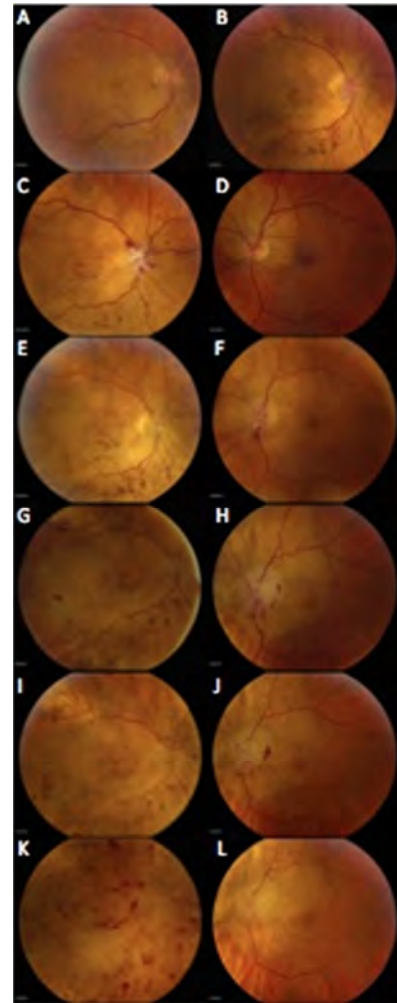
A 54-year-old male with a history of disseminated colon cancer presented with vision loss in his right eye in October 2013. 16 months prior, the patient underwent colonoscopy, revealing a moderately differentiated adenocarcinoma. Initial tumor treatment consisted of abdominoperineal resection (APR) with neoadjuvant 5-fluorouracil (5-FU) and radiation. Pathology staged the tumor as T1/N0/M0. A permanent colostomy was placed at the time of resection. A regimen of folinic acid, fluorouracil and oxaliplatin (FOLFOX) was started in November 2013 and continued for one year. In July of that same year, positron-emission scan (PET) scan showed questionable pulmonary metastases, which were monitored during chemotherapy. The patient was presented three months following diagnosis with complaints of decreased vision. Best-corrected visual acuity (BCVA) was 20/400 OD, 20/30

OS. Ophthalmoscopy revealed a 5.5mm yellow raised choroidal lesion extending from the disc margin to the foveal border along the inferior arcade. Optical coherence tomography (SD-OCT) demonstrated subretinal fluid overlying the lesion, while ultrasound demonstrated an echodense tumor. The left eye was otherwise unremarkable. External Beam Radiation Therapy (EBRT) was performed using 20 fractions of 40 G on the right eye in November 2013. Due to disease advancement, folinic acid, fluorouracil, irinotecan (FOLFIRI), with systemic bevacizumab, was initiated for 7 months from January 2014 until July 2014. In July 2014, a second optic nerve and choroidal metastasis was observed in the as-of-yet unaffected left eye. OCT of the lesion at the level of the optic nerve revealed overlying sub-retinal fluid, papilledema, and hemorrhage adjacent to the optic nerve. Ultrasound demonstrated a 6x6mm yellow choroidal and optic nerve mass. BCVA at this time was count fingers at 1ft OD, 20/20 OS with notable photopsias OS. A repeat MRI in October 2014 revealed enhancement along right optic nerve sheath. EBRT was recommended at this time for the tumor OS. However, the patient was enrolled in a clinical trial using an anti-IL-10 agent in conjunction with FOLFOX therapy. The trial prohibited radiation of any kind. Intravitreal bevacizumab was initiated the same month. In December 2014, Photodynamic Therapy (PDT) was performed November 2014 for the left eye. Despite his chemotherapeutic intervention, both optic nerve metastases progressed with resultant optic nerve swelling and vision loss. The patient was allowed to undergo EBRT in February 2015 after discontinuation from the trial. EBRT was supplemented bilaterally at the therapeutic dose of 30 G with the left eye receiving 20 fractions and the right eye 10 fractions, which were completed in March 2015. Triamcinilone Acetonide was also injected in the left eye for resultant vein occlusions. Despite these interventions, the patient ultimately became bilaterally no-light perception (NLP). The patient was enrolled in a second trial using regorafenib in combination with ruxolitinib. With no significant regression, the patient was discontinued from a second trial. A final clinical trial was attempted using OX40/PD-1 inhibitors, but with no success. He expired six month after total vision loss.

### 3. Discussion

The need for vigilant ophthalmic monitoring and screening for metastatic cancer is great, with metastases being the cause of death in 90% of patients [10]. The prognosis for patients with uveal metastasis is just over a year [11], while those with optic nerve involvement may be less than one year [12]. Optic nerve metastases are rare, occurring in approximately 5% of all intraocular tumors, and colorectal metastases lead to only 4% of intraocular metastases [8, 9, 13]. Khawaja et al 2015 identified only 8 other case reports in the literature of CRC metastatic to the eye, none of which involved the optic nerve [14]. The diagnosis of such disease is largely clinical. While fine-needle aspirate biopsy (FNAB) is reliable in establishing diagnosis [15], the systemic disease typically precedes ocular

metastases. As such, the ophthalmoscopic presentation, along with standard clinical testing provides sufficient information to guide the clinician in diagnosis.



**Figure 1.** Progression of Ocular Metastases in a Colorectal Cancer Subject.

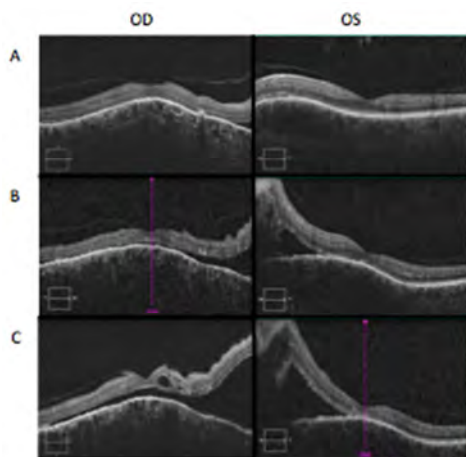
(A) Dec. 2013-1 month after diagnosis of metastatic eye disease. (B) Aug. 2014-9 months status-post EBRT; significant RPE changes with blot hemorrhages; Systemic Bevacizumab maintained (C-D) Oct. 2014-MRI shows enhancement in the right optic sheath; hemorrhages adjacent to the optic disc OD. New tumor diagnosed OS (E-F) Dec 2014-regressing tumor OD 1 month status-post PDT OS (G-H) Feb 2015-increased blot hemorrhages, advancing tumor; EBRT performed OS (I-J) Mar 2015-stable tumor OD; 1 month status-post EBRT; rare blot hemorrhage OS (K-L) Apr 2015-Final study; CRVO, stable tumor OD Blot hemorrhages, tumor regression inferonasal OS

The treatment for choroidal metastatic disease varies depending on the tissue of origin, the extent of metastasis, and the timeframe within which the tumors are found [4]. Both local and systemic treatments are available for those with metastatic eye disease. Systemic chemotherapy can cause choroidal metastases to regress [16]. In one study of metastatic carcinoma, systemic chemotherapy was as effective as EBRT, though individual tumors may respond preferentially to one treatment versus another [17].

Local therapy with external beam radiation has been

demonstrated often. EBRT can be useful in preserving vision [18]. In the best of cases, EBRT has been shown to partially restore the patient's vision [19]. External Beam Radiation Therapy is mainly enacted to manage discomfort, stabilize any loss of vision due to secondary tumors, and maintain the globe. Other radiation treatments are available. Plaque brachytherapy is a common treatment option [8], while proton beam therapy also has been demonstrated to be effective [20]. While other radiation treatments, such as cyber-knife gamma surgery, have shown some effectiveness in discrete ocular tumors [21, 22], little comparative data has been conducted, and are rarely used. For those patients with optic nerve involvement, optic fenestration has been performed if significant optic nerve compression is suspected [23]. Intravitreal bevacizumab has established efficacy in decreasing subretinal fluid that is associated with ocular tumors, and, in some cases, has shown to be able to reduce the tumor burden in patients [24]. Photodynamic therapy has been shown to be effective, particularly in the reducing the accompanying subretinal fluid [25]. If local tumor therapy treatments are not suitable to the clinician or patient, enucleation remains another course. While local treatment may be effective, the ultimate goal is to preserve vision and prevent further metastasis for as long as possible.

Our course of treatment aimed at regressing the tumor while managing symptoms. EBRT was effective at regressing the tumor of the right eye. Bevacizumab was initiated after EBRT to reduce retinal edema, which was later supplemented in the treatment course by PDT in the left eye. Due to the location of the tumor, occlusion of the retinal vessels caused further edema, for we continued intravitreal bevacizumab.



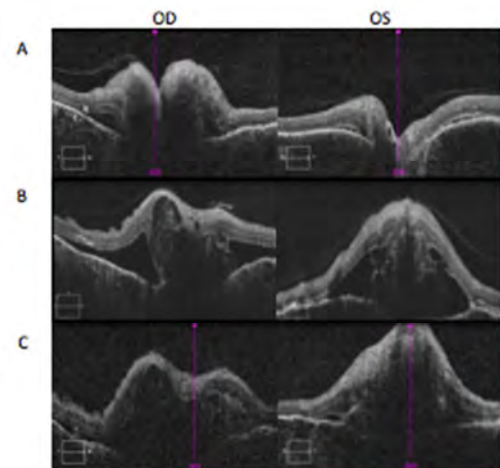
**Figure 2.** Macular Findings Using SD-OCT.

(A) Oct. 2014-13 months status-post EBRT OD; newly diagnosed metastasis with accompanying subretinal fluid OS (B) Jan 2015-increasing subretinal fluid OD; Three months after tumor diagnosed OS (C) Mar. 2015-Final treatment EBRT OU serous foveal detachment OD detachment threatening the fovea OS

In monitoring the growth of the left eye's tumor, radiation was an attractive option, given the response of the right eye. However, one of the trials excluded radiation treatment, and

given the state of the disease, the tumor was treated with chemotherapy alone. The patient lost vision rather quickly in the left eye, presumably due to compression of the optic nerve head: from December 2014 to June 2015, the patient decreased in vision from 20/20 to NLP. Similar to the right eye tumor, the left eye tumor behaved in the same manner of growth: appearing at the disc and occluding both vessels and nerve. While it has been noted that optic disc edema and optic neuropathy were sequelae in FOLFOX regimes [26], the compression of the optic sheath was difficult to manage effectively. Previous case reports have shown significant vision decrease by tumor compression of the nerve [27] and one report suggest these types of tumors warrant higher doses of radiation [28].

The management of such metastatic tumors is difficult in highly aggressive malignancies that have demonstrated growth through both local and systemic treatments, such as the one presented here. In such cases, the optimal clinical decisions consider the likely outcomes, the patient's wishes regarding treatment and prognosis, and the entire medical team's therapeutic course. In the best of cases, vision is preserved so that the patient's quality of life is optimized in respect to his visual status.



**Figure 3.** Optic Disc Head Involvement Using SD-OCT.

(A) Oct. 2014 –Papilledema; MRI enhancement along optic sheath OD; newly diagnosed tumor OS (B) Jan. 2015- 1 month prior to EBRT OU; significant Disc swelling with subretinal fluid extending outward OU (C) Apr. 2015-Final study; CRVO OD; Papilledema OU

## 4. Conclusion

Vigilant monitoring of choroidal and optic nerve metastases in highly aggressive tumors is needed to optimize patient health and visual status throughout disease course. Managing refractory metastatic disease presents unique challenges in properly prioritizing therapeutic routes such as EBRT. Ophthalmologists may play a significant role in managing symptoms and preventing further disease progression in those with metastatic disease. As in this case report, optimizing care is both preventative and palliative.

---

## References

- [1] Howlader, *et al.* SEER Cancer Statistics Review, 1975-2013, NCI, Bethesda, Based on Nov. 2015 SEER Data Submission, Posted to SEER Website, April 2016.
- [2] Rodriguez-Bigas, MA, *et al.* "Stage IV Colorectal Cancer" In Kufe DW *et al.*, editors. *Holland-Frei Cancer Medicine*. 6<sup>th</sup> ed. Hamilton(ON): BC Decker; 2003.
- [3] Riihimaki M, *et al.* "Patterns of Metastasis in Colon and Rectal Cancer" *Sci. Rep.* 6: 29765. 2016.
- [4] Arepalli, S. *et al.* "Choroidal Metastases: Origin, Features and Therapy" *Indian J Ophthalmol.* 63: 122-127. 2015.
- [5] Mongan J, *et al.* "Brain Metastases from Colorectal Cancer: Risk Factors, Incidence, and the Possible Role of Chemokines" *Clin Colorectal Cancer* 8(2): 100-105. Apr. 2009.
- [6] Eliassi-Rad B, *et al.* "Frequency of Ocular Metastases in patients Dying of Cancer in Eye Bank Populations." *Br J of Ophthalmol.* 80. 125-128. 1996.
- [7] Nelson CC "A Histopathologic Study of 716 Unselected Eyes in Patients with Cancer at the Time of Death" *Am J of Ophthalmol* 95: 788-793. 1983.
- [8] Shields C, *et al.* Survey of 520 Eyes With Uveal Metastases. *Ophthalmology.* 104(8): 1265-1276. 1997.
- [9] Shields J. *et al.* "Metastatic Neoplasms In The Optic Disc: The 1999 Bjerrum Lecture: Part 2". *Arch Ophthalmol.* 118: 217-224. 2000.
- [10] Sporn MB. "The War on Cancer" *The Lancet.* 247(9012): 1377-81. 1996.
- [11] Font RL, Ferry, AP. "Carcinoma Metastatic to the Eye and Orbit III. A Clinicopathologic Study Of Cases Metastatic To The Orbit". *Cancer.* 28(3): 1326-35. 1976.
- [12] Mack H. *et al.* "Isolated Metastases to the Retina or Optic Nerve" *Int. Ophthalmol Clin.* 37 (4): 251-260. 1997.
- [13] Shields J, *et al.* "Survey of 1264 Patients With Orbital Tumors and Stimulating Lesions: The 2002 Montgomery Lecture, Part 1" *Ophthalmology* 111(5): 997-1008. 2004.
- [14] Sing AD, Biscotti CV. "Fine Needle Aspiration Biopsy of Ophthalmic Tumors" *Saudi J Ophthalmol.* 26(2): 117-123. 2012.
- [15] Chen, *et al.* "Emerging Treatments for Choroidal Metastases" *Surv of Ophthalmol* 56(6): 511-521. 2011.
- [16] Letson AD, *et al.* "Chemotheapy for Treatment of Choroidal Metastases from Breast Carcinoma" *Am. J of Ophthalmol.* 93 (1): 102-106. 1982.
- [17] Lim JI, *et al.* "Radioactive Plaque Therapy for Metastatic Choroidal Carcinoma" *Ophthalmology.* 107: 1927-31. 2000.
- [18] Rudoler, *et al.* "Functional Vision is improved in the Majority of Patients Treated with External-Beam Radiotherapy for Choroidal Metastases: A Multi-variate Analysis of 188 patients" *Journal of Clinical Oncology.* 15(3): 1244-51. 1997.
- [19] Tsina EK, *et al.* "Treatment of Metastatic Tumors of the Choroid With Proton Beam Irradiation" *Ophthalmology* 112(2): 337-343.
- [20] Marchini G, *et al.* "Stereotactic Radiosurgery of Uveal Melanomas: Preliminary Results with Gamma Knife Treatment" *Stereotact Funct Neurogurg* 65: 72-79. 1995.
- [21] Daftari IK, *et al.* "A Noninvasive Eye Fixation Monitoring System For Cyberknife Radiotherapy of Choroidal and Orbital Tumors" *Med Phys* 36: 719-724. 2009.
- [22] Gasperini J, *et al.* "Perineural Metastasis of Breast Cancer Treated with Optic Nerve Sheath Fenestration" *Ophthalmol Plast Reconstr Surg.* 23(4): 331-3. 2007.
- [23] Kuo, I. *et al.* Regression of a Subfoveal Choroidal Metastasis of Colorectal Carcinoma After Intravitreal Bevacizumab Treatment. *Archives of Ophthalmology.* 126 (9): 1311-1313. 2008.
- [24] Kaliki S, *et al.* "Photodynamic Therapy For Choroidal Metastasis In 8 Cases" *Ophthalmology.* 119(6): 1218-22. 2012.
- [25] Tuner LD, Harrison JD "Bilateral Optic Disc Oedema and Associated Optic Neuropathy In The Setting of FOLFOX Chemotherapy" *BMC Ophthalmol* 13:42. 2013.
- [26] Tamai H, *et al.* "Compression Neuropathy Caused By Cancer Metastasis To The Optic Nerve Canal" *BMC Res Notes.* 6: 546 2013.
- [27] Allaire GS, *et al.* "Metastasis To The Optic Nerve: Clinicopathological Correlations" 30(6): 306-11. 1995.