



Case Report

Severe Corneoscleral Dellen Following Uneventful Bilateral Pterygia Excision in a Nigerian Adult: A Case Report

Chidi Ihemedu¹, Oluwaseun Awe^{2, *}, Ogbonne Nwankwo¹

¹Department of Ophthalmology, Lily Hospitals Limited, Warri, Nigeria

²Department of Ophthalmology, Obafemi Awolowo University, Ile-Ife, Nigeria

Email address:

linkseunawe@gmail.com (O. Awe)

*Corresponding author

To cite this article:

Chidi Ihemedu, Oluwaseun Awe, Ogbonne Nwankwo. Severe Corneoscleral Dellen Following Uneventful Bilateral Pterygia Excision in a Nigerian Adult: A Case Report. *International Journal of Ophthalmology & Visual Science*. Vol. 3, No. 2, 2018, pp. 17-20.

doi: 10.11648/j.ijovs.20180302.11

Received: May 20, 2018; **Accepted:** June 19, 2018; **Published:** July 17, 2018

Abstract: We describe a patient who had uneventful excision of bilateral nasal pterygia using bare sclera technique with adjunctive topical antimetabolite therapy and subsequently developed bilateral corneoscleral dellen. A 44-year old Nigerian male presented with signs of bilateral nasal pterygia and had surgery done on both eyes. The pterygia excisions were performed under local anaesthesia using bare sclera technique with intraoperative adjunctive antimetabolite application. There was no post-operative complication until after 23 days with the appearance of bilateral corneal and sclera dellen, first on the left eye then the right with 5 days interval between both eyes. Treatment modality involved topical lubricant therapy, alternating eye patching and bandage contact lens. Corneal and sclera epithelization occurred in both eyes after six weeks of medical therapy with a slightly inflamed recurrent pterygium in the right eye. Corneal and sclera dellen is a rare late complication of uneventful pterygium excision with adjunctive therapy and it can however be managed effectively by medical therapy albeit increased risk of early recurrence of the pterygium.

Keywords: Corneal Dellen, Scleral Dellen, Scleral Thinning, Bilateral Pterygia, Nigerian Adult

1. Introduction

Pterygium is a common ocular surface disease characterized by elastotic degeneration of the conjunctival tissue crossing the limbus unto the cornea [1]. Several surgical techniques for treatment are available and these include excision with bare sclera, simple conjunctival closure, amniotic membrane graft and conjunctival autograft [2, 3]. Similar to other ocular surgeries, post-operative complications often occur with recurrence of the pterygium being the commonest irrespective of the surgical technique. However, several adjunctive methods have been found to reduce recurrence and such include use of intra-operative antimetabolite (5-fluorouracil or mitomycin C) or post-operative beta irradiation [4].

Cornea and sclera dellen are very rare complications which when present, poses great concern to both the patient and the ophthalmologist. They are small saucer-like excavations at the

margin of the corneal and scleral [5] with localized dehydration and thinning of the corneoscleral tissue thus exposing the underlying uvea. Known causes include post-ptyerygium surgery, large filtration blebs, dermoids, scleritis, scarring after extraocular muscle surgery or severe conjunctival chemosis [5]. Treatment of corneoscleral dellen may be medical or surgical [6, 7]. The former involves the use of ocular lubricant, antibiotics, patching and occasionally use of bandage contact lens while the surgical treatment involves raising a conjunctival flap or placement of amniotic membrane over the dellen [7, 8].

We report a case of severe bilateral corneoscleral dellen which occurred following an uneventful bilateral pterygia excision with intra-operative 5-fluorouracil administration.

2. Case Report

A 44-year old male engineer presented with two years

history of conjunctival tissue growth in both eyes with associated recurrent redness, foreign body sensation, excessive lacrimation and cosmetic discontent. He had no history of hypertension, diabetes, poor wound healing, no known autoimmune disease or known drug reaction. Ocular examination with the slit lamp revealed bilateral grade III nasal pterygia and he was subsequently scheduled for surgery. The procedure was performed first on the left eye under topical and subconjunctival anaesthesia (lidocaine 2% and epinephrine 1/200.000). A conjunctival bleb was formed by the subconjunctival injection and pterygium was carefully avulsed from its apex on the corneal towards its base. It was then excised ensuring no retained pterygium tissue. Haemostasis was achieved by gentle cauterization with a bipolar cautery machine. A cellulose microspoon tip soaked with 5-fluorouracil (50mg/ml) was applied over the bare sclera surface for 5 minutes and then rinsed with 20ml of normal saline. Chloramphenicol ointment (1% w/w) was applied and the eye padded. A similar procedure was performed on the other eye 5 days later. Both procedures were uneventful. The eye pads were removed on the first post-operative days and the bare sclerae in both eyes were intact with no sign of infection or excessive inflammation. Guttate dexamethasone (0.3mg/g) and guttate ciprofloxacin were prescribed for use for one month.

Twenty-three days later, he presented with a two-day history of severe pain, intense photophobia, gritty sensation and appearance of a black spot in the left eye. Symptoms affected his routine activities but vision was however intact. Ocular examination revealed a best corrected vision of 6/6 in both eyes, intraocular pressure was 12mmHg and 14mmHg in the right and left eye respectively. There was severe progressive corneoscleral thinning in the left eye extending to about 3mm of the corneal stroma and about 6mm posterior to the limbus. A similar progressive corneoscleral thinning on the right eye was noticed but not as severe as the left eye. (Figures 1 and 2)

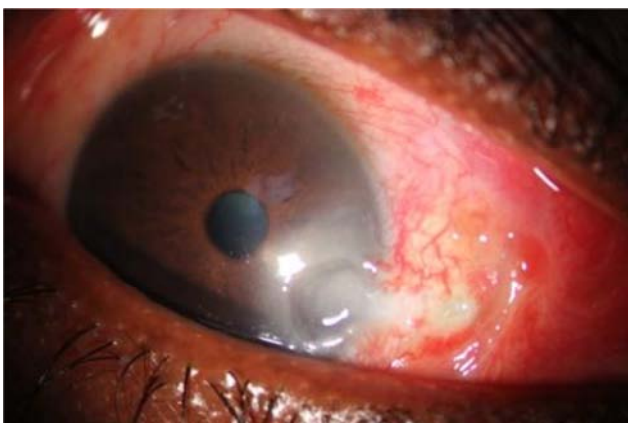


Figure 1. Right eye at presentation.

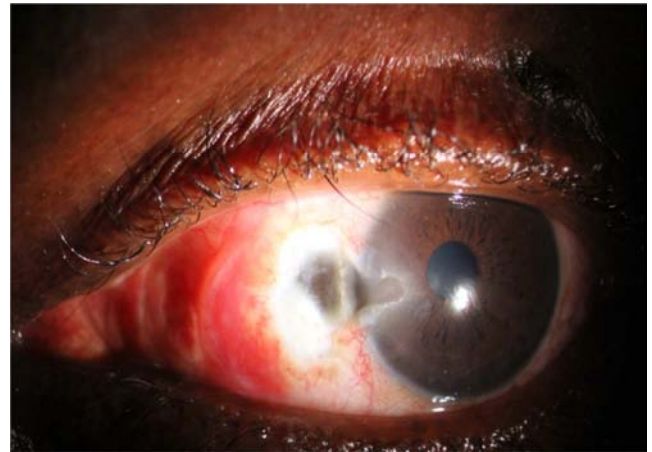


Figure 2. Left eye at presentation.

The anterior chamber was deep and no sign of inflammation, pupillary light reaction and intraocular pressures were normal but patient had been on topical anti-glaucoma medical therapy (Latanoprost) before surgery. Blood sample analysis (full blood count, electrolyte sedimentation rate and C-reactive protein) to identify any systemic evidence of inflammatory or infectious diseases were all negative. A diagnosis of bilateral post-terygium corneoscleral dellen was made. Patient declined any surgical intervention, hence was managed medically. The earlier prescribed topical dexamethasone was discontinued and he was commenced on topical ocular lubricant (hydroxymethyl cellulose), topical analgesics (diclofenac), topical antibiotics (ciprofloxacin) and alternate padding of the eyes as well as weekly outpatient monitoring. He had bandage contact lens application in the right eye following intense photophobia despite two weeks of medication. After six weeks of medical therapy, the conjunctival and corneal defects were replaced by granulation tissue and corneal epithelium in both eyes and complete healing was observed after eight weeks. However, patient developed recurrence of pterygium in the right eye. The photographs (figures 3-6) below illustrate the progression of the disease after initiation of medical therapy.

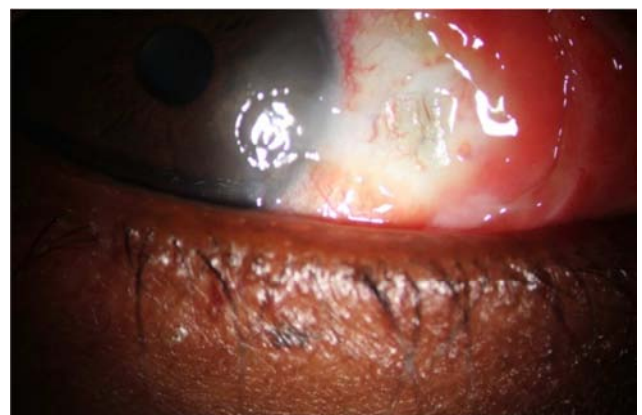

Figure 3. The right eye after three weeks of medical therapy.

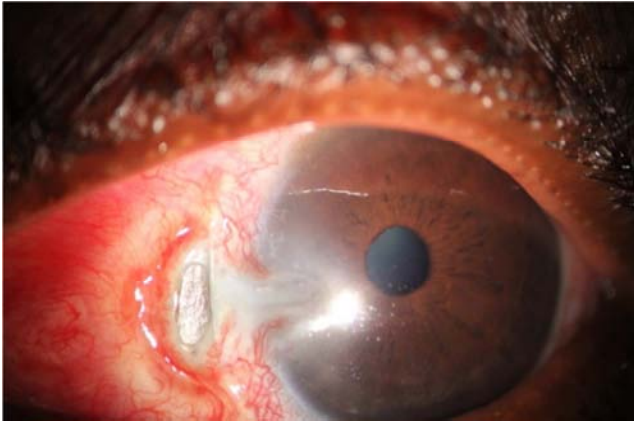


Figure 4. The left eye after three weeks of medical therapy.

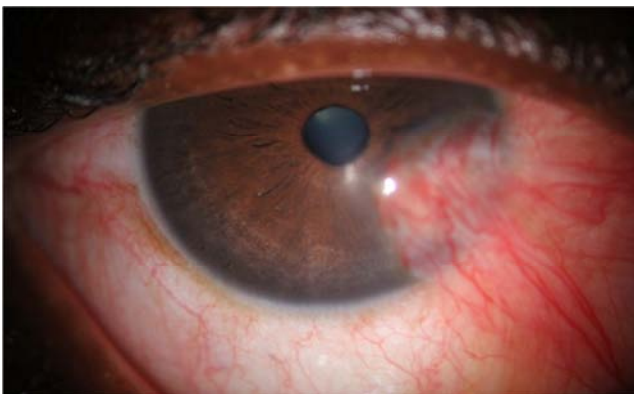


Figure 5. The right eye after 8 weeks of medical therapy and recurrence of the pterygium.

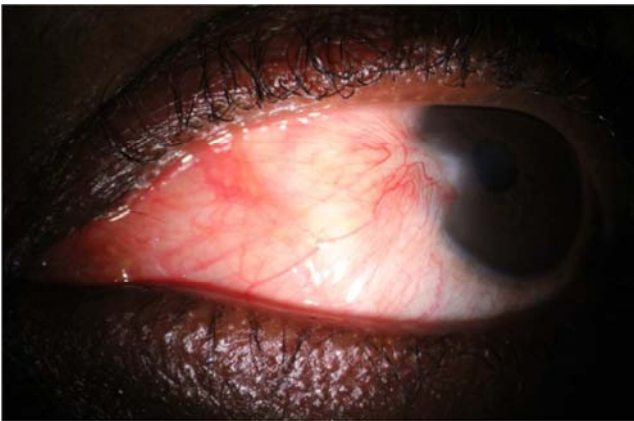


Figure 6. The left eye after 8 weeks of medical therapy.

3. Discussion

Corneoscleral dellen as a complication of pterygium excision is rarely anticipated and often times missed out during pre-surgery counseling as a likely surgical complication. In bare scleral technique, the sclera is exposed and denuded for some time and this theoretically might favor the onset of dellen [5]. The exposed sclera is prone to dryness and concomitant significant conjunctival edema inhibiting a normal tear distribution over the defect causing dryness more often in the presence of decreased tear

production [5, 9, 10]. Also, vigorous cauterization of episcleral vessels during surgery has been theoretically postulated to contribute to the onset of sclera dellen or perforation as it may cause local ischemia of the sclera [9]. Use of subconjunctival intraoperative anaesthesia containing vasoconstrictive agent (adrenaline) and post-operative topical corticosteroid may also be implicated in the onset of dellen as the former may cause local ischemia of the sclera while the latter would enhance collagenases, inhibit collagen synthesis and delay would healing [9]. In addition, exposure to a dusty and dry weather condition as well as presence of certain ocular and systemic diseases such as Sjögren syndrome, keratoconjunctivitis sicca, acne rosacea, atopic keratoconjunctivitis, diabetes (poor wound healing), herpes keratitis, autoimmune disease or vasculitis have also been proposed to be contributory factors to the onset of corneoscleral dellen [5]. However, the role of intraoperative antimetabolite use remains unclear and controversial in the onset of post pterygium dellen [11, 12].

In view of the likely risk factors postulated in the onset of post-ptyerygium dellen by different authors, some were applicable to this patient who had bilateral bare sclera pterygium excision technique with adjunctive therapy (5-Fluorouracil), under subconjunctival anesthesia with 2% Lidocaine with adrenaline, careful cauterization of the episcleral vessels and post-operative topical corticosteroids. Combinations of the aforementioned might have contributed to the development of bilateral corneoscleral dellen since there was no evidence of diabetes, autoimmune disease, Sjögren syndrome and other ocular or systemic conditions that may implicate the onset of a dellen. However, patient had symptomatic evidence of dry eye before surgery, probably due to the pterygium and was using benzalkonium chloride-preserved anti-glaucoma medication (latanoprost) which may also have contributed in part to the ocular surface dryness.

The duration of onset of the dellen post-surgery differ between patients and may range between 2 to 21 days as reported in most studies [4, 7–9, 12, 13] and rarely may occur up to one year after surgery [14, 15]. The dellen in this patient appeared after 21 days and 23 days of surgery in the left eye (with symptoms) and the right eye respectively. The authors believe that out of all the identified risk factors, perhaps reduced tear production and/or quality had the greatest impact in the onset of dellen as evidenced by the significant improvement and resolution of the dellen following intensive medical treatment with topical lubricants. Whereas other risk factors though present, were not particularly unusual as they conform to standard postoperative procedures for pterygium excision which many patients have had and this was the first case of corneal or sclera dellen.

4. Conclusion

Corneal or sclera dellen albeit a rare complication can occur in those at risk with reduced tear film production the major risk factor. Therefore, pre-operative ocular surface and tear

film assessment in all patients with pterygium prior to surgery might help to identify the risk of a postoperative dellen development. Furthermore, at-risk patients may benefit from inclusion of ocular wetting agent to the early postoperative medications to ensure adequate ocular lubrication.

Dellen highly predisposes to early recurrence of the pterygium and can be managed effectively by conservative method even though surgical intervention may also be indicated based on patients' preference.

References

- [1] Sehu KW, Lee WR. *Ophthalmic pathology: an illustrated guide for clinicians*. John Wiley & Sons, 2012.
- [2] Hirst LW. The Treatment Of Pterygium. *Surv Ophthalmol* 2003; 48: 145–180.
- [3] Ang LPK, Chua JLL, Tan DTH. Current concepts and techniques in pterygium treatment. *Curr Opin Ophthalmol* 2007; 18: 308–313.
- [4] Chen S, Noonan C. Scleral dellen complicating primary pterygium excision. *Eye* 2000; 14: 100–101.
- [5] Accorinti M, Gilardi M, Giubilei M. Corneal and Scleral Dellen after an Uneventful Pterygium Surgery and a Febrile Episode. 2014; 111–115.
- [6] Walkow T, Daniel J, Meyer CH, et al. Long-Term Results After Bare Sclera Pterygium Resection With Excimer Smoothing and Local Application of Mitomycin C. 2005; 24: 378–381.
- [7] Tsai Y, Lin J, Shy J. Acute Scleral Thinning After Pterygium Excision with Intraoperative Mitomycin C A Case Report of Scleral Dellen After Bare Sclera Technique and Review of the Literature. 2002; 21: 227–229.
- [8] Kymionis GD, Plaka A, Kontadakis GA, et al. Treatment of corneal dellen with a large diameter soft contact lens. *Contact Lens Anterior Eye* 2011; 34: 290–292.
- [9] Garcia-Medina JJ, Del-Rio-Vellosillo M, Zanon-Moreno V, et al. Severe scleral dellen as an early complication of pterygium excision with simple conjunctival closure and review of the literature. *Arq Bras Oftalmol* 2014; 77: 182–184.
- [10] Li M, Zhang M, Lin Y, et al. Tear function and goblet cell density after pterygium excision. *Eye* 2007; 21: 224–228.
- [11] Sridhar MS, Bansal AK, Rao GN. Multilayered amniotic membrane transplantation for partial thickness scleral thinning following pterygium surgery. *Eye* 2002; 16: 639–642.
- [12] Safianik B, Ben-Zion I, Garzozzi HJ. Serious corneoscleral complications after pterygium excision with mitomycin C. *Br J Ophthalmol* 2002; 86: 357–358.
- [13] Hicks RR, Irvine AR, Spencer WH, et al. Scleral dellen. *Arch Ophthalmol* 1975; 93: 88–89.
- [14] Saifuddin S, Zawawi A. Scleral changes due to mitomycin C after Pterygium excision: A report of two cases. *Indian J Ophthalmol* 1995; 43: 75–76.
- [15] Norliza WMW, Raihan IS, Azwa JA, et al. Scleral melting 16 years after pterygium excision with topical Mitomycin C adjuvant therapy. *Contact Lens Anterior Eye* 2006; 29: 165–167.