

---

# Repair Options Following Iatrogenic Bile Duct Injuries

Mohamed Salah Eldin Abdelhamid<sup>1</sup>, Ahmed Mohamed Sadat<sup>2</sup>, Ayman Hamdi Abouleid<sup>3</sup>,  
Amr Mohamed Aly Mohamed<sup>1</sup>, Mahmoud Ahmed Negida<sup>2</sup>, Ahmed Zaki Gharib<sup>3</sup>,  
Adel Morad Abdullah<sup>3</sup>

<sup>1</sup>Surgery Department, Bani-Suef Faculty of Medicine, Bani-Suef University, Bani-Suef, Egypt

<sup>2</sup>Surgery Department, Kasr Elaini Faculty of Medicine, Cairo University, Cairo, Egypt

<sup>3</sup>Surgery Department, October 6<sup>th</sup> Faculty of Medicine, October 6<sup>th</sup> University, Giza, Egypt

## Email address:

Mohamedsalah\_2000@hotmail.com (M. S. Abdelhamid), dr-ahmedelsadat\_@gmail.com (A. M. Sadat),

Ayman-abouleid@hotmail.com (A. H. Abouleid), Amr-bekhet@gmail.com (A. M. A. Mohamed), Dr.negida@yahoo.com (M. A. Negida),

dr.ahmedzaki@yahoo.com (A. Z. Gharib), adelmorad9@hotmail.com (A. M. Abdullah)

## To cite this article:

Mohamed Salah Eldin Abdelhamid, Ahmed Mohamed Sadat, Ayman Hamdi Abouleid, Amr Mohamed Aly Mohamed, Mahmoud Ahmed Negida, Ahmed Zaki Gharib, Adel Morad Abdullah. Repair Options Following Iatrogenic Bile Duct Injuries. *Journal of Surgery*.

Vol. 3, No. 5, 2015, pp. 50-55. doi: 10.11648/j.js.20150305.12

---

**Abstract:** In the era of laparoscopic cholecystectomy there was a dramatic increase in the incidence of the bile duct injuries. It was estimated that major bile duct injury occurred in approximately 0.2% to 0.4% during open cholecystectomy opposed to 0.6% to 0.8% of patients undergoing laparoscopic cholecystectomy. The aim was to highlight the repair options for the happened injury. Included in the study were 22 patients, 19 sustained injury at our hospital and 3 referral cases between Feb. 1999 to Nov2014. The treatment options were end to end anastomosis over T-tube or straight stent and Roux-en Y hepaticojejunostomy with or without stenting the anastomosis. Regarding the injuries, according to Strasberg there were 2 A, 4 D, 8 E1, and 5 E2. The three referral cases were choledochodoudonostomy. They were treated through simple ligation of cystic duct in two cases, end to end anastomosis in seven cases (three of them over T-tube and four over straight stent). The remaining fifteen cases were treated with Roux-en Y hepaticojejunostomy with or without stenting the anastomosis (22 patients with 24 interventions due to 2 redo). We concluded that proximal bile ducts are at greater risk with laparoscopic cholecystectomy even with expert surgeon. Satisfactory results were obtained with end to end anastomosis over either T-tube or straight stent, however these two options cannot be applied to all cases as it is difficult to be done with non dilated ducts, so Roux-en-Y hepaticojejunostomy is the most feasible among all types of repairs as it can be applied to most cases even those with non dilated common bile duct.

**Keywords:** Cholecystectomy, Laparoscopic, Bile Duct, Injuries

---

## 1. Introduction

The procedures of laparoscopic and open cholecystectomy are associated with a risk of iatrogenic bile duct injuries (IBDI), especially in the presence of inflammatory state of the gall-bladder. IBDI is a complex complication its treatment poses a challenge for the operating surgeon, and even the most careful treatment adversely affects the patient's life due to complications. [1] Bile duct injury during cholecystectomy, either laparoscopic or open, is a complex and serious complication, observed with a frequency of 0.2% to 0.4%. The frequency has not diminished and probably will not. Even as the knowledge advances, lesions continue to occur. [2] Less than half of these injuries are recognized

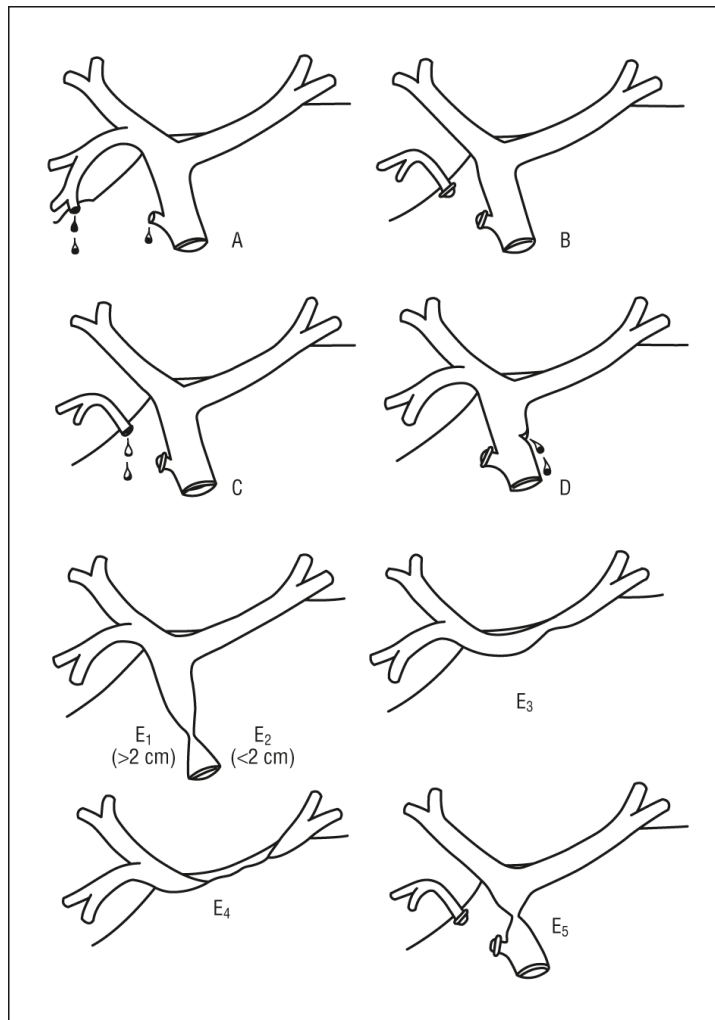
during the operation, most of them are recognized in the early postoperative period [1]. A variety of strategies are performed after the injury that are shaped according to different scenarios, type of injury, recognition, patients health status, surgeon's experience, hospital's facilities, ect. [3] There are several established iatrogenic injury patterns identified in laparoscopic cholecystectomy, the most prevalent type of injury involves mistaking the common bile duct for the cystic duct, this occurs just distal to the common hepatic duct, the common bile duct is clipped and divided, then gall bladder retracted up taking with it the common hepatic duct until it is divided again closer to the base of the liver, at the end there is distal common bile duct clipped, upper hepatic transected. The second most common type of

injury occurs when the distal clips are placed on the common bile duct, and the proximal clips on the cystic duct, the end result is a cystic duct stump leak with distal CBD obstruction. The third and least prevalent type is due to tenting of the CBD from excessive retraction, the cystic duct is identified and clipped, then the tented CBD is clipped and divided, the result is excision of a short segment of CBD with the cystic duct and gall bladder. In this case the patient presents with either biliary leak or obstruction, depending on clip placement. [4]

Right hepatic ductal injury occurs with and without anatomic variation. In case of normal anatomy, overzealous superior retraction leads to misinterpretation of the right hepatic duct for the cystic duct. In case the cystic duct from the right, both clipped and divided, then gall bladder removal leads to excision of portion of right ductal system [5].

Recently Strasberg *et al* [6] classified bile duct injury and strictures as class A; that is injury to small ducts in continuity with the biliary system, with a leak in the duct of Luschka or the cystic duct. Class B is injury to a sectoral duct with

resultant obstruction of part of the biliary system. Class C is injury to a sectoral duct with bile leak, bile leakage occurs from a duct not continuous with the biliary system. Class D is lateral injury to the extra hepatic biliary ducts. Class E1 is stricture more than 2cm. Class E2 is stricture less than 2 cm from the bifurcation of the right and left bile duct. Class E3 is stricture at the bifurcation of the right and left bile ducts. Class E 4 is strictures involving the right and left bile ducts, the left and right ducts are not continuous. Class E5 is complete occlusion of all bile ducts, including sectoral ducts (fig 1). When the common hepatic or common bile duct has been ligated, simple deligation and placement of a T-tube, one limb of which goes through the area of the damage suffices. [6] This procedure is associated with a high incidence of late bile duct strictures [7]. If part of the bile duct is accidentally resected but the proximal duct is well below the bifurcation of the hepatic duct and local circumstances are optimal, an acute reconstruction by a hepaticojejunostomy can be performed [8].



**Figure 1.** Strasberg classification of bile duct injury.

Among the surgical strategies for repair, hepaticojejunostomy yields the most favorable results. End-to-end repair has a high failure rate, with late stenosis and/or

dysfunction consequent to loss of substance from the duct and ischemia secondary to the dissection [9]. An anastomosis with a Roux-en-Y jejunal loop to prevent reflux of intestinal

contents to the anastomosis site is the best option for reconstruction. The anastomosis has to be performed with careful apposition of the biliary epithelium with the intestinal mucosa, using nonreactive absorbable sutures. The placement of anastomotic stents has been a matter of debate. Experienced groups have shown good results with and without stents [10]. Recently successful laparoscopic end-to-end choledochocholedochostomy was reported [11]. Although the percent of the injuries are small, the number is big so we aimed at checking the feasibility of the repair.

## 2. Patients and Methods

Between February 1999 and November 2014, 1486 cholecystectomies were operated upon. 292 (19.6%) were open cholecystectomies from the start mostly due to cardio pulmonary insufficiency, with contraindications to abdominal insufflations, others were due to associated pancreatitis, cholangitis or complicated acute cholecystitis. 1194 (80.4%) were laparoscopic cholecystectomies of which 1086 (91%) could be completed laparoscopically, only 108 (9%) converted to open cholecystectomies. 22 CBD injuries were operated upon. All patients whose injury was not acute had preoperative evaluation of biliary anatomy by means of percutaneous transhepatic cholangiography in case of biliary dilatation or ERCP. Patients with acute injury had intraoperative cholangiography to evaluate the biliary anatomy. Non progress or suspected injuries were the policy for conversion.

Written consents were signed by all patients and the form was approved from the ethical committee. There were no exclusion criteria.

The operative procedure

A – T-tube placement, a complete Kocher maneuver to loosen the lower end of the common bile duct, if at that stage the two ends of the common bile ducts could be approximated without any minimal tension, this procedure is completed, but in case of any tension the procedure is abandoned. T-tube is placed through a small separate stab in the lower segment then the two ends were reconstructed end-to-end [12].

B – Roux-en-Y hepaticojejunostomy was the choice when there were common bile ducts with lost segment the two ends cannot be approximated without tension and in high injuries. After the bile duct is exposed, a 70cm Roux-en-Y loop of jejunum is brought up to the site of the future anastomosis. The anterior row of sutures on the bile duct is placed first, working from the left to right, the sutures are passed from inside out and secured on a clamp with the needles left in place.

The anterior sutures are elevated to display the posterior duct wall. The posterior sutures are now placed, from jejunum to bile duct, again working from left to right. None of the sutures is tied but rather secured with a clamp until the entire row is completed [13]. If a trans-anastomotic stent to be placed, it is brought to the outside through the side of the intestinal loop or through the end of the loop after anchoring the loop in

both situations well to the anterior abdominal wall [13].

C – Straight stent: In case where the two ends could be approximated without undue tension, end-to-end anastomosis done over a straight stent [14].

After hemostasis was achieved, closed suction drains were placed, and the abdominal wall was closed. In the postoperative period, liver function tests were obtained. Patients were discharged when no fever or sepsis was found, when normalization of intestinal transit was demonstrated, and no hospital dependence was considered.

The interventions were done by 5 surgeons all did more than 100 laparoscopic cholecystectomy and in case of injury the senior handled the case.

## 3. Results

A total of 22 patients were included in this study. 19 patients had sustained the injury at our hospital, 3 patients were referred for reconstruction after a previous operative repair attempt. Two of our patients had had reconstruction twice.

There were two patients with recognized intra-operative injury (R.I.O.I.) during open cholecystectomy. Both of them were E1 as the proximal ductal stump was more than 2cm. one was managed by T-tube insertion, and did well. The other one treated by loop hepaticojejunostomy (stented) and showed early massive leak and explored twice, later the patient died due to organ failure.

In laparoscopically converted group of patients (nine), there were 8 patients with R.I.O.I., 3 were E1 and the defects were small and easy approximation could be achieved through duodenal mobilization, end-to-end done over a straight stent, all of them had smooth postoperative course without any complication. The other 5 patients with R.I.O.I. were E2 as the stump was 2cm or less and treated by Roux-en-Y loop, three of them were stented; the other two were not stented. The remaining one in the converted group presented with leak in early postoperative period and on exploration proved to be leaking cystic duct stump due to clip slipping. This case was converted before due to bleeding cystic artery and not due biliary injury. This case was classified as A and treated by ligation of the cystic duct stump.

In the laparoscopically completed patients there were 4 patients presented with leak and 4 presented with jaundice, two early (within two weeks) and two late (↑ 3 months). In the leaking group of patients, one was cystic duct leak (Class A) to which duct ligation done. The other three cases classified as E1 as upon exploration, there was a clip applied to the distal CBD with cystic duct leaking (pattern 2) the clip removed, duct ligated and T-tube inserted in two patient while the other a straight stent was inserted. The 4 cases presented with early and late jaundice, on exploration a clip was found entangling part of the wall of CBD with a varying degree with more or less duct closure with vary degrees of proximal dilatation to which a loop was applied without stenting the anastomosis.

The three cases that were operated elsewhere, all presented

with jaundice, the first on exploration proved to be choledochoduodenostomy to which Roux-en-Y was applied, the other two cases were E1 and E2 as there were CBD stricture one low and the other high but the actual cause was not obvious.

Regarding the redo cases, there were two, one presented with leak, operated upon twice then expired. The other one presented with jaundice and recurrent cholangitis, Roux-en-Y done again and the patient did well after this.

**Table 1.** Presentation and repair.

Access	Injury	Presentation	Classification	Repair
Open	2	2 R.I.O.I.	2 E1	1 T-tube 1 Loop (Stent)
Converted	9	8 R.I.O.I.	3 E1 5 E2	3 Tubes 5 Loop +3 Stent
Lap	8	1 Leak 4 Leak	1A 1A	Ligation Ligation
		4 Jaundice - 2 early - 2 late	3 E1 4D	2 T-tube, 1 Tube 4Loop
Referral	3	3 Jaundice	Choledochoduodonostomy E1 E2	Loop Loop Loop
Redo	2	1 Leak 1 Jaundice	Loop Loop	Loop LoopP
Total	24	10 R.I.O.I., 6 Leak, 8 Jaundice	2A, 4D, 9E1, 6E2, 2 Loop Choledochoduodonostomy	3 T-tube, 4 Tubes, 15 Loop, 2 Ligation

The cases presented with RIOI, postoperative leak or jaundice(early – late).

**Table 2.** Injury Classes according to Strasburg sustained at our hospital.

Access	No	Types	Percent
Open	2	2 E1	100%
Lap	17	2A 4D 6 E1 5 E2	11.7% 23.5% 35.2% 29.4%
Open + Lap	19	2A 4D 8 E1 5 E2	10.5% 21% 42% 26.3%

### 4. Discussion

Although common bile duct injury occurs more commonly in the early portion of surgeons’ learning curve [15]. Recent reports suggest that even surgeons with a great deal of experience with laparoscopic cholecystectomy have high rates (0.4% - 0.6%) of common bile duct injury [16]. Proximal bile duct is at greater risk for injury than it had been before laparoscopy and the problem of proximal bile duct injury persists while peak incidence may have passed, the

proportion with injuries of the proximal bile duct have remained relatively constant over time [10].

All the injuries included in our study were recognized mostly (more than half) intraoperatively or soon after the operation except two cases which were thought that they were due to partial clipping of the tented common bile duct, this partial clipping with recurrent attacks of cholangitis with some external reactions and fibrosis led to occlusion of a part of the extra hepatic duct system, this is supported by Jarnagin and Blumgart [10] who mentioned that some injuries evolve slowly or cause partial obstruction. This partial obstruction depended mainly of the degree of CBD entangled in the clip, as there were another two cases presented with jaundice early and were found to be also due to partial CBD clipping.

In the current study we got according to Strasberg 2A -4D – 8 E1 – 5 E2 – (among the 19 patients with iatrogenic injuries at our hospital not including the redo nor the referral accounting to 10.5% A – 21% D – 42% E1 – 26.3% E2. In the open group E1 was the only reported type of injury accounting to 100% of injuries, while in laparoscopic injuries E1 was 35.2% and E2 was 29.4% this means that proximal bile ducts are at risk for injury. This goes hand in hand with Jarnagin and Blumgart [10] who stated that the proximal bile duct is at greater risk for injury than it had been before laparoscopy. In the laparoscopic cholecystectomy patients there were 11.7% A – 23.5% D – 35.2% E1 – 29.4% E2, these were not in accordance with Murr et al [17] who found E1 to be 8%, E2 27% and E3 42%. This means that about half of their injuries near the bifurcation meaning more proximal injuries than those reported in our study. These sites of injury were reported early but now much decreased. If a common bile duct lesion is adequately identified and not associated with extensive damage or tissue loss and thus suitable for primary repair, an end to end anastomosis should be performed over a T-tube for drainage. This procedure is associated with a high incidence of late bile duct stricture, but provides optimal internal biliary drainage with a reasonable chance for cure. It also creates the optimal circumstances for reconstructive surgery by means of an elective hepaticojejunostomy at a later stage [8].

In the current study, the two cases with leaking cystic duct stump were treated by cystic duct ligation as the biliary tree was free without injury. The four cases presented with early and late jaundice, treated by hepaticojejunostomy without insertion of a trans-anastomosis stent as the proximal bile duct was dilated enough to fashion an easy anastomosis without the fear of later leak or stricture formation. All of these four cases did well with smooth postoperative convalescence.

There were 8 cases with E1 two were in the open cholecystectomy, six cases in the laparoscopic group of patients. One case in the open cholecystectomy and two cases in laparoscopic cholecystectomy were treated by end to end anastomosis over a T-tube after mobilization of the duodenum without any tension, the other one in the open group was isolated right hepatic duct injury (IRHDI). That one treated with anastomosis over a stent, the patient

developed postoperative leak twice and expired due to septic complications. It was stented as the duct caliber was small with thin wall. The other four were treated by end to end anastomosis over a straight stent, omitting the side effects of T-tube and preserving the normal pathway of the bile, the only proposed limit to use this technique was the idea of its association with some forms of pancreatitis, but we did not encounter such complication in any of our patients.

Regarding the E2 there were five cases treated by Roux-en-Y, three stented and the other two, without stent. This was to guard against post operative edema at the level of the anastomosis, although transit is enough to produce obstruction, high intraductal pressure and leakage. The same results were obtained by Mercado et al [18] who stated that good results are obtained with Roux-en-Y hepaticojejunostomy after complex injuries. In our patients we did not use stents whenever there was ductal dilatation as this was associated with easy anastomosis technically with fewer tendencies to produce edema at the level of anastomosis, so the use of trans anastomotic stents has to be selective according to the individual characteristics of each patient and the experience of each surgeon. According to the previous statement the three cases with previous surgery were treated by a loop without stents.

Several studies seem to indicate at least a 2-fold increase in bile duct injuries (BDI) since the inception of laparoscopic cholecystectomy. Moreover, injuries seem to be more proximal, seem to be revealed earlier, are expressed by leaks more often than by strictures, are repaired more frequently by no specialists (either during the index operation or soon after), and appear to be more often associated with loss of substance and ischemia. [19].

Roux-en-Y hepaticojejunostomy anastomosis is the treatment of choice for common hepatic duct injury type E2. It has been performed laparoscopically with the advancement of laparoscopic skill. Recently, a telemanipulative robotic surgical system was introduced, providing laparoscopic instruments with wrist-arm technology and 3-dimensional visualization of the operative field [20].

Late complications arising after bile duct injury (BDI) include biliary strictures, hepatic atrophy, cholangitis and intra-hepatic lithiasis. Later, fibrosis or even secondary biliary cirrhosis and portal hypertension can develop, enhanced by prolonged biliary obstruction associated with recurrent cholangitis. Secondary biliary cirrhosis resulting in associated hepatic failure or digestive tract bleeding due to portal hypertension is a substantial risk factor for morbidity and mortality after bile duct repair [21].

In the open cholecystectomy 100% of the injuries were recognized intraoperatively, while in case of laparoscopic cholecystectomy we had 8 cases with RIOI out of 17 cases (47%). Nine out of the 17 laparoscopic cholecystectomy cases (53%) were recognized post operatively and this was expected as identification of injuries in open surgery is much easier than during laparoscopic surgery.

Hepaticojejunostomy is the easiest way to deal with such injuries. Regarding feasibility, it is the most feasible between

all types of repairs. Doing a repair on T tube or straight stent seems to be physiological and anatomical but on the ground of feasibility, these are not feasible in cases where there is loss of a segment, and cases with retraction of the ends and in cases where the ends are crushed especially the distal end.

## 5. Conclusion

Proximal bile ducts are at greater risk with laparoscopic cholecystectomy even with expert surgeon. Satisfactory results are obtained with end to end anastomosis over either T-tube or straight stent, however these two options cannot be applied to all cases as it cannot be done to non dilated ducts, so Roux-en-Y hepaticojejunostomy is the most feasible among all types of repairs as it can be applied to all cases even the non dilated common bile ducts.

## References

- [1] Głuszek S, Kot M, Bałchanowski N, et al. Iatrogenic bile duct injuries--clinical problems Pol Przegl Chir. 2014 Jan; 86(1): 17-25.
- [2] Walsh RM, Henderson JM, Vogt DF, et al. Trends in bile duct injuries from laparoscopic cholecystectomy. J Gastrointest Surg. 1998; 2: 458-462.
- [3] Stewart L, Way LW. Bile duct injuries during laparoscopic cholecystectomy; Factors that influence the results of treatment. Arch Surg. 1995; 130: 1123-1130.
- [4] Branum G, Schmit C, Baillie J, et al.: management of major biliary complications after laparoscopic cholecystectomy. Ann surg. 1993; 217: 532-41.
- [5] West Cott CJ, Pappas TN. Benign biliary strictures. In Cameron JL (ed). Current surgical therapy.: st. Louis, Missouri, Mosby. 1998; pp 425-434, 6<sup>th</sup> ed.
- [6] Strasberg SM, Herti M, Soper Nj.: Analysis of the problem of biliary injury during laparoscopic cholecystectomy. J Am Coll surg. 1995; 180: 101-125.
- [7] Solheim K, Buanes T.: Bile duct injury. Int Surg. 1995; 80 (4): 361-4.
- [8] Gouma DJ, Obertop H.: Operative bile duct injury. In Taylor I and Johnson CD (eds). Recent advances in surgery.: London, Harcourt Publishers Limited. 2001; pp 139-150.
- [9] Mercado MA, Orozco H, Martinez LM, et al. Survival and quality of life after bile duct reconstruction. HPB surg. 2000; 2: 321-324.
- [10] Jarnagin WR, Blumgart LH. Operative repair of bile duct injuries involving the hepatic duct confluence. Arch surg. 1999; 134: 769-775.
- [11] Choi YS, Han YS, Lee TG, et al.: Laparoscopic end to end choledochocholedochostomy. Lap endo Surg. 2006; 16 (3): 264-6.
- [12] Ludwig K, Bernhardt J, Steffen H et al. Contribution of I.O.C. to the incidence and outcome of common bile duct injury during LC. Surg Endosc, 2002; 16 (7): 1098-104.

- [13] Lillemoe KD, Melton GB, Cameron JL, et al. Postoperative bile duct strictures: management and outcome in the 1990. *Annsurg.* 2000; 232: 430-441.
- [14] De Ledinghen V, Person B, Legoux JL, et al. Prevention of biliary stent occlusion by ursodeoxycholic acid plus norfloxacin: a multicenter randomized trial. *Dig dis sci.* 2000; 45: 145-150.
- [15] Woods MS, Traverso WL, Kozarek RA, et al.: Characteristics of biliary tract complications during laparoscopic cholecystectomy. *Am J Surg.* 1994; 167: 27-34.
- [16] Flum DR, Koepsell T, Heagerty P, et al. Common bile duct injury during laparoscopic cholecystectomy and the use of intraoperative cholangiography. *Arch surg.* 2001; 136 (11): 1287-92.
- [17] Murr MM, Gigot JF, Nagorney DM et al. Long term results of biliary duct injuries. *Arch Surg.* 1999; 134 (6): 604-610.
- [18] Mercado MA, Chan C, Orozco H, et al. To stent or not to stent bilioenteric anastomosis after iatrogenic injury. *Arch Surg.* 2002; 137 (1): 60-63.
- [19] Fingerhut A, Dziri C, Garden OJ, et al. ATOM, the all-inclusive, nominal EAES classification of bile duct injuries during cholecystectomy *Surg Endosc.* 2013 Dec; 27 (12): 4608-19.
- [20] Prasad A, De S, Mishra P, Tiwari A. Robotic assisted Roux-en- Y hepaticojejunostomy in a post-cholecystectomy type E2 bile duct injury. *World J Gastroenterol.* 2015 Feb 14; 21(6): 1703-6.
- [21] Barbier L, Souche R, Slim K et al. Long-term consequences of bile duct injury after cholecystectomy. *J Visc Surg.* 2014 Sep; 151(4): 269-79.