



Anterior Segmental Decompression and Interbody Fusion for Multi-segmental Cervical Spondylotic Myelopathy in the Elderly

Guowei Zhang, Zhengbin Cai, Qiuling Liu, Zhisheng Ji, Yuhao Yang, Hongsheng Lin*

Department of Orthopedics, the First Affiliated Hospital of Jinan University, Guangzhou, China

Email address:

tlinhsh@jnu.edu.cn (Hongsheng Lin)

*Corresponding author

To cite this article:

Guowei Zhang, Zhengbin Cai, Qiuling Liu, Zhisheng Ji, Yuhao Yang, Hongsheng Lin. Anterior Segmental Decompression and Interbody Fusion for Multi-segmental Cervical Spondylotic Myelopathy in the Elderly. *Journal of Surgery*. Vol. 5, No. 4, 2017, pp. 58-61.

doi: 10.11648/j.js.20170504.11

Received: May 25, 2017; Accepted: June 5, 2017; Published: July 21, 2017

Abstract: To explore the clinical effect of anterior segmental decompression and interbody fusion in treatment of elderly patients with complex cervical spondylotic myelopathy of three segments or more, 50 patients, with titanium plate internal fixation bone fusion underwent anterior cervical decompression and multi segmental cervical spondylosis, were collected. Parameters of operation time, intraoperative blood loss, JOA score 1 week before and after, 12 months after operation, cervical X-ray, CT and MRI before and after operation were measured. Clinical symptoms and the improvement of JOA, internal fixation and bone grafting fusion, cervical standard sagittal Cobb angle, lateral fusion segment of vertebral body height (height of anterior border, HAB) and posterior height (height of posterior border, HPB), were observed. Operation time was 90 ~ 150 minutes, average 120 minutes. The amount of bleeding 150 ~ 450 ml, average 325.5 ml. Mean follow-up time was 15.1 months. 2 weeks after operation, sympathetic symptoms were improved obviously, lower limb muscle strength was increased, physical activity was significantly improved, and anesthesia of double upper limbs disappeared. Except for the 3 cases who had serious cervical spinal cord injury showed no obvious recovery, the other 47 patients showed significant improved neurological recovery. X-ray results of 12 months after operation showed that 50 cases of fused intervertebral, intervertebral height and lordosis maintained good. In general, anterior segmental decompression and bone graft fusion and titanium plate internal fixation operation is a safe and effective operation for treating the three section and above cervical spondylotic myelopathy, worth recommending.

Keywords: Cervical Spondylosis, Segmental Decompression, Bone Graft, Fusion

1. Introduction

Cervical spondylotic myelopathy is the most severe degenerative disease of cervical spine, with high incidence. The surgical incision is located in front of the neck. The vertebral body is needed to be exposed through the anterior cervical sheath and visceral sheath. The surgical procedure is complex, with high difficulty and high risk. Anterior multilevel cervical decompression and fusion can completely and directly release the compression from the front of the spinal cord, can recover the normal vertebral height and physiological curvature of the cervical spine, with fewer fusion segments and less impact on the cervical activity [1]. The current study tries to explore the clinical effect of anterior

segmental decompression and interbody fusion on multi-segmental cervical spondylotic myelopathy in the elderly.

2. Methods

2.1. General Data

From Nov 2008 to Jun 2011, 50 case of elderly with complex cervical spondylotic myelopathy of three segments or more were collected and followed up with 2 years. All the patients were diagnosed by MRI. 62 cases of male and 56 cases of female, aging from 60 to 78, with average 60.2 years old. The duration of the disease was 3 to 71.5 months, of

average 25.6 months. Clinical symptoms: neckache, discomfort or stiff feeling, activity inconvenience, upper limb numbness, holding instability, positive Hoffmann or Babinski symptoms, urine obstruction and etc., chronic onset and progressive aggravated. 36 cases showed 4 damaged segments and 14 cases of 3 segments. X-ray, CT and MRI examinations were determined before surgery.

2.2. Inclusion Criteria

Patients with the following characters were included: (1) in the diagnosis criteria for cervical spondylotic myelopathy from the summary of the 2nd National Symposium on Cervical Spondylosis; (2) impacted segments < 3 (continuous or discontinuous), severe degenerative symptoms making the compression on the spinal cord, meeting the criteria with anterior operation; (3) ages > 60 years old; (4) stable condition and clear consciousness, can cooperate to collect clinical data; (5) with consent.

2.3. Exclusion Criteria

Patients with the following characters were excluded: (1) accompanied with other diseases, such as severe kidney and liver disease, diabetes, blood disease, cancer or other organ failure; (2) with other cervical diseases, such as cervical amyotrophic lateral sclerosis, spinal canal tumor, secondary adhesion arachnoiditis and peripheral neuritis and etc.; (3) with mental disease or those do not cooperate.

2.4. Surgical Method

The surgeries were carried out as follows: take the left sternocleidomastoid as in incision entry or the cervical transverse incision approach as entry; take both the neck long muscle as the safety line; take segmental single gap decompression and single vertebral resection combined with bone graft fusion and fixation. (1) remove the C3 ~ 4, C4 ~ 5, C5 ~ 6, C6 ~ 7 intervertebral disc; (2) 1/5 ~ 1/4 of C3, C7 vertebrae, 2/5 ~ 1/2 of C5 vertebrae and all C4, C6 vertebrae; (3) remove osteophyte in the vertebral posterior margin; (4) remove the back of Luschka joints. Excision procedure: (1) remove the lesion discs, the cartilage and adjacent bone tissue, left out only a thin bone tissue in the vertebral posterior margin; (2) use the bone clamp to remove the residual bone tissue of C4 and C6, retain the remaining C5 vertebrae, clear the bone groove for implanting; (3) with meninges knife, gently separate the disc, vertebral posterior margin and posterior longitudinal ligament gap; with vertebral pliers to remove disc, osteophyte in the vertebral posterior margin and part of the Luschka joint. Bone implanting procedure: according to the size of the bone groove, put 2 vertebrae 1.5 mm larger than the groove into the implant place, careful to protect C5 vertebrae for fragile. Postoperative management: normal application of antibiotics, hormones, dehydrating for 3 days, neck stitches removal at day 6, iliac stiches removal at day 10 and conventional wearing neck brace at week 8.

2.5. Observational Indexes

Record the operation time and volume of bleeding. Use to the JOA score system as the efficacy evaluation standard. Record the JOA values preoperative, 1 w and 12 month postoperative, and count the improve rate of the last follow-up. Postoperative improvement rate is divided into four levels: excellent (higher than 80%), good (50% - 79%), pass (5% - 49%) and poor (lower than 5%). Standard cervical Cobb’s angle, height of anterior vertebrae (HAB) and posterior vertebrae (HPB) were calculated. Postoperative improvement rate = (postoperative score - preoperative score) / (17 - preoperative score) × 100%.

2.6. Statistical Analysis

Data were analyzed by SPSS 20.00, dependent *t*-tests and Pearson correlations were used when comparing measures between the two groups. P < 0.05 means statistical significant differences.

3. Results

3.1. General Data

The operation time ranged from 90 to 150 min, with average 120 min. Bleeding volume was 150 – 450 mL, with average 325.5 mL. No cases died, infected or recurrent laryngeal nerve injured. 3 cases showed cerebrospinal fluid leakage. The follow-up time was 12 – 24 months, with average 15.1 months.

3.2. Postoperative Nerve Function Improvement

2 weeks post operation, the nerve symptoms were significantly improved, muscle strength of lower limb increased, physical activity was significantly improved and abnormal feelings of both upper limbs disappeared. 2 cases with severe cervical spinal cord injury before operation, showed no improvement; other 48 cases the nerve function significantly improved. The results of postoperative improvement rate were: 28 cases of excellent, 11 cases of good, 9 cases of pass and 2 cases of poor. The results were shown in Table 1.

Table 1. JOA score (x ± s, n = 50).

Index	Preoperative	Postoperative
Upper limb motor function	2.02 ± 0.35	3.14 ± 0.46
Lower limb motor function	2.11 ± 0.56	3.35 ± 0.32
Sensory function	2.75 ± 0.57	4.13 ± 0.73a
Bladder function	2.01 ± 0.44	2.46 ± 0.58
Total	8.13 ± 2.15	14.51 ± 2.05a

a, compared with preoperative, P < 0.05.

3.3. The Results of Cobb’s Angle, HAB and HPB

1 week after surgery, Cobb’s angle, HAB and HPB values were significantly improved (P < 0.01); the value of last followup significantly improved (P < 0.05) when compared with preoperative, however showed no difference with 1 w

after surgery. Data can be found in Table 2.

Table 2. Cobb's angle, HAB and HPB score ($\bar{x} \pm s$, $n = 50$).

Time point	Cobb's angle	HAB (mm)	HPB (mm)
Preoperative	7.8 ± 1.8	48.3 ± 3.6	44.6 ± 1.8
1w postoperative	9.1 ± 2.1a	49.9 ± 2.3a	46.0 ± 2.6a
Last followup	8.8 ± 2.3b	49.7 ± 3.2b	45.8 ± 3.5b

a, compared with preoperative, $P < 0.01$;

b, compared with preoperative, $P < 0.05$;

3.4. Postoperative Cervical Spinal Canal Decompression

PA & LAT X-ray results of all the 50 patients 12 months after surgery showed intervertebral fusion, intervertebral height and spinal curvature maintained good (Figure 1).

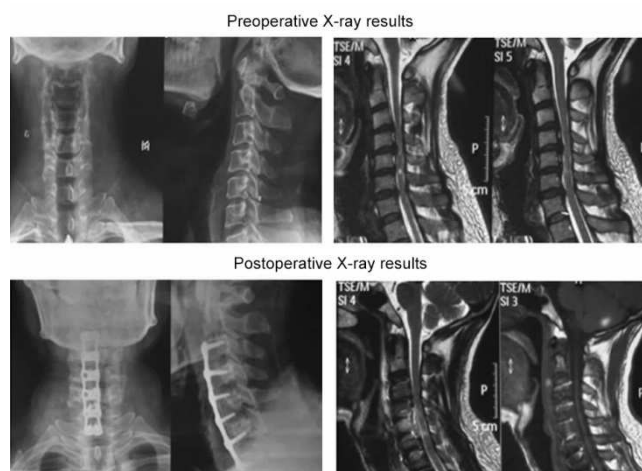


Figure 1. The representative PA & LAT X-ray results of patients preoperative and postoperative.

4. Discussion

The clinical manifestations of cervical spondylosis are complex, such as neck and shoulder pain radiated to the headrest or upper limb, accompanied with limb and finger numbness; postural vertigo, accompanied with nausea, limb cold, sweating and other sympathetic nerve symptoms; or even lower limbs stiff, walking difficulty or paralyzed [2]. The incidence of cervical spondylosis is about 3.8% - 17.6% [3]. As people study, work and lifestyle changes dramatically, the risk factors of cervical spondylosis is increasing. Until now, surgery is a commonly accepted method for the treatment of cervical spondylosis. Usual anterior, posterior and combined surgical methods are widely used in clinical [4].

There are normal anterior decompression fusion method: (1) anterior decompression + bone graft fusion; (2) anterior decompression + bone graft fusion and internal fixation; (3) anterior decompression + interbody implantation fusion in bone graft fusion [5]. Anterior decompression + bone graft fusion method always take the right lateral transverse incision, exposed from the carotid sheath and visceral compartment to the front of the vertebral body, located by the C-arm. Distract the intervertebral space, remove the proliferative spur of the

compressed vertebrae and crochet joint, degenerated intervertebral disc and hyperplastic posterior longitudinal ligament and he adhesions [6]. Make vertebral bone graft, implant autologous or allogeneic bone, thus to guarantee the volume, the height and the morphology of spinal canal and nerve root canal. Recent years, studies show that because of the characteristics of large activity and poor stability of cervical vertebrae, there are bone graft loss and collapse induced cervical deformity, pseudoarthrosis and other complications during the anterior cervical decompression and bone graft fusion [7]. Also long time external fixations are required postoperative, for early break achievement and for better lateral intervertebral fusion [8, 9].

Recently, in order to overcome the complications, to get the stability of the operational segment and to increase the incidence of fusion, anterior cervical fixation come into light and develops rapidly. As the clinical application of ACDF, anterior decompression is found accompanied with other complications, like local pain, numbness, fractures and infections, with incidence of 20% - 25% literally [10-12]. Thus, artificial bone grafts are used, but with less fusion, making the difficult choices of perfect implanting material [13]. Interbody fusion devices came into the sight. Early Cage was made of metallic materials, however, because of the debris effect, hard to absorb, always induced complications like metal corrosion, stress block, foreign body sensation and metal structure loose, the material is replaced by carbon fiber, PEEK and other polymer materials [14-16]. Combined usage of cervical Cage and plate increases the stability and the chances of fusion, increases patients' early off-bed activity and decreases days of hospitalization and complications [17, 18]. The current study suggest that titanium plate internal fixation with decompression and bone grafting is an effective and safe way for the treatment of cervical spondylosis myelopathy with three or more lesion segments, worth of promotion and wide spread.

5. Conclusion

The clinical effect of anterior segmental decompression and interbody fusion in treatment of elderly patients with complex cervical spondylosis myelopathy of three segments or more are investigated in the current research and the results show that anterior segmental decompression and bone graft fusion and titanium plate internal fixation operation is a safe and effective operation for treating the three section and above cervical spondylosis myelopathy, worth recommending.

Acknowledgments

The authors declare no conflict of interests. This work was supported by the Natural Science Foundation of Guangdong Province (2014A030313357), the National Health and Family Planning Commission of the People's Republic of China (No. W2013ZT083) and Medical Scientific Research Foundation of Guangdong Province (A2016038).

References

- [1] Gok, B., D. M. Sciubba, G. S. McLoughlin, M. McGirt, S. Ayhan, J. P. Wolinsky, A. Bydon, Z. L. Gokaslan, and T. F. Witham, Surgical treatment of cervical spondylotic myelopathy with anterior compression: a review of 67 cases. *J Neurosurg Spine*, 2008, 9 (2): 152-7.
- [2] Hirai, T., S. Kawabata, M. Enomoto, T. Kato, S. Tomizawa, K. Sakai, T. Yoshii, K. Sakaki, K. Shinomiya, and A. Okawa, Presence of anterior compression of the spinal cord after laminoplasty inhibits upper extremity motor recovery in patients with cervical spondylotic myelopathy. *Spine (Phila Pa 1976)*, 2012, 37 (5): 377-84.
- [3] Li, Y., H. Wang, Y. Wang, and H. Liu, [Effect of Anterior Cervical Spinal Cord Compression Factor in Treatment of Cervical Spondylotic Myelopathy]. *Zhongguo Xiu Fu Chong Jian Wai Ke Za Zhi*, 2015, 29(9): 1099-103.
- [4] Cho, Y., The Change of Range of Motion at Anterior Compression of the Cervical Cord after Laminoplasty in Patients with Cervical Spondylotic Myelopathy. *Korean J Spine*, 2016, 13(4): 177-182.
- [5] Zhou, X., P. Cai, Y. Li, H. Wang, S. Xia, and X. Wang, Posterior or Single-stage Combined Anterior and Posterior Approach Decompression for Treating Complex Cervical Spondylotic Myelopathy Coincident Multilevel Anterior and Posterior Compression. *Clin Spine Surg*, 2016.
- [6] Hirai, T., T. Yoshii, Y. Arai, K. Sakai, I. Torigoe, H. Maehara, M. Tomori, T. Taniyama, H. Sato, and A. Okawa, A Comparative Study of Anterior Decompression With Fusion and Posterior Decompression With Laminoplasty for the Treatment of Cervical Spondylotic Myelopathy Patients With Large Anterior Compression of the Spinal Cord. *Clin Spine Surg*, 2017.
- [7] Singh, K., A. R. Vaccaro, J. Kim, E. P. Lorenz, T. H. Lim, and H. S. An, Enhancement of stability following anterior cervical corpectomy: a biomechanical study. *Spine (Phila Pa 1976)*, 2004, 29 (8): 845-9.
- [8] Suzuki, A., K. Tamai, H. Terai, M. Hoshino, H. Toyoda, S. Takahashi, K. Hayashi, S. Ohyama, and H. Nakamura, Clinical Outcome of Cervical Laminoplasty and Postoperative Radiological Change for Cervical Myelopathy With Degenerative Spondylolisthesis. *Spine (Phila Pa 1976)*, 2016, 41 (23): 1808-1812.
- [9] Dean, C. L., J. P. Gabriel, E. H. Cassinelli, M. J. Bolesta, and H. H. Bohlman, Degenerative spondylolisthesis of the cervical spine: analysis of 58 patients treated with anterior cervical decompression and fusion. *Spine J*, 2009, 9 (6): 439-46.
- [10] Kim, H. C., H. S. Jun, J. H. Kim, I. B. Chang, J. H. Song, and J. K. Oh, The Effect of the Pedicle-Facet Angle on Degenerative Cervical Spondylolisthesis. *J Korean Neurosurg Soc*, 2015, 58 (4): 341-5.
- [11] Suzuki, A., M. D. Daubs, H. Inoue, T. Hayashi, B. Aghdasi, S. R. Montgomery, M. Ruangchainikom, X. Hu, C. J. Lee, C. J. Wang, B. J. Wang, and H. Nakamura, Prevalence and motion characteristics of degenerative cervical spondylolisthesis in the symptomatic adult. *Spine (Phila Pa 1976)*, 2013, 38 (17): E1115-20.
- [12] Park, M. S., S. H. Moon, H. M. Lee, S. W. Kim, T. H. Kim, B. K. Suh, and K. D. Riew, The natural history of degenerative spondylolisthesis of the cervical spine with 2- to 7-year follow-up. *Spine (Phila Pa 1976)*, 2013, 38 (4): E205-10.
- [13] Ashkenazi, E., Y. Smorgick, N. Rand, M. A. Millgram, Y. Mirovsky, and Y. Floman, Anterior decompression combined with corpectomies and discectomies in the management of multilevel cervical myelopathy: a hybrid decompression and fixation technique. *J Neurosurg Spine*, 2005, 3 (3): 205-9.
- [14] Liu, J. M., X. Xiong, A. F. Peng, M. Xu, X. Y. Chen, X. H. Long, R. Xu, and Z. L. Liu, A comparison of local bone graft with PEEK cage versus iliac bone graft used in anterior cervical discectomy and fusion. *Clin Neurol Neurosurg*, 2017, 155: 30-35.
- [15] Yson, S. C., J. N. Sembrano, and E. R. Santos, Comparison of allograft and polyetheretherketone (PEEK) cage subsidence rates in anterior cervical discectomy and fusion (ACDF). *J Clin Neurosci*, 2017, 38: 118-121.
- [16] Farrokhi, M. R., Z. Nikoo, M. Gholami, and K. Hosseini, Comparison Between Acrylic Cage and Polyetheretherketone (PEEK) Cage in Single-level Anterior Cervical Discectomy and Fusion: A Randomized Clinical Trial. *Clin Spine Surg*, 2017, 30 (1): 38-46.
- [17] Farrokhi, M. R., Z. Nikoo, M. Gholami, and K. Hosseini, Comparison between Acrylic Cage and Polyetheretherketone (PEEK) Cage in Single-Level Anterior Cervical Discectomy and Fusion: A Randomized Clinical Trial. *Clin Spine Surg*, 2016.
- [18] Chen, Y., G. Lu, B. Wang, L. Li, and L. Kuang, A comparison of anterior cervical discectomy and fusion (ACDF) using self-locking stand-alone polyetheretherketone (PEEK) cage with ACDF using cage and plate in the treatment of three-level cervical degenerative spondylopathy: a retrospective study with 2-year follow-up. *Eur Spine J*, 2016, 25 (7): 2255-62. a.