



Total Thyroidectomy Without Prophylactic Central Cervical Lymph Node Dissection: Is It Oncologically Safe in Patients with Early-Stage Papillary Thyroid Carcinoma

Tamer Abd-Elhafez El-Bakary*, Mohamed Aly Mlees

General Surgery Department, Tanta University Hospital, Tanta, Egypt

Email address:

telbakary@yahoo.com (T. Abd-Elhafez El-Bakary)

*Corresponding author

To cite this article:

Tamer Abd-Elhafez El-Bakary, Mohamed Aly Mlees. Total Thyroidectomy Without Prophylactic Central Cervical Lymph Node Dissection: Is It Oncologically Safe in Patients with Early-Stage Papillary Thyroid Carcinoma. *Journal of Surgery*. Vol. 5, No. 6, 2017, pp. 124-129. doi: 10.11648/j.js.20170506.17

Received: November 5, 2017; **Accepted:** November 15, 2017; **Published:** December 11, 2017

Abstract: Background: The necessity and the benefits of prophylactic central cervical lymph node dissection (PCLND) in clinically node negative patients with early-stage papillary thyroid carcinoma (PTC) remain controversial. Objective: to evaluate the safety of total thyroidectomy without PCLND in clinically node-negative early-stage PTC. Patients & Methods: 34 patients with T1 or T2 & N0 PTC were included in the study and submitted to total thyroidectomy without PCLND. Post-operatively, all patients received TSH suppression therapy & radio-active iodine (RAI) ablation. Any suspicious local neck recurrence during the follow up was confirmed cytologically and treated by RAI ablation. Results: The mean age was 42.1 years. 55.9% of patients were less than 45 years and 44.1% were 45 years old or more. Male to female ratio was 10:24. T1 was found in 14 cases & T2 in 20 cases. Total thyroidectomy was successfully done for all the cases. Central cervical lymph nodes sampling was done in 5 cases. Excised lymph nodes were found in 8 specimens; 5 cases with lymph node sampling (14.7%) and 3 cases (8.8%) with accidental lymph node excision during thyroidectomy. only 6 of these 8 patients (17.6%) showed positive metastasis (pN1). No recurrent laryngeal nerve injury was reported. In 12 patients (35.3%), temporary hypocalcemia was encountered. The mean follow up period was 34.6 months. There were 2 recurrences (5.9%); 1 in the central & 1 in the lateral neck compartment. All recurrences were treated by RAI ablation. No distant metastasis or mortality was reported. Conclusion: total thyroidectomy without PCLND in clinically node-negative early stage PTC is an excellent treatment option that gives adequate loco-regional control of the disease with low rate of surgical complications. Close follow up for longer periods is needed.

Keywords: Papillary Thyroid Carcinoma, Cervical Lymph Node Dissection, Total Thyroidectomy

1. Introduction

Papillary thyroid carcinoma (PTC) is the commonest type of thyroid cancer representing more than 80% of all cases [1]. It is an indolent type of cancer with 10-year survival rate of about 90% after the proper treatment [2]. Metastasis in cervical lymph nodes is common in PTC; its incidence is widely variable in the literature with a rate of about 60-90% [3, 4]. However, the presence of cervical lymph node metastasis does not have a significant effect on the overall survival with increased disease-related mortality of only 1-3% in node-positive patients if

compared to node-negative patients [5].

In node positive patients, the proper surgical approach is total thyroidectomy with neck dissection of the affected compartment [6]. However, lymph node dissection in clinically node-negative patients i.e. prophylactic cervical lymph node dissection remains a matter of debate. Proponents of prophylactic cervical lymph node dissection claims that it removes the microscopic disease, facilitates radio-active iodine (RAI) administration, maintains lower levels of thyroglobulin which allows better follow up, and theoretically reduces local recurrence [7-9]. On the other hand, opponents of prophylactic cervical lymph node

dissection believe that omitting this prophylactic dissection during total thyroidectomy for PTC does not significantly affect the recurrence rates or the overall survival with significant reduction of the rate of surgical complications e.g. hypocalcemia and recurrent laryngeal nerve injury [10, 11]. The aim of this study is to evaluate the oncological outcomes of total thyroidectomy alone without prophylactic central lymph node dissection (PCLND) in clinically node-negative patients with early stage PTC.

2. Patients & Methods

2.1. Patients

This study was conducted between November 2010 and August 2015. It included 34 patients presented with early-stage PTC i.e. stage I (T1N0M0), and stage II (T2N0M0) according to American Joint Committee on Cancer TNM Staging System [12]. Exclusion criteria included non PTC, lymph node involvement detected clinically or by neck ultrasonography (US) either in the central or the lateral neck compartment, T3 & T4 tumors, M1 tumors, micro papillary thyroid carcinoma, & previous thyroid or cervical lymph node surgeries.

2.2. Preoperative Work up

After approval of the research by the ethical committee, all the patients were submitted to thorough clinical examination, radiological investigations in the form of neck US (figure 1) and US guided fine needle aspiration cytology (FNAC) to confirm the papillary nature of the tumor, and laboratory tests in the form of thyroid function tests including T3, T4, thyroid stimulating hormone (TSH) levels. Also, thyroglobulin (Tg) level was initially obtained for all the patients.

2.3. Operative Technique

After confirming that the patient had PTC of stage I or stage II with no clinical or radiological evidence of cervical lymph nodes involvement, an informed consent for total thyroidectomy was taken from all the cases.

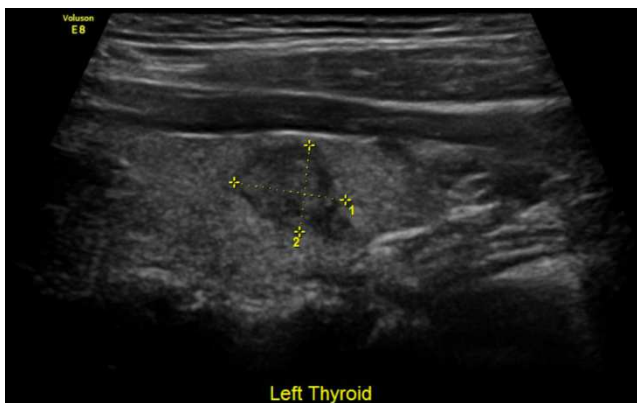

Figure 1. Neck US showing left thyroid lobe with 2x1.5 cm (T1) papillary thyroid carcinoma.

All the patients were submitted to total thyroidectomy only without PCLND (figure 2, 3). If enlarged lymph nodes were found intra-operatively, the surgeon opted to do lymph node sampling. The removed specimen was sent for histopathological examination that included the nature and the size of the primary thyroid tumor, presence of any extra thyroid extension, presence of excised lymph nodes, and any evidence of metastasis in these excised lymph nodes.

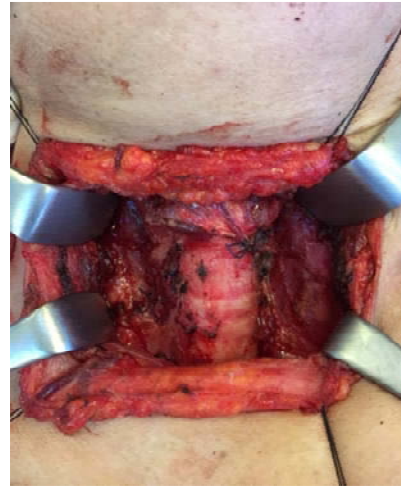


Figure 2. Intra-operative photograph of the neck after total thyroidectomy.

2.4. Post-Operative Follow up

Post-operatively, all the patients were monitored and assessed to exclude hypocalcemia or any evidence of recurrent laryngeal nerve injury. All of them received TSH suppression therapy to maintain TSH level less than 0.5 micro-unit/ml. RAI ablation was given to all the patients under thyroid hormone therapy withdrawal.

Follow up of the patients was carried out in the outpatient clinic 2 weeks post-operatively. Then, they were clinically examined every 3 months. Neck US, serum T3, T4, TSH, & Tg levels were done every 6 months. Any suspicious local neck recurrence was confirmed cytologically by US guided FNAC, while any distant metastasis was assessed by RAI uptake scanning and CT scan.

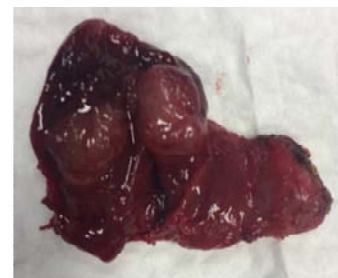

Figure 3. Right thyroid lobe with 3.5 cm (T2) papillary thyroid carcinoma.

3. Results

The study included 34 patients with early-stage PTC treated by total thyroidectomy without PCLND. The age of the patients ranged between 23 & 58 years with mean age of

42.1 years. Nineteen patients were less than 45 years (55.9%) and 15 patients were 45 years old or more (44.1%). Twenty four patients (70.6%) were females (table 1) and 10 patients (29.4%) were males. T1 was encountered in 14 patients (41.2%) while 20 patients presented with T2 tumors (58.8%). None of the patients had any clinical or radiological evidence of cervical lymph nodes involvement (N0) neither in the central nor in the lateral neck compartment. Total thyroidectomy was successfully done for all the cases. In 5 patients (14.7%), central cervical lymph nodes sampling was done as enlarged cervical lymph nodes were found intra-operatively (table 2).

Table 1. Criteria of the Patients.

Criteria	No. (%)
Sex:	
Male	10 (29.4)
Female	24 (70.6)
Age:	
Less than 45 years	19 (55.9)
45 years or more	15 (44.1)
T stage:	
T1	14 (41.2)
T2	20 (58.8)

Pathological examination of the removed specimens confirmed the papillary nature of the tumor in all the cases. Excised lymph nodes were found in 8 specimens (23.5%); 5 cases with lymph node sampling (14.7%), and 3 cases (8.8%) with accidental lymph node excision during thyroidectomy (table 2). Only 6 out of the 8 cases (17.6%) with excised lymph nodes showed positive lymph node metastasis (pN1). All of these patients were treated by RAI ablation without any further surgical intervention. No recurrent laryngeal nerve injury was reported. In 12 patients (35.3%), temporary hypocalcemia was encountered that improved within 6 weeks after surgery.

Table 2. Excised Lymph Nodes.

Patients	No. (%)
No. of patients with excised lymph nodes	8 (23.5)
No. of patients with positive lymph nodes	6 (17.6)

The follow up period ranged between 81 and 24 months with a mean of 34.6 months. No disease related mortality was reported in the study. There were 2 recurrences detected during the follow up period (5.9%). The recurrence was reported 43 & 30 months respectively after surgery with a mean of 36.5 months. The recurrence was found to be in the central neck compartment in 1 case and in the lateral neck compartment in the other case. Both cases were males with one patient above 45 years old and the other was less than 45 years old (table 3). Both recurrences were treated by RAI ablation. No distant metastasis was detected during the follow up period.

Table 3. Patients with Recurrence.

Patients	No. (%)
Patients with recurrence	2 (5.9)
Male	2 (5.9)

Patients	No. (%)
Female	0 (0)
Less than 45 years	1 (2.95)
45 years or more	1 (2.95)

4. Discussion

Surgical treatment for any PTC more than 1 cm is total thyroidectomy. If central cervical lymph nodes are found to be involved, therapeutic central cervical lymph node dissection (TCLND) should be performed. TCLND includes dissection of level VI i.e. anterior compartment nodes from hyoid bone down to the suprasternal notch and from midline till the common carotid artery bilaterally and level VII that includes lymph nodes inferior to the suprasternal notch in the superior mediastinum [13, 14]. Moreover, if lateral cervical lymph nodes have biopsy proven disease, therapeutic central and lateral lymph node dissection is the ideal option [15, 16]. Lateral cervical node dissection includes level II (upper jugular group), level III (middle jugular group), level IV (lower jugular group), and level V which is the posterior jugular lymph nodes [13].

Lateral cervical lymph node dissection is not usually needed alone without central cervical lymph node dissection in treatment of PTC because skip metastasis to lateral cervical lymph nodes without central nodal involvement is rare [17].

There is no general consensus whether to do unilateral or bilateral central nodal dissection. Some studies demonstrated that ipsilateral central node dissection is enough [18] to decrease the incidence of operative complications. However, others advised ipsilateral central node dissection only in micro-papillary thyroid carcinoma i.e. less than 1 cm and bilateral central node dissection for PTC larger than 1 cm [19] and for PTC with lateral cervical node involvement [20].

The use of elective or prophylactic central lymph node dissection (PCLND) i.e. in clinically node negative patients is controversial. It is claimed that PCLND decreases recurrence rates and improves survival [21, 22]. However, other studies showed that total thyroidectomy with RAI ablation in node negative patients without PCLND is sufficient specially in T1 & T2 tumors as PCLND did not show significant reduction in recurrence rates with significant increase in the incidence of operative complications specially recurrent laryngeal nerve injury and hypocalcemia [23, 24].

This study included 34 patients, 24 females (70.6%), and 10 males (29.4%) with a mean age of 42.1 years. Nineteen patients (55.9%) were less than 45 years and 15 patients (44.1%) were 45 years old or more. These results are consistent with results of other studies. Yuan et al [24] reported in their study on a total number of 190 patients with clinically node negative PTC a male incidence of 32.1% and female incidence of 67.9% with 64.7% of the patients less than 45 years old and 35.3% of patients 45 years old or more. Calo et al [25] reported a mean age of 44.2 years with 21.3% of patients was males and 78.7% were females.

The study included patients with T1 or T2 tumors with N0. Exclusion criteria included any T3, T4, or N1 cases (stage III & IV) because TCLND is needed for N1 tumors and T3 & T4 cases will need cervical lymph node dissection even if they are clinically N0 (PCLND) [15, 16, 26]. Also, patients with micro-papillary thyroid carcinoma were excluded because these patients can be sufficiently treated by hemithyroidectomy [26].

Patients with previous thyroid or cervical lymph node surgery were also excluded because in these patients lymph node assessment is more difficult and they may need further modalities of management.

Non papillary thyroid carcinomas were excluded from the study because it may have different pathological behavior e. g. follicular thyroid carcinoma that shows less tendency to give lymph node metastasis with higher incidence of distant bony metastasis [27] and anaplastic thyroid carcinoma that may need different modalities of treatment e. g. total thyroidectomy with neck dissection, RAI, radiotherapy, &/or chemotherapy [28, 29].

In the current study, all the patients were submitted to preoperative neck US and US guided FNAC to confirm the pathological nature of the disease. US is the primary imaging modality used in patients with thyroid disease. It is very sensitive in detecting positive nodal metastasis as small as 2-3 mm. It doesn't carry the risk of radiation exposure and can be easily repeated for follow up [30, 31].

US guided FNAC is well recommended now by all the guidelines for assessment of the thyroid nodules. If compared to palpation guided FNAC, US guided FNAC significantly reduces the rate of non-sufficient and false negative samples by selective targeting of the thyroid nodule. It helps to reduce the incidence of unnecessary thyroidectomy and it increases the thyroid cancer yield in the specimens of thyroidectomy [32, 33]. However, US guided FNAC is not without limitations. It is operator dependent and it has its own complications e. g. hematoma, tracheal or esophageal injury, and tumor seeding [34, 35].

In 8 cases, there were excised lymph nodes in the thyroidectomy samples (23.5%). Only 6 out them (17.6%) showed positive tumor metastasis. These patients were treated by RAI ablation. Nixon et al [6] reported in their study N1 stage in 14.5% in patients with no central node dissection. On the other hand, Calo et al [25] reported positive lymph node metastasis in only 3.5% of clinically node negative PTC patients. Said et al [36] reported positive lymph node metastasis in 2.6% of clinically node negative PTC.

No recurrent laryngeal nerve injury was encountered in the current study. However, there were 12 patients (35.3%) who developed transient hypocalcemia that improved within few weeks after surgery. Islam et al [37] in their study reported a rate of 32% of hypocalcemia after thyroidectomy. In another study by Sousa et al [38], the incidence of temporary hypocalcemia was 40.8%. The incidence of hypocalcemia after thyroidectomy is widely variable and can reach up to 50% of cases with recovery in 3 to 6 months [39, 40]. Post-thyroidectomy hypocalcemia is a complex phenomenon that

may happens due to many factors even with preservation of the parathyroid glands e. g. surgical trauma to parathyroid glands, and parathyroid devascularization specially that parathyroid glands share the blood supply with thyroid. This blood supply is delicate and easy to be disrupted [37, 41].

After surgery, all the patients were put on TSH suppression therapy and were followed up by clinical examination, neck US, and thyroglobulin level because elevated thyroglobulin level was found to be associated with high incidence of local and distant recurrence in cases of PTC [6, 42].

During follow up period, 2 recurrences (5.9%) were reported; 1 in the central neck compartment and 1 in the lateral compartment. Many studies did not show any statistically significant difference in the rate of loco-regional recurrence in patients who underwent PCLND and those who did not. Calo et al [25] had recurrence rate of 3.9% in patients with no PCLND and 2.1% in those with PCLND. Said et al [36] reported 2.8% rate of recurrence in non PCLND group and 2.9% recurrence rate in PCLND group with no statistically significant difference.

5. Conclusion

In conclusion, total thyroidectomy without PCLND in clinically node-negative patients with early stage PTC seems to be an excellent treatment option as it gives adequate loco-regional control of the disease and low rate of surgical complications including recurrent laryngeal nerve injury & hypocalcemia, and without significant increase in the recurrence rates. However, close regular follow up of these patients is needed. These results will be more valid if the study can be extended to include more patients with longer follow up periods especially with the long survival rates of patients with PTC.

References

- [1] Lundgren CI., Hall P., Dickman PW., & Zedenius J. Clinically significant prognostic factors for differentiated thyroid carcinoma: a population-based, nested case-control study. *Cancer* 2006; 106, 3: 524-531.
- [2] Eichhorn W., Tabler H., Lippold R., et al. Prognostic factors determining long term survival in well differentiated thyroid cancer: an analysis of four hundred eighty-four patients undergoing therapy and aftercare in the same institution. *Thyroid* 2003; 13 (10): 949-958.
- [3] Qubain SW., Nakano S., Baba M., et al. Distribution of lymph node micrometastasis in pN0 well-differentiated thyroid carcinoma. *Surgery* 2002; 131: 249-256.
- [4] Arturi F., Russo D., Giuffrida D., et al. Early diagnosis by genetic analysis of differentiated thyroid cancer metastases in small lymph nodes. *J. Clin. Endocrinol. Metab.* 1997; 82: 1638-1641.
- [5] Adam MA., Pura J., Goffredo P., et al. Presence and number of lymph node metastases are associated with compromised survival for patients younger than age 45 years with papillary thyroid cancer. *J. Clin. Oncol.* 2015; 33 (21): 2370-2375.

- [6] Nixon IJ., Wang LY., Ganly I., et al. Outcomes for patients with papillary thyroid cancer who do not undergo prophylactic central neck dissection. *Br. J. Surg.* 2016; 103 (3): 218-225.
- [7] Hughes DT., White ML., Miller BS., et al. Influence of prophylactic central lymph node dissection on prospective thyroglobulin levels and radioiodine treatment in papillary thyroid cancer. *Surgery* 2010; 148: 1100-1106.
- [8] Popadich A., Levin O., Lee JC., et al. A multicenter cohort study of total thyroidectomy and routine central lymph node dissection for cN0 papillary thyroid cancer. *Surgery* 2011; 150: 1048-1057.
- [9] Hartl DM., Leboulleux S., Al Ghuzlan A., et al. Optimization of staging of the neck with prophylactic central and lateral neck dissection for papillary thyroid carcinoma. *Ann. Surg.* 2012; 255 (4): 777-783.
- [10] Lang BH., Ng SH., Lau LL., et al. A systematic review and meta-analysis of prophylactic central neck dissection and short term loco-regional recurrence in papillary thyroid carcinoma after total thyroidectomy. *Thyroid* 2013; 23: 1087-1098.
- [11] Shen WT., Ogawa L., Ruan D., et al. Central neck lymph node dissection for papillary thyroid cancer: comparison of complication and recurrence rates in 295 initial dissections and reoperations. *Arch. Surg.* 2010; 145 (3): 2720275.
- [12] Wdge SB., Byrd DR., Compton CC., et al. *AJCC Cancer Staging Manual*. 7th edition. New York, NY: Springer-Verlag; 2010.
- [13] The American Thyroid Association Surgery Working Group, American Association of Endocrine Surgeons, American Academy of Otolaryngology—Head and Neck Surgery, et al. Consensus Statement on the Terminology and Classification of Central Neck Dissection for Thyroid Cancer. *Thyroid* 2009; 19 (11): 1153-1158.
- [14] Grodski S., Cornford L., Sywak M., et al. Routine level VI lymph node dissection for papillary thyroid cancer: surgical technique. *ANZ J. Surg.* 2007; 77 (4): 203-208.
- [15] Brown AP., Chen J., Hitchcock YJ., Szabo A., et al. The risk of second primary malignancies up to three decades after the treatment of differentiated thyroid cancer. *J. Clin. Endocrinol. Metab.* 2008; 93 (2): 504-515.
- [16] Cooper DS., Doherty GM., Haugen BR., et al. Revised American association management guidelines for patients with thyroid nodule and differentiated thyroid cancer. *Thyroid* 2009; 19 (11): 1167-1214.
- [17] Machens A., Hinze R., Thomusch O., et al. Pattern of nodal metastasis for primary and reoperative thyroid cancer. *World J. Surg.* 2002; 26 (1): 22-28.
- [18] Sywak M., Cornford L., Roach P., et al. Routine ipsilateral level VI lymphadenectomy reduces postoperative thyroglobulin levels in papillary thyroid cancer. *Surgery* 2006; 140 (6): 1000-1005, discussion 1005-1007.
- [19] Moo TA., Umunna B., Kato M., et al. Ipsilateral versus bilateral central neck lymph node dissection in papillary thyroid carcinoma. *Ann. Surg.* 2009; 250 (3): 403-408.
- [20] Roh JL., Park JY., Rha KS., et al. Is central neck dissection necessary for the treatment of lateral cervical node recurrence in papillary thyroid carcinoma? *Head Neck* 2007; 29 (10): 901-906.
- [21] Shah MD., Hall FT., Eski SJ., et al. Clinical course of thyroid carcinoma after neck dissection. *Laryngoscope* 2003; 113 (12): 2102-2107.
- [22] Wang TS., Dubner S., Szynter LA., & Heller KS. Incidence of metastatic well-differentiated thyroid cancer in cervical lymph nodes. *Archives of Otolaryngology-Head and Neck Surgery* 2004; 130 (1): 110-113.
- [23] Wang TS., Evans DB., Fareau GC., et al. effect of prophylactic central compartment neck dissection on serum thyroglobulin and recommendations for adjuvant radioactive iodine in patients with differentiated thyroid cancer. *Ann. Of Surg. Oncol.* 2012; 19 (13): 4217-4222.
- [24] Yuan J., Zhao G., Du J., Chen X., et al. To identify predictors of central lymph node.
- [25] Metastasis in patients with clinically node-negative conventional papillary thyroid carcinoma. *Int. J. Endocrinol.* 2016; article ID 6109218, 1-6.
- [26] Calo PG., Lombardi CP., Podda F., et al. Role of prophylactic central neck dissection in clinically node-negative differentiated thyroid cancer: assessment of the risk of regional recurrence. *Updates Surg.* 2017; 69: 241-248.
- [27] Ito Y., Hirokawa M., Uruno T., Kihara M., et al. prevalence and biological behavior of variants of papillary thyroid carcinoma: experience at a single institute. *Pathology* 2008; 40 (6): 617-622.
- [28] Haigh PI. Follicular thyroid carcinoma. *Curr. Treat. Options Oncol.* 2002; 3 (4): 349-354.
- [29] Garcia-Rostan G. & Sobrinho-Simoes M. Poorly differentiated thyroid carcinoma: an evolving entity. *Diagn. Histopathol.* 2011; 17: 114-123.
- [30] Ibrahimpasic T., Ghossein A., Carlson DL., et al. Outcomes in patients with poorly differentiated thyroid carcinoma. *J. Clin. Endocrinol. Metab.* 2014; 99: 1245-1252.
- [31] Stulak JM., Grant CS., Farley DR., et al. Value of preoperative ultrasonography in the surgical management of initial; and reoperative papillary thyroid cancer. *Arch. Surg.* 2006; 141 (5): 489-494, discussion 954-955.
- [32] Kouvaraki MA., Shapiro SE., Fornage BD., et al. Role of preoperative ultrasonography in the surgical management of patients with thyroid cancer. *Surgery* 2003; 134 (6): 946-954, discussion 954-955.
- [33] Danese D., Sciacchitano S., Farsetti A., et al. Diagnostic accuracy of conventional versus sonography-guided fine needle aspiration biopsy of thyroid nodules. *Thyroid* 1998; 8: 15-21.
- [34] Cesur M., Corapcioglu D., Bulut S., et al. Comparison of palpation guided fine needle aspiration biopsy to ultrasound guided fine needle aspiration biopsy in the evaluation of thyroid nodules. *Thyroid* 2006; 16: 555-561.
- [35] Degirmenci B., Haktanir A., Albayrak. et al. Sonographically guided fine needle biopsy of thyroid nodules: the effects of nodule characteristics, sampling technique, and needle size on the adequacy of cytological material. *Clin. Radiol.* 2007; 62: 798-703.
- [36] Hegedus L. Clinical practice. The thyroid nodule. *N. Engl. J. Med.* 2004; 351 (17): 1764-1771.

- [37] Said M., Fujimoto M., Franken C., et al. Preferential use of total thyroidectomy without prophylactic central lymph node dissection of early-stage papillary thyroid cancer: oncologic outcomes in an integrated health plan. *Prem. J.* 2016; 20 (4): 22-26.
- [38] Islam S., Al-Maqbali T., Howe D. & Campbell J. Hypocalcemia following total thyroidectomy: early post-operative parathyroid hormone assay as a risk stratification and management tool. *J. Laryngology & Otology* 2014; 128: 274-278.
- [39] Sousa Ade A., Salles JM., Soares JM. et al. Predictor factors for post-thyroidectomy hypocalcemia. *Rev. Col. Bras. Cir.* 2012; 39 (6): 476-482.
- [40] Karamanakos SN., Markou KB., panagopoulos K., et al. Complications and risk factors related to the extent of surgery in thyroidectomy. Results from 2043 procedures. *Hormones* 2010; 9: 318-325.
- [41] Rosato L., Avenia N., Bernante P., et al. Complications of thyroid surgery: analysis of a multicentric study on 14934 patients operated on in Italy over 5 years. *World J. Surg.* 2004; 28: 271-276
- [42] Lombardi CP., Raffaelli M., Princi P., et al. Parathyroid hormone levels 4 hours after surgery do not accurately predict post-thyroidectomy hypocalcemia. *Surgery* 2006; 140: 1016-1025.
- [43] Coelho SM., Buescu A., Corbo R., et al. Recurrence of papillary thyroid cancer suspected by high anti-thyroglobulin antibody levels and detection of peripheral blood thyroglobulin mRNA. *Arq. Bras. Endocrinol. Metabol.* 2008; 52 (8): 1321-1325.