

Techniques for the Treatment of Maxillary Hypoplasia in Cleft Patients: An Overview

Midhuna Prathap¹, Varun Menon P.²

¹Department of ENT, ENT Resident, Kerala University, Sree Gokulam Medical College and Research Foundation, Trivandrum, India

²Department of Oral and Maxillofacial Surgery, Oral and Maxillofacial Resident, Kerala University, PMS College of Dental Science, Trivandrum, India

Email address:

midhunapratha@gmail.com (M. Prathap), varunmp@gmail.com (Varun M. P.)

To cite this article:

Midhuna Prathap, Varun Menon P. Techniques for the Treatment of Maxillary Hypoplasia in Cleft Patients: An Overview. *Science Journal of Clinical Medicine*. Special Issue: Clinical Conspectus on Cleft Deformities. Vol. 5, No. 4-1, 2016, pp. 59-63.

doi: 10.11648/j.sjcm.s.2016050401.20

Received: February 5, 2016; **Accepted:** April 15, 2016; **Published:** June 16, 2016

Abstract: *Purpose of review* Maxillary hypoplasia is often unavoidable sequelae in cleft lip and palate patients who had undergone timely surgical and orthodontic intervention. Since 1970s these deformities have been traditionally corrected by means of orthognathic surgery. Numerous published studies have tried different techniques to combat the same. The advantages and disadvantages of the various techniques are overviewed. *Recent Findings* Distraction osteogenesis is one of the recent major developments in the field of oral and maxillofacial surgery and provides promising outcome. Tooth borne device hyrax proved good skeletal stability of distracted anterior maxillary segment. Distraction forces when directly transferred to the bone resulted in significant dentoalveolar compensation. This modern technique has also been used to evaluate its immediate and long term impact on nasal index as well which showed significant increase. This technique overcomes significant disadvantages of relapse and velopharyngeal insufficiency and also helps to produce better normal facial esthetics and profiles and masticatory function. *Summary* The oral and maxillofacial surgeons have widely accepted the use of maxillary distraction osteogenesis as an attractive alternative to treat malocclusion in CLP patients and this has broadened the reconstructive spectrum. Recent advancements have led to a wider clinical application and improved acceptance.

Keywords: Distraction Osteogenesis, Maxillary Hypoplasia, Rigid External Device, Le Fort 1 Osteotomy

1. Introduction

Maxillary hypoplasia has been recognized as a common developmental problem in cleft lip and palate (CLP) patients due to congenital reduction in midfacial growth. It is also seen as an effect of the surgical scar from cleft palate repair[1]. CLP patients usually present with symptoms varying from malocclusion, retrusion of midface, and a narrow hard palate. A detailed evaluation and individualized treatment planning is of utmost importance in dealing with these patients. Treatment involves the contribution from both the orthodontist and the craniofacial team. The principle of gradual lengthening has been applied to patients affected by different types of skeletal craniofacial deficiency. Sometimes it may be necessary to assess patient's extent of hypoplasia in several steps through clinical and radiological investigation. For best outcomes a multidisciplinary

treatment planning and sequentially staged treatment is essential. Numerous published studies have tried different techniques to combat the same. In most situations, surgical correction following cessation of growth is required to treat severe skeletal disharmony.

In the following section, we have tried to highlight the various methods which have been used as treatment modality to treat maxillary hypoplasia over the years.

2. Discussion

In 1992 McCarthy introduced Distraction osteogenesis (DO) of the craniofacial skeleton.[2].The conventional orthognathic surgery which has been in practice since over several decades is the Go to:

Treatment of maxillary hypoplasia has traditionally involved conventional Le Fort I osteotomies and advancement. Advancements of greater than 10 mm risk significant relapse. This risk is greater in the cleft lip and palate population, whose anatomy and soft tissue scarring from prior procedures contributes to instability of conventional maxillary advancement. Le Fort I advancement with distraction osteogenesis has emerged as viable, stable treatment modality correction of severe maxillary hypoplasia in cleft, syndromic, and noncleft patients. In this article, the authors provide a review of current data and recommendations concerning Le Fort I advancement with distraction osteogenesis. In addition, they outline their technique for treating severe maxillary hypoplasia with distraction osteogenesis using internal devices.

Keywords: Le Fort I distraction osteogenesis, cleft lip/palate, Le Fort I osteotomy, maxillary hypoplasia, midface advancement

Le Fort I advancement and has been a reliable procedure for correction of maxillary retrusion. Since then several internal and external distraction devices have been developed for maxillary advancement.

2.1. Demerits of Le Fort I Distraction Osteogenesis

1. The degree of relapse after conventional Le Fort I advancement in cleft patients is variable from 22 to 40% in the horizontal plane, and 19 to 70% in the vertical plane
2. Advancement achieved in cleft patients is a maximum of only around 6 mm.
3. Greater movement risks instability and eventual relapse.
4. Soft tissue scarring, potentially poor bone quality, and aberrant dentition make maxillary advancement in the cleft lip and palate patient population a particular challenge.
5. Le Fort I osteotomies is generally confined to patients approaching skeletal maturity. [3]

2.2. Advantages of Distraction Osteogenesis

1. Allows for high osteotomies and a lack of rigid fixation techniques, which avoids injury to tooth follicles and allows for advancement in the growing patient.
2. Provides a treatment modality for growing patients with severe maxillary hypoplasia of more than 10 mm advancement requirement in noncleft patients.
3. It is a reproducible and valuable alternative to standard orthognathic surgery procedures
4. Allows for a global improvement in facial aesthetic.
5. Allows a maxillary correction in patients during the period of mixed dentition.
6. Allows either for an unchanged or better velopharyngeal function. Deterioration in velopharyngeal function appeared to be associated with larger advancement.
7. Allows a larger degree of advancement.
8. Soft tissue and hard tissue relapse is less. [4]

2.3. Demerits of Conventional Maxillary Advancement

Cheung et al did a randomized control study of 29 patients and found a statistically significant increase in relapse in the conventional osteotomy (CO) group at 12 weeks[5]. Kumar et al found a 48% greater relapse for cleft lip and palate patients treated for severe maxillary deficiency (>10 mm) by CO compared with DO[6]. In a comparison of cleft patients treated with CO versus DO for advancements ranging from 4 to 10 mm, Chua et al found a significantly increased relapse at 5 years in the CO group[7].

2.4. Long Term Outcomes of Le Fort I Distraction Osteogenesis

A horizontal relapse of 5.5% to 23% have been observed by authors in follow-up period during ranging from 2 to 6 years. Two major observational trials have found a decrease in the ANB angle (A point-nasion-B point angle) over time which could be overcome by overcorrection in growing patients.

Terbish et al advocated a premaxillary distraction osteogenesis and arch expansion as an effective treatment strategy for improving function, aesthetics, and stability for cleft patients with multiple missing teeth[8]. He performed Le Fort I osteotomy followed by vertical osteotomy located distally of the upper right canine and left first premolar to separate the anterior segment of the maxilla. After a 3-month consolidation period, orthodontic treatment and bilateral intraoral vertical ramus osteotomy were performed for the mandibular setback. The implant and prosthodontic treatments were applied to the alveolar ridge area created by the distraction osteogenesis. The quality of the alveolar bone created by distraction osteogenesis was acceptable for the prosthodontic implant and achieved good aesthetic results.

Gao QW et al [9] explored the clinical application of mandibular-driven simultaneous maxillo-mandibular distraction to correct hemifacial microsomia with rapid prototyping technology.

The patient's skull resin model was manufactured with rapid prototyping technology. According to the preoperative design, the patients underwent Le Fort I osteotomy and mandibular ramus osteotomy. The internal mandible distractor was embedded onto the osteotomy position and occlusal titanium pin was implanted. The longest distance of distraction achieved was 28 mm, and the shortest distance was 16 mm. The facial asymmetry deformity was significantly improved at the end of distraction. The occlusal plane of patients obviously improved.

Rattan V et al [10] studied twelve adult subjects in the age range of 17-21 years with complete unilateral cleft lip and palate who underwent advancement of the maxilla by DO. The effect of maxillary DO on the infraorbital rim remodeling was evaluated from lateral cephalograms recorded prior to the DO (T0), at the end of DO (T1), and at least 2-years after the DO (T2) by Walker's analysis. The Walker's analysis showed 1.49 ± 1.22 mm and 2.31 ± 1.81 mm anterior movement of the infraorbital margin (Orbitale

point) at the end of T1 and T2, respectively ($P < 0.01$). This apposition of bone at the infraorbital rim region further improved the facial profile of these patients.

Mitsukawa N et al [11] proposed mandibular distraction osteogenesis as against the conventional treatment of mandibular advancement by sagittal split ramus osteotomy (SSRO) for patients with severe mandibular micrognathia with marked mandibular retrognathism or hypoplasia in maxillary prognathism. Here intermaxillary fixation in centric occlusion was performed after osteotomy, and proximal bone segments were distracted in a posterosuperior direction. This procedure is a superior surgical technique that avoids the drawbacks of SSRO and conventional mandibular distraction. However, it applies a large load to the temporomandibular joints and requires thorough management. Thus, careful evaluation needs to be made of the indication for backward distraction osteogenesis.

Mitsukawa N et al [12] did another study where he performed maxillary Le Fort I osteotomy and subsequent distraction separately for each bone segment using a halo device in patients with bilateral cleft lips and palates who have premaxillary protrusion and characteristic jaw deformities involving three-dimensional malposition of the premaxilla and bilateral maxillary bone segments. This report described this novel treatment method which produced good results and achieved distraction close to the desired amount. The widths of the alveolar clefts were narrowed, and satisfactory occlusion and maxillary arch form were achieved after the surgery. In addition, subsequent bone grafting for alveolar cleft defects was beneficial, dental prostheses were unnecessary, and frequency of surgery and surgical invasiveness were reduced. This method is a good surgical procedure that should be considered for patients with bilateral cleft lips and palates who have premaxillary protrusion and hypoplasia of the right and left lateral segments.

Multiple internal and external devices have been developed and utilized for maxillary DO.

2.5. Advantages of External Distraction Systems:

When distracting using an external device, the vector can be adjusted any time during distraction.

The device can be removed without the need for sedation or general anesthetic.

Distracting using an external device potentially allows for a higher Le Fort I osteotomy, as there is no need to consider a zygomatic area for the footplate of an internal distractor [13,14].

2.6. Advantages of Le Fort I Advancement Using Internal Devices

External devices can be intimidating and cumbersome to patients and clinicians.

Internal devices are largely buried under soft tissues, and may be better tolerated during the distraction/ consolidation process than external devices.

It has been postulated that the “pushing” forces of internal distraction may impart a stability advantage over external DO.

Yu H Dai et al [15] evaluated the combination of midfacial distraction and orthognathic surgery in the treatment of nasomaxillary hypoplasia. After Le Fort II osteotomy, the rotational distraction of nasomaxillary complex was performed to rehabilitate facial convexity. Then bilateral sagittal split ramus osteotomy with or without Le Fort I osteotomy was used to correct malocclusion. All patients healed uneventfully, and the maxillae moved forward conspicuously. A significant advancement and downward movement of the maxilla were shown by cephalometric analysis. Thus the combination of midfacial distraction and orthognathic surgery provides us an ideal alternative in the treatment of nasomaxillary hypoplasia

Hettinger PC et al [16] reviewed the treatment of midface hypoplasia in nonsyndromic cleft lip-cleft palate patients using rotation advancement of the midface with Le Fort III distraction. Amira imaging software was used to perform surface analysis on the last five consecutive patients in this series. Extending osteotomies to the Le Fort III level allows occlusal correction along with improvements in malar and nasal projection required to achieve facial harmony in this group of patients.

Sakamoto Y et al [17] described the case of an adolescent with Crouzon syndrome showing frontal recession exophthalmos and an anterior crossbite which was treated with monobloc minus Le Fort I and Le Fort I distraction using only internal devices, which the authors have designated Le Fort IV plus I distraction with successful outcome,

Patients with syndromic craniosynostosis have a smaller mandible length and obtuse gonial angle. Correction of midfacial hypoplasia with DO results in inferior and posterior mandibular movement. Clinicians can use this information to counsel patients regarding anticipated changes in facial profile and the need for adjunct procedures [18].

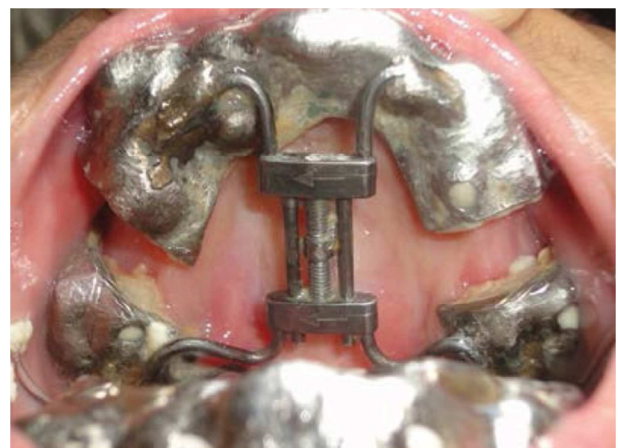


Fig. 1. Distraction appliance in situ.

External and internal distractors like the Dynaform system, modified hyrax appliance (Fig 1) and the hybrid distractors have been described in relation to an anterior maxillary

distraction

Dobbs TD et al [19] proposed the combined use of distraction osteogenesis with an external distraction device such as the rigid external distraction (RED) frame and has become an established method for treating midface hypoplasia. It allows for greater advancement of the midface than achievable with traditional Le Fort III osteotomies. Drawbacks associated with this include frame application such as pin site migration and need for frame removal. The RED frame was used to achieve table soft tissue distraction, greater than previously achievable with traditional Le Fort III osteotomy

Dua G et al [20] evaluated postoperative stability in maxillary distraction osteogenesis in patients of cleft lip and cleft palate using a rigid external device (RED). After distraction, evaluation was done for ease of the procedure, stability, and complications. Lateral cephalograms were evaluated at 3 stages: T1, pre-distraction; T2, post-distraction; and T3, 1 year post-distraction. Maxillary position improved in relation to the cranial base. This study showed that the RED was versatile in midface advancement

Tong H et al [21] evaluated the effects of transsutural distraction osteogenesis applied to the maxillary complex with a new internalized distraction device and to analyze the long-term osteogenesis outcome. The feasibility was evaluated, and the effects of the maxillary growth were measured using radiography and computed tomography (CT). The regenerated bone was examined with micro-CT and biomechanical testing. One year after the distraction, the micro-CT showed more incompact structure and bone volume/total volume to be significantly less. Biomechanical testing also showed a significantly lower yield.

It is expected that this device may provide new thoughts in developing an appropriate appliance for clinical use in young patients with midfacial hypoplasia. Moreover, the long-term osteogenesis analysis findings suggest that the metabolism of sutural area still remained active, which enhanced our understanding of bone remodeling in the sutural area to manage maxillary relapse after transsutural distraction osteogenesis

Margaride LA et al [22] experimented a new model of distraction osteogenesis that is transmaxillary osteogenic distraction, using tooth-borne devices. It is a simple method and allows ambulatory retraction of distractors. Osteogenesis between molars and premolars at the alveolar level was found to be stable and allowed orthodontic mobilization and dental implants. Anchorage in molars and maxillary tuberosities avoided velopharyngeal incompetence. Results were satisfactory and stable, surgery is simple, and custom-made intraoral devices are easy to handle with minimal discomfort for the patients.

Olmez S et al [23] compared the pattern and amount of stress and displacement during maxillary sagittal distraction osteogenesis (DO) between a patient with unilateral cleft lip and palate (UCLP) and a noncleft patient. They constructed three-dimensional finite element models for both skulls and displacements of the surface landmarks and stress

distributions in the circummaxillary sutures were analyzed after an anterior displacement of 6 mm was loaded to the elements where the inferior plates of the distractor were assumed to be fixed and were below the Le Fort I osteotomy line. In sagittal plane, more forward movement was found on the noncleft side in the UCLP model (-6.401 mm on cleft side and -6.651 mm on noncleft side for the central incisor region). In the vertical plane, a clockwise rotation occurred in the UCLP model, whereas a counterclockwise rotation was seen in the control model. The mathematical UCLP model also showed higher stress values on the sutura nasomaxillaris, frontonasalis, and zygomaticomaxillaris on the cleft side than on the normal side.

Laure B et al [24] achieved orbitofrontal monobloc advancement which is frontofacial monobloc advancement minus maxillary dental arch in patients suffering from Crouzon syndrome with synostosis of coronal sutures, exophthalmia, hypertelorism, and hypoplasia of the middle third of face. Frontofacial monobloc advancement, which is the gold standard, increases the maxillo-mandibular dysmorphia. After 20 days of distraction, the final advancement was 10.2 mm for cranial distractors and 10.5 mm at fronto-zygomatic and was thus found to be an useful tool for treatment of such cases.

Konaş E et al [25] offered a new solution to have an adequate oral opening and to prevent reankylosis in congenital maxillomandibular syngnathia after the release of bony syngnathia, they placed a distractor between mandibular segment and maxillozygomatic complex and this proved to be a major improvement in the patient's status. Distraction may thus broaden our horizons in this rare and difficult-to-treat deformity.

Harada et al [26] examined the change in blood flow and recovery of sensibility in the maxillary dental pulp during and after maxillary distraction.. Pulpal blood flow (PBF) was measured by laser Doppler flowmetry, and pulpal sensibility (PS) was investigated by electrodiagnostics. A higher proportion of patients who underwent distraction osteogenesis was positive for pulpal sensitivity.

3. Conclusion

Distraction osteogenesis is a good treatment option for patients with facial asymmetry and mandibular hypoplasia. New bone is formed between bone segment surfaces that are gradually separated by incremental traction. Postoperative orthodontic treatment can achieve tooth alignment and closure of the posterior open bite. These therapeutic treatments improved the patient's facial appearance. Distraction osteogenesis consists of slow regeneration of the bone following corticotomy or osteotomy after vector planning. In CLP patients, the relapse after orthognathic surgery is greater due to tense scar tissue from multiple previous surgeries. Larger advancements with better stability can be achieved with the help of distraction. Anterior segmental distraction osteogenesis of the hypoplastic cleft maxilla besides

improving facial balance and aesthetics helps to achieve stable occlusion while correcting dental-crowding without any detrimental effect on speech. The additional use of rigid external devices helped in midface improvement.

References

- [1] Chacko T, Vinod S, Mani V, George, Sivaprasad KK. Management of Cleft Maxillary Hypoplasia with Anterior Maxillary Distraction: Our Experience. *J Maxillofac Oral Surg.* 2014 Dec; 13(4): 550-5.
- [2] Scolozzi P. Distraction osteogenesis in the management of severe maxillary hypoplasia in cleft lip and palate patients. *J Craniofac Surg.* 2008; 19(5): 1199–1214.
- [3] Patrick D. Combs, MD and Raymond J. Harshbarger, III. Advancement Using Distraction Osteogenesis Le Fort I Maxillary Semin *Plast Surg.* 2014 Nov; 28(4): 193–198.
- [4] Rachmiel A. Treatment of maxillary cleft palate: distraction osteogenesis versus orthognathic surgery—part one: maxillary distraction. *J Oral Maxillofac Surg.* 2007; 65(4): 753–757
- [5] Cheung L K, Chua H D. A meta-analysis of cleft maxillary osteotomy and distraction osteogenesis. *Int J Oral Maxillofac Surg.* 2006; 35(1): 14–24.
- [6] Kumar A, Gabbay J S, Nikjoo R. et al. Improved outcomes in cleft patients with severe maxillary deficiency after Le Fort I internal distraction. *Plast Reconstr Surg.* 2006; 117(5): 1499–1509.
- [7] Chua H D, Hägg M B, Cheung L K. Cleft maxillary distraction versus orthognathic surgery—which one is more stable in 5 years? *Oral Surg Oral Med Oral Pathol Oral Radiol Endod.* 2010; 109(6): 803–814.
- [8] Terbish M, Choi HY, Park YC, Yi CK, Cha JY. Premaxillary Distraction Osteogenesis Using an Intraoral Appliance for Unilateral Cleft Lip and Palate: Case Report. *Cleft Palate Craniofac J.* 2015 Jul; 52(4): e95-e102.
- [9] Gao QW, Song HF, Xu MH, Liu CM, Chai JK.. [Mandibular-driven simultaneous maxillo-mandibular distraction for hemifacial microsomia with rapid prototyping technology] *Int J Oral Maxillofac Surg.* 2009; 35(1): 14–24.
- [10] Rattan V¹, Jena AK, Singh SP, Utreja AK. Maxillary distraction osteogenesis at Le Fort-I level induces bone apposition at infraorbital rim. *Clin Oral Investig.* 2014 Sep; 18(7): 1741-8.
- [11] Mitsukawa N, Morishita T, Saiga A, Akita S, Kubota Y, Satoh K Backward distraction osteogenesis in a patient with severe mandibular micrognathia. *J Craniofac Surg.* 2013 Sep; 24(5): 1653-6.
- [12] Mitsukawa N, Saiga A, Morishita T, Satoh K Special distraction osteogenesis before bone grafting for alveolar cleft defects to correct maxillary deformities in patients with bilateral cleft lips and palates: distraction osteogenesis performed separately for each bone segment. *J Craniofac Surg.* 2014 Jul; 42(5): 623-8.
- [13] Figueroa A A, Polley J W. Clinical controversies in oral and maxillofacial surgery: Part two. External versus internal distraction osteogenesis for the management of severe maxillary hypoplasia: external distraction. *J Oral Maxillofac Surg.* 2008; 66(12): 2598–2604.
- [14] Ross R B. Treatment variables affecting facial growth in complete unilateral cleft lip and palate. *Cleft Palate J.* 1987; 24(1): 5–77.
- [15] Yu H¹, Dai J, Wang X, Zhang W, Shen SG. Le Fort II midfacial distraction combined with orthognathic surgery in the treatment of nasomaxillary hypoplasia. *J Craniofac Surg.* 2014 May; 25(3): e241-4.
- [16] Hettinger PC, Hanson PR, Denny AD. Le Fort III distraction using rotation advancement of the midface in patients with cleft lip and palate.. *Plast Reconstr Surg.* 2013 Dec; 132(6): 1532-41.
- [17] Sakamoto Y, Nakajima H, Tamada I, Sakamoto T. Le Fort IV + I distraction osteogenesis using an internal device for syndromic craniosynostosis *J Oral Maxillofac Surg.* 2014 Apr; 72(4): 788-95.
- [18] Sruthi Rao (Janardhan), S. M. Kotrashetti, J. B. Lingaraj, P. X. Pinto, K. M. Keluskar, Siddharth Jain, Piyush Sone,² and Santhosh Rao Anterior Segmental Distraction Osteogenesis in the Hypoplastic Cleft Maxilla *J Craniomaxillofac Surg.* 2012 Jul; 42(5): 423-9.
- [19] Dobbs TD, Watt-Smith SR, Wall SA, Johnson D. A novel use of the rigid external distraction frame: acute on-table distraction with autologous bone grafting *J Craniofac Surg.* 2014 Sep; 25(5): 1843-5.
- [20] Dua G, Navin Kumar A, Roy ID, Roy SK. Maxillary distraction osteogenesis in cleft lip and palate cases with midface hypoplasia using rigid external distractor: an alternative technique. *J Craniofac Surg.* 2014 May; 25(3): 746-51.
- [21] Tong H, Gao F, Yin J, Zhang X, Zhang C, Yin N, Zhao Z. Transsutural distraction osteogenesis applied to maxillary complex with new internalized distraction device: analysis of the feasibility and long-term osteogenesis outcome. *J Craniofac Surg.* 2015 Mar; 26(2): 402-7
- [22] Margaride LA, Breuer J. Transmaxillary osteogenic distraction with intraoral tooth-borne distractors.. *J Craniofac Surg.* 2012 Sep; 23(5): 1425-7.
- [23] Olmez S, Dogan S, Pekedis M, Yildiz H. Biomechanical evaluation of sagittal maxillary internal distraction osteogenesis in unilateral cleft lip and palate patient and noncleft patients: a three-dimensional finite element analysis. *Angle Orthod.* 2014 Sep; 84(5): 815-24.
- [24] Laure B, Moret A, Joly A, Travers N, Listrat A, Krastinova D, Goga D. Orbitofrontal monobloc advancement for Crouzon syndrome. *J Craniofac Surg.* 2014 Sep; 42(6): e335-8.
- [25] Konaş E, Aliyev A, Tunçbilek G. Congenital maxillomandibular syngnathia: a new management technique using distraction techniques *J Craniofac Surg.* 2015 Jan; 26(1): e68-70.
- [26] Harada K, Sato M, Omura K. Blood-flow change and recovery of sensibility in the maxillary dental pulp during and after maxillary distraction: a pilot study. *Oral Surg Oral Med Oral Pathol Oral Radiol Endod.*