

Protective Potentials of Brown Chicken Eggshell against Potassium Bromate Effect on Testicular Functional Indices in Wistar Rats

Charles Obiora Nwonuma^{*}, Emenike Onyebum Irokanulo, Owa Olugbenga Stephen, Ucheabba Destinee Esther

Biochemistry Unit, Department of Biological Sciences, College of Science and Engineering, Landmark University, Omuaran Kwara State, Nigeria

Email address:

charlesdetermination@gmail.com (C. O. Nwonuma), eoirokanulo@yahoo.co.uk (E. O. Irokanulo), nonsoabba@gmail.com (U. D. Esther), owa.stephen@lmu.edu.ng (O. O. Stephen)

To cite this article:

Charles Obiora Nwonuma, Emenike Onyebum Irokanulo, Owa Olugbenga Stephen, Ucheabba Destinee Esther. Protective Potentials of Brown Chicken Eggshell against Potassium Bromate Effect on Testicular Functional Indices in Wistar Rats. *American Journal of BioScience*. Vol. 3, No. 5, 2015, pp. 183-189. doi: 10.11648/j.ajbio.20150305.14

Abstract: Potassium bromate, a common ingredient in bakery industry, serves as leaven in flour dough. However previous studies have demonstrated that potassium bromate is toxic. This study evaluated the effect of eggshell powder solution (ESPS) on the testicular indices in Wistar rats administered with potassium bromate. Twenty Wistar rats weighing between 200-250 g were randomly grouped into 5: A, B, C, D and E; with 4 rats per group. Group A served as the positive control and was administered with 1ml of 10 mg/kg body weight of potassium bromate solution Group B served as the negative control which was administered with 1ml of distilled water. Groups C, D and E were administered with 1ml each of 200, 300 and 400 mg/kg body weight of *ESPS* respectively reconstituted in distilled water in addition to 1ml of 10 mg/kg body weight of potassium bromate. The treatment was carried out successively for 28 days before the animals were sacrificed 24 hours after the last day of treatment and their testes, harvested. Biochemical tests to evaluate the testicular function using UV/VIS spectrometer and histological tests on the testicular homogenate and tissues respectively were carried out. The result showed significant decrease ($P<0.05$) in the total protein, the superoxide dismutase activity (SOD) and malondialdehyde (MDA). Contrary, there was a significant increase ($P<0.05$) in the Reduced glutathione (GSH) and testicular glycogen of the test rats. The histopathology result showed normal germ cells at lower doses of the *ESPS*. This experiment showed marked reduction in the lipid peroxidation in rats' testes given *ESPS* at a lower dose.

Keywords: Testes, Brown Eggshell, Potassium Bromate, Histopathology

1. Introduction

Potassium bromate is an inorganic salt that has been utilized extensively in bakery industry where it is used to leaven and strengthen dough. It has remained a choice ingredient in bread making all over the world because it is cheap, easily accessible and perhaps the best and most effective oxidizing agent, this salt should have no residue of it left in bread baked under optimum conditions such as using the right quantity, baking long enough and use of appropriate high temperature during the baking process, otherwise it become harmful when consumed in the bread. It is used as a fish paste chemical addition in Japan and has been curtailed, following the

discovery that non-heat-treated potassium bromate has carcinogenic properties, in rats, mice and hamsters [1]. In Nigeria and some other countries, the use of potassium bromate has been banned due to its carcinogenic properties. However, some bakers in Nigeria and elsewhere still resort to its use in raising dough illegally [2]. Bromate is a powerful oxidizing agent, and can oxidize chloride to chlorine under strong acid condition. It reacts with a vast number of reducing agents such as glutathione and other thiols, ferrous ion, hydrogen sulphide, bromide, nitrite, and iodide found in vivo [3]. It is also one of a sum of chemicals that can participate in oscillation reactions; its intermediates can be renewed until the available reducing agents transform it entirely to bromide or other non-oxidizing species. Some of the reactive

bromine-oxygen species have been implicated as the main cause of DNA damage in the body when they are produced in proximity of DNA within the cell [4]. It has been shown by previous studies that potassium bromate to be nephrotoxic in both man and experimental animals [5].

The organic matter of eggshell and shell membrane contain proteins as major constituents with small amounts of carbohydrates and lipids [6]. The major component of eggshell is calcium carbonate; it is approximately 94% of dry weight of the eggshell. Chicken eggshells, which first serve to protect and provide nutrients to the enclosed embryo [7], have been used by humans for a long period as a food additive, but on a very modest scale. Chicken eggshell powder (ESP) have a large store of calcium [8] and have been shown to have antirachitic effects in rats [9]. In vitro, ESP stimulated the growth of chicken embryo cartilage cells [10]. Demembranized chicken ESP was shown to decrease pain and increase bone mineral density (BMD) in the management of osteoporosis [11]. The hormone-like activity present in ESP, has been suggested to be responsible for the effects on BMD and pain [12, 13] Transforming growth factor- β 1 (TGF- β 1) is thought to play a role in regulating BMD [14]. The organic matter of eggshell contains two glycosaminoglycans including hyaluronic acid and chondroitin sulfate-dermatan sulfate copolymer. Sialic acid is another carbohydrate found in eggshell membranes [15 16].

In view of highly reported health hazard that potassium bromate poses in food, it has become necessary to explore ways of ameliorating or eliminating of the potential risk when used as additive or enhancer in bread baking. This study will therefore investigate the extent to which ESPS can protect the rats' testes from lipid peroxidation induced by potassium bromate when used in food.

1.1. Collection and Preparation of ESPS Solution

Eggs from brown egg chickens were collected and their contents removed for the shells. The shells were thoroughly washed in non-chlorinated water to remove residual albumin. They were then allowed to dry protected from dust particles in a ventilated room at ambient temperature of between 28°C and 30°C. At constant weight they were milled into fine powder using a Warren blender. The powder was sieved using a clean and sterile mesh to remove large coarse particles. The resultant fine powder was dissolved in clean sterile distilled water to form a solution which was administered to the rats.

1.2. Animal Selection and Care

Twenty male Wistar rats weighing between 200 and 250 g were procured from the Experimental Animal Unit of the Department of Biological Sciences, Landmark University, Omu aran Nigeria. They were acclimatized under laboratory conditions prior to the commencement of experiment. The animals were housed in wire-meshed cages and allowed access to commercial rat diet and water *ad libitum*. The animals were kept at standard conditions of temperature and humidity with 12 h light/dark cycles. They were fed with commercial rat diet. Handling of the experimental animals also conforms to international guidelines on the care and use of laboratory animals (National Research Council) [17].

1.3. Animal Grouping

The thirty animals used in this experiment were randomly grouped into A, B, C, D and E. Group A, the positive control was administered 1ml of 10 mg/kg body weight of potassium bromate solution orally, B the negative control was fed 1ml of distilled water. Groups C, D and E were administered with 1ml each of 200, 300 and 400 mg/kg body weight of ESPS respectively reconstituted in distilled water, in addition to 1ml of 10 mg/body weight of potassium bromate by oral gavage. The Treatment were carried out successively for 28 days before the animals were sacrificed 24 hours after the last day of treatment and their Testes, harvested.

1.4. Animal Sacrifice and Preparation of Testicular Homogenates

The animals were sacrificed under mild diethyl ether anaesthetization 24 hours after cessation of last treatment. The testes were removed and placed in an isotonic solution of 0.25 M sucrose solution (1:5 w/v). The testes were weighed and homogenized in the ice cold 0.25 M sucrose solution. The homogenates were centrifuged at 5000 \times g for 10 minutes in a refrigerated centrifuge (TDL-5000B Shanghai Anke company, Ltd., China). The supernatant was collected and stored frozen.

1.5. Estimation of Biochemical Indices

The biochemical parameters were investigated in the rats' testicular homogenate using UV/VIS spectrometer; Total protein in testicular homogenate was determined by the method of Gornall *et al.* [18]. The level of reduced glutathione (GSH) in the samples was determined by the method described by Jollow *et al.* (1974) [19]. The superoxide dismutase (SOD) activity was determined by the method described by Misra and Fridovich [20]. Thiobarbituric acid reactive substances (TBARS) was measured as an estimate of malondialdehyde (MDA) which is a product of lipid peroxidation using the method described by Satoh [21]. Glycogen content in the testes was determined by the method described by Kemp *et al.* [22]. The concentration of total cholesterol in the testes was analysed using reagent assay kit according to the method of Fredrickson *et al.* [23]. Both acid phosphatase (ACP) and alkaline phosphatase activities (ALP) were determined by the method described by Wright *et al.* [24, 25].

1.6. Histological Examination

The preparation of tissues for histological examination was done as described by Adeyemi and Akanji (2010b) [26] The representative portions of the testes removed from sacrificed rats were fixed in 10% buffered formalin (pH 7.4) for 12hrs, then embedded in paraffin. The paraffin embedded tissues were cut into 5- μ m sections. The tissue sections were deparaffinised and stained with haematoxylin and eosin. The stained sections were viewed under light microscope and were captured using Sony DSC-W35.

1.7. Data Analysis

Data were analysed using one way ANOVA, followed by Duncan post hoc mean comparison test which was used to assess for significant differences between variables. The analysed data were presented as mean of five replicates \pm standard error of mean (SEM). *P*-values less than 0.05 ($P < 0.05$) were considered statistically significant. All statistical analyses were done using the Statistical Package for Social Science (IBM SPSS Statistics 19).

2. Results

2.1. Proximate Analysis of ESP

The proximate analysis carried out on ESP indicated the presence of Moisture (6.55%), Protein (27.47%), Fat (1.66%), Fiber (3.74%), Starch (4.08%), ash (21.08%), sugar (5.23%), calcium (37.08%), and phosphorus (1.40%)

2.2. Effect of ESPS on Testis – Body Weight Ratio and Testicular Total Protein in Rat

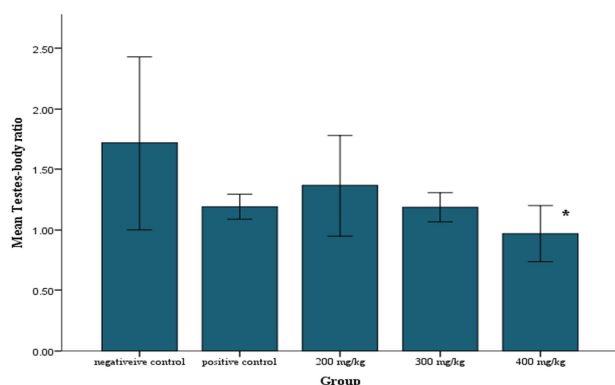


Fig. 1. Effect of Eggshell on the organ-body ratio of rats administered with potassium bromate. Each value is represented as mean of four replicates \pm SEM. *Statistical difference relative to control at $P < 0.05$.

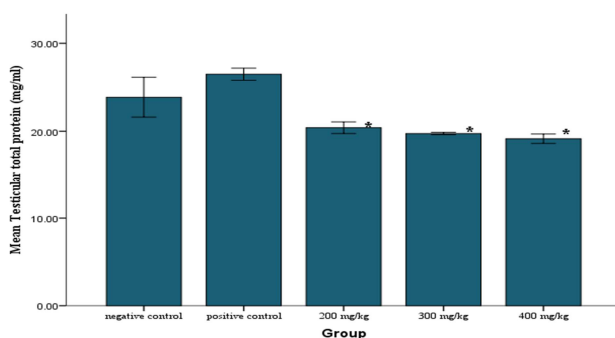


Fig. 2. Effect of Eggshell on the Total protein concentration of rats administered with potassium bromate. Each value is represented as mean of four replicates \pm SEM. *Statistical difference relative to control at $P < 0.05$.

There was an increase in organ-body ratio in the group given 200 mg/kg body weight of ESPS compared to the positive control though not significant (Fig. 1). Contrary, there was a decrease in the total testicular protein concentration in all groups administered with various doses of

ESPS compared to positive and negative control (Fig 2).

2.3. Effect of ESPS on Testicular Cholesterol, Glycogen and MDA Content in Rat

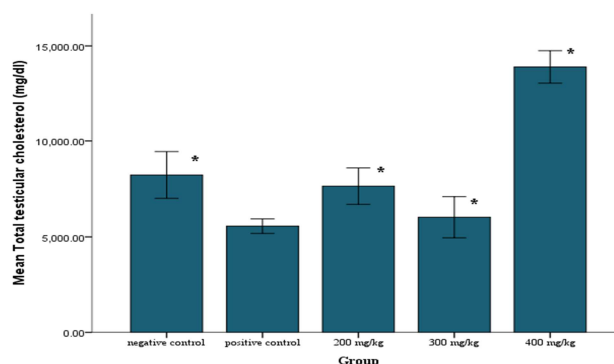


Fig. 3. Effect of Eggshell on the Total cholesterol of rats administered with potassium bromate. Each value is represented as mean of four replicates \pm SEM. *Statistical difference relative to control at $P < 0.05$.

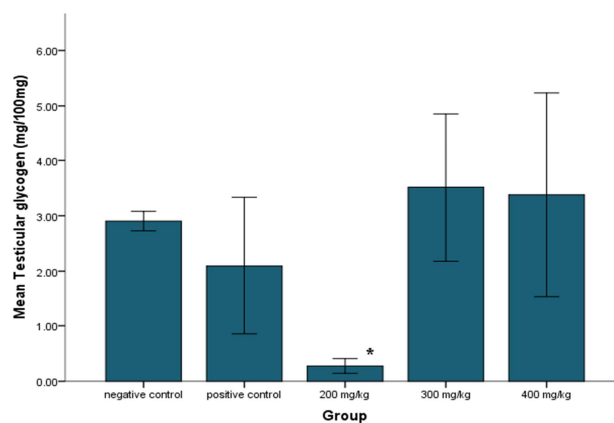


Fig. 4. Effect of Eggshell on the Glycogen of rats administered with potassium bromate. Each value is represented as mean of four replicates \pm SEM. *Statistical difference relative to control at $P < 0.05$.

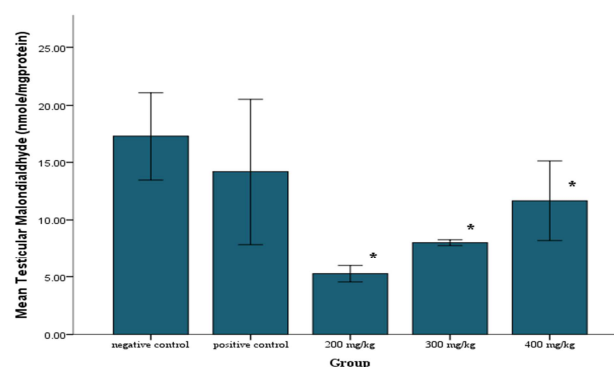


Fig. 5. Effect of Eggshell on the Malondialdehyde of rats administered with potassium bromate. Each value is represented as mean of four replicates \pm SEM. *Statistical difference relative to control at $P < 0.05$.

At 200 mg/kg of ESPS there was a significant increase in testicular cholesterol compared to the positive control but non-significant increase compared to the negative control (Fig. 3). There was a marked decrease ($P < 0.05$) in the testicular glycogen in rats give 200 mg/kg ESPS compared to the

positive and negative controls (Fig.4). The testicular MDA level was significantly reduced ($P < 0.05$) in all the test groups that received ESPS treatment compared to the positive and negative control groups. (Fig.5).

2.4. Effect of ESPS on Testicular SOD and GSH Activities in Rat

A significant increase ($P < 0.05$) was observed in the SOD activity and GSH for the groups administered with 200 mg/kg body weight of ESPS compared to the positive and negative control groups (Fig. 6; 7)

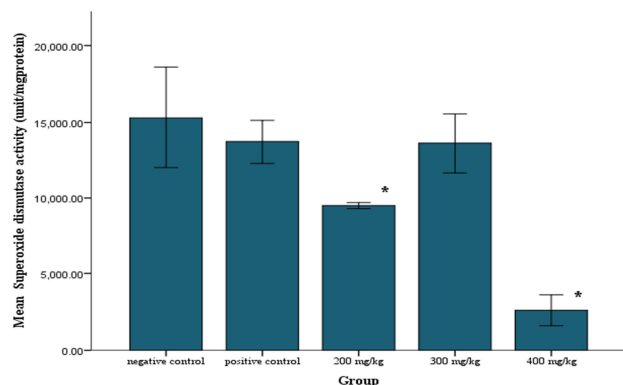


Fig. 6. Effect of Eggshell on the Superoxide dismutase activity of rats administered with potassium bromate. Each value is represented as mean of four replicates \pm SEM. *Statistical difference relative to control at $P < 0.05$.

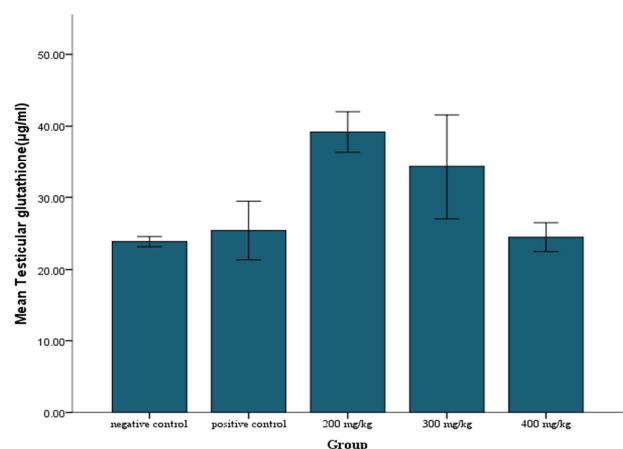


Fig. 7. Effect of Eggshell on the reduced glutathione of rats administered with potassium bromate. Each value is represented as mean of four replicates \pm SEM. *Statistical difference relative to control at $P < 0.05$.

2.5. Effect of ESPS on Testicular ALP and ACP Activities in Rat

Fig. 8 and Fig. 9 represent the influence of different doses of ESPS on testicular ALP and ACP activities in rat. There was no significant change ($P > 0.05$) in the acid phosphatase and alkaline phosphatase activity in all the test groups compared to the control groups.

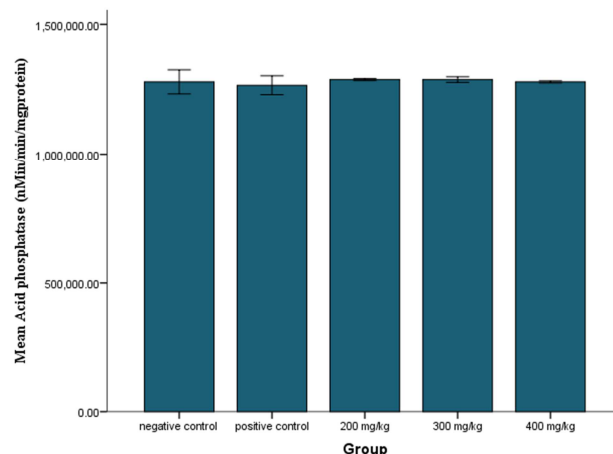


Fig. 8. Effect of Eggshell on the Acid phosphatase activity of rats administered with potassium bromate. Each value is represented as mean of four replicates \pm SEM. *Statistical difference relative to control at $P < 0.05$.

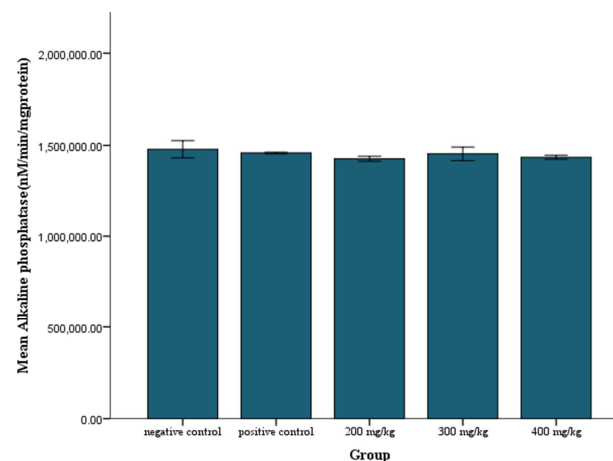


Fig. 9. Effect of Eggshell on the Alkaline phosphatase activity of rats administered with potassium bromate. Each value is represented as mean of four replicates \pm SEM. *Statistical difference relative to control at $P < 0.05$.

2.6. Effect of ESPS on Testicular Histology in Rat

The histopathological result showed normal germ cells at the group given 200 mg/kg of ESPS while there was apoptosis of germ cells at 400 mg/kg body weight (Fig 10).

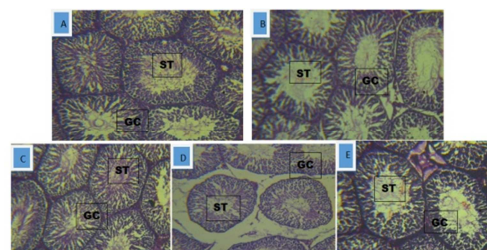


Fig. 10. The photomicrograph of testis of rats administered with (X100 H&E): (A) positive control 10 mg/kg of potassium bromate normal germ cell with tail of spermatozoa at the seminal tubule (ST) (B) Negative Control, The germ cells (GC) were normal with tails of spermatozoa obvious (C) 10 mg/kg of potassium bromate and 200 mg/kg of eggshell (D) 10 mg/kg potassium bromate and 300 mg/kg of eggshell (E) 10 mg/kg of potassium bromate and 400 mg/kg of eggshell; showed apoptotic of the germ cells (spermatogonia, spermatocyte, spermatotid and spermatozoa).

3. Discussion

The experiment showed no significant change in testes-body weight in the groups administered with 200 and 300 mg/kg body weight compared to the positive and negative control which may be an indicative of ESPS protective effect. However at higher dose of 400 mg/kg there was significant decrease in the teste body weight. The reason for the significant decrease in the testes-body ratio may be ascribed to the decrease in the number of germ cells in the rats [27]. Testicular proteins are necessary for spermatogenesis and sperm maturation [28]. The decrease in the total protein (Fig.2) in all the tests groups compared to the positive control and negative control may be due to enzymatic inhibition of protein synthesis by influencing genetic information [29]. The groups given 200 and 300 mg/kg body weight of the ESPS showed significant increase in the total cholesterol compared to the positive control but there was a marked increase in the group with 400 mg/kg body weight. Furthermore this may be ascribed to protection by ESPS which showed synthesis of cholesterol, a precursor in steroidogenesis of male sex hormone. Contrary, the marked increase observed in the cholesterol level (Fig. 3) in the testes of rats that received 400mg of the egg shell powder solution may imply damage to sertoli cells; one that can lead to phagocytosis resulting in the deposition of the cell membrane lipid [30]. High testicular cholesterol has been attributed to inhibition of androgen synthesis by leydig cell. Leydig cells release a class of hormones called androgens: testosterone, androstenedione and dehydroepiandrosterone (DHEA), when stimulated by pituitary luteinizing hormone (LH). LH increases the activity of the enzyme cholesterol desmolase stimulating synthesis and secretion of testosterone by the Leydig cells [31]. Testicular glycogen is the major source of energy in the testes in the animal reproductive system [32]; it provides carbohydrate reserves for seminiferous tubular cells. The level of glycogen is directly proportional to steroid hormones [33]. There was a marked decrease in the testicular glycogen in the group given 200 mg/kg body weight of ESPS compared to the positive and negative control. The decrease could be due to increase in the testicular activity due to ESPS leading to high consumption in the glucose in the testes (Fig.4). Malondialdehyde is a product of lipid peroxidation of the cell membrane. The marked decrease showed by the group given 200 mg/kg of ESPS compared to the positive and negative groups could be due to lipid peroxidation protecting effect by the ESPS. However, the result also showed more protective effect at lower dose compared to the group given 300 and 400 mg/kg body weight (Fig.5). The superoxide dismutase enzyme activity showed a significant reduction in the group given 200 mg/kg body weight of ESPS compared to the positive and negative control. This may imply that ESPS had a protective effect against oxidative stress due to potassium bromate. However a marked decrease in superoxide dismutase enzyme activity in the group with 400 mg/kg body weight may be due to the saturation of the enzyme or due to destruction to the molecular machinery principle to induce the enzyme (34, 35)

by the increasing free radical release resulting from the high dose ESPS the rats received (Fig. 6). Glutathione (G-S-S-G) a tripeptide, maintained in a reduced state by an efficient glutathione peroxidase/glutathione reductase system. Glutathione, an endogenous potent antioxidant protects cells from a number of noxious stimuli including oxygen derived free radicals [36]. The level of reduced glutathione is a measure of the cellular redox status [37]. Hence alteration in glutathione level may affect the overall redox status of the cell. Severe oxidative stress could result to a reduction in glutathione and glutathione s-transferase [38]. At 200 mg/kg ESPS there was an increase in the reduced glutathione compared to the negative control. The marked increase shown was as a result of optimal performance of the reduced glutathione in protecting the testes against free radicals due to lipid peroxidation protection by ESPS. However reduction in the reduced glutathione shown at a higher dose of eggshell could be due to decreased effectiveness as a result of depletion of reduced glutathione (Fig. 7). It is suggested therefore, that oxidative stress may have been induced by the egg shell powder at higher concentrations. This experiment also showed an inverse relationship between peroxidation and glutathione status [39, 40, 41, 42]. Glutathione depletion of 20% to 30% can impair the cell defense against the toxic action of xenobiotic and may lead to cell injury/death [43, 44]. Alkaline phosphatase is an important enzyme in steroidogenesis, it is involved in the intra and inter cellular transport needed for the metabolic reactions to channel necessary inputs for steroidogenesis (45, 46). ALP is involved in mobilizing carbohydrates and lipid metabolites to be utilized either within the cells of the accessory sex structures or by the spermatozoa in the seminal fluid [47] There was no significant increase in the alkaline and acid phosphatase activity in all the test groups compared to the negative and positive controls (Fig.8&9). The histopathological photomicrograph of the testes showed normal germ cells in the group given 200 mg/kg ESPS compared to the positive and negative controls. However, the group given 400 mg/kg eggshell showed a marked apoptotic of the germ cells. Oxidative stress is one of the contributory factors to induce germ cell apoptosis [48].

4. Conclusion

The histopathological and biochemical indicators of testicular functional indices recorded in this study showed a marked reduction in lipid peroxidation eliciting potential of potassium bromate in rats administered with chicken ESPS at regulated doses.

References

- [1] Y. Kurokawa, A. Maekawa, M. Takahashi and Y. Hayashi "Toxicity and carcinogenicity of potassium bromate - a new renal carcinogen". *Environ. Health Perspect.* 87: 309-335 1990.
- [2] A. S. Ekop, I.B. Obot, E.N. Ikpatt "Anti-Nutritional Factors and Potassium Bromate Content in Bread and Flour Samples in Uyo Metropolis", *Niger.E-J.Chem.* 5 (4):736-741. 2008

- [3] J. D. Keith, G.E. Pacey, J.A. Cotruvo, G. Gordon "Experimental results from reaction of bromate ion with synthetic and real gastric juices". *Toxicology* 221:225-8. 2006
- [4] J. K. Chipman, J. E. Davies, J. L. Parson, G. O'Neill, and J. K. Fawell, "DNA Oxidation by Potassium Bromate; a Direct Mechanism or Link to Lipid Peroxidation" *Toxicology*. 126:93-102. 2001
- [5] H. A. Uchida, H. Sugiyama, S. Kanehisa, K. Harada, K. Fujiwara, and T. Ono "An elderly patient with severe acute renal failure due to sodium bromate intoxication" *Intern Med* 45: 151-154. 2006
- [6] R. W. Burley, and D. V. Vadehra, "The egg shell and shell membranes: Properties and synthesis" Pages 25–64 in *The Avian Egg, Chemistry and Biology*. John Wiley, New York. 1989
- [7] S. E. Solomon, M. M. S. Bain, Cranstoun, and V. Nascimento Hens egg shell structure and function. Pages 1–24 in: *Microbiology of the Avian Egg*. R. G. Board and R. Fuller, ed. Chapman and Hall, London, England. 1994
- [8] F. Lichtenstein "Eierschalen zur peroralen Kalktherapie". *Zentbl. Gynaekol.* 4:346–348. 1948
- [9] F. Bo'lo'nyi, and S. Orso's "Examen de leffet antirachitique de la coquille doeuf sur les dents des rats" *Acta Morphol. Acad. Sci. Hung.* 4:45–49. 1954
- [10] J. J. Rovensky O. Marek Schreiberova, and M. Stancikova "Somatomadin-type activity of Biomin H. *Casopis Lekaru Ceskych* 133:213–214. 1994
- [11] F. Makai and J. Chudacek "The treatment of osteoporosis with Biomin"-H. *Arch. Gerontol. Geriatr.* 2:487–490. 1991
- [12] M. P. Stancikova A. Masaryk K. Letkovska, J. Rovensky, Wendlova', and E. Orvisky, "Effect of Biomin H on the biochemical markers of osteoporosis in postmenopausal women. *Osteoporosis Int.* 6 (Suppl. 1):267. (Abstr.). 1996
- [13] T. Itoh, K. Munakata, S. Adachi, H. Hata, T. Nakamura, T. Kato, and M. Kim. *Jpn. J. Zootech. Sci.* 61:277–282, 1990.
- [14] T., N. Nakano, Ikawa, and L. Ozimek, "Extraction of glycosaminoglycans from chicken eggshell" *Poult. Sci.* 80:681–684, 2001.
- [15] D. J. Grainger, J. Percival, M. Chiano, and T. D. Spector, "The role of serum TGF-beta isoforms as potential markers of osteoporosis". *Osteoporosis Int.* 9:398–404, 1999.
- [16] K. Nakano, T. Nakano, D. U. Ahn, and J. S. Sim, Sialic acid contents in chicken eggs and tissues. *Can. J. Anim. Sci.* 74:601–606, 1994.
- [17] National Research Council. *Guide for the Care and Use of Laboratory Animals*, 8th ed.; The National Academies Press: Washington, DC, USA, 2011.
- [18] A. G. Gornall, C. J. Bardawill, and M. M. David, "Determination of serum proteins by means of the biuret reaction," *The Journal of biological chemistry*, vol. 177, no. 2, pp. 751–766, 1949.
- [19] D.J. Jollow, J.R. Mitchell, N. Zampaglione, & J.R. Gillete, "Bromobenze induced liver necrosis: protective role of glutathione and evidence for 3,4 bromobenzene oxide as the hepatotoxic metabolite" *Pharmacology*, 11, 151-169, 1974.
- [20] H.P. Misra, I. Fridovich, "The role of superoxide anion in the autoxidation of epinephrine and a simple assay for superoxide dismutase. *J.Biol Chem* 247 (10):3170 – 3175, 1972.
- [21] K. Satoh "Serum lipid peroxide in cerebrovascular disorders determined by a new colorimetric method. *Clinica Chimica Acta*, Volume 90, Page 37-43, 1978.
- [22] A. Kemp, J.M. Adrienne and K.V. Heijningen A colorimetric micro-method for the determination of glycogen in tissues. *Biochemistry Journal*. Volume 56, Page 646-648, 1954.
- [23] D. S. Fredrickson R. I. Levy and R. S. Lees "Fat transport in lipoproteins-an integrated approach to mechanisms and disorders. *New England Journal of Medicine*, 276, 34-44, 94-103, 148-156, 215-225, 273-281, 1967.
- [24] P.J. Wright, D.T. Plummer, P.T. Leathwood "Enzyme in rat urine alkaline phosphatase" *Enzymologia* 42: 317-327, 1972.
- [25] P.J. Wright, D.T. Plummer, P.T. Leathwood "Enzyme in rat urine alkaline phosphatase" *Enzymologia* 42: 317-327, 1972.
- [26] O.S. Adeyemi M. A. Akanji, (2010b) "Psidium guava leaf extract; effects on rats' serum homeostasis and tissue morphology" *Comp Clin Pathol*.doi: 10.1007/s0058-010-1106-2.
- [27] D. R. Simorangkir, N. G. Wreford D.M. De Kretser "Impaired germ cell development in the testes of immature rats with neonatal hypothyroidism" *J Androl* 18, 186-193 1997.
- [28] M. Kasturi B. Manivannan N.R. Ahmed P.D. Shaikh K. M. Pattan" Changes in epididymal structure and function of albino rat treated with Azadirachta indica leaves. *Indian J Expt Biol* 1995; 33(10)
- [29] K. D. Kusal and D. Shakuntala "Effect of Nickel Sulfate on Testicular Steroidogenesis in Rats during Protein Restriction" *Environ Health Perspect.* 2002 Sep; 110(9): 923–926, 2002
- [30] J. B. Kerr, R. A. Mayberry and D. C. Irby, "Morphometric studies on lipid inclusions in Sertoli cells during the spermatogenic cycle in the rat," *Cell Tissue Res.*, 236, 699-709, 1984.
- [31] Y. Shima, K. Miyabayashi, S. Haraguchi, T. Arakawa, H. Otake, T. Baba, S. Matsuzaki, Y. Shishido, H. Akiyama, T. Tachibana, K. Tsutsui, K. Morohashi, "Contribution of Leydig and Sertoli cells to testosterone production in mouse fetal testes," *Mol. Endocrinol.* 27 (1), 63-73, 2013.
- [32] Datta, K. Misra, J. Dasgupta, T. Sengupta, S. "Glycogen metabolism in human fetal testes" *J.Biosc.*; Vol 13, Number 2, 1987
- [33] S. Pathak A.O. Prakash "Post-coital contraceptive effect of F. jaeschkeana Vatke and its hormonal properties. *Phytother Res* 1989; 3: 61-66.
- [34] Spolarics Z., Wu J.X.: Role of glutathione and catalase in H₂O₂ detoxification in LPS-activated hepatic endothelial and Kupffer cells. *Gastroint. Liver Physiol.* 273, G1304, 1997
- [35] Ramalingam and Vimaladevi; 2002
- [36] A. Bast, GRMM Haenen, "Cytochrome P450 and glutathione: what is the Significance of their interrelationship in lipid peroxidation?" *Trends Bio Sci*, 9: 510-513, 1984.
- [37] B. Chance, H. Sies, & A. Boveris, Hydroperoxide metabolism in mammalian organs. *Physiol. Rev.*, 59 527-605, 1979.

- [38] Aniya, Y. & Naito, A. (1993) Oxidative stress-induced activation of microsomal glutathione S-transferase in isolated rat liver. *Biochem Pharmacol.*, 45, 37-42.
- [39] S. Curello C. Ceconi C. Bigoli R. Ferrari Albertini A. "Changes in the cardiac glutathione status after ischemia and reperfusion". *Experientia*, 41: 42-43, 1985.
- [40] M.F. Hill P.K. Singal Antioxidant and oxidative stress changes during heart failure subsequent to myocardial infarction in rats. *Am J Pathol*, 148: 291-293, 1996.
- [41] P.K. Singal A.K. Dhalla M. Hill T.P. Thomas. Endogenous antioxidant changes in the myocardium in response to acute and chronic stress conditions. *Mol Cell Biochem*, 429: 179-186, 1993
- [42] H. P. Misra and I. Fridovich, "The role of superoxide anion in the autoxidation of epinephrine and a simple assay for superoxide dismutase," *J. Biol. Chem.*, 247 (10), 3170 – 3175, 1972.
- [43] A. Mezzetti C. Dillio A.M. Claiborne, A. Aceto L. Marzio "Glutathione peroxidase, glutathione reductase and glutathione S-transferase activities in the human artery, vein and heart". *J Mol Cell Cardiol*, 22: 935 – 938, 1990.
- [44] Mimic O.J. Simic T, Djukanovic Z 1995. Red blood cell glutathione peroxidase and superoxide dismutase activity in different status of chronic renal failure. *Clin Nephrol*, 44: 44 – 48.
- [45] M.A. Adaikpoh and F.O. Obi Prevention of cadmium-induced alteration in rat testes and prostate lipid patterns by α -tocopherol; *African Journal of Biochemistry Research* Vol.3 (10), pp. 321-325, October, 2009 Available online at <http://www.academicjournals.org/AJBR> ISSN 1996-0778 © 2009 Academic Journals,
- [46] N. Sofikitis and I. Miyagawa, "Secretory dysfunction of the male accessory genital gland due to prostate infections and fertility: A selected review of the literature," *Jpn. Fertil. Steril.* 36, 690-699, 1991.
- [47] J.B. Kerr R.A. Mayberry, D.C. Irby, "Morphometric studies on lipid inclusions in Sertoli cells during the spermatogenic cycle in the rat" *Cell Tissue Res* 1984; 236: 699-709, 1996.
- [48] M. Maneesh H. Jayalakshmi, S. Dutta, A. Chakrabarti D.M. Vasudevan "Role of oxidative stress in ethanol induced germ cell apoptosis-An experimental study in rats. *Ind J Clin Biochem* 20, 62-67, 2005.