

Efficacy of topical zinc sulphate on wound healing of experimentally induced skin ulcers by Nicorandil and induction effect on transforming growth factor- β

Shireen Sameen¹, Tagreed Altaei^{2,*}

¹College of Pharmacy/ Hawler Medical University, Erbil, Kurdistan-Iraq

²College of Dentistry/ Hawler Medical University, Erbil, Kurdistan-Iraq

Email address:

Tagreedaltaei@yahoo.com (T. Altaei)

To cite this article:

Shireen Sameen, Tagreed Altaei. Efficacy of Topical Zinc Sulphate on Wound Healing of Experimentally Induced Skin Ulcers by Nicorandil and Induction Effect on Transforming Growth Factor- β . *American Journal of Clinical and Experimental Medicine*. Vol. 2, No. 6, 2014, pp. 137-150. doi: 10.11648/j.ajcem.20140206.15

Abstract: Induced ulcer wound repair needs re-epithelialisation to replace necrotised and/or damaged tissue and to re-establish its integrity. Transforming growth factor- β (TGF- β) affects all cell types that are involved in all stages of wound healing. The assessment of induced ulcer wound healing activity was carried out through three models: First, excision model, second, induced ulcer wound using 50 mg Aspirin, and third by using 10 mg Nicorandil wound model. The animals were divided into eight groups; and were treated with different concentrations of Zinc sulphate, compared to their controls. The efficacy of Zinc sulphate on healing process of lesion induced was assessed by; body weight change, macroscopical appearance of the induced ulcers (ulcer area and wound contraction), microscopically appearance and histopathology; as well as qualitative assessment. Moreover, the effect of ulcer induction on the serum levels of TGF- β according to the procedure of the kit was assessed in all groups. Different concentrations of topical Zinc sulphate have not significantly enhanced the healing of excision wounds. Thirty milligram Zinc sulphate has not significantly enhanced the healing of lesion ulcer induced by 50 mg Aspirin or 10 mg Nicorandil. Nevertheless, the 50 mg Aspirin and 10 mg Nicorandil caused delay in healing. In all groups, a significant reduction in ulcer area was observed compared to that of the baseline. Besides, a significant elevation in wound contraction was noticed compared to that of the baseline. Qualitative assessment of the healing process of the induced ulcer confirms that Aspirin or Nicorandil delay healing. Assessment of serum TGF- β level in serum showed no statistical significant elevation in those groups treated with different concentrations of Zinc sulphate compared to their control, while TGF- β level showed non-significant reduction in the group of induced ulcer by Aspirin or Nicorandil and treatment with 30 mg Zinc sulphate, compared to their controls. In conclusion, Nicorandil cause ulceration in the same manner of Aspirin, which delay the healing process, and TGF- β appears to play a more profound role in the healing process perforations than in the healing of induced ulcers in skin.

Keywords: Transforming Growth Factor- β (TGF- β), Induced Ulcer, Aspirin, Nicorandil, Zinc Sulphate

1. Introduction

Wound healing is a complex multi-step process, which consists of inflammation, granulation tissue formation, angiogenesis, re epithelialisation, and wound contraction [1-3].

When a full-thick dermal wound is made and filled by a fibrin clot, inflammatory cells first migrate into the plasma clot and release local growth factors, such as transforming growth factor-beta (TGF- β), which stimulate fibroblasts from the adjacent intact dermis to migrate to the wounded site.

The migrating fibroblasts, along with newly formed vessels, fill the wound, which results in the formation of granulation tissue. TGF- β is a multi-functional cytokine involved in cellular proliferation, survival, differentiation, migration, extracellular matrix production and remodeling [4, 5].

The use of a simple and reproducible model is a basic requirement inevitable for objective statement of the effects of different external factors on skin wound healing, allowing the determination of three basic phases which occur during wound healing "inflammation, proliferation, and maturation" [6, 1].

Nicorandil is a potassium channel activator used in the treatment of Angina pectoris [7]. The first reports of Nicorandil induced oral ulceration came from France in 1997 [8]. Interestingly, there have been no reports of Nicorandil induced oral ulceration from Japan. Nicorandil induced oral ulceration may cause severe symptoms for the sufferer, including weight loss as a consequence of anorexia due to discomfort and dysphagia [9, 10]. There have even been reports of depression [11]. It is important that clinicians elsewhere be made aware that Nicorandil can be a potential inducer of ulcers that may mimic major aphthous ulcers or even carcinoma [10].

Zinc is a potent catalyst of wound healing and zinc deficiency may be a common cause of delayed tissue repair. Zn plays a part in the maintenance of epithelial and tissue integrity by promoting cell growth and suppressing apoptosis and by protecting against free radical damage during inflammatory responses, an underappreciated role [12].

2. Materials and Methods

This study was undertaken in the Department of Pharmacology and Toxicology, College of Pharmacy, and College of Medicine (animal house), Hawler Medical University, based on an ethical approved protocol for M.Sc. study.

2.1. Experimental Animals

New Zealand albino rabbits (*Oryctolagus cuniculus*) of both sexes, each weighing about 1500 ± 500 g were obtained from the animal house of the College of Medicine, University of Hawler, in compliance with the institutional Animal Care and Use Committee. The rabbits were kept in housing cages, five animals per cage, with standardised food and water, under a light/dark cycle of 12 h. The cages were kept in a room which had a constant temperature of $25 \pm 2^\circ\text{C}$. In order to prevent the animals from coming in contact with their feces and/or urine, a permeable metal floor was installed in the cages, separating the rabbits from the lower part of the cage.

2.2. Ulcer Model Wounding Design

All surgical procedures were performed under general anesthesia, by intramuscular administration of 30-35 mg/kg of ketamine hydrochloride (Ketamin-Hameln inj. 50 mg/ml, Combiphar) combined with 2 mg/kg midazolam (DORMITA-5, 5 mg/1 ml, ELSaadpharma).

The dorsal fur of the animals was shaved with an electric clipper, and the area of the wound to be created was outlined on the back of the animals, and sterilised with 70% ethanol. Then, a full thickness of excision wounds of circular area of 8 mm in diameter was created from a predetermined shaved area on the back of each animal by using a surgical circular blade. The experimental groups were treated with 10, 20, and 30 mg Zinc sulphate once daily for 6 consecutive days. A progressive decrease in the wound area was periodically monitored. The ulcer contractions or closures were

determined by measuring the diameter by calliper and calculated as percentage. The actual value was converted into percentage value taking the area of the ulcer at the time of wounding as 100%. The animals were allocated to eight groups with five animals per group:

G.A: The skin ulcer was induced by surgical excision then it was locally treated with 10 mg Zinc sulphate solution (10 mg/0.1 ml glycerin) after 24 h of ulcer induction.

G.B: The skin ulcer was induced by surgical excision then it was locally treated with 20 mg Zinc sulphate solution (20 mg/0.1 ml glycerin) after 24 h of ulcer induction.

G.C: The skin ulcer was induced by surgical excision then it was locally treated with 30 mg Zinc sulphate solution (30 mg/0.1 ml glycerin) after 24 h of ulcer induction.

G.D: The skin ulcer was induced by surgical excision then the wounds were covered with a sterilised dressing.

G.E: The skin ulcer was induced by surgical excision and was exposed for 20 s to make contact with 50 mg Aspirin, then it was locally treated with 30 mg Zinc sulphate solution (30 mg/0.1 ml glycerin) after 24 h of ulcer induction.

G.F: The skin ulcer was induced by surgical excision and was exposed for 20 s to make contact with 50 mg Aspirin; the wounds were covered with a sterilised dressing.

G.G: The skin ulcer was induced by surgical excision and was exposed for 20 s to make contact with 10 mg Nicorandil, and then it was locally treated with 30 mg Zinc sulphate solution (30 mg/0.1 ml glycerin) after 24 h of ulcer induction.

G.H: The skin ulcer was induced by surgical excision and was exposed for 20 s to make contact with 10 mg Nicorandil, the wounds were covered with a sterilised dressing.

Blood sample was drawn from the heart of the animals before induction of ulcer and after treatment at Day 7.

The rabbits were sacrificed on the 7th day after wounding by intravenous administration of pentobarbital solution. The wound areas were excised and fixed in 10% buffered formalin solution for histopathology study.

Blood sample was drawn from the heart of the animals before induction of ulcer and after treatment at Day 7.

The rabbits were sacrificed on the 7th day after wounding by intravenous administration of pentobarbital solution. The wound areas were excised and fixed in 10% buffered formalin solution for histopathology study.

2.2.1. Measurement of Ulcer Contraction

The area was measured by mathematical method. The wound contraction rate was measured as percentage reduction in wound area. Ulcer contraction was measured every day throughout the monitoring period using the following equation (Agren *et al.*, 1997).

2.2.2. Histological Evaluation

After overnight fixation, the tissue was trimmed and cut through at the widest margin. The tissue was embedded in paraffin and sectioned in 5 mm increments. The sections were made perpendicular to the anterior-posterior axes and perpendicular to the surface of the wound. Three sections

were placed on a slide, and stained with hematoxylin and eosin. Of the three sections on any one slide, the section with the widest original wound margin was used for assessment.

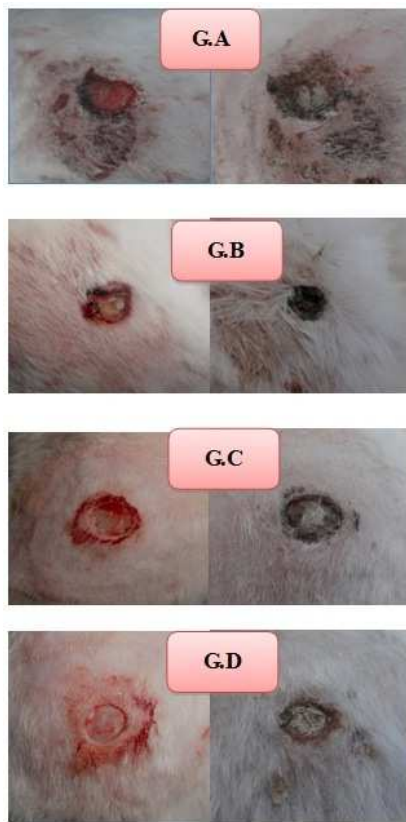

Figure 1. The progression of ulcer healing in the animals with induced ulcers by excision, and treatment with different concentrations of Zinc sulphate groups [Left side shows the ulcer at Day 1, while the right side shows the progression in healing of the groups at Day 7] $p=0.04$.

In order to characterise qualitatively the wound healing process induced by zinc sulphate, the tissue parameters, epithelialisation, congestion, inflammatory process, presence or absence of necrosis, were analysed by optical microscopy on the 7th day after the surgery. The histological parameters were classified according to the intensity of occurrence in five levels (- absence; + discrete; ++ moderate; +++ intense; ++++ very intense).

2.3. TGF- β

2.3.1. Evaluation of TGF- β

Serum TGF- β evaluated before induction of ulcer and after treatment for each rabbit by ELISA (BIO-MEDICAL ASSAY).

2.3.2. Principle of Method of TGF- β

The rabbit TGF- β ELISA kit is an *in vitro* enzyme linked immunosorbent assay for the quantitative measurement of rabbit TGF- β in serum, plasma, tissue lysates, cell culture supernatants and other biological fluids. The rabbit TGF- β monoclonal antibodies were precoated on to 96-well plate. Standard and samples were aspirated into the wells and rabbit TGF- β present in a sample is bound to the wells by the immobilised antibody. The biotinylated detection antibodies were added to the wells and then followed by wash buffer. After washing away unbound biotinylated antibody, enzyme conjugate working buffer was added to the wells. The wells were washed again, a TMB solution was added to the wells and there was colour change after adding acidic stop solution. The intensity of the colour is proportional to the amount of rabbit TGF- β bound in samples and measured at $450\text{nm} \pm 10\text{nm}$. The sensitivity of the kit is $< 15 \text{ pg/ml}$.

2.4. Statistical Analysis

Data were summarised as mean \pm SD and analysed using the Statistical Package for Social Sciences (SPSS, version 19). Student's *t* test was used to compare between means of two groups. Analysis of Variance (ANOVA) was used to compare between three means or more. A *p* value of ≤ 0.05 was considered statistically significant.

3. Results

3.1. Efficacy of 10, 20, 30 mg Zinc Sulphate on Healing Process of Ulcer Induced by Excision, Compared to Control

3.1.1. Body Weight of Ulcer Induced by Excision Model

All animals were weighted daily starting from Day 0 till Day 7. The mean body weights for each group throughout the trial are presented in Table 3.1. There was no significant weight difference ($P=0.796$) of treated group compared to control, across Days 0 to 7.

Table 1. Shows the body weight of rabbits with induced ulcer by excision, and treated by 10, 20, 30 mg zinc sulphate (G.A, G.B, G.C) compared to control (G.D) throughout the experimental periods.

Time/day	Weight/g			
	G.A Mean \pm SD	G.B Mean \pm SD	G.C Mean \pm SD	G.D Mean \pm SD
0	1276.8 \pm 711.9	1338 \pm 207.4	1299.4 \pm 258.4	1279 \pm 369.4
1 st	1238.6 \pm 478.3	1286.4 \pm 230.3	1287.2 \pm 219.2	1291 \pm 318.5
2 nd	1247.8 \pm 467.8	1292.2 \pm 253.8	1290.2 \pm 211.9	1304.6 \pm 319.0
3 rd	1236.6 \pm 469.4	1304.8 \pm 248.5	1295.4 \pm 200.9	1299.2 \pm 325.7
4 th	1232.8 \pm 455.2	1306.2 \pm 266.8	1276.4 \pm 199.7	1297.4 \pm 335.6
5 th	1213.6 \pm 484.8	1289.4 \pm 262.0	1287.6 \pm 187.8	1305.2 \pm 352.6
6 th	1229.6 \pm 481.4	1268.8 \pm 264.1	1300.6 \pm 162.5	1299.8 \pm 336
7 th	1217.8 \pm 488.5	1286 \pm 243.4	1319.4 \pm 205.0	1285.8 \pm 348.4

G.A: Induced ulcer by excision treated by local application of 10 mg Zinc sulphate. G.B: Induced ulcer by excision treated by local application of 20 mg Zinc sulphate. G.C: Induced ulcer by excision treated by local application of 30 mg Zinc sulphate. G.D: Induced ulcer by excision – Control/non-treated group. Data are expressed as mean \pm standard deviation. The mean recorded is the average of 5-measured wound (mm^2).

3.1.2. Macroscopical Appearance of the Induced Ulcer by Excision

Each induced ulcer was evaluated for the presence of exudate or other signs. All induced ulcers were free of exudate throughout the study. On Day 7, the ulcer size was reduced significantly ($p=0.04$) in all groups, and a scab-like powder accumulation was noticed over the ulcer surface on Day 7 as shown in Figure 1.

3.1.2.1. The Ulcer Area

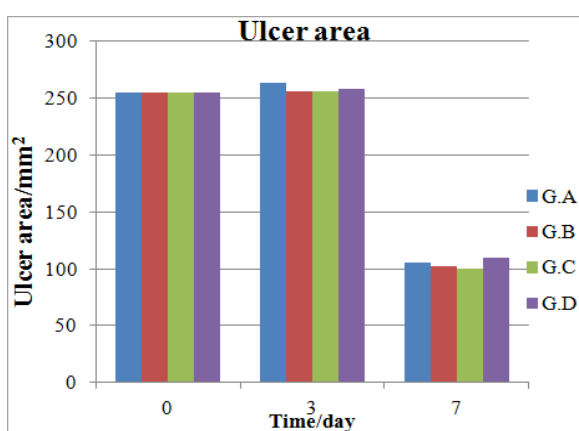


Figure 2. The ulcer area (mm^2) in the treated groups of rabbits by different concentrations of ZnSO_4 during the days of the study.

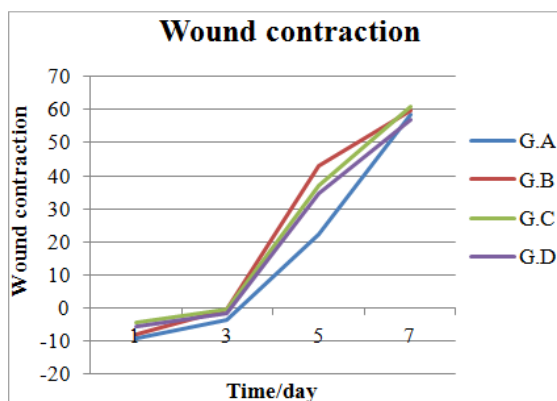


Figure 3. The contraction of the induced ulcer by excision & treatment with different concentrations of Zinc sulphate groups in comparison to the control.

The induced ulcer by excision of the rabbits' skin caused obvious ulcerated lesions from Day 3 up to Day 7. Measurement of dimensions of the induced ulcers by calliper was carried out from Day 0 till Day 7. No significant increase in the dimensions of the ulcerated area was detected in the treated groups and control till Day 3; G.A ($P=0.07$), G.B ($P=0.95$), G.C ($P=0.94$), G.D ($P=0.859$). There was a

reduction in the ulcer area after Day 4 of the study, as a significant reduction of the ulcer area was found at the 7th day of the study compared to that of the baseline; G.A ($P=0.00056$), G.B ($P=0.0001$), G.C ($P=0.00024$), G.D ($P=0.0004$). However, no significant difference was seen between these groups ($P=0.867$) as shown in Figure 2.

3.1.2.2. The Wound Contraction

The ulcer was evident macroscopically; the ulcerated area showed loss of surface epithelium and exposure of the underlying connective tissues. At Day 3, all treated groups (G.A, G.B, G.C) and control group (G.D) showed no significant reduction of wound contraction; G.A ($P=0.396$), G.B ($P=0.487$), G.C ($P=0.653$), G.D ($P=0.39$). Nevertheless there was a significant elevation of wound contraction at Day 7; G.A ($P=0.00022$), G.B ($P=0.0058$), G.C ($P=0.0065$), G.D ($P=0.0067$) compared to those of Day 1. Besides, there was no significant difference in the wound contraction for the four groups ($P=0.984$). Wound contraction was lower in the control rabbits compared to those of treated rabbits by different concentrations of ZnSO_4 . These are shown in Figure 3.

3.1.3. Microscopical Appearance & Histopathology of the Induced Ulcer

Biopsies from the site of the induced lesions were taken from animals of each group at Day 7. Both re-epithelialisation and formation of granulation tissue were first analysed by histological means in the histological sections. The results of this analysis are shown in Figure 4.

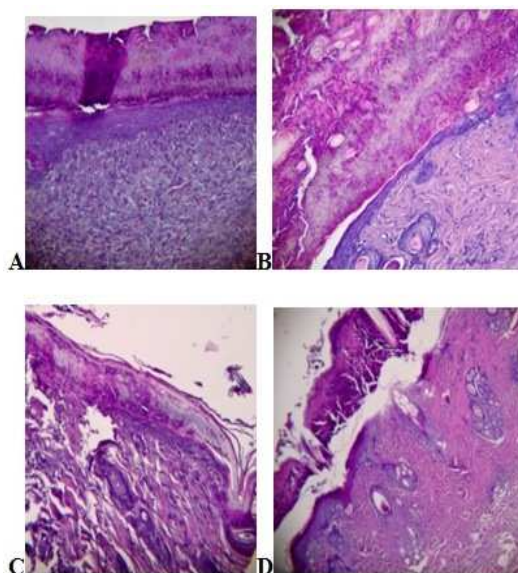


Figure 4. The microscopical features of induced ulcer at Day 7, the loss of epithelia is clearly evident: A: G.A section shows surface ulceration with early re-epithelialisation inflammatory cells and new blood vessel. B: G.B section shows surface ulceration with early epithelialisation, inflammatory cell, new blood vessel and collagen deposition. C: G.C section shows surface ulceration with early re-epithelialisation, inflammation and necrosis present. D: G.D section shows surface ulceration with very early epithelialisation, and collagen deposition is profound. H & E (power $\times 10$).

3.1.3.1. Qualitative Assessment of the Healing Process

In order to characterize qualitatively the ulcer healing process induced by excision, the tissue parameters, epithelialization, congestion, inflammatory process, presence or absence of necrosis and collagen deposition were analyzed

by optical microscopy. The histological parameters were classified according to the intensity of occurrence in five levels (- absence; + discrete; ++ moderate; +++ intense; ++++ very intense), compatible with (Araújo, *et al.*, 2010) as showed in Table 2.

Table 2. The intensity of histological parameters assessment of induced ulcer by excision & treatment with different concentration of Zinc sulphate (G.A, G.B, G.C) compared to the control (G.D).

Groups	Epithelialization	Congestion	Histological parameter Inflammation	Necrosis	Collagen
A	++	+	++	-	-
	+	++	++	+	-
	+	+	++	+	+
	+	+	+	+	+
	+	+	++	+	+
B	+	++	+	+	+++
	+	+	++	-	+
	+	+	++	+	+
	+	+	++	+	+
	+	+	++	++	-
C	+	+	+	++	+
	+	+	++	-	+
	+	+	+	-	+
	+	++	++	-	+
	+	-	++	+	++
D	+	+	++	-	++
	+	+	++	-	++
	+	+	++	+	++
	+	+	++	+	++
	+	+	++	+	+++

Note: Identification of groups in section 2.2.

3.2. Effect of Zinc Sulphate on the Healing Process of the Induced Ulcer by 50 mg Aspirin

3.2.1. Body Weight of the Induced Ulcer by 50 mg Aspirin Model

The animals were weighted daily starting from Day zero till the 7th day in the group of induced ulcer by 50 mg Aspirin, and were treated with 30 mg Zinc sulphate (G.E), in order to compare them with the control group (G.F). The mean body weights for each group throughout the study period are presented in Table 3. There was no significant weight difference for treated groups compared to that of the control group ($P=0.165$). This is where the control group showed a noticeable reduction in the body weight across Days 0 to 7, ($P>0.05$).

Table 3. The body weight of rabbits with induced ulcer by 50 mg Aspirin and treated with 30 mg Zinc sulphate (G.E) compared to that of its control (G.F) throughout the experimental period.

Time (day)	Body weight (g)	
	G.E Mean \pm SD	G.F Mean \pm SD
0	1177.4 \pm 742.7	1382.4 \pm 124.242
1 st	1191 \pm 613.8	1356.2 \pm 125.1
2 nd	1183 \pm 602.2	1357.4 \pm 132.1
3 rd	1186.8 \pm 607.7	1350.6 \pm 124.6
4 th	1174.4 \pm 592.6	1322.8 \pm 103.0
5 th	1176 \pm 598.6	1314.4 \pm 121.4
6 th	1164 \pm 574.6	1308.6 \pm 126.6
7 th	1180.2 \pm 588.8	1332.4 \pm 128.4

The mean recorded is the average of 5-measured wound (mm^2), $P>0.05$.

3.2.2. Macroscopical Appearance of the Induced Ulcer by 50 mg Aspirin

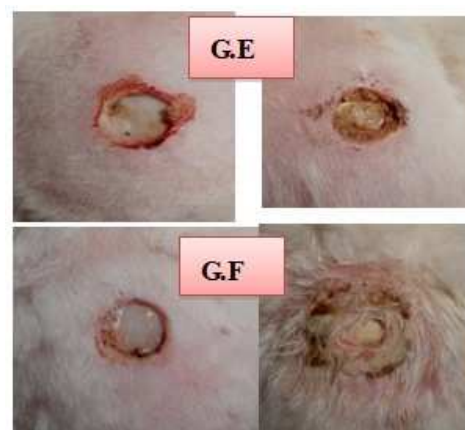

Figure 5. Ulcer healing in the animals with induced ulcers by 50 mg Aspirin, and treated with 30 mg of Zinc sulphate, compared to that of the control group [Left side showing the ulcer at Day 1, and right side showing the progression in the healing of the groups at Day 7].

Each induced ulcer by 50 mg Aspirin was evaluated for the presence of exudate or other signs. It was observed that all induced ulcers were free of exudate throughout the study. However, on Day 7, the ulcer size was reduced significantly in both groups as shown in Figure 5.

3.2.2.1. The Ulcer Area

It was noticed that the induced ulcer by 50 mg Aspirin that has been treated with 30 mg zinc sulphate and with 50 mg Aspirin (control) of the rabbits' skin caused obvious ulcerated lesions from Day 2 up to Day 7. Measurements of dimensions of the induced ulcers by calliper were carried out from Day 0 till Day 7. No significant increase in the dimensions of the ulcerated area was detected in the treated group and control till Day 3; G E ($P=0.694$), G F ($P=0.857$), while that a highly significant reduction of the ulcer area was found at Day 7; for the Groups G E ($P=0.0012$), G F ($P=0.0028$) compared to that of the baseline. Noticeably, no significant difference in ulcer area was seen between both groups during the same period; ($P=0.708$) as shown in Figure 6.

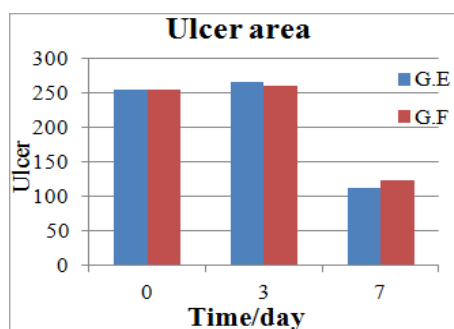


Figure 6. The ulcer area of the induced ulcer by 50 mg Aspirin group and treated with 30 mg Zinc sulphate group (G.E), compared to its control group (G.F) of rabbits at different days of the study.

3.2.2.2. The Wound Contraction

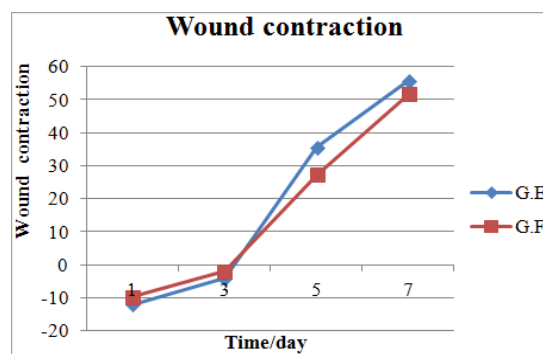


Figure 7. The wound contraction of those groups induced by 50 mg Aspirin & treated with 30 mg Zinc sulphate group (G.E) compared to its control group (G.F).

Table 4. The intensity of histological parameters assessment of induced ulcer by 50 mg Aspirin & treatment with 30 mg Zinc sulphate (G.E) compared to that of the control (G.F).

Groups	Epithelialization	Congestion	Inflammation	Necrosis	Collagen
E	-	+	++	++	+
	-	+	++	+	+
	-	+	++	+	+
	-	+	+	+	+
	-	+	+	+	+
F	-	+	++	-	+
	-	+	++	+	+
	-	+	++	+	+
	-	+	++	+	+
	-	+	+	+	+

The ulcer was evident macroscopically; the ulcerated area showed loss of surface epithelium and exposure of the underlying connective tissues. At Day 3, treated group with 30 mg and control group showed no significant reduction in wound contraction; G E ($P=0.177$), G F ($P=0.177$), while there was a significant elevation of wound contraction at Day 7; G E ($P=0.0031$), G F ($P=0.0064$), compared to that of Day 1. It is worth to mention that there was no significant difference in the wound contraction for both groups ($P=0.704$), as wound contraction was seen to be lower in the control rabbits than in those treated with 30 mg of $ZnSO_4$ as shown in Figure 7.

3.2.3. Microscopical Appearance & Histopathology of the Induced Ulcer by 50 mg Aspirin

The induced ulcers' biopsies that were taken from rabbits' skin of each group at Day 7 are shown in Figure 8.

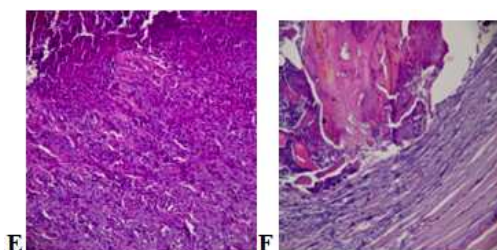


Figure 8. The microscopically features at Day 7 of the induced ulcer by 50 mg Aspirin: G.E; section showing surface ulceration with no epithelialization also showing abundant inflammatory cell, new blood vessels, necrosis and collagen deposition present. G.F; section showing no epithelialization, deep ulceration, and crust is abundant, inflammation and new blood vessel present. H & E (Power x 10).

3.2.4. Qualitative Assessment of the Healing Process of the Induced Ulcer by 50 mg Aspirin

The qualitative assessment of the ulcer healing process for the induced ulcers by 50 mg Aspirin, the tissue parameters, epithelialisation, congestion, inflammatory process, presence or absence of necrosis and collagen deposition were analysed by optical microscopy. The histological parameters were classified according to the intensity of occurrence in five levels (- absence; + discrete; ++ moderate; +++ intense; ++++ very intense), compatible with (Araújo, *et al.*, 2010) as shown in Table 4.

3.3. Effect of Zinc Sulphate on the Healing Process of Induced Ulcer by 10 mg Nicorandil

3.3.1. Body Weight of Induced Ulcer by 10 mg Nicorandil Model

Table 5. The body weight of rabbits with induced ulcer by 10 mg Nicorandil and were treated with 30 mg Zinc sulphate (G.G) compared to that of the control (G.H) throughout the experimental period.

Time (day)	Body Weight (g)	
	G.G Mean \pm SD	G.H Mean \pm SD
0	1597.8 \pm 266.2	1619.6 \pm 270.6
1 st	1588.8 \pm 260.0	1610.6 \pm 256.8
2 nd	1583 \pm 263.0	1593.4 \pm 227.1
3 rd	1595 \pm 267.9	1579.4 \pm 207.3
4 th	1592.4 \pm 269.0	1599.6 \pm 195.3
5 th	1571.2 \pm 272.6	1601.6 \pm 216.0
6 th	1546.4 \pm 273.4	1608.6 \pm 235.5
7 th	1568 \pm 275.8	1649.6 \pm 201.9

The mean recorded is the average of 5-measured wound (mm²), $P > 0.05$.

The animals were weighted daily starting from Day 0 to the 7th day in the group of induced ulcer by 10 mg Nicorandil, and treated with 30 mg Zinc sulphate (G.G) compared to the control group (G.H). The mean body weights for each group throughout the study period are presented in Table 5. One can see from the results that there is no significant weight difference in both groups across the study from Days 0 to 7, ($P > 0.35$).

3.3.2. Macroscopical Appearance of the Induced Ulcer by 10 mg Nicorandil

Each induced ulcer by 10 mg Nicorandil was evaluated for the presence of exudate or other signs. It was found that all induced ulcers were free of exudate throughout the study. On Day 7, the ulcer size was reduced significantly in both groups (compared to the baseline), as shown in Figure 9.

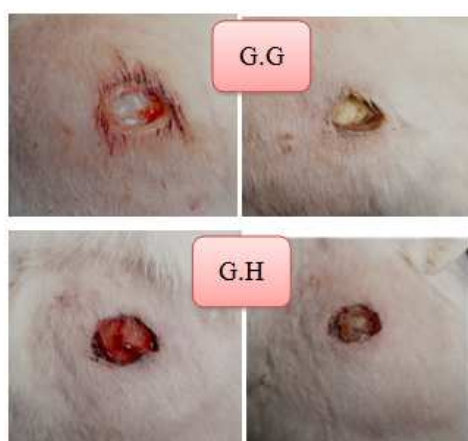

Figure 9. The gross appearance of the induced ulcers by 10 mg Nicorandil and treated with 30 mg of Zinc sulphate (G.G), compared to its control group (G.H) [Left side showing the ulcer at Day 1, and right side showing the progression in the healing of the groups at Day 7].

3.3.2.1. The Ulcer Area

The induced ulcer by 10 mg Nicorandil and treatment with 30 mg Zinc sulphate group (G.G), and with 10 mg Nicorandil (control) of the rabbits' skin caused obvious ulcerated lesions from Day 2 up to Day 7. Measurement of dimensions of the induced ulcers by calliper was carried out from Day 0 till Day 7. Noteworthy, no significant increase in the dimensions of the ulcerated area was detected in the treated groups and control group till Day 3; G.G ($P = 0.363$), G.H ($P = 0.521$). Nevertheless, there was a highly significant reduction in the ulcer area at Day 7; G.G ($P = 0.00045$), G.H ($P = 0.00016$) - compared to that of the baseline. However, no significant difference was seen between both groups in the same period ($P = 0.921$) as shown in Figure 10.

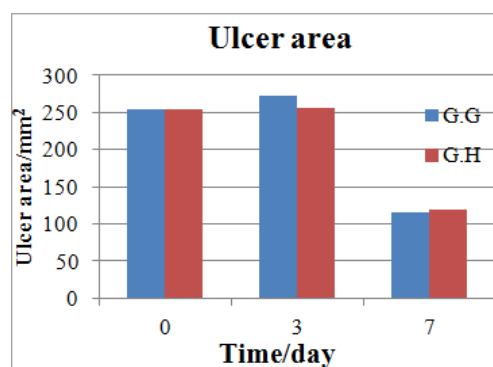


Figure 10. The ulcer area of the induced ulcer by 10 mg Nicorandil and treatment with 30 mg Zinc sulphate group (G.G) compared to its control group (G.H) during the experimental period of the study.

3.3.2.2. The Wound Contraction

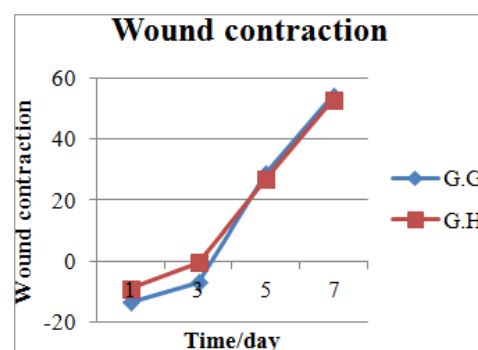


Figure 11. The contraction of induced ulcer by 10 mg Nicorandil group and treatment with 30 mg Zinc sulphate group (G.G) compared to that of its control (G.H) during the period of the experiment.

The contraction of the macroscopically evident induced ulcers by 10 mg Nicorandil control then treated with 30 mg zinc sulphate and control group showed loss of surface epithelium and exposure of the underlying connective tissues. At Day 3, treated group with 30 mg zinc sulphate and control group showed no significant reduction in wound contraction; G.G ($P = 0.189$), G.H ($P = 0.084$), but there was a significant elevation of wound contraction at Day 7; G.G ($P = 0.01$), G.H ($P = 0.0012$) compared to that of Day 1. The results showed no significant difference in wound

contraction between the two groups ($P=0.963$). Wound contraction was lower in the controlled rabbits than in those treated with 30 mg of $ZnSO_4$ as shown in Figure 11.

3.3.3. Microscopical Appearance & Histopathology of the Induced Ulcer by 20 mg Nicorandil

Induced ulcers' biopsies were taken from rabbits' skin of each group at the 7th day. Both re-epithelialisation and formation of granulation tissue were first analysed by histological means, as shown in Figure 12.

3.3.3.1. Qualitative Assessment of the Healing Process of the Induced Ulcer by 10 mg Nicorandil

The qualitative assessment of the ulcer healing process that was induced by 10 mg Nicorandil; the tissue parameters, epithelialisation, congestion, inflammatory process, presence or absence of necrosis and tissue collagen deposition, were analysed by optical microscopy. The histological parameters

were classified according to the intensity of occurrence in five levels (- absence; + discrete; ++ moderate; +++ intense; ++++ very intense), as shown in Table 6.

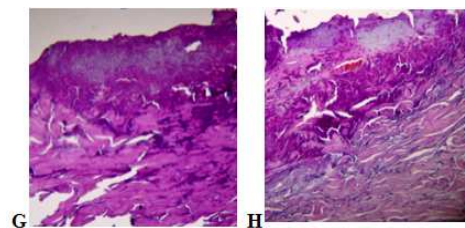


Figure 12. The microscopically features of the induced ulcer by 10 mg Nicorandil at Day 7: The left side (G.G); this section shows no epithelialization, inflammatory cell infiltration, abundant collagen deposition found in the ulceration and desecret inflammatory cells. The right section (G.H); this section shows the surface ulceration, no epithelialization, inflammatory cell infiltration abundant collagen deposition present. H & E (high power x 10).

Table 6. The intensity of histological parameters assessment of induced ulcer by 10 mg Nicorandil & treatment with 30 mg Zinc sulphate (G.G), compared to that of the controlled group (G.H).

Groups	Epithelialization	Congestion	Inflammation	Necrosis	Collagen
G	-	+	++	-	+
	-	+	++	+	++
	-	+	++	+	+
	-	+	+	+	+
	-	+	+	+	++
H	-	+	++	-	+
	-	+	++	+	+
	-	+	++	+	+
	-	+	++	+	+
	-	+	++	+	+

3.4. Comparison of the Three Methods of Ulcer Induction

Comparisons of the different methods of ulcer induction on the studied parameters are discussed in this section.

3.4.1. Body Weight Comparison of the Three Models

Table 7. The body weight of rabbits with induced ulcer by three methods; excision (G.D), induced by 50 mg Aspirin (G.F), and induced ulcer by 10 mg Nicorandil (G.H).

Time	G.D	Weight/g	G.H
	Mean \pm SD	G.F Mean \pm SD	Mean \pm SD
0	1279 \pm 369.4	1382.4 \pm 124.2	1619.6 \pm 270.6
1 st	1291 \pm 318.5	1356.2 \pm 125.1	1610.6 \pm 256.8
2 nd	1304.6 \pm 319.0	1357.4 \pm 132.1	1593.4 \pm 227.1
3 rd	1299.2 \pm 325.7	1350.6 \pm 124.6	1579.4 \pm 207.3
4 th	1297.4 \pm 335.6	1322.8 \pm 103.0	1599.6 \pm 195.3
5 th	1305.2 \pm 352.6	1314.4 \pm 121.4	1601.6 \pm 216.0
6 th	1299.8 \pm 336.0	1308.6 \pm 126.6	1608.6 \pm 235.5
7 th	1285.8 \pm 348.4	1332.4 \pm 128.4	1649.6 \pm 201.9

The mean recorded is the average of 5-measured wound (mm^2), $P > 0.05$.

The animals were weighed daily starting from Day 0 till Day 7. The mean body weights for each group of different ulcer induction throughout the study are presented in Table 7. There was no significant weight difference between the

groups assigned by various ulcer induction methods across Days 0 to 7. ($P=0.385$).

3.4.2. Macroscopical Appearance of the Induced Ulcers by the Three Methods

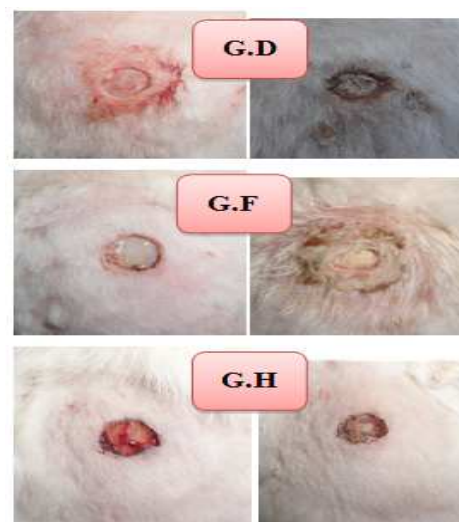

Figure 13. The progression of ulcer healing in the animals with induced ulcers by the three methods (G.D, G.F, G.H) [Left side shows the ulcer at Day 1, and right side shows the progression in healing of the groups at Day 7].

Each induced ulcer by excision, 50 mg Aspirin, and 10 mg Nicorandil, was evaluated for the presence of exudate or other signs. All induced ulcers were seen to be free of exudate throughout the study. On Day 7, the ulcer size was reduced significantly in the three groups compared to that of baseline, as shown in Figure 13.

3.4.2.1. The Ulcer Area

The induced ulcer by the three methods of the rabbits' skin caused obvious ulcerated lesions from Day 2 up to Day 7. Measurement of dimensions of the induced ulcers by caliper was carried out from Day 1 till Day 7. No significant increase in the dimensions of the ulcerated area was detected in the three groups till Day 3; G.D ($P=0.859$), G.F ($P=0.857$), G.H ($P=0.521$). However, there was a reduction in the ulcer area after Day 4 of the study, and a significant reduction of the ulcer area was found at Day 7 of the study compared to that of the baseline; G.D ($P=0.0004$), G.F ($P=0.0028$), G.H ($P=0.00016$). Nevertheless no significance difference was seen between these groups ($P=0.754$), as shown in Figure 14.

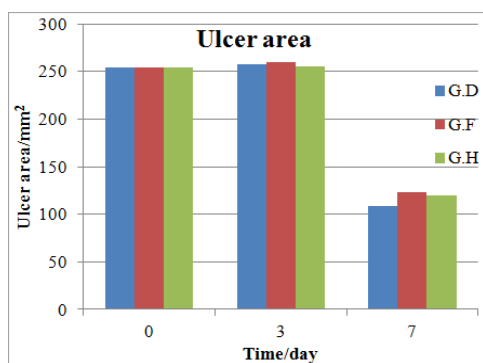


Figure 14. The ulcer area of the induced ulcer by different methods (G.D, G.F, G.H), during the experimental period.

3.4.2.2. The Wound Contraction

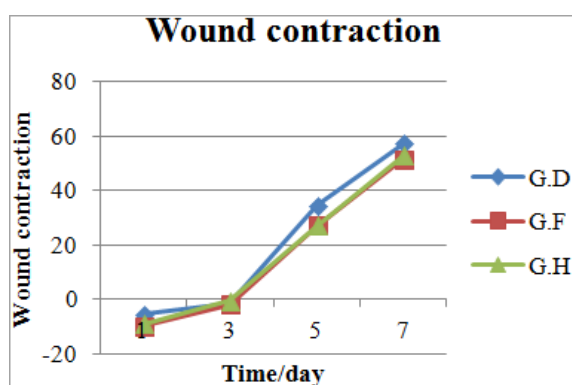


Figure 15. The wound contraction of the induced ulcer by different methods (G.D, G.F, G.H) during the period of experiment.

The contraction of the macroscopically evident induced ulcers by the three methods is shown in Figure 15. It is seen from the figure that the ulcerated area showed loss of surface epithelium and exposure of the underlying connective

tissues. At Day 3, treated group with 30 mg zinc sulphate and control group showed no significant reduction in wound contraction; G.D ($P=0.39$), G.F ($P=0.177$), G.H ($P=0.084$), while there were significant elevations of wound contraction at Day 7; G.D ($P=0.0067$), G.F ($P=0.0064$), G.H ($P=0.0012$) compared to that at Day 1. Additionally, there was no statistical difference in ulcer contraction between the three groups during the studied period ($P=0.879$). Interestingly, ulcer contraction and epithelialisation were lower in the F group, followed by group H, while group D showed a better ulcer contraction during the experimental period.

3.4.3. Microscopical Appearance and Histopathology of the Induced Ulcer by the Three Methods

Induced ulcers' biopsies were taken from rabbits' skin of each group at the 7th day. Both re-epithelialisation and formation of granulation tissue were first analysed by histological means, as shown in Figure 16.

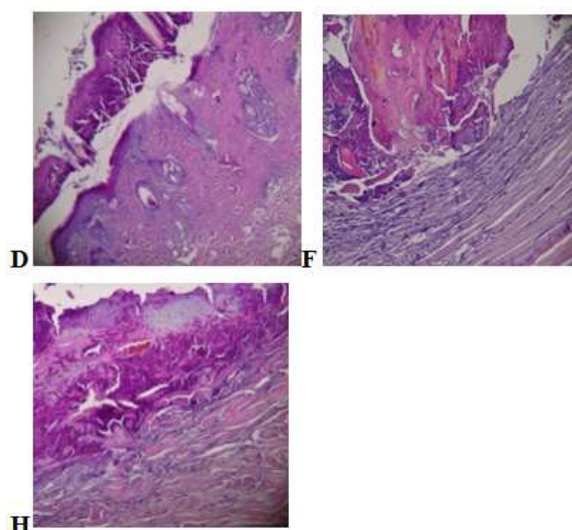


Figure 16. The microscopically features of the induced ulcer by the three methods at Day 7. The G.D section shows surface ulceration with very early epithelialization, and collagen deposition is profound. The G.F section shows no epithelialization, deep ulceration, and crust is abundant, inflammation and new blood vessel present. The G.H section shows the surface ulceration, no epithelialization, inflammatory cell infiltration abundant collagen deposition present, H & E (high power x 10).

3.4.3.1. Qualitative Assessment of the Healing Process of the Induced Ulcer by the Three Methods

The ulcer healing process of the three methods of induction was assessed qualitatively by optical microscopy depending on the tissue parameters, epithelialisation, congestion, inflammatory process, presence or absence of necrosis and tissue re-formation, which analysed. The histological parameters were classified according to the intensity of occurrence in five levels (- absence; + discrete; ++ moderate; +++ intense; ++++ very intense), as shown in Table 8.

Table 8. The intensity of histological parameters assessed in the groups of induced ulcer by different methods; excision (G.D), induced by 50 mg Aspirin (G.F), and induced ulcer by 10 mg Nicorandil (G.H).during the studied period.

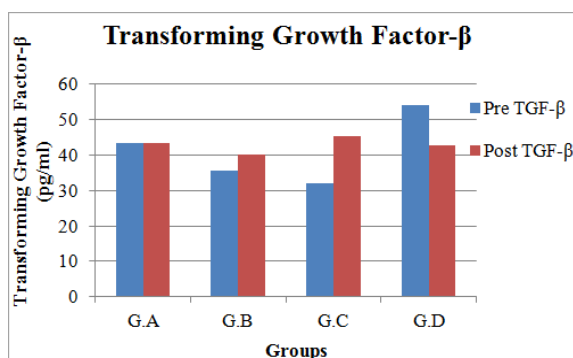
Groups	Epithelialization	Congestion	Inflammation	Necrosis	Collagen
D	+	-	+	+	++
	+	+	+	-	++
	+	+	+	-	++
	+	+	++	+	+++
	-	+	++	-	+
F	-	+	++	+	+
	-	+	++	+	+
	-	+	+	+	+
	-	+	+	+	++
	-	+	++	-	+
H	-	+	++	+	+
	-	+	++	+	+
	-	+	++	+	+
	-	+	++	+	+

3.5. Ulcer induction and Transforming Growth Factor- β

TGF- β is generally involved in wound healing. This section shows the effect of ulcer induction by different methods on the healing process via the level of the TGF- β . In addition to the effect of medications used on the serum levels of TGF- β .

3.5.1. Transforming Growth Factor- β Values of the Induced ulcers by Excision & Treated with Different Concentrations of Zinc Sulphate

The levels of serum TGF- β of the groups were increased after 7 days of ulcer induction. No change in the levels of serum TGF- β of the induced lesions of rabbits' skin was noted in group A, while noticeable increase in the levels of serum TGF- β was found in groups B and C. The results showed a 7th day dependent elevation effect on serum TGF- β levels, and group D showed a slight elevation in the levels of TGF- β , compared to that of the baseline levels. Meanwhile, No significant difference was found between four groups ($P=0.759$), as shown in Figure 17.

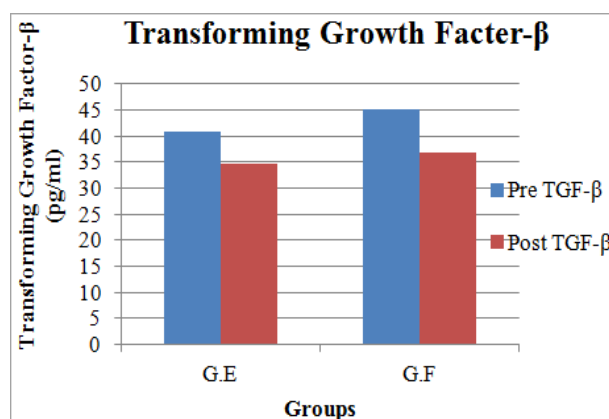
**Figure 17.** TGF- β values in animals with induced ulcer by excision & treatment with different concentrations of Zinc sulphate groups (G.A, G.B, G.C) compared to the controlled group (G.D)

3.5.2. Effect of Zinc Sulphate on the Healing Process of Ulcer Induced by 50 mg Aspirin

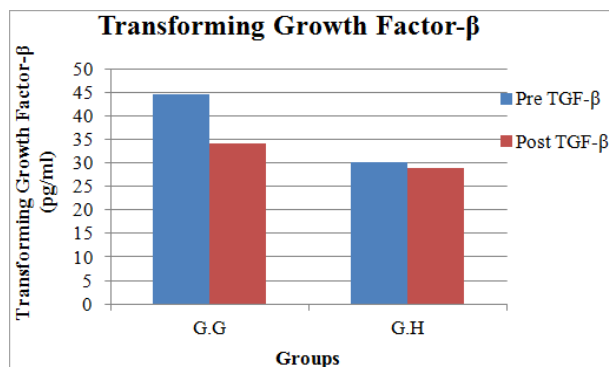
A noticeable reduction in the serum levels of TGF- β of the induced ulcer by 50 mg Aspirin was noted in both groups.

The results showed a 7th day dependent effect on the serum levels of TGF- β , compared to that of the baseline.

No significant difference was seen in the level of TGF- β of group (F) compared to that of its control (E), $P=0.911$, as shown in Figure 18.

**Figure 18.** The TGF- β values in animals with induced ulcer by 50 mg Aspirin & treatment with 30 mg Zinc sulphate group (G.E), compared to its control (G.F).

3.5.3. Effect of Zinc Sulphate on the Healing Process of Ulcer Induced by 10 mg Nicorandil

**Figure 19.** The TGF- β values in animals with induced ulcer by 10 mg Nicorandil group & treatment with 30 mg Zinc sulphate group (G.G), compared to its control (G.H).

The levels of TGF- β of the induced ulcer by 10 mg Nicorandil showed a notable reduction in the treated group (G.G), while in the control (G.H) a very slight reduction has been observed. Comparison of the two groups; showed non-significant difference in the levels of TGF- β in group (G) compared to that of the control group (H), $P = 0.79$, as shown in Figure 19.

3.5.4. Effects of the Different Induction Methods of the Ulceration on the TGF- β Values

The comparison of the three methods of ulcer induction on serum levels of TGF- β showed a non-significant difference between the groups ($P=0.875$). There was a notable reduction in the serum levels of TGF- β in group F, while there was a slight reduction in the serum levels of TGF- β in group H, and slight elevation in the level of TGF- β in group D, as shown in Figure 20.

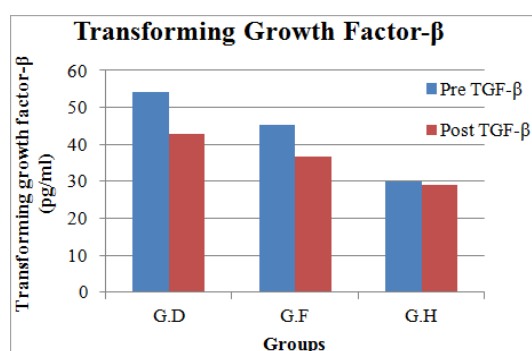


Figure 20. The TGF- β values of induced ulcers on the rabbits' skin by the three different methods (G.D, G.F, G.H).

4. Discussion

Wound healing is categorised into three stages; inflammatory phase (consisting of homeostasis and inflammation); proliferative phase (consisting of granulation, contraction and epithelialisation [13].

This study was designed using excision wound model in animals to study the induction of ulcer by three methods, also to show the effect of topical zinc sulphate on wound healing in these different models compared according to; body weights, macroscopical appearance (ulcer area, and contraction), Microscopical appearance & Histopathology (Qualitative assessment), and effect of ulcer induction by the three methods on the Transforming Growth Factor- β , which will discuss in the following paragraphs.

Concerning the body weights; there were no significant weight differences in the groups treated with different concentrations; 10, 20, and 30 mg of zinc sulphate compare to the control, across the study from Days 0 to 7, ($P>0.05$). Also non-significant weight difference was observed between the groups that was induced with ulcer by 50 mg and treated with 30 mg zinc sulphate compare to its control. The group that was induced with ulcer by 10 mg Nicorandil and treated with 30 mg zinc sulphate when compared to its control showed non-significant weight difference. Wounding

is severe in the excision wound model, this allowed for the investigation of central tissue movements associated with repair, starting with haemorrhage followed by re-epithelialisation, granulation tissue formation, and angiogenesis [14].

Wounds of all groups were enlarged on Day 1 post wounding, an indication of progressing pathology due to acute inflammation. It was observed that, a few hours after wounding, the wounded area had soon been closed by a thin scab, which became hardened within the first 2 days of repair in accordance with Paddock's accession, 2003 [14]. Ulcer size and area had increased until Day 3 then it was generally reduced by the end of experimentation relative to their original sizes, in all studied groups; groups treated with Zinc sulphate, showed dose dependent effect by the reduction of ulcer area, compared to the control, and those group with induced ulcer by Aspirin that were treated with 30 mg Zinc sulphate showed reduction in the ulcer area very slightly faster than the control one, while the groups with induced ulcer by 10 mg Nicorandil and treated with 30 mg Zinc sulphate showed reduction of ulcer area faster than the control one, in the same period of the study. But no significant differences were found between groups.

This study disagrees with the study which reported that reduction in surface ulcer area with zinc mouthwash plus fluocinolone ointment was greater than that with the ointment alone, which is attributable to the effect of zinc on healing of disrupted epithelium [15].

Comparing the three methods of ulcer induction, showed obvious ulcerated lesions from Day 2 till Day 7, ulcer area reduction which was started in the excision wounded skin group was slightly faster than the group with induced ulcer by 50 mg Aspirin, and 10 mg Nicorandil of the rabbits' skin, depending on this finding both Aspirin and Nicorandil delayed healing without significant effect.

Contraction and epithelialisation are two independent processes that heal full-thickness cutaneous wounds; contraction reduces the size of a wound by centripetal movement of the dermis and epidermis to facilitate closure of the defect. Epithelialisation process is proliferation and migration of epidermal cell at a wound's edge to cover the surface of the cutaneous ulcer [16]. Wound contraction is an essential process in healing which leads to wound closure. Thus, visible appearances and measurements of wound contraction become reliable parameters in macroscopic evaluation for wound healing [17].

This study showed that there was no statistical significant difference in wound contraction between the studied groups. Ulcer contraction was increased significantly with time in rabbits during the studied period (compared to baseline). Comparing the three methods of ulcer induction showed that the group of excision only showed slight elevation of wound contraction more than those induced by 50 mg Aspirin and 10 mg Nicorandil, the explanation of this difference related to the presence of chemical agent that impair and delayed the healing process and this effect is mild.

The excision wound is found to be more suitable for histological evaluation due to the broader morphological changes occurring during the process of wound healing [18]. This study agrees with that, in which the closure of wound increased significantly during the studied period.

Prolong ulcer due to the presence of chemical agent lead to the persistent damage to the tissue. Previous experimental studies showed that surgically induced lesions of the same size heal at a much faster rate than chemically induced ulcers. The possible mechanisms that have been suggested as the cause of this prolonged healing of the induced lesions is that the chemicals may binds directly to the bases of DNA and interferes with nuclear function. Thus, it would interfere with the cell replication necessary for the healing of tissues. Probably, these changes represent disruption of cellular processes due to persistent damage of the nucleus. A reduced ability of the damaged tissues to differentiate and produce contractile cells probably explains the reduced contraction of induced skin ulcers [19].

In general, similar wound healing of histological pattern was observed with the treatment by 10, 20, and 30 mg zinc sulphate or the control groups on the 7th day of experiment an inflammatory process was observed, presenting congestion, necrosis, inflammatory cells, some collagen deposition and discrete epithelialisation, fibrin-leukocyte crusts were present in all studied groups.

The outcome of histopathological analysis of this study showed that the intensity of the above parameters was likely similar, may be the small difference observed between them, this is compatible with the study which showed that readily water soluble zinc sulphate had no or even deleterious effect on wound healing [20].

Evaluation of the histological parameters for the induced ulcer by 50 mg aspirin group, then treated with 30 mg zinc sulphate compared to its control, showed that both groups have similar profile in wound healing process, fibrin-leukocyte crusts observed in both groups, inflammatory cell infiltration, new blood vessel formation, necrosis present, with absence of epithelium. The outcome of this finding is that 30 mg zinc sulphate does not enhance healing, in accordance with the Agren, *et al* results as previously discussed. Histopathological assessment of the induced ulcer by 10 mg Nicorandil and treated with 30 mg Zinc sulphate group; showed similar picture of histopathological events, which include; absence of epithelialisation, discrete congestion, moderate inflammation, discrete necrosis, and discrete collagen deposition. The outcome of histopathological analysis of this study showed that the intensity of the above parameters was likely similar, may be the small difference were found between them, this study is compatible with the study which reported that readily water soluble zinc sulphate had no or even deleterious effect on wound healing [20]. Microscopical appearance of the three different methods reported that untreated group (control; induced ulcer by excision) showed discrete epithelialisation. While untreated group (ulcer induced by 50 mg Aspirin) and

untreated group (ulcer induced by 10 mg Nicorandil) group showed absence epithelialisation. Comparing the three different methods of ulcer induction showed that group of excision only, starts re-epithelialisation and collagen proliferation earlier than those groups, which were induced by either 50 mg Aspirin, or 10 mg Nicorandil. Also the intensity of inflammation was more in the group with induced ulcer by Aspirin or Nicorandil than the group with excision ulcer; this result showed that Aspirin and Nicorandil delayed healing. When comparing the wound healing process of the induced lesion by the three methods studied, it was observed that, despite having similar profiles as described above, they differ on the intensity and speed of occurrence of the two phases of lesion healing. From microscopical appearance and histopathology study of the three methods of ulcer induction, it showed that both Aspirin and Nicorandil delayed healing process as explained by; first, through preventing epithelialisation. Second, the amount of collagen deposition and proliferation of collagen in the induced ulcer by 50 mg, or by 10 mg Nicorandil groups were less if compared to the group with induced ulcer by excision. Third, the intensity of inflammation, inflammatory cell infiltration was more and intense in the groups with ulcer induced by Aspirin or by Nicorandil than the group with ulcer induced by excision. This finding agrees with the reports of Nicorandil inducing ulceration, a number of reports have linked its use with oral, anal, vulval and parastomal ulceration, it also include anal fistulation, fistula between nasolabial fold, colorectal, ileal, peristomal, foreskin, and genital ulceration like penile ulcerations [7, 21-25]. This is the first study of using topical Nicorandil for the induction of skin ulcer in rabbits.

Local wound infection and foreign bodies affect healing by prolonging the inflammatory phase. Wound contamination in association with tissue hypoxia potentially suppresses macrophage-regulated fibroblast proliferation [26]. This study agrees with that, which may explain the findings of this study.

This study disagree with the study that showed the topical application of NSAIDs on the surfaces of chronic wounds, which provides moist wound healing, reduces persistent and temporary wound pain, and benefits chronic venous leg ulcer healing [27].

The acute inflammation during the early stages of wound healing generates factors that are essential for tissue repair, but a prolonged inflammatory phase may lead to cell destruction and altered composition of the extracellular matrix with subsequent failure of epithelialisation [28-30]. The complexity of wound healing makes it vulnerable to interruption at any stage. Factors that affect physiologic responses and cellular function can potentially affects the wound healing process. Several local factors can greatly influence the wound healing process; wounds with foreign bodies, infection, contamination, and ischemic tissue, will all impair or delay the wound healing progress [31], for these reasons the induced ulcer by 50 mg Aspirin or 10 mg

Nicorandil showed delay in the healing process, compared to the group with induced ulcer by excision only.

Oral ulceration is known to occur with aspirin like; chemical burn, if left to dissolve whilst in contact with the oral mucosa, [32]. Excision wounds can be covered with occlusive dressings, which retain the exudate (wound fluid) as a means of assessing the status of various soluble factors in the wound environment, such as nutrients, proteinases, cytokines, and tissue degradation products [33]. This explains how the excision with dressing group started healing faster than those groups with chemical contact (50 mg Aspirin or 10 mg Nicorandil).

TGF- β is an essential cytokine needed for the initiation of inflammation as well as the formation of granulation tissue, and collagen formation; it influenced re-epithelisation in wound-healing process [34, 35, 2]. TGF- β 1 deficient mice showed an impaired wound repair with a deceleration in the re-epithelialisation process. Fibroblasts exposed to longer periods of hypoxia may not participate in the formation of the extracellular matrix, thus delaying the healing process [36]. It had also been reported, to encourage wound contraction through its direct induction of alpha smooth muscle actin expression in fibroblasts [37]. The controversial data on the effects of TGF- β 1 on cutaneous wound healing may reflect the complex nature of biological functions of TGF- β 1, which may be cell type and context specific. As keratinocytes are one of the major sources of TGF- β 1 after cutaneous injury [34].

In the present study, serum level of TGF- β showed notable elevation in those groups which were treated by local application of 10, or 20, or 30 mg Zinc sulphate, but their controls showed mild increase in the cytokine serum levels, when compared to the baseline, it showed that the treated group with 10 mg zinc sulphate showed no change in the serum level of TGF- β at the end of experiment, but no significant difference was seen between the four groups, depending on this finding, serum level of TGF- β does not respond to the different concentrations of zinc sulphate.

Serum levels of TGF- β for the induced ulcer by 50 mg Aspirin group, and treated with 30 mg zinc sulphate compared to the untreated one showed noticeable reduction, but no statistical significant change was seen, this rationalise no effectiveness of zinc sulphate on ulcers induced by Aspirin.

For the groups with induced ulcer by 10 mg Nicorandil, serum levels of TGF- β were reduced in both treated and untreated groups, but no statistical significant change was found between them. This result disagree with the study which show that zinc supplementation has been reported to induce the expression of TGF- β *in vitro*, and therefore, TGF- β 1 is essential for the healing process [38], this is may be as a result of the pharmaceutical dosage form and routes of administration.

Comparing the three methods of ulcer induction, the group with induced ulcer by 50 mg Aspirin showed notable reduction in the serum levels of TGF- β , while the group with

induced ulcer by 10 mg Nicorandil showed very slight reduction in the serum levels of TGF- β , but their control showed slight increase in this cytokine levels. But there was no statistical significant difference between them.

Although animal wound repair is an imperfect reflection of human wound healing and its clinical challenges, these models continue to be crucial tools for the development of new strategies and approaches to rational wound therapy.

References

- [1] Yao C, Li A, Gao W, Pallua N, Steffens G. Topical Stem and Progenitor Cell Therapy for Diabetic Foot Ulcers. *Int J Burns Traum*; 1(1): 1726. 2011.
- [2] El Gazeerly H, Elbardisey DM, Eltokhy HM, Teaama D. Effect of Transforming Growth Factor Beta 1 on Wound Healing in Induced Diabetic Rats. *Int J Health Sci*; 7 (2): 160–172. 2013.
- [3] Lev-Tov H, Li CS, Dahle S, Isseroff RR. Cellular versus acellular matrix devices intreatment of diabetic foot ulcers: study protocol for a comparative efficacy randomized controlled trial. *Trials*, 14: 8. 2013.
- [4] Han C, Bowen WC, Li G, Demetris AJ, Michalopoulos GK, Wu T (2010). Cytosolic Phospholipase A2 α and PPAR- γ Signaling Pathway Counteracts TGF- β -mediated Inhibition of Primary and Transformed Hepatocyte Growth. *Hepatology*; 52(2): 644–655. 2010
- [5] Navin K, Kapur MD. Transforming Growth Factor- β Governing the Transition From Inflammation to Fibrosis in Heart Failure With Preserved Left Ventricular Function. *Circulation*; 4: 5-7 doi: 10.1161/CIRCHEARTFAILURE.110.960054. 2011.
- [6] Velnar T, Bailey T, Smrkolj V. The wound healing process: an overview of the cellular and molecular mechanisms. *J Int Med Res*; 37 (5): 1528-1542. 2009.
- [7] Ciantar M, Gibson J. Nicorandil-induced oral ulceration. *Malta Med J*; 20 (1): 30. 2008.
- [8] Riechert S, Antunes A, Trechot P, Barbaud A, Weber M, Schmutz JL. Major aphthous stomatitis induced by Nicorandil. *Eur J Dermatol*; 7: 132. 1997.
- [9] Cribier B, Marquart-Elbaz C, Lipsker D, Alt M, Grosshans E. Chronic buccal ulceration induced by nicorandil. *Br J Dermatol*; 138: 372–373. 1998.
- [10] Shorts RH, Scully C, Avery CM, Porter SR. Nicorandil induced severe oral ulceration. *Oral Surg Oral Med Oral Pathol Oral Radiol Endod*; 87: 706–707. 1999.
- [11] Marquart-Elbaz C, Lipsker D, Grosshans B, Cribier B. Prevalence and clinicopathological features of nicorandil-induced oral ulceration. *Ann Dermatol*; 125(3): 317. 1998.
- [12] Berger A. Science Commentary: What does zinc do? *Br Med J*; 325: 1062-1063. 2002.
- [13] Diegelmann RF, Evans MC. Wound healing: an overview of acute, fibrotic and delayed healing. *Front Biosci*; 9: 283-289. 2004.

- [14] Paddock HN, Schultz GS, Mast BA. Methods in reepithelialization. A porcine model of partial-thickness wounds. *Methods Mol Med* 78: 17-36. 2003.
- [15] Mehdi pour M, Zenouz AT, Bahramian A, Yazdani J, Pouralibaba F, and Sadr K. Comparison of the Effect of Mouthwashes with and without Zinc and Fluocinolone on the Healing Process of Erosive Oral Lichen Planus. *J Dent Res*; 4(1): 25–28. 2010.
- [16] Sardari K, Ehsan Kakhki G, Mohri M. Evaluation of wound contraction and epithelialization after subcutaneous administration of TheraNekron® in cows. *Comp Clin Pathol*; 16:197–200. 2007.
- [17] Gal P, Kilik R, Mokry M, Vidinsky B, Vasilenko T, Mozes S, *et al.* Simple method of open skin wound healing model in corticosteroid-treated and diabetic rats: standardization of semi-quantitative and quantitative histological assessments. *Vet Med*; 53 (12): 652–659. 2008.
- [18] Shen Y. Plasminogen: A novel inflammatory regulator that promotes wound healing. ISBN: 978-91-7459-652-6. 2013.
- [19] Adam J. Singer, MD, Richard AF, Clark MD. Cutaneous wound healing. *NJEM*; 341 Number 10: 738- 746. 1999.
- [20] Agren MS, Chvapil M, Franze'n L. Enhancement of re-epithelialization with topical zinc oxide in porcine partial-thickness wounds. *J Surg Res*; 50: 101–5. 1991.
- [21] Bhatti I, Cohen SN, Bleiker T, Lund J, Tierney G. Nicorandil-induced foreskin ulceration. *Case Rep*; 11: 424–425. 2009.
- [22] Guo S, DiPietro. Factors Affecting Wound Healing. *J Dent Res*, 89(3): 219–229. 2010.
- [23] Malde S, Wilson A. Rectal ulceration caused by the anti-anginal nicorandil: Case report of a preventable complication. *Patient Saf Surg*, 4: 10. 2010.
- [24] McDaid J, Reichl C, Hamzah I, Fitter S, Harbach L, Savage AP. Diverticular fistulation is associated with nicorandil usage. *Ann R Coll Surg Engl*; 92 (6): 463–465. 2010.
- [25] Yap T, Philippou P, Perry M, Lam W, Corbishley C, Watkin N. Nicorandil-induced penile ulcerations: a case series. *BJUI*; 107(2): 268–271. 2011.
- [26] Bankey P, Fiegel V, Singh R, Knighton D, Cerra F. Hypoxia and endotoxin induce macrophage-mediated suppression of fibroblast proliferation. *J Trauma*; 29(7): 972-9. 1989.
- [27] Guo S, DiPietro. Factors Affecting Wound Healing. *J Dent Res*, 89(3): 219–229. 2010.
- [28] Cotran RS, Kumar V, Robbins SL, Schoen FJ. eds Robbins Pathologic Basis of Disease. Philadelphia, PA: WB Saunders; PP. 35-92. 1994.
- [29] Eming SA, Werner S, Bugnon P, Wickenhauser C, Siewe L, Utermöhlen O, *et al.* Accelerated wound closure in mice deficient for interleukin-10. *Am J Pathol*; 170 (1): 188-202. 2007.
- [30] Gutiérrez-Fernández A, Inada M, Balbín M, Fueyo A, Pitiot AS, Astudillo A, *et al.* Increased inflammation delays wound healing in mice deficient in collagenase-2 (MMP-8). *FASEB J*; 21(10): 2580-91. 2007.
- [31] Joshua S. Boateng, Kerr H. Matthews, Howard N.E. Stevens, Gillian M. Eccleston. Wound Healing Dressings and Drug Delivery Systems: A Review. Wiley InterScience. Journal of pharmaceutical sciences, VOL. 97, NO. 8, 2008. DOI 10.1002/jps.21210.
- [32] Altaei T. Topical lavender oil for the treatment of recurrent aphthous ulceration. *Am J Dent*; 25: 39-43. 2012.
- [33] Davidson J M. Animal models for wound repair. *Arch Dermatol Res*; 290 (Suppl): S1–S11. 1998.
- [34] Wang XJ, Han G, Owens P, Siddiqui Y, Li AG. Role of TGF β mediated inflammation in cutaneous wound healing. *J Invest Dermatol Symp Proc*; 11: 112–117. 2006.
- [35] Werner S, Krieg T, Smola H. Keratinocyte-fibroblast interactions in wound healing. *J Invest Dermatol*; 127(5): 998–1008. 2007.
- [36] Steinbrech DS, Longaker MT, Mehrara BJ, Saadeh PB, Chin GS, Gerrets RP, *et al.* Fibroblast response to hypoxia: The relationship between angiogenesis and matrix regulation. *J Surg Res*; 84: 127. 1999.
- [37] Desmouliere A, Geinoz A, Gabbiani F, Gabbiani G (1993). Transforming growth factor- β 1 induces α smooth muscle actin expression in granulation tissue myofibroblasts and in quiescent and growing cultured fibroblasts. *J Cell Biol*; 122 (1): 103–111.
- [38] Estai MA, Suhaimi F, Das S, Shuid AN, Mohamed Z, Soelaiman I-N. Expression of TGF- β 1 in the blood during fracture repair in an estrogen-deficient rat model. *Clinics*; 66 (12): 1807-5932. 2011.