



Case Report

A Case of a Child with Stroke and Severe Hypertension Due to Vasculopathy in Neurofibromatosis Type I

Kusa K.¹, Rozsival P.¹, Melek J.¹, Lukeš A.², Štefáčková Š.³, Albahri Z.^{1,*}

¹Department of Pediatrics, Faculty Hospital, Charles University in Hradec Králové, Hradec Králové, Czech Republic

²Pediatric Cardiology, Faculty Hospital, Charles University in Hradec Králové, Hradec Králové, Czech Republic

³Pediatric Neurology, Faculty Hospital, Charles University in Hradec Králové, Hradec Králové, Czech Republic

Email address:

marziadmar@seznam.cz (Albahri Z.)

*Corresponding author

To cite this article:

Kusa K., Rozsival P., Melek J., Lukeš A., Štefáčková Š., Albahri Z. A Case of a Child with Stroke and Severe Hypertension Due to Vasculopathy in Neurofibromatosis Type I. *American Journal of Pediatrics*. Vol. 3, No. 1, 2017, pp. 1-3. doi: 10.11648/j.ajp.20170301.11

Received: September 14, 2016; **Accepted:** October 12, 2016; **Published:** March 17, 2017

Abstract: Ischemic stroke is an infrequent disease of pediatric patients. We report a case of 2 year old child with neurofibromatosis, who had acute hemiplegia and severe hypertension (required artery angioplasty) due to both cerebral vascular disease and renal artery stenosis.

Keywords: Neurofibromatosis, Vasculopathy, Stroke, Renovascular Stenosis

1. Introduction

Neurofibromatosis type 1 (NF1) is an autosomal-dominant, multisystemic neurocutaneous disorder with an incidence of approximately 1 in 2600 to 3000 individuals [1], characterized by cutaneous findings, most notably café-au-lait spots, skeletal dysplasias, plexiform neurofibromas, optic nerve and central nervous system gliomas, malignant peripheral nerve sheath tumors, and vasculopathy. It is caused by a mutation of a gene which encodes a protein known as neurofibromin, localised on the long arm of chromosome 17 [2].

Vasculopathies are the most important cause of morbidity and mortality in children and young adults afflicted with NF1. A characteristic NF1 vasculopathy of arteries of all sizes can cause arterial stenosis, occlusion, aneurysm, pseudoaneurysm, rupture, or arteriovenous fistula formation and may occur almost anywhere in the body. Cerebral vasculopathy (CV) is an important but under-recognized complication of NF1, CV have been reported in 2 to 6% of children with NF1 who underwent neuroimaging, most patients were asymptomatic [3, 4].

The prevalence of systemic hypertension in children is estimated to be 2% to 5% [5], a secondary cause of

hypertension is most likely to be found before puberty; after puberty, hypertension is likely to be essential. Secondary hypertension is more common in children compared with adults who predominantly have primary hypertension. Endocrine conditions associated with hypertension include: iatrogenic steroid use for various conditions and catecholamine producing tumors (pheochromocytoma), corticoid hormone disorders (Cushing's syndrome and disease, hyperaldosteronism, congenital adrenal hyperplasia), and hyperthyroidism. Cardiovascular disorders like coarctation of the aorta are less frequent cause of hypertension in children.

Renal conditions are the commonest cause of secondary hypertension in children; it is responsible for 5–25% of paediatric hypertension cases, and include renal parenchymal disease and renal vascular stenosis. Renal artery stenosis may occur in association with NF 1, Fibromuscular dysplasia, Takayasu arteritis, middle aortic syndrome, Williams syndrome, Ehlers-Danlos syndrome, congenital aneurysms, Kawasaki syndrome, Crohn's disease and polyarteritis nodosa. Renovascular hypertension is responsible for 3.0% to 8.5% of pediatric hypertension [6, 7].

2. Case Report

A 2 year-old female child was admitted to our hospital with complaints of weakness over right upper limb for 2 days. There was no history of fever, convulsion, head injury or tick bite. Early infancy was uneventful with normal development.

A clinical examination revealed no signs of meningeal irritation, gait and tone was normal, multiple café au lait spots over the trunk, all other systems were found to be normal. Her mother had Café-au-lait spots with neurofibroma-like lesions and no other abnormalities.

Laboratory parameters including cerebrospinal fluid analysis, hematological examination, renal and liver function tests, and urine examination were within normal limits.

MRI of the brain revealed an left side acute ischemic stroke of the frontal lobe and periventricular white matter (Fig. 1A). The patient was treated with anticoagulation medication.

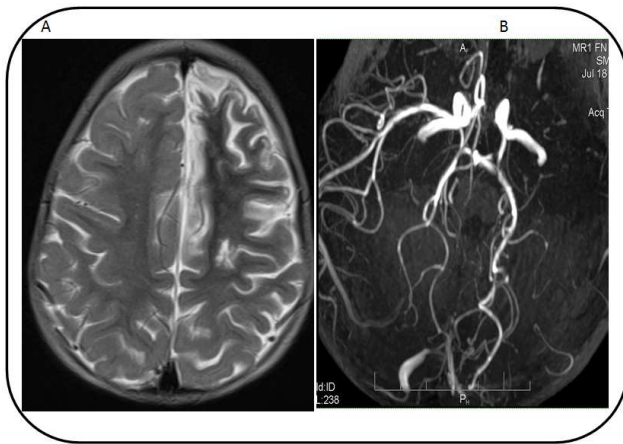


Fig. 1. Brain MR imaging(A: Left side acute ischemic strokeB: Brain angiography:cerebral arteries stenosis).

After 3 days of admission, she was found to have severe hypertension (200/100 mmHg), an echocardiogram demonstrated normal structure of the heart with mild left ventricular hypertrophy. Ocular fundus with normal findings, US of the abdomen was normal; both kidneys were of normal size.

Antihypertensive (AH) treatment was ineffective, decrease of 25% of blood pressure was achieved by a 3 combination of AH, treatment that included 4 agents of AH (ACE inhibitors, Calcium channel blockers, Alpha-2 adrenergic receptor agonists and vasodilator) was needed to control blood pressure in our patient.

Brain MRI angiography showed a carotid artery stenosis, multiple stenoses of the proximal parts of the left MCA, ACA and PCA (Fig. 1A), narrowing of abdominal aorta and its parts between coeliac and mesenteric arteries, including right renal artery (Fig. 2).

Asymmetrical renal size and suspected arteriovenous malformations of right brachial artery were documented.

Vasography examination showed unidentified left renal artery, double accessory right renal arteries were identified with a 70% stenosis of the caudal branch, which was treated

by balloon dilatation. There after, the patient improved with decrease of the blood pressure to upper limits of normal levels. The Patient underwent consecutive periods of rehabilitation.

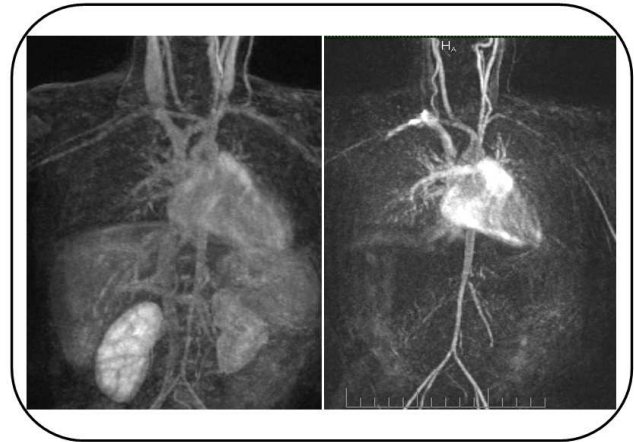


Fig. 2. Abdominal MR imaging and Abdominal MRI angiography.

3. Discussion

Clinical diagnosis of NF1 requires the presence of at least 2 of 7 criteria to confirm the presence of NF1. The 7 clinical criteria used to diagnose NF1 are as follows: 1) Six or more café-au-lait spots or hyperpigmented macules ≥ 5 mm in diameter in prepubertal children and 15 mm postpubertal. 2) Axillary or inguinal freckles. 3) Two or more typical neurofibromas or one plexiform neurofibroma. 4) Optic nerve glioma. 5) Two or more iris hamartomas (Lisch nodules), often identified only through slit-lamp examination by an ophthalmologist. 6) Sphenoid dysplasia or typical long-bone abnormalities such as pseudoarthrosis. 7) First-degree relative with NF1 [2]. Our patient was suspected to have NF1, her mother had Café-au-lait spots and neurofibroma-like lesions with no other abnormalities. She first presented with stroke due to CNS vasculopathies. In one study of a total of 279 patients with NF1, the mean age at diagnosis was 3.4 years. 99% of the patients had café au lait spots and 47% had a first degree relative with NF-1, 60% had Lisch nodules, optic glioma was found in 14.7%, cutaneous neurofibromas in 38.4%, plexiform neurofibromas in 24.7%, neurofibrosarcoma in 1.8%, learning disabilities in 39%, attention deficit disorder in 40.5%, osseous dysplasias in 7.2%, pseudoarthrosis in 3.6% [8]. Up to 15% of the normal population has one to three café-au-lait macules, however, the presence of six or more café-au-lait macules is highly suggestive of NF1 [9]. NF1 is presumed to result from loss-of-function mutations. We presented before a rare case of a 10 month old male infant, who was first seen with peripheral facial paralysis as the first symptom of malignant hypertension due to renal artery stenosis, the patient with NF1 [10].

More than 500 different mutations of the NF1 gene have been identified. Genetic analysis for mutation detection in our patient and her mother is under assessment.

Hypertension is present in 1% of NF1 patients and is significantly associated with mortality and morbidity [11]. Our patient had a severe hypertension resistant to antihypertensive medication, it was treated with a combination of 4 agent hypertensive drugs, the child was found to have unilateral proximal renal artery stenosis, balloon dilatation without stenting was performed and it was successful in hypertension management to this date. The prevalence of vascular lesions in NF1 is 0.4% to 6.4% [12, 13]. The renal artery is the most frequent site of involvement with a prevalence of 41% of all vascular abnormalities, of which 68% are unilateral [12]. Pediatric renovascular hypertension is often associated with extra-renal vascular anomalies, the most important in the abdomen being abdominal aortic stenosis, associated with mesenteric arterial narrowing and cerebrovascular disease. Additional to RAS, abdominal aortic coarctation, internal carotid and cerebral arteries stenosis were also presented in our patient. Stroke was the first presentation that leads to the initial diagnosis of NF1 in this child.

Midaortic syndrome (MAS), which is characterized by stenosis of abdominal aorta and its major branches, is an important cause of pediatric renovascular hypertension. Renovascular hypertension patients with MAS are often refractory to antihypertensive medications. Our patient needed 4 agents AH and balloon dilatation to control the severe hypertension. König et al. [14] reported that maximum doses of six antihypertensive drugs failed to achieve successful blood pressure control in two children with MAS, who eventually underwent percutaneous transluminal renal angioplasty (PTRA) with 1–3 stents.

Treatment modalities in renovascular hypertension secondary to NF1 involve a combination of drug therapy, PTRA, and surgery. Up to two-thirds of children will remain on antihypertensive medication after PTRA, stenting has been used for recurrent lesions in children and to manage iatrogenic dissection. Re-stenosis occurs in 20-34% of patients, but repeated PTRA produces significant benefit [7], the long-term behaviour of stents in children is not known [15].

4. Conclusion

Vasculopathy of NF1 tends to be progressive and is one of the leading causes of death in this population. NF1 should be considered in patients with multiple café au lait spots and acute neurological manifestations. Hypertension refractory to antihypertensive medications due to RAS in NF1 patients could be referred to MAS and may be required balloon dilatation, stenting procedures or angioplasty.

References

- [1] Lammert M, Friedman JM, Kluwe L, Mautner VF. Prevalence of neurofibromatosis 1 in German children at elementary school enrollment. *Arch Dermatol* 2005; 141: 71.
- [2] Friedman JM. Neurofibromatosis 1. GeneReviews® [Internet]. <http://www.ncbi.nlm.nih.gov/books/NBK1109/>.
- [3] Rea D, Brandsema JF, Armstrong D, et al. Cerebral arteriopathy in children with neurofibromatosis type 1. *Pediatrics* 2009; 124: e476.
- [4] Cairns AG, North KN. Cerebrovascular dysplasia in neurofibromatosis type 1. *J Neurol Neurosurg Psychiatry* 2008; 79: 1165.
- [5] McNiece KL, Poffenbarger TS, Turner JL, Franco KD, Sorof JM, et al. Prevalence of hypertension and pre-hypertension among adolescents. *J Pediatr* 2007; 150: 640-644.
- [6] Hiner LB, Falkner B. Renovascular hypertension in children. *Pediatr Clin North Am.* 1993; 40: 123-140.
- [7] Stanley JC, Criado E, Upchurch Jr GR, Brophy PD, Cho KJ, Rectenwald JE. Pediatric renovascular hypertension: 132 primary and 30 secondary operations in 97 children. *J Vasc Surg.* 2006; 44: 1219-1229.
- [8] Boulanger JM1, Larbrisseau A. Neurofibromatosis type 1 in a pediatric population: Ste-Justine's experience. *Can J Neurol Sci.* 2005; 32 (2): 225-231.
- [9] Tekin M, Bodurtha JN, Riccardi VM. Café au lait spots: the pediatrician's perspective. *Pediatr Rev.* 2001; 22 (3): 82-90.
- [10] Albahri Z, Lukeš A And Rozsival P. Peripheral facial paralysis in an infant with malignant hypertension and suspected neurofibromatosis disease. *Journal of the Neurological Science.* 2015; (357): 1: 172–e173.
- [11] Malav IC, Kothari SS. Renal artery stenosis due to neurofibromatosis. *Ann Pediatr Cardiol.* 2009; 2: 167-169.
- [12] A. E. Lin, P. Birch, B. R. Korf, R. Tenconi, M. Niimura, M. Poyhonen, et al. Cardiovascular malformations and other cardiovascular abnormalities in Neurofibromatosis type I. *Am J Med Genet.* 2000; 95: 108-117.
- [13] Friedman J. M., J. Arbiser, J. A. Epstein, D. H. Gutman, S. Huot, A. E. Lin, et al. Cardiovascular disease in neurofibromatosis 1: report of the NF1 cardiovascular task force *Genet Med* 2002; 4: 105-111.
- [14] König K, Gellermann J, Querfeld U, Schneider MB. Treatment of severe renal artery stenosis by percutaneous transluminal renal angioplasty and stent implantation: review of the pediatric experience: apropos of two cases. *Pediatr Nephrol.* 2006; 21: 663-671.
- [15] Meyers KE1, Cahill AM, Sethna C. Interventions for pediatric renovascular hypertension. *Curr Hypertens Rep.* 2014; 16 (4): 422.