

Case Report

Clinical Characteristics and Report of Seven Iranian Neonates Born to Mothers with Covid-19

Farhad Abolhasan Choobdar¹, Maral Ghassemzadeh^{2, *}, Ezzat Abbariki², Mohammad Attarian²

¹Department of Neonatology, Ali Asghar Children's Hospital, Iran University of Medical Sciences, Tehran, Iran

²Department of Neonatology, Firuzgar Hospital, Iran University of Medical Sciences, Tehran, Iran

Email address:

drchoobdar@gmail.com (F. A. Choobdar), maral.ghassemzadeh1985@gmail.com (M. Ghassemzadeh),

ezzatt.abbariki@yahoo.com (E. Abbariki), attarian.444@gmail.com (M. Attarian)

*Corresponding author

To cite this article:

Farhad Abolhasan Choobdar, Maral Ghassemzadeh, Ezzat Abbariki, Mohammad Attarian. Clinical Characteristics and Report of Seven Iranian Neonates Born to Mothers with Covid-19. *American Journal of Pediatrics*. Vol. 6, No. 3, 2020, pp. 303-311. doi: 10.11648/j.ajp.20200603.32

Received: June 17, 2020; Accepted: July 14, 2020; Published: August 4, 2020

Abstract: The outbreak of Covid-19 infection is an actual public health challenge. Iran is fighting hard against the virus outbreak. Although at first it seemed that the disease does not affect infants and the neonates, But the population of affected infants and neonates appears to be increasing. This article is written to share some of the experiences about encountering with neonates born to mothers with covid-19. It describes the maternal, perinatal and neonatal aspects of the disease in seven Iranian cases. It also explains the outcome of delivery and follow up of mothers and their neonates after they discharged from hospital. According to our vague and incomplete knowledge about this novel disease and also hazardous side effects of its specific drugs which are not fully evaluated in neonatal population, in this article we just emphasize on routine and supportive care and avoiding unconventional therapy. In this case series we manage our patients according to their disease such as pneumonia, transient tachypnea of neonates or respiratory distress syndrome by using antibiotics, total parenteral nutrition and supplementary oxygen therapy with the preference of non-invasive methods. We didn't use any novel treatment for Covid-19 disease. We also carefully considered isolation and personal protection issues.

Keywords: Covid-19, Neonates, Mothers, Clinical Characteristics

1. Introduction

1.1. Covid-19 Outbreak

In December 2015 Menachery et al. published an article in which they inspirationally predicted the future treat of Sever acute respiratory syndrome coronavirus (SARS-CoV). They also mentioned that this virus was circulating in Chinese horseshoe bat population in that time [1]. They tried to warn scientific societies of the virus efficacious replication in human airway cells [2].

China is the earliest country to report novel coronavirus [3]. As predicted by Menachery through December 2019, sporadic cases in adults from the beautiful city of Wuhan in the Hubei province in central china, developed sever respiratory symptoms. Results from initial investigation showed that most

of the infected patients had been exposed at the Hunan wholesale seafood market and from that point pneumonia caused by novel sever acute respiratory syndrome (SARS-Cov2) appeared in Wuhan. The outbreak was reported by china to WHO on December 31 and WHO announced a pandemic state of coronavirus disease2019 (covid19), caused by SARS-Cov2 [4].

At the writing time of this article there were 6,087,409 confirmed cases globally, with the mortality rate ranged from 6 to 10 percent. The mortality rate of SARS-CoV-2 infection in pregnant women reported as 25 percent [3, 5]. Studies showed that all of the age groups are at risk of this infection, and the severity of disease is associated with comorbidities and age [4]. The fast spread of 2019 novel coronavirus treat the whole world as a new and mysterious public health catastrophe.

SARS-CoV-2 is the member of the large coronavirus family, that can bring a various range of infections from a simple common cold to severe acute respiratory syndrome in human, other mammals and birds. coronaviruses are enveloped and largest single stranded RNA viruses, with a crown like figure under the electron microscope that are able to invade multiple organs such as respiratory and neurologic system as well as liver and gastrointestinal system [6].

The incubation period of COVID-19 is 2 days to 2 weeks. The main way of transmission is respiratory droplets and close contact. The presentation of the disease is variable in both intensity and feature. Ranging from mild coryza to diarrhea, high grade fever, dyspnea and even death [11].

1.2. Perinatal and Neonatal Aspect of Covid-19

It is wisely to consider pregnancy as an immunocompromised state. Some studies showed that Adverse outcomes of COVID-19 in pregnant women are more than non-pregnant ones. The risk of developing any kind of viral infection is higher in pregnant women. These infections including COVID-19 may cause variety of complications such as maternal mortality, spontaneous abortion, preterm labor and still birth [9, 10]. Although some other studies such as Chen's study revealed that clinical characteristics of COVID19 pneumonia in pregnant women are similar to non-pregnant patients. However, it would be valuable to specify whether conditions such as diabetes, hypertension or renal and hepatic insults which are considered as COVID19 risk factors in non-pregnant population, can also act as an additional risk factors for pregnant population [12].

According to the first published case series of 19 pregnant women with clinical symptoms of COVID-19 in china, the virus was not detected in amniotic fluid or in the neonatal blood taken from the umbilical cord [7]. Initial studies revealed no morphological changes in placenta of pregnant women infected with COVID-19 and there was no footprint of viral infection in their placental tissue [8].

By our current knowledge about COVID-19, Its very difficult to determine that there is vertical transmission of SARS CoV2 during pregnancy or not. But gathering the results of different studies together, we can conservatively conclude that vertical transmission from maternal infection during the third trimester is almost impossible or if any, it should be very rare. About maternal infection during early pregnancy, our information is even more unclear [2].

About the risks of SARS-CoV-2 infection in neonates, some case series are published. The data about risk of prematurity and severe sepsis or pneumonia is also unclear. It is difficult to determine if these complications are related to the routine course of neonatal prematurity or common septic condition or CoVid-19. Some neonates without any respiratory symptoms had positive viral results and vice versa. It seems that repeating PCR tests may be helpful to get results which are comparable with clinical and serological status of suspected neonates [13-15].

Similarly, there are studies about transmission of SARS-CoV-2 through human milk, in which human milk

samples were collected and tested for SARS-CoV-2. Although the samples were negative for virus, not the sample size nor the study design were suitable enough to make definite conclusion about this matter [16].

2. Materials and Methods

Here, we presented a report from seven neonates who born to mothers infected with Covid-19 and positive for CoVID-19 PCR. All the neonates who born to infected mothers between February 20 and May 21, 2020 and who were admitted in NICU wards at two hospitals which are Iran University of medical sciences subset (Firuzgar and Lolagar hospitals) were included in this study. The diagnosis of mothers was initially begun according to clinical symptoms (fever and/ or respiratory symptoms, myalgia, anosmia and cough). These clinical presentations should be confirmed by high resolution CT scan evidence of typical viral (covid-19) pneumonia that is bilateral and peripheral ground-glass and consolidative pulmonary opacities. Some laboratory data such as low lymphocyte count ($1100 >$) may help clinicians to make the diagnosis. According to the national guidelines, the definite diagnosis of covid-19 is confirmed by reverse-transcription polymerase chain reaction (RT-PCR) test from oropharyngeal and nasopharyngeal swab samples and detection of lesion by chest CT scan. However according to the experience of fellow Chinese, chest CT-scan had a sensitivity of 97% for diagnosis covid-19-even superior to RT-PCR [14-17]. Although there is no specific treatment for covid-19 up to now, respiratory and other supportive care are recommended to manage the cases [17-18].

2.1. Data Collection

The maternal information including epidemiological data, prenatal data, clinical symptoms, laboratory and radiological characteristics was obtained from medical records from patients' files or direct communication with patients through face to face interview considering PPE or through phone call. Maternal throat swab samples were collected and tested for SARS-CoV-2 in laboratory of Firuzgar and Lolagar hospital, Iran University of medical sciences, following WHO guidelines for RT-PCR.

The neonates' information including gender, gestational age, birth weight, clinical symptoms, laboratory and radiologic characteristics was obtained from files and electronic medical records. Neonatal throat and nasopharyngeal swab samples were also collected for testing the presence of SARS-CoV-2. unfortunately, our two centers were not well equipped for testing amniotic fluid, placenta and umbilical cord samples.

2.2. Case Presentations

Case 1:

A girl with 32 weeks' gestational age born on April 18, 2020, via cesarean section. Her Apgar score was 8 in the first minute and 10 in the fifth minute of life. The mother was aged 26 years and she was primigravida. She had cholestasis and rise of

bilirubin during the late phase of pregnancy which was complicated with gestational diabetes that controlled by using insulin. She also had hypertension during pregnancy which was treated by methyldopa. Two days before delivery her respiratory distress started. She had cough, dyspnea and fever accompanied by shaking chills. She returned to an obstetric center in which she was tested for PCR of covid-19 by swab from oropharyngeal and nasopharyngeal area. The test was positive in that center. There after because of severity of her dyspnea she was referred to our center. At that time, she was completely dependent on oxygen with mask. The day after her transfer to our center, her pregnancy was terminated because of cholestasis and sever respiratory distress. Considering the positive PCR test, Covid-19 treatment with kalettra, hydroxychloroquin and methylprednisolone were started for her. After delivery an HRCT also was done for her, which was completely comparable with Covid-19. The mother had ESR as high as 91 mm/hour. LDH was 454 U/L. WBC 4000 /mm³ with lymphopenia (1000/mm³). The diagnosis of maternal Covid19 was made according to clinical manifestation, positive PCR test and positive HRCT findings. Maternal PCR was negative for three times thereafter in our center.

There were no fetal concerns during pregnancy or delivery. Delivery occurred in an isolation room, with total and restrict consideration of PPE. delayed cord clamping was not performed. after delivery, neonate was immediately separated from his mother, and isolated for at least 14 days. After delivery a girl neonate with 2120-gram weight which was appropriate for her gestational age (32 w) was born.

she didn't need advanced resuscitation. Skin to Skin contact was not performed. The neonate was washed 6 hours after delivery. She admitted to NICU isolated room because of mild to moderate tachypnea and mild subcostal retraction. He received supplementary oxygen by NIPPV, with 30 to 40 percent Fio₂ and 6 cm H₂O Peep and PIP about 15 Cm H₂O. Because of her dependency to high fio₂ and peep, she received two course of crosurf and she was under mechanical ventilation for 1.5 days. Then she got extubated and she went under NIPPV for about three days. Her first and second time PCR test form oropharyngeal and nasopharyngeal area was negative during first days of life. Thereafter because of long lasting dependency to oxygen despite getting full BPD and pneumonia treatment with vancomycin and meropenem, and also because of strange pattern of diffuse haziness in CXR, we decided to repeat PCR swab test from oropharyngeal and nasopharyngeal area, which was positive in 23rd day of life. We recommended an HRCT for her which demonstrate peripheral consolidation compatible with covid-19. Because of conjunctivitis and also as an anti-inflammatory treatment of BPD we use azithromycin for 7 days. Her dependency to oxygen was gradually tapered off. she was not critically ill in any phase of her admission. We started premature formula for her in 6th day of life. after the positive result of third PCR, we repeated PCR test for two other times in the same center within 24 hours' interval, which were positive again, then we decided to repeat PCR test in another reliable center for two other times immediately after the last two positive tests. The

result of those two tests in another center was negative. And serological findings also revealed negative IgG and IgM amount.

We concluded that if considering the first two PCR tests in first days of life as true negative, she might get infected by covid-19 through nosocomial way. But we got confused how to analyze paradoxical PCR results in the fourth week of life which was two times positive and two times negative in different laboratory center. If we consider her as a case of nosocomial Covid-19, we can count her in window period because of negative serological findings.

Anyhow, the neonate had negative CRP, and 8900/mm³ WBC with no lymphopenia (3204/mm³), LDH was 1519 U/L, higher than normal range. CSF analysis and blood and urine culture was normal and negative. Neonatal blood group was A+. Finally, after one month of routine pneumonia and BPD treatment and complete weaning of any kind of supplementary oxygen and after two negative PCR tests she discharged from NICU. Her mother third PCR test was negative and after 14 days of neonate's life, she breastfed her neonate. The protocol of isolation of neonate and mother and other family members was explained for the family. Up to writing time, the neonate and his mother are in a good condition and they don't have any problem.

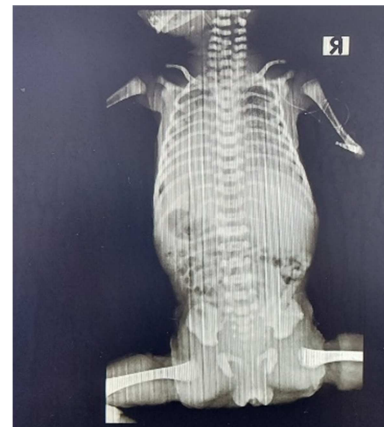

Figure 1. CXR of neonate case 1 shows RDS characteristics

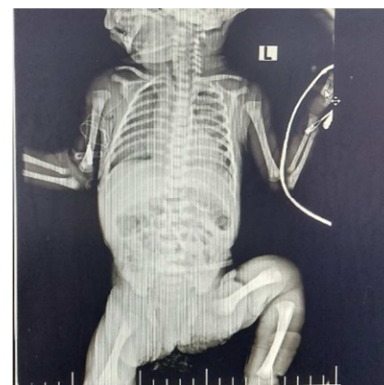


Figure 2. Second CXR of the neonate case 1, 14 days after the first CXR, there are diffuse haziness and reticular infiltration, the third PCR test was positive after this CXR on day 23rd of life.

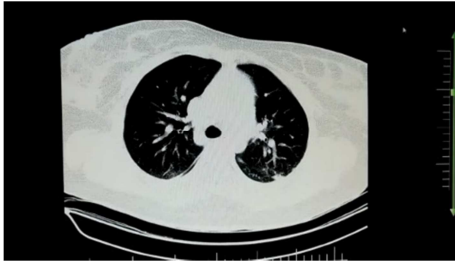


Figure 3. HRCT of mother of case 1,. It seems that CT findings of mother were not as severe as her clinical manifestation.

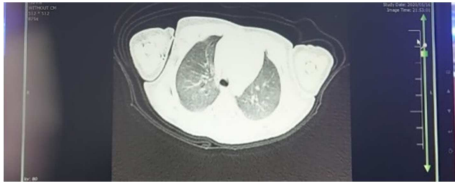


Figure 4. HRCT of neonate case 1 shows diffuse and bilateral ground glass opacities.

Case 2:

A boy with 39 weeks' gestational age born on April 18, 2020 via cesarean section. His Apgar score was 9 in first minute of life and 10 in fifth minute. The mother was aged 32 years, she was G3, P2, L2. And she had gestational diabetes which was controlled with nutritional regimen. She was screened for Covid-19 just because of anosmia. Her PCR test for CoVid-19 and HRCT were both positive and indicative of CoVid-19. After delivery mother presented with fever (38.5) and cough. Her laboratory findings showed total WBC count as $15500/\text{mm}^3$ and lymphopenia ($1085/\text{mm}^3$) and her ESR was 34 mm/hour. Her LDH was 630 U/L she was admitted in covid ward for one week and during admission she was given supplementary oxygen by nasal cannula. She also received Kaletra as Covid-19 treatment for one week. Her blood group was A+. Mother didn't remember any suspicious contact with a person who might have CoVID19. She was tested for Covid-19 with pharyngeal swab just at the time of admission which was positive. Her CT-Scan performed the day after delivery. There were no fetal concerns during pregnancy or delivery. Delivery occurred in an isolation room, with total and restrict consideration of PPE. delayed cord clamping was not performed. after delivery, neonate was immediately separated from his mother, and isolated for at least 14 days. The neonate's weigh was 4170 gr which was large for his gestational age. He didn't need advanced resuscitation. Skin to Skin contact was not performed. The neonate was washed 6 hours after delivery. He admitted to NICU isolated room because of mild to moderate tachypnea and mild subcostal retraction. He received supplementary oxygen by oxyhood for two days. After one day he started feeding with formula and gradually his respiratory distress was disappeared.

Neonatal laboratory data revealed negative CRP, WBC was 15400 with 32.5% lymphocytes. His LDH was 1430 U/L. His Blood culture was negative and CSF analysis was normal. AST and ALT were in normal range but LDH was elevated. His blood group was A+. He received ampicillin and amikacin

for 10 days. He also received calcium gluconate as treatment of hypocalcemia. During his admission phototherapy was used for him. It seems that his clinical and laboratory presentations were compatible with Infant of diabetic mother. Considering TTN (R/O Pneumonia, Hypocalcemia and Jaundice). PCR tests from oropharyngeal and nasopharyngeal specimen were negative for two times. The first was performed during the first day of life and the other one was performed after 24 hours.

He discharged after 10 days receiving antibiotics for his pneumonia. The protocol of isolation of neonate and mother and other family members was explained for the family. Mother was tested two times for PCR after the initial positive test. Both second and third tests of mother were negative and after 14 days she started to breastfed her neonate at home. Up to writing time, the neonate and his mother are in a good condition and they don't have any problem.

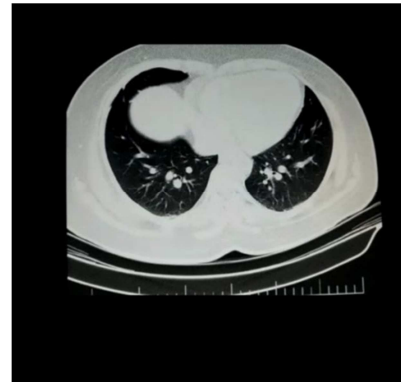

Figure 5. CXR of the neonate case 2, showing diffuse opacification of the lungs.

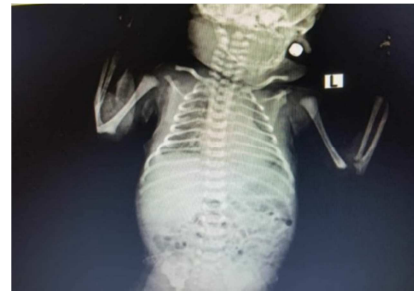

Figure 6. Lung HRCT belonging to mother of neonate case 2, with bilateral peripheral opacities.

Case 3:

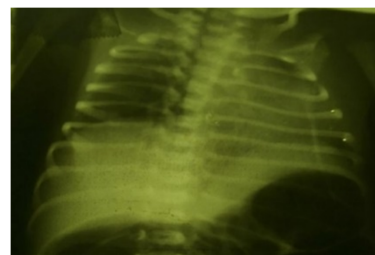


Figure 7. CXR of the neonate case3, which is approximately normal.

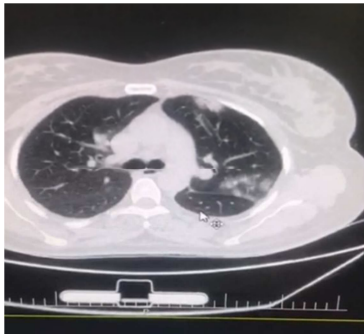


Figure 8. HRCT of the case 3 's mother with peripheral consolidation.

A girl with 36 weeks' gestational age born on April 13, 2020 via cesarean section. Her Apgar score was 9 in first minute and 10 in fifth minute of life. The mother was aged 39 years. She was G4, P3, Ab 1, L 3. She had mitral valve prolapse and she was on propranolol. The pregnancy was terminated because of severe labor pain and deceleration of FHR. After delivery mother's clinical presentation of covid-19 appeared. She became febrile and dyspneic. Her ESR raised up to 95 mm/hour. Mother's WBC was $13000/\text{mm}^3$ without lymphopenia (lymphocyte count: $2400/\text{mm}^3$). Maternal and neonatal blood group was o+. She received Kaletra and hydroxychloroquine for three days at hospital and there after she discharged and continue her treatment for three other days at home, while she and her family were considering isolation protocols. Mother didn't remember any suspicious contact with a person who might have CoVID19. She was tested for Covid-19 with pharyngeal swab just at the time of admission, which was tree days before delivery. HRCT-Scan performed for her the day after delivery. Both PCR and CT-scan were positive for Covid-19. There were no fetal concerns during pregnancy or delivery. Delivery occurred in an isolation room, with total and restrict consideration of PPE. delayed cord clamping was not performed. after delivery, neonate was immediately separated from her mother, and isolated for at least 14 days. The neonate's weigh was 2490 gr which was appropriate for her gestational age. He didn't need advanced resuscitation. Skin to Skin contact was not performed. The neonate was washed 6 hours after delivery. He admitted to NICU isolated room because of hypoglycemia and maternal covid-19. After receiving serum and beginning of sepsis workup, her hypoglycemia was corrected. But she became febrile on third day of life. Lumbar puncture and suprapubic urinary examination were done for her. All of laboratory data including LP and U/a and U/c and CRP were normal. Her WBC count was 8000 with 1600 lymphocytes. Despite normal laboratory findings her fever was persistent and her body temperature became as high as 39.5. Finally, after changing antibiotics from ampicillin and amikacin to vancomycin and cefotaxim, her fever dismissed. Two times PCR tests from her nasopharyngeal and oropharyngeal swab testing were negative. The neonate had normal LDH level and negative blood culture. Her mother was isolated t home until her second and third PCR tests revealed negative results. And there after she was given permission to visit her neonate in NICU ward

and breastfed her neonate (before that the neonate was formula fed). The neonate was discharged from NICU ward after 14 days, with no fever. Up to writing time and according to our follow up, both mother and neonate are healthy.

Case 4:

A girl with 34 weeks' gestational age born on April 7, 2020 via cesarean section. Her first and fifth minute Apgar score was 9 and 10. Her mother aged 35 years old. She was G2, P2, L 2. Mother comes to emergency ward with sever vaginal bleeding, fever and respiratory distress. According to the history which was taken from the mother, she had such presentations including fever and shaking chills, myalgia, dyspnea and cough. She was admitted in Covid ward just one day before delivery and oxygenation with nasal cannula was needed for her to keep the saturation above 90%. Her first PCR testing by swab from nasopharyngeal area was positive and she had ESR level increased up to 65 mm/ hour, although her CRP was negative. Maternal lymphocyte count was $1100/\text{mm}^3$. Her LDH level was more than normal value (850U/L) and her blood group was A-. she was treated with favipiravir, hydroxychloroquine and infliximab. She was admitted in hospital for one week. Her second PCR was negative and she was discharged to home while taking advise to consider isolation protocol for her family and herself.

Mother didn't remember any suspicious contact with a person who might have CoVID19. She was tested for Covid-19 with pharyngeal swab just at the time of admission which was positive. Her CT-Scan performed the day after delivery and was compatible with Covid-19.

There were no fetal concerns during pregnancy or delivery. Delivery occurred in an isolation room, with total and restrict consideration of PPE. delayed cord clamping was not performed. after delivery, neonate was immediately separated from his mother, and isolated for at least 14 days. The neonate's weigh was 2100 gr which was appropriate for his gestational age. He didn't need advanced resuscitation. Skin to Skin contact was not performed. The neonate was washed 6 hours after delivery. He admitted to NICU isolated room because of mild tachypnea which recovered using oxyhood for 2 hours.

The neonate's first CRP was weakly positive and Her CXR revealed haziness in right Para hilar area. Both first and second time PCR tests of the neonate which was taken from oropharyngeal and nasopharyngeal area and her blood culture, were negative. Blood group of the neonate was B-. Her LDH was 370 U/L. Her WBC count was $14700/\text{mm}^3$ and no lymphopenia was detected ($4000/\text{mm}^3$). She also had hypocalcemia which corrected after receiving calcium gluconate. It seems she had congenital pneumonia which was cured by antibiotics (ampicillin and amikacin) and supportive care. The neonate was discharged from NICU ward after 10 days, and she was formula fed from the beginning. with no respiratory distress at the time of discharge. Up to writing time and according to our follow up, both mother and neonate are in good condition.

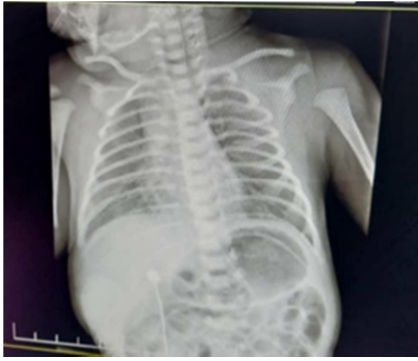

Figure 9. CXR of case number 4 neonate with right para hilar haziness according to pneumonia.

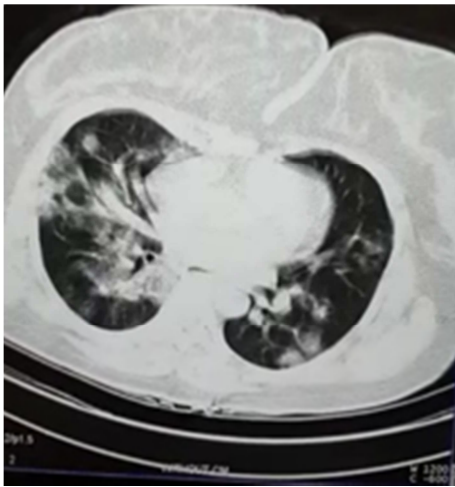

Figure 10. HRCT of the case number 4 neonate's mother with bilateral peripheral consolidation.

Case 5 and 6 (Twins):

these two cases are two boys with 33 weeks' gestational age, born via cesarean section on April 29, 2020 from mother ages 33 years old. The mother was G1, P 2, Ab 0. She had the history of cerclage surgery. The important point in her history was her recovery from Covid 19 infection during pregnancy. In March 4, 2020, approximately 2 months before delivery, the mother's presentations started with fever and respiratory distress. She was admitted in Covid-19 ward of another center in which her PCR test was positive for Covid-19. She also underwent HRCT at that time which was compatible with Covid-19. She got Covid treatment (Hydroxychloroquin and kaletra), She was admitted 4 days at that time and she completed the treatment course thereafter at home for one week. At that time, she didn't have high ESR or LDH, and her lymphocyte count was normal. At the gestational age of 33 weeks her preterm labor pain started and because of uterine insufficiency, the gynecologist forced to terminate the pregnancy. Two boys were born which both of them had 9 and 10 Apgar score in first and fifth minutes of their lives. The first twin was 2250 gram and the second 2100 gram, Both appropriate for gestation age. Maternal blood group was O+, and both of twins were B+. Maternal third and fourth PCR were negative and because of passing almost 2 months from the first and only positive PCR of mother, after documentation

of her two negative PCRs, she got the permission to visit her twins and breastfed them considering wearing mask and washing her hands perfectly.

There were no fetal concerns during pregnancy or delivery. Delivery occurred in an isolation room, with total and restrict consideration of PPE. delayed cord clamping was not performed. after delivery, twins were immediately separated from their mother, and isolated for at least 14 days. They didn't need advanced resuscitation. Skin to Skin contact was not performed. The neonates were washed 6 hours after delivery. They both admitted to NICU isolated room because of mild tachypnea which recovered using low set up NIPPV.

The first twin had WBC count $10600/\text{mm}^3$ with 42% (normal) lymphocyte count. Quantitative CRP was 5.2 and LDH 260 U/L which both were in normal range. The first twin showed late onset sepsis presentation from fourth day of life with hyperglycemia and recurrent prolonged apnea which caused him to become intubated for one day. Full sepsis work up including LP and urinary analysis and culture were done for him. The results of CRP, B/c, CSF and urine analysis and culture were all negative. After changing antibiotics to vancomycin and cefotaxim and amikacin (from ampicillin and amikacin) his condition gradually improved, He received methyl xezantin for apnea and after 14 days he discharged from NICU. He had no fever or respiratory distress during the course of admission. Two PCR tests of this neonate were negative within the 48 hours' interval.

The second twin had feeding intolerance for few days which necessitated CSF and urine analysis to rule out late onset sepsis. He didn't show NEC criteria, and after few days of probable ileus due to late onset sepsis, He started to tolerate feeding. His laboratory tests all were normal including CRP and leukocyte and lymphocyte count. His LDH was 293 U/L and his CRP was 4 (negative) with 10200 WBC and 46% lymphocyte. and after 14 days he discharged from NICU. He had no fever or respiratory distress during the course of admission. Two PCR tests of this neonate were negative within the 48 hours' interval. Up to writing time, our follow up revealed that both twins and their mother are in normal condition.

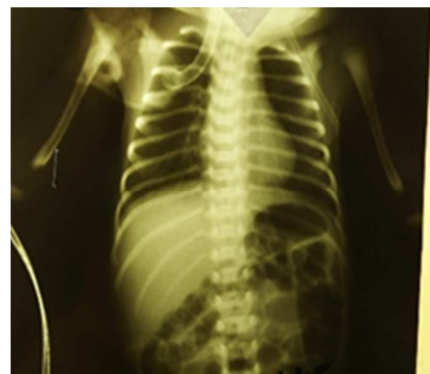

Figure 11. CXR of first twin during intubation period. It seems there is no evidence of unusual involvement of the lungs.

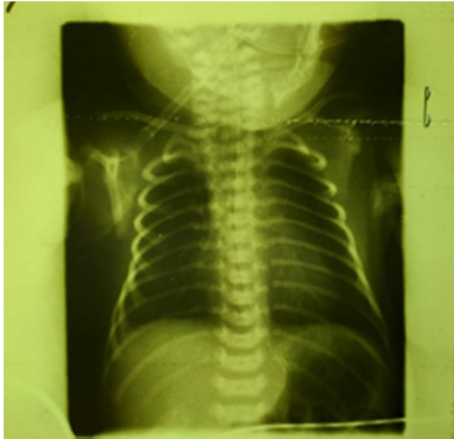


Figure 12. CXR of second twin, it seems there is no evidence of unusual involvement of the lungs.

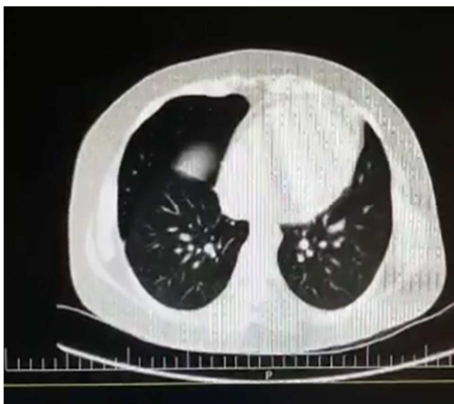

Figure 13. HRCT of twins' mother after recovery from Covid-19. Mild ground glass changes are seen in peripheral area.

Case 7:

A girl neonate with 35 weeks' gestational age, born on April 16, 2020, via cesarean section from the mother aged 30 years old. The mother was G2, P1, L1. The indication of pregnancy termination was PPRM. The neonate had Apgar score of 9 and 10 in the first and fifth minutes of the life, and she was 2295 gram which is appropriate for gestational age. Mother had fever in last two days before delivery, but she had no respiratory symptoms. She didn't have raised ESR or LDH and no lymphopenia was detected in her. But her CT scan revealed signs of Covid-19. And she got 5 days of treatment for COvid-19 at the hospital with hydroxichloroquin and infliximab.

There were no fetal concerns during pregnancy or delivery. Delivery occurred in an isolation room, with total and restrict consideration of PPE. delayed cord clamping was not performed. after delivery, neonate was immediately separated from his mother, and isolated for at least 14 days. She didn't need advanced resuscitation. Skin to Skin contact was not performed. The neonate was washed 6 hours after delivery. She admitted to NICU isolated room to undergo sepsis work-up, because of 2 days PPRM. She didn't receive supplementary oxygen. After one day he started feeding with

formula but she had feeding intolerance and she was assessed for NEC because of abdominal distention. She received vancomycin and meropenem and after 5 days the abdominal distension was better and she started to tolerate little amount of premature formula gradually. Her three PCR (On day 2 and 4 and 14) and CRP were negative, but her LDH was 1467 U/L. Her WBC count was 13400/mm³ with 47% lymphocytes. Mother didn't remember any suspicious contact with a person who might have CoVID19. She was tested for Covid-19 with pharyngeal swab just at the time of admission and later in third day of admission which all were negative. Her CT-Scan performed the day after delivery and was compatible with Covid-19.

There were no fetal concerns during pregnancy or delivery. Delivery occurred in an isolation room, with total and restrict consideration of PPE. delayed cord clamping was not performed. after delivery, neonate was immediately separated from his mother, and isolated for at least 14 days. She didn't need advanced resuscitation. Skin to Skin contact was not performed. The neonate was washed 6 hours after delivery. She admitted to NICU isolated room because of mild tachypnea which recovered using oxyhood for 4 hours. She discharged after 10 days of sepsis and NEC work up. Up to writing time and according to our follow up, both mother and neonate are in good condition. The neonate is on formula up to now because of maternal own will.

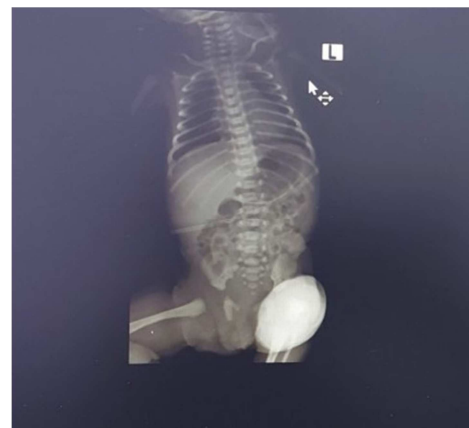

Figure 14. Neonate case 7, CXR which reveals no signs of pulmonary involvement.

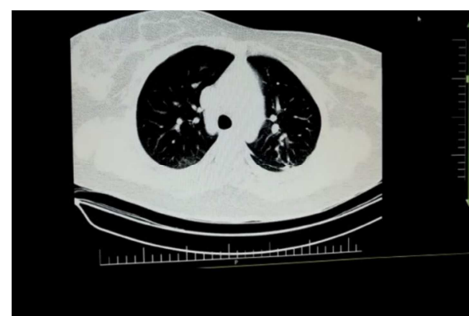


Figure 15. maternal HRCT of neonate case 7, with suspicious peripheral ground-glass appearance.

Table 1. Neonates' data summarized.

Data cases	Gender	GA	CRP1	CRP2	CRP3	WBC	Lymphocyte count
1	female	32w	—	—	—	8900/mm ³	3204/mm ³
2	male	39 w	—	—	—	15400/mm ³	5005/mm ³
3	female	36w	—	—	—	8000/mm ³	1600/mm ³
4	female	34w	Weakly positive	—	—	14700/mm ³	4000/mm ³
5	male	33w	—	—	—	10600/mm ³	4452/mm ³
6	male	33w	—	—	—	10200/mm ³	4284/mm ³
7	female	35w	—	—	—	13400/mm ³	6298/mm ³

Table 1. Continued.

Data cases	PCR1	PCR2	PCR3	LDH	Apgar Score	Clinical Presentation
1	—	—	+	1519U/L	8→10	Respiratory Distress and Oxygen dependency
2	—	—	—	1430 U/L	9→10	Tachypnea, Hypoglycaemia, IDDM
3	—	—	—	740 U/L	9→10	Fever
4	—	—	—	370U/L	9→10	Early Onset Sepsis, Pneumonia
5	—	—	—	260U/L	9→10	Apnea, Hyperglycaemia, Late onset sepsis
6	—	—	—	293U/L	9→10	Feeding Intolerance
7	—	—	—	1467U/L	9→10	Tachypnea, Pneumonia

3. Limitations

Since our knowledge was not completely support us for encountering with Covid-19, especially during first weeks of outbreak, we were not well equipped to precisely evaluate all

covid-19 infected mothers according to their PCR results from amniotic fluid, placental tissue and umbilical cord. Moreover, it was great conflicts between some negative PCR results and HRCTs highly compatible with covid-19.

It seems that it would be much better to mostly rely on HRCT results rather than many false negative PCR results.

Table 2. Mothers' data summarized.

Cases Data	Age	GA at termination	Fever	Myalgia	Respiratory Distress	WBC
1	26y	32 w	+	+	+	4000/mm ³
2	32y	39w	+	—	—	15500/mm ³
3	39y	36w	+	—	+	13000/mm ³
4	35y	34w	+	+	+	3700/mm ³
5	29y	33w	+	—	+	7600/mm ³
6	30y	35w	+	—	—	5600/mm ³

Table 2. Continued.

Cases Data	Lymphocyte	PCR1	PCR2	PCR3	LDH	CT Sacn Findings
1	1000/mm ³	+	—	—	454U/L	Approximately Compatible with covid-19
2	1085/mm ³	+	—	—	630U/L	Compatible with covid-19
3	2400/mm ³	+	—	—	700 U/L	Compatible with covid-19
4	1100/mm ³	+	—	—	850U/L	Compatible with covid-19
5	2300/mm ³	+	—	—	320 U/L	Compatible with covid-19
6	2100/mm ³	—	—	—	230 U/L	Compatible with covid-19

4. Discussion

From our seven cases of neonates born to mother with Covid-19, there were 4 girls and 3 boys. We had one twins among our neonates. All of them were born via cesarean section. The youngest mother aged 22 years old and the oldest one aged 39 years old. Only one of the neonate was term and 39 weeks' gestational age. All six others were late preterm or preterm, ranging from 32 weeks to 36 weeks' gestational age. two of our neonates were intubated and one of them receive two doses of crurof and few days of NIPPV due to RDS. The other one was intubated for one day because of recurrent

apnea due to late onset sepsis. Three of them had feeding intolerance which one of them was suspicious to NEC. only one of the neonates presented with fever up to 39.5 c, for 2.5 days. and only one of our neonates had positive PCR tests for 3 subsequent times which was compatible with his HRCT findings, the one who presented with RDS and received 2 doses of crurof and oxygen dependency for several days.

Generally, we didn't use any specific proceeding for Covid-19 in our patients, we just follow routine treatment and supportive respiratory actions. We tried to consider PPE perfectly to provide spreading of the virus, our isolated neonates had special nurse who didn't get involved with non covid patients at the time. Because of unstable condition of

mothers during first 2 weeks after birth and taking variety of medicine which their safety during lactation was unclear, we postpone breast feeding of neonates until maternal recovery and stopping their medicine and having two negative PCRs to be allowed for entrance to the ward and having close contact with their neonates.

5. Conclusion

Considering other studies and also our neonatal cases born to mothers which were infected with Covid-19, it seems unless we encounter with severely ill neonate with unexplained clinical, laboratory and imaging manifestations, It's better to follow routine neonatal treatment and supportive respiratory care including exact PPE protocols for patients with either RDS, Pneumonia, early or late onset sepsis and NEC. In our cases we managed all patients without using any especial treatment for covid-19 and all of them show acceptable outcome in their out-patient follow up.

References

- [1] Menachery VD, Yount BL Jr, Debbink K, Agnihothram S, Gralinski LE, Plante JA, et al. A SARS-like cluster of circulating bat coronaviruses shows potential for human emergence. *Nat Med*. 2015; 21: 1508-13.
- [2] Mimuoni F, Lakshminrusimha S, Pearlman S. A, Raju T, Gallagher P. G, Mendlovic J. perinatal aspects on the covid-19 pandemic: a practical resource for perinatal-neonatal specialists. *journal of perinatology*. 2020; 40: 820-826, The first covid-19 case original on November 17, according to Chinese officials searching for 'patient zero'. 2020. www.msn.com.
- [3] Singhal T. A review of coronavirus disease-2019 (COVID-19). *Indian J Pediatr*. <http://doi.org/10.1007/s12098-020-03263-6>. 2020. In press World Health Organization. Middle East respiratory syndrome coronavirus (MERS-COV). November, 2019 (EB/OL). 2019-11) (2020-01-25). <http://www.who.int/emergencies/mers-cove/en/>.
- [4] BANAEI M, GHASEMI V, SAEI GHARE NAZ M, KIANI Z, RASHIDI-FAKARI F, BANAEI SB, MOHAMMAD SOURI B, ROKNI M. Obstetrics and Neonatal Outcomes in Pregnant Women with COVID-19: A Systematic Review. *Iran J Public Health*. 49 (Suppl. 1): 38-47.
- [5] Chen H, Guo J, Wang C, Luo F, Yu X, Zhang W, Li J, Zhao D, Xu D, Gong Q, Liao J, Yang H, Hou W, Zhang Y. Clinical characteristics and intrauterine vertical transmission potential of COVID-19 infection in nine pregnant women: a retrospective review of medical records. *Lancet*. 2020; 395 (10226): 809-15.
- [6] Chen S, Huang B, Luo DJ, Li X, Yang F, Zhao Y, Nie X, Huang BX. [Pregnant women with new coronavirus infection: a clinical characteristics and placental pathological analysis of three cases]. [Article in Chinese]. *Zhonghua Bing Li Xue Za Zhi*. 2020 Mar 1. [Epub ahead of print].
- [7] Fan C, Lei D, Fang C, Li C, Wang m, Liu Y. et al. prei-natal transmission of covid-19 associated SARS-Cov-2: Should we worry? *clinical Infectious disease*. 2020.
- [8] Wang1a X, Zho2a Z, Zhang J, Zhu F, Tang Y, Shen X. et al. A case of 2019 Novel coronavirus in a pregnant woman with preterm delivery. 2020.
- [9] Hui DS, Azhar EI, Madani TA, Ntoumi F, Kock R, Dar O, et al. The continuing 2019-n Cov epidemic threat of novel coronaviruses to global health- The latest 2019 novel coronavirus outbreak in Wuhan, China. *Int J infect Dis*. 2020; 264-6.
- [10] Chen H, Guo J, Wang C, Luo F, Yu X, Zhang W, et al. Clinical characteristics and intrauterine vertical transmission potential of COVID-19 infection in nine pregnant women: a retrospective review of medical records. *Lancet*. 2020; 395: 809-15.
- [11] Zhu H, Wang L, Fang C, Peng S, Zhang L, Chang G, et al. Clinical analysis of 10 neonates born to mothers with 2019-nCoV pneumonia. *Transl Pediatr*. 2020; 9: 51-60.
- [12] Dong Y, Mo X, Hu Y, Qi X, Jiang F, Jiang Z, et al. Epidemiological characteristics of 2143 pediatric patients with 2019 coronavirus disease in China. *Pediatrics*. 2020. In press. <https://doi.org/10.1542/peds.2020-0702>.
- [13] Zeng L, Xia S, Yuan W, Yan K, Xiao F, Shao J, et al. Neonatal early-onset infection with SARS-CoV-2 in 33 neonates born to mothers with COVID-19 in Wuhan, China. *JAMA Pediatrics*. <https://doi.org/10.1001/jamapediatrics.2020.0878>. 2020. In press.
- [14] Huang C, Wang Y, Li X, Ren L, Zhao J, Hu Y, et al. Clinical features of patients infected with 2019 novel coronavirus in Wuhan, China. *Lancet*. 2020; 395: 497-506.
- [15] Parry J. Wuhan: Britons to be evacuated as scientists estimate 44 000 cases of 2019-nCoV in the city. *BMJ*. 2020; 368: m351. [DOI: 10.1136/bmj.m351] [PMID].
- [16] Song F, Shi N, Shan F, Zhang Z, Shen J, Lu H, et al. Emerging 2019 novel coronavirus (2019-nCoV) Pneumonia. *Radiology*. 2020; 00 (0): 1-8. [DOI: 10.1148/radiol.20200274] [PMID].
- [17] Kanne JP. Chest CT findings in 2019 novel coronavirus (2019-nCoV) infections from Wuhan, China: Key points for the radiologist. *Radiology*. 2020; xxx (x—xxx): 1-2. [DOI: 10.1148/radiol.20200241] [PMID].
- [18] Rahimzadeh G, Ekrami Noghabi M, Kadkhodaei Elyaderani F, Navaeifar M R, Enayati A A, Manafi Anari A, et al. COVID-19 Infection in Iranian Children: A Case Series of 9 Patients. *J. Pediatr. Rev*. 2020; 8 (2): 139-144 URL: <http://jpr.mazums.ac.ir/article-1-314-en.html>.