



Review Article

Isthmoplasty: Surgical Techniques and Review of Literature

Andres Vigueras Smith^{1,*}, Monica Tessmann Zomer Kondo¹, Carlos Trippia², William Kondo¹

¹Department of Gynecology, Sugisawa Hospital, Curitiba, Brazil

²Department of Radiology, Nossa Senhora das Graças Hospital, Curitiba, Brazil

Email address:

afvigueras@gmail.com (A. V. Smith)

*Corresponding author

To cite this article:

Andres Vigueras Smith, Monica Tessmann Zomer Kondo, Carlos Trippia, William Kondo. Isthmoplasty: Surgical Techniques and Review of Literature. *Advances in Surgical Sciences*. Vol. 6, No. 2, 2018, pp. 72-80. doi: 10.11648/j.ass.20180602.16

Received: November 1, 2018; **Accepted:** November 21, 2018; **Published:** December 19, 2018

Abstract: The present review aims to analyze the current data available on the different endoscopic surgical techniques described for Isthmocele treatment. A semantic review of literature was made of all english language publications on databases Pubmed and Google Scholar following a Mesh and key word searching. The studies were finally selected by one author according to the aim of this review. The isthmocele, defined as a defect of the anterior wall of the uterine cervical canal at the site of a previous cesarean section scar, is a prevalent condition in women submitted to gynecological endoscopic procedures. Epidemiological studies report a 1.9% of cesarean scar defects, rising in the last decades, and it is clear that the repair carries benefits in terms of symptom control and sub-fertility. The minimally invasive approach is the gold standard due the inherent benefits in quality and magnification of image, less postoperative pain, hospital stay and minor complications rate. It can be treated either by laparoscopy or hysteroscopy according to the presentation of the disease and the preference of the surgical team, since both have the same efficacy in symptoms improvement (59% to 90%). Laparoscopy is usually indicated when overlying myometrial mantle is less than 3 mm, and allows an increase in postoperative myometrial strength. Different surgical techniques have been described and supposedly, there is no significant difference among them. Large analytical prospective experimental studies are required to confirm the results of this data and to investigate as to whether there is a better laparoscopic technique.

Keywords: Laparoscopic Surgery, Hysteroscopic Surgery, Isthmocele, Surgical Treatment, Techniques, Niche, Cesarean Scar Defect

1. Introduction

1.1. Definitions and Epidemiology

Isthmocele, also known as uterine niche, endometrial reservoir, cesarean scar defect (CSD) or uterine scar insufficiency, was defined by Gubbini and Armstrong as a defect of the anterior wall of the uterine cervical canal at the site of a previous cesarean section (CS) scar. [1, 2] Anatomically, it is a discontinuation of the myometrium at the site of the previous CS, with a deficiency of the lower part of the scar, but not compromising the uterine serosa. [3] (Figure 1 and Figure 2)

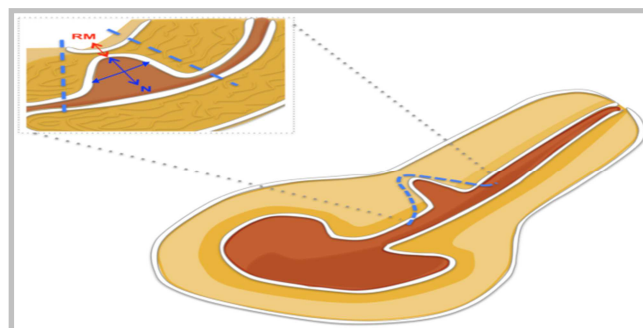


Figure 1. General configuration of cesarean scar defect. N: Niche. RM: Residual overlying myometrium.

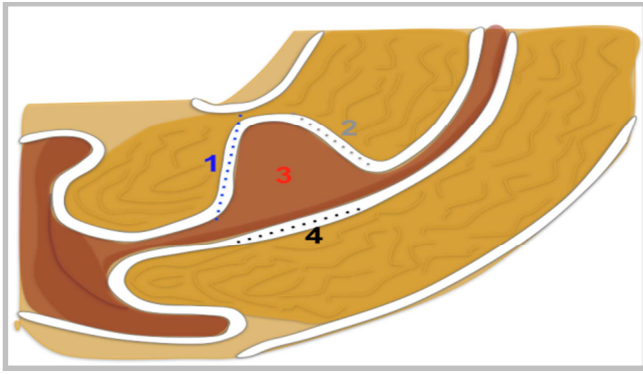


Figure 2. Anatomical points in the Isthmocele: 1: Caudal edge. 2: Cranial edge. 3: Bottom. 4: Posterior face of the defect.(anterior surface of endocervical canal).

According to one of the biggest studies, the incidence of cesarean scar dehiscence and isthmocele is about 1.9% and 0.6 % respectively, showing a rise in the last decades by the exponential increase of CS deliveries. [4, 5] The Systematic Review of Bu de Vatte in 2014 find a prevalence (among all CS) between 56% to 84%, when sonohysterography is used as diagnostic method. [6] Similarly in Tulandi's Metanalysis, 24% to 88% of patients with previous CS submitted to ultrasound present the characteristic features. [7] Finally, Nezhat informs an overall rate of 21%, with a range between 6.2 to 32%. [8]

1.2. Pathology, Etiology and Risk Factors

The pathogenesis comes from an alteration of two major processes: the inadequate healing of the caesarean suture line and the reduction of the residual thickness of the overlying myometrium. [9]

Morris was the first to analyze macro and microscopical changes within the scar tissue of the Isthmocele, finding fibrosis, old blood, mucus, debris and inflammatory cells. [10] This fibrotic tissue can cause pelvic pain and the menstrual blood accumulation inside leads to several types of abnormal bleeding. Also, the pathological abnormalities will harm the sperm and cervical mucus quality. [11] Additionally, newly formed fragile vessels within CSD may play a role in the formation of blood or fluid within the niche and uterine cavity. [12].

The clear etiology is unknown, but arises from the scar of previous CS. It appears that the major factor is an inadequate surgical management of the hysterotomy closure, including the suture material and technique, numbers of layers closed, among others. [3] Thus, retroverted uterus, single layer closer CS, a very low incision through cervical tissue, use of locking sutures, endometrial-sparing closure, the CS at advanced trail of labor and preeclampsia are accepted risk factors. [6, 13, 14]

Furthermore, Baratham spotted underlying anatomical uterine defects that could weaken the myometrial layer as an additional risk, as well as postoperative infections. [15] Finally, general conditions as diabetes, infection, emergency surgery, multiple cesarean deliveries and congenital anomalies could impair wound healing, increase local inflammation and rise the risk of CSD. [16].

There is no an universal classification. For instance, Olifi classified it as mild to severe, depending on the percentage (cut at 50%) of loss in myometrial layer within the scar. [17] Other authors consider that when the defect is higher than 80% in the anterior myometrium layer, a dehiscence is present. Independently of this lack, the size of the CSD, overlying myometrial mantle (OM) and total myometrial thickening (TMT) are relevant variables when planning the treatment. (Figure 3)

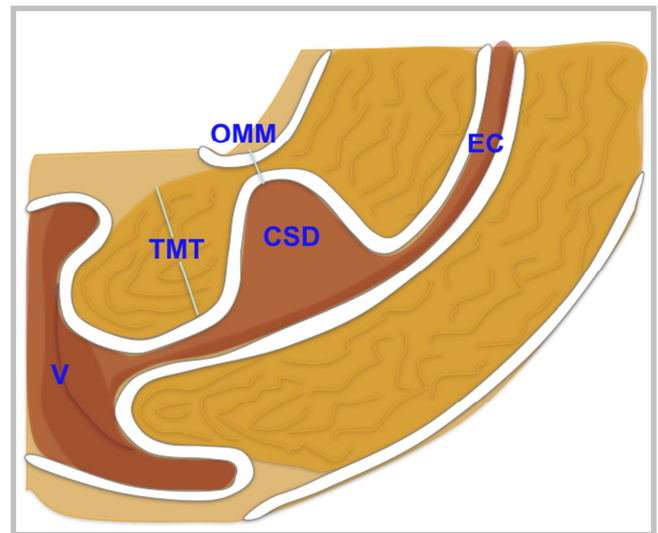


Figure 3. Anatomical scheme of the Isthmocele area. V: Vaginal cavity. EC: Endocervical canal. CSD : Cesarean scar defect. OMM : Overlying myometrial mantle. TMT : Total Miometrial Thickness.

1.3. Clinical and Imaging Diagnosis

The diagnosis is suspected by clinical history and imaging explorations in all the patients with previous cesarean delivery and positive risk factors. [18]

Approximately 30% (range between 19 to 88 %) of CSD will be symptomatic, with the AUB being a major symptom by far. [3, 19, 20] Post-menstrual spotting, discharge, fetid post-menstrual bleeding, chronic pelvic pain, dyspareunia and secondary infertility could present. [11, 21] There is a direct association between the size of the lesion and the intensity of the symptoms. [22]

The first relation between CSD and AUB symptoms was made by Stewart and Evans in the BJOG of 1975. [23] Later, Thurmond described menstrual blood collection within the pouch, and proposed this as a cause. [24]

Concerning sub-fertility, the blood retention and cervical mucus accumulation could harm the quality of the sperm, interfere with the implantation process and disrupt the sperm movements. [25, 26]

Other unusual presentations are the postpartum hemorrhage, endometritis and ectopic pregnancy. [3]

Furthermore, future obstetrical complications as scar dehiscence, uterine rupture, scar pregnancy and placental accretism could present. [27]

In some cases, incidental routine imaging exam or general gynecological surgery can evidence it. [28] Commonly,

TVUS is widely considered the primary diagnostic approach. A triangular and/or hypo echoic fluid showing an irregular defect in the anterior uterine wall, at level of the cesarean section scar, is usually enough for the diagnosis. (Figure 4) [6] This triangle is usually orientated with its base to the cervical canal and the apex to the anterior myometrial wall. [28]

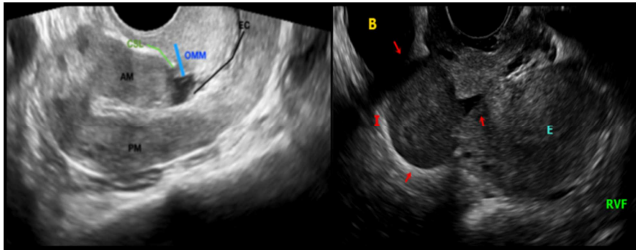


Figure 4. Ultrasound View. Hipo-echoic cyst-like formation within the anterior cervical isthmus wall in the C-section scar site. In a close look it is possible to identify the anatomical parts of the Isthmocele. TMT: Total myometrial thickness. OMM: Overlying myometrial mantle. AM: Anterior myometrium. PM: Posterior myometrium. EC: Endocervical channel. B: Bladder. E: Endometrium. RVF: Retroversoflexion.

Besides, MRI is helpful in cases of doubts or technical difficulties such as obese patients, giving exact information of the size, location and its relationship with adjacent structures. (Figure 5) [3]

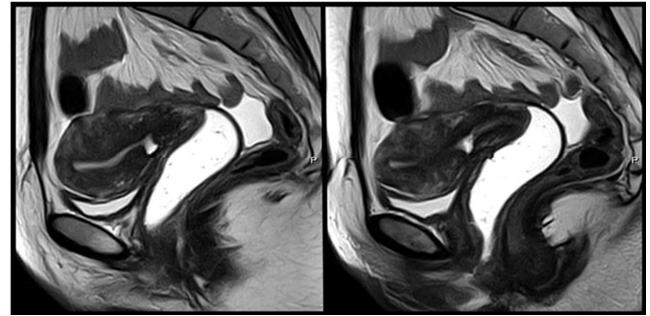


Figure 5. MRI View. A muscular loss and thinning with a hyper-intense cyst-like image within the C-section scar on anterior myometrium, in a sagittal T2-Weighted.

Nevertheless, the final diagnosis is by surgical direct visualization. (Figure 6 and Figure 7)

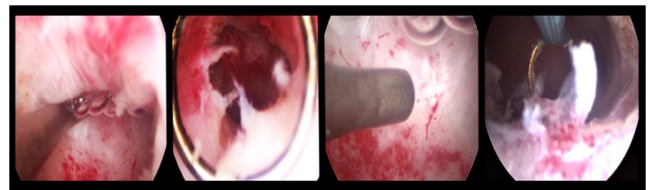


Figure 6. Hysteroscopic View. Anterior pouch like defect surrounded by fibrotic tissue. Note the the fibrotic white tissue within and near the lesion. Inflammatory reaction and proliferation is found in the posterior surface of endocervical canal at level of the Isthmocele.

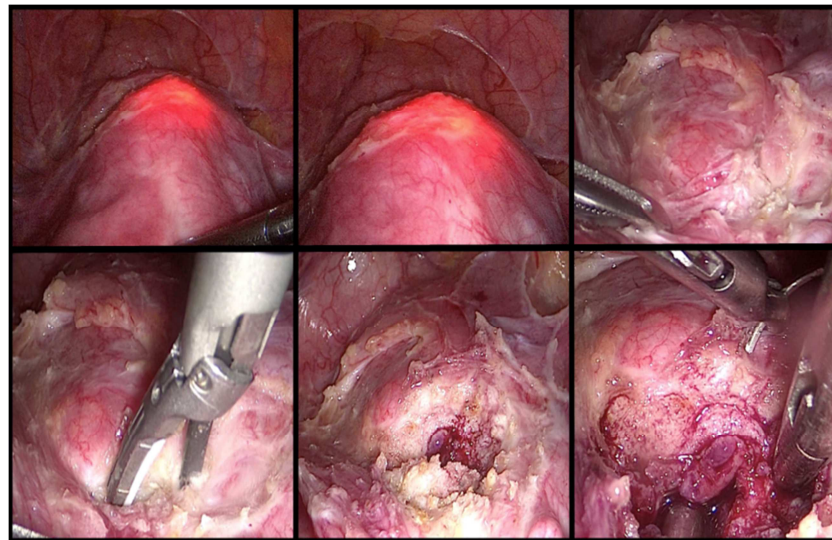


Figure 7. Laparoscopic View. Using the “Rendez Vous” technique note the “Halloween Sign” delimiting the defect (by hysteroscopy). Complete laparoscopic resection is made and a two layer closing is performed with 2-0 absorbable synthetic monofilament thread.

2. Methods

The primary objective is To analyze the current information related to surgical treatment of isthmocele, focused on different surgical techniques described for the minimally invasive approaches.

A comprehensive review of literature was carried out, conducting a total computerized search for English publications on databases Pubmed and Google Scholar related to isthmocele and the surgical technique. We included all

studies found under the search of following Mesh and the key words terms: Isthmocele AND Hysteroscopic Surgery OR Laparoscopic surgery OR Surgical treatment OR Techniques OR Niche OR Cesarean scar defect. One author independently made a selection of relevant abstracts according to the aim of this review. The primary objective was to know the techniques, effectiveness and security of the different surgical treatments for isthmocele.

We start giving definitions and epidemiological information. Afterward, a review of surgical techniques are presented. Finally, we discuss the general and specific results of the

isthmoplasty between the different techniques and draw conclusions.

3. Results: Treatments for Isthmocele

It is a general consensus that in the presence of a symptomatic disease, or when there is a direct cause of infertility, the treatment is indicated. Nevertheless, exhaustive study to rule out other causes of those symptoms is mandatory. The main objective is to resolve those symptoms and, additionally, restore the normal anatomy of the cervical canal. [28] Election will depend mostly on the clinical presentation, parity, desire of fertility and team experience.

There are two primary treatments for the isthmocele: conservative, including follow-up and hormonal estrogen - progesterone based treatments, and surgical repair. Medical options include oral contraceptives or levonorgestrel IUD, and must be offered first. Although they can improve microcirculation, the temporarily effects, high rate of irregular bleeding and the lack of proved effectiveness make them a suboptimal option. [12, 29] Thus, when those are contraindicated, failed or when the patients are looking for a pregnancy, surgery is indicated.

The primary aim of the surgery is to excise or ablate the fibrotic tissue of the scar defect, flattening the defect and restoring the cervical canal anatomy. This improves the symptoms caused by the inflamed tissue present within and near the lesion, and facilitates the drainage of menstrual blood. [30]

Multiple enlightening techniques have been used, including vaginal, laparoscopic, hysteroscopic and robot assisted. [11, 31-33]

Until September of 2017, 14 studies for hysteroscopy, 13 for laparoscopy, 7 to vaginal and 3 to laparotomy have reported different types of treatments. [34] It is important to know the safe and effectiveness of these approaches.

3.1. Laparoscopic Isthmoplasty

Will be choice when the residual myometrium achieved preoperatively is less than 3mm. [25, 34]

The first laparoscopic repair of a CSD in a 24 years old woman was carried out by Jacobson in 2003. Initially, he mobilized the bladder inferiorly to the level of the vagina, after previous identification of the superior vesicle artery in order to facilitate the bladder flap. Under hysteroscopic guidance, the edges of the fistula were re-excised using CO2 laser and the renewed margins were re-approximated using interrupted sutures of Vicryl 2-0. [35]

Later, Donnez in the Fertility Sterility describe the main surgical technique. Using CO2 laser, the scar is opened from “end to end”, and the fibrotic tissue is excised from the edges, accessing to the healthy myometrium. Before the surgical closure, and with the aim to preserve the cervical canal, a Hegar probe is inserted trans-cervically. Finally, a double layer closure is performed, including the peritoneum. [36] (Figure 8)

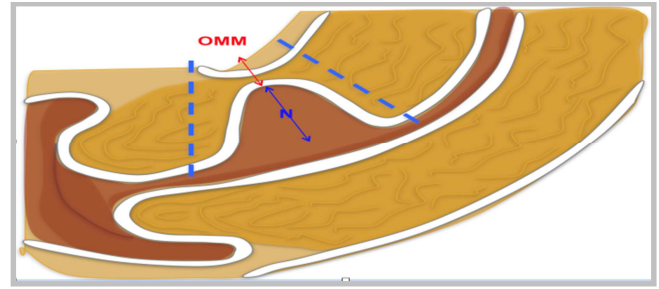


Figure 8. Laparoscopic Repair. Complete resection of fibrotic area, renewing the edges and avoiding the damage of endocervix and posterior endocervical face. OMM: Overlying myometrial mantle. N: Niche.

Zhang summarized the technique in consecutive steps. Initially, the peritoneum over the bladder is opened and the bladder is mobilized down. Posteriorly, a hysteroscopic exploration of cervical canal is performed. The light is pointed to the top of the CSD allowing the laparoscopist to identify the upper and lower edge of the scar, and excise all the ceiling-lateral wall-inferior edge of the pseudo cavity. The endometrium of the posterior wall of the isthmus should be preserved, along with the cervical blood supply, preventing adhesions formation. Finally, a two layer running or interrupted suture using 1-0 PDS or Vicryl is performed, making sure that the whole myometrial and endometrial layers were taken in. Afterwards, re-peritonization covering the isthmus is made. [37]

Urman explain other techniques in the JMIG. [27] Starting with a dissection of vesicle-vaginal space, the defect is delimited by laparoscopic sharp and blunt dissection, helped by a curette placed trans-cervically and pushed anteriorly to delineate the margins. All the fibrotic tissue placed in the ceiling and lateral border of the isthmocele is excised using cold scissors. Finally, a continuous non locking 3-0 barbed sutures are used for closure.

Similarly, Nazik begins opening the visceral peritoneum covering the isthmus using bipolar dissection and scissors. Following, the bladder is mobilized caudally by blunt and sharp dissections. After an adequate delimitation, the scar is completely removed using harmonic scalpel and the surgical wound is repaired with a continuous Polyglactin 2-0 suture. [9]

Bakaviciute emphasizes the paramount importance of the complete resection of fibrous tissue and the renew of the wound edges before the closure. [38]

Recommendations were given by the AAGL global congress in 2016. Always perform a hysteroscopy to verify the CSD and then place an intra-cervical cannula. Start mobilizing the bladder and continue with a lateral dissection above the uterine vessels. Then, the surgeon should go back to the hysteroscopy to define the CSD and proceed to the hysteroscopic resection of the lower segment of the defect. Posteriorly, the light of the hysteroscope is targeted to the niche and the laparoscopic time start by excising the isthmocele in a cephalic-caudal way using ultrasonic or monopolar energy. The repair must be done in three layers: two interrupted or U-shaped 3-0 monofilament sutures at the

angles of the resection, and a finally 3-0 barbed suture following the baseball style. Once the closure is completed, repeat the hysteroscopy to verify absence of cervical stenosis and complete surgical repair. [39]

As Setubal explained in 2017, the critical step of the procedure is the precise identification of the CSD, which can be done by using hysteroscopy and putting the tip of the light towards it. Also, a number 6 Hegar dilator can be placed and pushed forward blindly to the uterine isthmus, distending the lesion and allowing better laparoscopic identification. [34]

In fact, this combined laparoscopic-hysteroscopic repair, called the “Rendez-Vous” technique has been describe. The primal advantage is the clear localization, size, width and depth of the defect using the “halloween sign”, a laparoscopic visualization of the CSD while the hysteroscope light is put behind the lesion. [40] The procedure is scheduled one week after menstruation. An ultrasonic scalpel is used to open the peritoneal fold over the bladder, which is dissected and pushed down at least 2 cm apart from the lower edge. Afterward, hysteroscopy must identify the isthmocoele by the presence of diverticular mucosal hyperplasia (partially white). Using monopolar, the scar is opened, resected and closed laparoscopically using full thickness 2-0 absorbable stitches, including the peritoneal layer. (29) Recently, Nirgianakis confers this technique as safer, effective and feasible. [40]

Efficacy issues for laparoscopic repair were presented by Donnez and Liu, reporting a postoperative pregnancy rate of 44%, and a 89% of symptoms improvement. [31, 41]

3.2. Hysteroscopic Isthmoplasty

It is the less invasive approach, but it will require adequate equipment and sufficient residual myometrium to prevent bladder injuries. Generally it is indicated when the overlying myometrial mantle (OMM) is superior to 2mm (cut off value between 2 to 4 mm). Two major surgical ways are described: resection of the lower rim or both, the lower and the upper part. These can be combined with vessels coagulation within the niche or in the entire surface. Surgeons must know that, theoretically, proximal resection could cause cervical incompetence in the next pregnancies. [12]

The primary objective is to facilitate the drainage of menstrual blood through the cervix, rather than anatomical correction. Any surgical technique must follow four basic steps: diagnostic hysteroscopy, cervical dilatation, resectoscopic excision of the proximal border and cauterization of the superficial dilated vessels inside the pouch.

Different instrument sizes are used, varying from 16 to 27 Fr. A major cause of incomplete resection will be the intraoperative technical difficulties due the size of the instrument. [1, 42, 43]

Xie begins by mechanical cervical dilatation up to 12 mm and afterward the hysteroscope is inserted and the CSD is recognized. Using monopolar energy, a cutting loop is used to remove the fibrotic tissue flap under the pouch, starting from the bottom of the defect to the endocervical canal. The remaining tissue is then cauterized. [44]

Gubbini described a four consecutive step technique using an homonymous 16 Fr Resectoscope. A bipolar loop is use to resect the proximal (step 1) and distal (step 2) part of the isthmocoele with a 360 degrees resection (endocervical ablation), including all residual inflamed tissue near the primary lesion. The third step is an entire coagulation of niche surface with a roller ball electrode, looking to replace the normal mono stratified cubic cell epithelium of the cervical isthmus. The final step is hemostasis of any endocervical bleeding, helped by reducing inflow volume and pressure of distention. [30] (Figure 9)

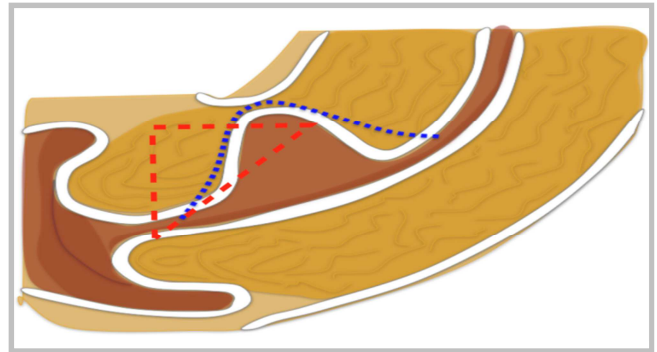


Figure 9. Hysteroscopic Repair. The aim is a complete resection of the fibrotic area avoiding the uterine anterior perforation. Could be done resecting all the defect (Blue line) or just the proximal margin in a wedge resection fashion (Red line).

Another technique is described by Fabres, performing a resection of the fibrotic tissue as a flap that appeared underneath the triangularly pouch defect placed in the anterior uterine segment behind the inner OS, using a 9mm Resectoscope and monopolar energy. Fulguration of superficial dilated blood vessels and endometrial glands within the pouch is finally made. [42]

Muzzi, using a 10mm resectoscope and monopolar energy, removed the flap over the fibrotic tissue seeing underneath the pouch defect, starting from the distal limit to the endocervix, modulating the technique in the base until the normal myometrium tissue below is evident. Finally, he cauterizes the residual tissue within and near the defect with a 3mm roller ball. [5]

Efficacy issues for hysteroscopy reports until 100% of postoperative pregnancy rate. [26] Meanwhile, for symptoms control, Raimondo find that 80% of the 200 patients treated, achieved the resolution of their symptoms. [43]

3.3. Vaginal Isthmoplasty

Requires great surgical expertise and a “not to high” isthmocoele, since this rise the intra-operative complications.

The main surgical technique was described by Zhang and Yang in 2016. Initially the cervix is grasped by two forceps and a diluted bovine pituitary hormone preparation is injected sub-epithelially at the cervico-vaginal junction, aiming less blood and better tissue planes recognition. Then, an incision is made and the bladder is mobilized. Afterward, a complete identification and resection of CSD must be done. [45]

When vaginal is compared to laparoscopic, similar results in bleeding symptoms control and anatomic correction are found, with 89% and 87% respectively. [46]

3.4. Robotic and Robotic Assisted Isthmoplasty

Mahmoud and Nezhat described the procedure and it is quite similar to the laparoscopic repair. All the scar tissue of the defect is removed and the wall is closed using delayed absorbable suture. Chromoperturbation is used to confirm the water tightness of the repair. [47]

3.5. Laparotomic Isthmoplasty

According to Schepker, a complete resection of the dehiscence myometrium and a two-layer suture with 2-0 to 4-0 Vicryl interrupted sutures must be performed. The major points of the procedure are the correction of the myometrial edges layer by layer, and the hemostasis. [48]

This approach is important in cases of scar dehiscence, when the urgency of the situation commands a quick diagnosis and repair. Conservative treatment (restore after debridement) is an option, but hysterectomy must be considered when infection is present.

4. Discussion

Isthmoplasty can be performed by any approach and the surgical technique will try to flatten the scar affect area, restoring the anatomical continuity of the cervical canal and improve the normal menstruated flux by avoiding niche blood accumulation and subsequent reflux to the uterine cavity.

The primary aim of the treatment will be the symptoms control, so asymptomatic CSD should not be treated. [30]

Fabres was the first to propose that the surgical remotion of the fibrotic scar tissue will improve menstrual symptoms. Despite the rise of publications, the lack of randomized controlled trails has limited our knowledge about the better choice when dealing with the disease. [28]

Global treatment success between different approaches appears to be equal, with AUB improvement between 59 to 100%. [49] However, according to what was presented recently by Li and Chen, surgical time and intra-operative complications seems to be lower in the hysteroscopic rather than laparoscopic or vaginal route. [50, 51]

Florio and Gubbini in 2011, studying retrospectively a total of 46 symptomatic isthmocèles treated with hormonal modulation or hysteroscopic resection, found that endoscopic treatment was more effective in symptoms control. [19]

In the prospective study of Gubbini, all the 41 resectoscope-treated infertile patients had a complete regression of their symptoms and got spontaneous pregnancy within the 24 months after surgery. [52]

A prospective evaluation of the efficacy of resectoscopy was published by Muzzi in 2017. In 23 women treated, a significant reduction in total menstrual duration and symptoms relief were found. [5]

A comparison between laparoscopy and hysteroscopy in

terms of pregnancy rates and symptoms improvement was presented by Tulandi in his Metanalysis. Among the 32 trails included, he found a pregnancy rate of 77% - 100%, and a AUB improvement of 59 - 100% for hysteroscopic repair. Meanwhile for laparoscopy, the result was 86% for both outcomes. [7]

Finally, Api in the JMIG concludes that hysteroscopy is equally effective to laparoscopy in terms of symptoms control, but did not increase the myometrial thickness. [53]

Since both approaches are equally effective in symptoms control, the discussion moves beyond and includes other variables.

The overlying myometrial thickness will be crucial when choosing the surgical approach. [28] For Vevoort, hysteroscopy is not the best choice for defects larger than 5mm and/or when the residual myometrial thickness is less than 3mm due the high risk of bladder injuries. [54] Also, hysteroscopy is capable to coagulate the superficial but not the deep myometrial vessels, rising the risk of bleeding. These results were confirmed by a recent RCT of the same author, when resectoscopy was a safe and effective tool to perform isthmoplasty in those cases with residual myometrium equal or higher than 3mm. [12] Similarly, many authors give their recommendations for one or the other according to two standard anatomical parameters: the residual myometrial thickness and the percentage of uterine wall defect. For Li, women with bigger defects (residual thickness less than 3.5mm/myometrial defect higher than 50%), the laparoscopic repair will be preferred because, theoretically, it gives better postoperative anatomic results. For smaller ones, the hysteroscopy will be safe and effective. [50]

A further issue is the final anatomic result in terms of uterine wall thickness. Hysteroscopy fixes the scar defect but does not increase myometrial thickness and strenght, meanwhile laparoscopy theoretically increases the force of the wall, reducing the risk of dehiscence or rupture in subsequent pregnancies. [53]. At the same time, studies published in the BJOG claim a better wall recovery when repairs are performed by laparoscopy, since hysteroscopy could leave some scar tissue due to an incomplete resection. [28].

Vaginal isthmoplasty has demonstrated good clinical results in terms of symptoms relief [55], but with higher operating time, blood loss and hospital stay when compared to endoscopic procedures. [32]

Robotic assisted is clearly less used and more expensive, but providing all the advantages of robotics in terms of degrees of motion, no tremor and depth of perception.

Despite the approach, the pregnancy termination after isthmoplasty must be a cesarean section, always performed before labor and after 32 weeks.

In terms of prevention, the number of layers closed during C - section still inconclusive. The metanalysis published by Dood in the Cochrane of 2014, reveals a fewer risk of scar defects with a single closure in comparison to a two layers. [56] Meanwhile, other authors demonstrated less CSD when the hysterotomy is closed in a double layer and when endometrium is full included. [18, 57]

5. Conclusion

Laparoscopic, hysteroscopic and vaginal procedures show the same efficacy in symptoms control (59% to 90 %) and post-operative pregnancy rate (70% to 100%). Even when hysteroscopy trend to show less intra-operative complications and surgical time, the post-operative myometrial thickness is higher after laparoscopic repair.

Thus, the choice between hysteroscopy or laparoscopy will depend predominantly on the available instrumental, surgeon skills, size of the CSD and the OMM. When the isthmocele is bigger than 5mm and/or the defect is more than 50% of myometrial thickness and/or OMM is less than 2.5 or 3mm, probably the best choice will be the laparoscopy.

One of the dominant issues is the prevention, regarding to a correct CS indication and a good performance during the interventions, avoiding the inadequate healing of the suture line .

To date, the lack of good evidence hinders the final evaluation of efficacy, of different surgical techniques for the treatment of the isthmocele. It will be necessary to study the profits of each approach and technique through large-scale randomized studies with adequate follow-ups.

Acknowledgements

To our family and friends that will always support us.

Abbreviations

AJOG: American journal of obstetrics and gynecology; JMIG: Journal of minimally invasive gynecology; IUD: Intra uterine device. AUB: Abnormal uterine bleeding. CS: Cesarean section. CSD: Cesarean scar defect. OMM: Overlaying myometrial mantle. TMT: Total myometrial Thickening BJOG: British journal of Obstetrics and Gynecology. TVUS: Transvaginal ultrasound. OS: Ectocervix. RCT: Randomized controlled trail. Fr: French.

References

- [1] Gubbini G, Casadio P, Marra E. Resectoscopic correction of the isthmocele in women with postmenstrual abnormal uterine bleeding and secondary infertility. *J Minim Invasive Gynecol* 2008; 15: 172- 175.
- [2] Armstrong V, Hansen WF, Van voorhis BJ, Syrop CH. Detection of Cesarean scars by transvagi- nal ultrasound. *Obstet Gynecol* 2003; 101: 61- 65.
- [3] Darwish A. Fertility-oriented Female Reproductive Surgery , Microsurgical Cesarean Section 5. January 18th 2017. DOI: 10.5772/67123.
- [4] Diaz SD, Jones JE, Seryakov M, Mann WJ. Uterine rupture and dehiscence: ten year review and case control study. *South Med J*. 2002; 95:431–5.
- [5] Muzzi L, Domenici L, Lecce F et al. Clinical outcomes after resectoscopic treatment of cesarean-induced isthmocele: a prospective case-control study *Eur Rev Med Pharmacol Sci* 2017; 21:3341-3346.
- [6] Bij de Vaate AJ, Van der Voet LF, Naji O , et al. Prevalence, potential risk factors and development of uterine niches following cesarean section: systematic review. *Ultrasound Obstet Gynecol* 2014; 43:372-382.
- [7] Tulandi T, Cohen A. Emerging manifestations of cesarean scar defect in reproductive - aged women. *J Minim Invasive Gynecol*. 2016 Sep–Oct; 23(6):893–902.
- [8] Nezhat C, Soliemannjad R, Razavi GM, Nezhat A. Cesarean Scar defect: what is and how should it be treated? *OBG Management*. 2016; 28(4): 32-53.
- [9] Nazik, H, Nazik E. A new problem arising after cesarean, cesarean scar defect (Isthmocele) a case report. *Obstet Gynecol Int J* 2017, 7(5): 00264.
- [10] Morris H. Surgical pathology of the lower uterine segment cesarean segment scar: is the scar a source of clinical symptoms?. *Its J Gynecol Pathol*.1995; 14: 16-20.
- [11] Florio P, Filippeschi M, Moncini I, Gubbini G. Hysteroscopic treatment of the cesarean induced isthmocele in restoring infertility. *Curr Opin Obstet Gynecol*. 2012; 24(3): 180–6.
- [12] Vervoort A, Van der Voet LF, Hehenkamp WJK et al. Hysteroscopic resection of a uterine caesarean scar defect (niche) in women with postmenstrual spotting: a randomized controlled trial. *BJOG*.2017. DOI: 10.1111/1471-0528.14733.
- [13] Roberge S, Demers S, Girard M, Vikhareva O, et al. Impact of uterine closure on residual myometrial thickness after cesarean: a randomized controlled trial. *Am J Obstet Gynecol*. 2016. 214: 507. e1-6.
- [14] Osser OV, Jokubkiene L, Valentin L. Cesarean section scar defects: agreement between transvaginal sonographic findings with and without saline contrast enhancement. *Ultrasound Obstet Gynecol*. 2010; 35: 75-83.
- [15] Bharatam KK. Cesarean section uterine scar dehiscence—a review. *Uterus Ovary*. 2015; 2: e751.
- [16] Vervoort AJ, Uienbogaard LB, Hehenkamp WJ, Brölmann HA, Mol BW, Huirne JA. Why do niches develop in Caesarean uterine scars? Hypotheses on the etiology of niche development. *Hum Reprod*. 2015; 30(12): 2695–702.
- [17] O li - Yebovi D, Ben Nagi J, Sawyer E, et al. De cient low - segment cesarean section scars: prevalence and risk factors. *Ultrasound Obstet Gynecol*. 2008; 31: 72–77.
- [18] Hayakawa H, Itakura A, Mitsui T, Okada M, Suzuki M, Tamakoshi K, Kikkawa F. Methods for myometrium closure and other factors impacting effects on ce- sarean section scars of the uterine segment de- tected by the ultrasonography. *Acta Obstet Gyne- col Scand* 2006; 85: 429-434.
- [19] Florio P, Gubbini G, Marra E, Dore d, et al. A retrospective case–control study comparing hysteroscopic resection versus hormonal modulation in treating menstrual disorders due to isthmocele. *Gynecol Endocrinol*. 2011; 27: 434-438.
- [20] Tower AM, Frishman GN. Cesarean scar defects: an under recognized cause of abnormal uterine bleeding and other gynecologic complications. *JMIG*. 2013 Sept- Oct; 20(5): 562-572.
- [21] Zeirideen R. Should Laparoscopy be the Gold Standard of Isthmocele ?*World Journal Laparoscopic Surgery*. September-december 2016; 9(3): 118-121.

- [22] Klemm P, Koehler C, Mangler M, Schenider U, Schneider A. Laparoscopic and vaginal repair of uterine scar dehiscence following cesarean section as detected by ultrasound. *J perinatal Med*. 2005; 33: 324-31.
- [23] Stewart KS, Evans TW. Recurrent bleeding from the lower segment scar--a late complication of Caesarean section. *Br J Obstet Gynaecol*. 1975; 82: 682-686.
- [24] Thurmond AS, Harvey WJ, Smith SA. Cesarean section scar as a cause of abnormal vaginal bleeding: Diagnosis by sonohysterography. *J Ultrasound Med*. 1999 Jan; 18(1): 13-16.
- [25] Marotta MI, Donnez J, Squifflet J et al. Laparoscopic repair of post-cesarean section uterine scar defects diagnosed in non pregnant women. *J Minim Invasive Gynecol*. 2013; 20: 386-391.
- [26] Tanimura S, Funamoto H, Hosono T et al. New diagnostic criteria and operative strategy for cesarean scar syndrome. Endoscopic repair for secondary infertility caused by cesarean scar defect. *J Obstet Gynecol res*. 2015; 41: 1363-9.
- [27] Urman B, Arslan T, Aksu S, Taskiran C. Laparoscopic repair of cesarean scar defect "isthmocoele". *J Minim Invasive Gynecol*. 2016; 23(6): 857-8.
- [28] Van der Voet LF, Vervoort AJ, Veersema S, Bij de Vaate AJ, Brölmann HA, Huirne JA. Minimally invasive therapy for gynaecological symptoms related to a niche in the caesarean scar: a systematic review. *BJOG*. 2014; 121: 145-156.
- [29] Li C, Tang S, Gao X, et al. Efficacy of combined laparoscopic and hysteroscopic repair of post-cesarean section uterine diverticulum: A retrospective analysis. *Biomed Research International*. 2016; 2016: 1765624. DOI: 10.1155/2016/1765624.
- [30] Gubbini G, Casadio P, Franchini M. Small Size Resectoscope in Isthmocoele repair: Case Report. *Obstet Gynecol Int J*. 2017 7(5) : 00262. DOI:10.15406/ogij.2017.07.00262.
- [31] Donnez O, Donnez J, Orellana R, Dolmans MM. Gynecological and obstetrical outcomes after laparoscopic repair of cesarean scar defect in a series of 38 women. *Fertil Steril*. 2017 107(1): 289-296.
- [32] Luo L, Niu G, Wang Q, Xie HZ, Yao SZ. Vaginal repair of cesarean section scar diverticula. *J Minim Invasive Gynecol*. 2012 19(4): 454-458.
- [33] Yalcinkaya TM, Akar ME, Kammire LD, Johnston-Macananny EB, Mertz HL. Robotic assisted laparoscopic repair of symptomatic cesarean scar defect: a report of two cases. *J Reprod Med*. 2011; 56(5-6): 265-270.
- [34] Setubal A, Alves J, Osorio F, et al. Treatment of uterine Isthmocoele. A pouch like defect at the Site of a Cesarean Section Scar. *Journal of minimally Invasive Gynecology*. September 5, 2017. DOI:10.1016/j.jmig.2017.09.022.
- [35] Jacobson MT, Osias J, Velasco A, Charles R, Nezhat C. Laparoscopic repair of a utero-peritoneal fistula. *JSLs*. 2003; 7: 367-369.
- [36] Donnez O, Jadoul P, Squifflet J, Donnez J. Laparoscopic repair of wide and deep uterine scar dehiscence after cesarean section. *Fertil Steril*. 2008; 89: 974-980.
- [37] Zhang X, Wu C, Yang M et al. Laparoscopic repair of cesarean section scar defect and surgical outcome in 146 patients. *Int J Clin Exp Med*. 2017; 10(3): 4408-4416.
- [38] Bakaviciute G, Spiliauskaite S, Meskauskiene A, Ramasaukaite D. Laparoscopic repair of the uterine scar defect- successful treatment of secondary infertility: a case report and literature review. *Acta medica lituanica*. 2016. Vol. 23. No. 4. P.227-2231.
- [39] Surgical Tutorial 5 : Isthmocoele. Presented in the 45th global congress AAGL; November 14 - 18, 2016; Orlando Florida,
- [40] Nirgianakis K, Oehler R, Mueller M. "Le Rendez-vous technique for treatment of caesarean scar defects: a novel combined endoscopic approach," *Surgical Endoscopy*. 2016; vol. 30, no. 2, pp. 770-771.
- [41] Liu S, Ly W, Li W. Laparoscopic repair with hysteroscopy of cesarean scar diverticulum. *J Obstet Gynaecol Res*. 2016; 42: 1719-1723.
- [42] Fabres C, Arriagada P, Fernandez C et al. Surgical treatment and follow-up of women with intermenstrual bleeding due to Cesarean section scar defect. *Journal of Minimally Invasive Gynecology*. 2005; 12, 25-28.
- [43] Raimondo G, Grifone G, Raimondo D, et al. Hysteroscopic treatment of symptomatic cesarean induced isthmocoele: A prospective study. *J Minim Invasive Gynecol*. 2015 22(2): 297-301
- [44] Xie H, Wu Y, Yu F, He M, Cao M, Yao S. A comparison of vaginal surgery and operative hysteroscopy for the treatment of cesarean-induced isthmocoele: a retrospective review. *Gynecol Obstet Invest*. 2014; 77: 78-83.
- [45] Zhang X, Yang M, Wang Q, Chen J, Ding J, Hua K. Prospective evaluation of five methods used to treat cesarean scar defects. *Int J Gynaecol Obstet*. 2016; 134: 336-339.
- [46] Zhang Y. A comparative study of transvaginal repair and laparoscopic repair in the management of patients with previous cesarean scar defect. *J Minim Invasive Gynecol*. 2016; 23: 535-541.
- [47] Mahmoud MS, Nezhat FR. Robotic - assisted laparoscopic repair of a cesarean section scar defect. *J Minim Invasive Gynecol*. 2015; 22(7): 1135-6.
- [48] Schepker N, Garcia-Rocha GJ, von Versen-Hoynck F, Hillemanns P, Schippert C. Clinical diagnosis and therapy of uterine scar defects after caesarean section in non-pregnant women. *Arch Gynecol Obstet*. 2015; 291: 1417-1423.
- [49] Chang Y, Tsay EM, Long CY, Lee CY, Kay N. Resectoscopic treatment combined with sonohysterographic evaluation of women with post menstrual bleeding as a result of previous cesarean delivery. *Am J Obstet Gynecol*. 2016 200(4): 370.e1-370.e4.
- [50] Li C, Guo Y, Liu Y, Cheng J, Zhang W. Hysteroscopic and laparoscopic management of uterine defects on previous cesarean delivery scars. *J Perinat Med* 2014 42(3): 363-370.
- [51] Chen H, Yao J, Wang X. Surgery experience is transvaginal cesarean section diverticulum (CSD) repair. *Gynecol Minim Invas Ther*. 2016 5: 148-151.
- [52] Gubbini G, Centini G, Nascetti d, Marra E, et al. Surgical hysteroscopic treatment of cesarean-induced isthmocoele in restoring fertility: a prospective study. *J Minim Invasive Gynecol*. 2011; 18: 234-237.

- [53] Api M, Boza A, Gorgen H, Api O. Should cesarean sac defect be treated laparoscopically ? A case report and review of the literature. *J Minim Invasive Gynecol.* 2015; 22(7): 1145-1152.
- [54] Vervoort AJ, Uittenbogaard LB, Hehenkamp WJK, Brolman HAM, Mol BWJ, Huirne JAF. Why do niches develop in cesarean uterine scars? Hypotheses on the etiology of niche development. *Human reprod.* 2015; Dec; 30(12): 2695-2702.
- [55] Chen Y, Chang Y, Yao S. Transvaginal management of cesarean scar section diverticulum: a novel surgical treatment. *Med Sci Monit.* 2014; 20: 1395–9.
- [56] Dodd JM, Anderson ER, Gates S, Grivell RM. Surgical techniques for uterine incision and uterine closure at the time of caesarean section. *Cochrane Database Syst Rev.* 2014; 7: CD004732.
- [57] Fabres A, Aviles G, De la Jara C et al. The cesarean delivery scar pouch: clinical implications and diagnostic correlation between transvaginal sonography and hysteroscopy. *J Ultrasound Med.* 2003; 22 (7): 695-700.