

Case Report

Heart Disease Associated with COVID-19 in Children

Emilia Alonso Zurmendi^{1,*}, Federica Badía De Ferrari¹, Maren Karina Machado Echeverría¹, Mariangel Ospitaleche², María Catalina Pirez García¹

¹Pediatric Clinic “A”, University of the Republic School of Medicine, Montevideo, Uruguay

²Departmental Hospital of Rivera State Health Services Administration, Rivera, Uruguay

Email address:

emilia.alonso1@gmail.com (E. A. Zurmendi)

*Corresponding author

To cite this article:

Emilia Alonso Zurmendi, Federica Badía De Ferrari, Maren Karina Machado Echeverría, Mariangel Ospitaleche, María Catalina Pirez García. Heart Disease Associated with COVID-19 in Children. *Central African Journal of Public Health*. Vol. 7, No. 5, 2021, pp. 245-249.

doi: 10.11648/j.cajph.20210705.12

Received: September 30, 2021; Accepted: October 21, 2021; Published: October 30, 2021

Abstract: Introduction: Heart disease in children associated with COVID-19 is described during acute infection or in the context of the Multisystem inflammatory syndrome in children (MIS-C), and in patients with and without previous heart disease. It has different manifestations: asymptomatic, with alterations in complementary tests (elevated troponins, arrhythmias, imaging changes), up to severe forms: myocardial infarction, heart failure, cardiogenic shock, sudden death. We report a schoolgirl who had severe COVID-19, with cardiac, digestive, and respiratory manifestations. Clinical case: 10-year-old girl, carrier of disabling chronic disease. In the course of severe COVID-19, she added shock and respiratory failure, elevated inflammatory markers, increased troponins, and dilated cardiac cavities, with functional compromise of the left ventricle. She received non-invasive ventilatory assistance, antibiotics, and systemic corticosteroids. Cardiac manifestations reversed, with a decrease in inflammatory parameters. Discussion: The heart is frequently affected in COVID-19. Cardiac injury may be due to: viral replication, systemic inflammatory response, respiratory failure, or myocardial stress. The severity will depend on the extent of the damage and the inflammatory response. Cardiac involvement is more common in those who meet MIS-C criteria. Most recover cardiac function. The case report contributes to the knowledge of SARS-CoV-2 infection, and the severe forms of presentation with cardiac involvement in children highlight the need to advance in primary prevention by vaccines in the pediatric population.

Keywords: Cardiac Disease, Children, COVID-19, SARS-CoV-2

1. Introduction

In Uruguay, the SARS-CoV-2 virus infection reached a maximum incidence of 149.5 cases/100,000 inhabitants. Children under 15 years of age have a cumulative incidence of 5908.6/100,000 [1].

COVID-19 in children usually has an asymptomatic course, or with mild symptoms. Among the severe forms, the Multisystem inflammatory syndrome in children (MIS-C) stands out [2, 3].

Children's heart disease (CHD) associated with COVID-19, is described during acute infection, or in patients with MIS-C. It develops in children with and without previous heart disease

[4, 5]. It has different manifestations [6, 7]: asymptomatic, with abnormal complementary tests (elevated troponins, arrhythmias, imaging alterations), and even severe forms: myocardial infarction, heart failure, cardiogenic shock, sudden death [6, 7].

We report a school age girl, who carries a disabling chronic disease, that suffers a severe COVID-19, with cardiac, respiratory and digestive manifestations.

2. Clinical Case

A 10-year-old girl, hospitalized in January 2021, from a region with a Harvard index of 38.03. Carrier of merosin deficient congenital muscular dystrophy (Gene LAMA2):

Complementary studies: chest radiograph with inhomogeneous opacity in the right hemithorax (Figure 1). chest computed tomography: consolidation with air bronchogram in upper and lower lobes, mild right pleural effusion (Figure 2). Venous blood gases: severe metabolic acidosis; inflammatory markers: leukocytosis ($46,100 / \text{mm}^3$), neutrophilia (85.7%), ferritin (141.6 ng / ml), D-dimers (0.27 mg / L), C-reactive protein (20 mg / L) and erythrocyte sedimentation rate (20 mm / h). Troponins: 220 ng / L (Table 1). Electrocardiogram: sinus tachycardia. Echocardiogram: ventricles of normal morphology and size, left ventricular ejection fraction (LVEF) 65%, absence of pericardial effusion.

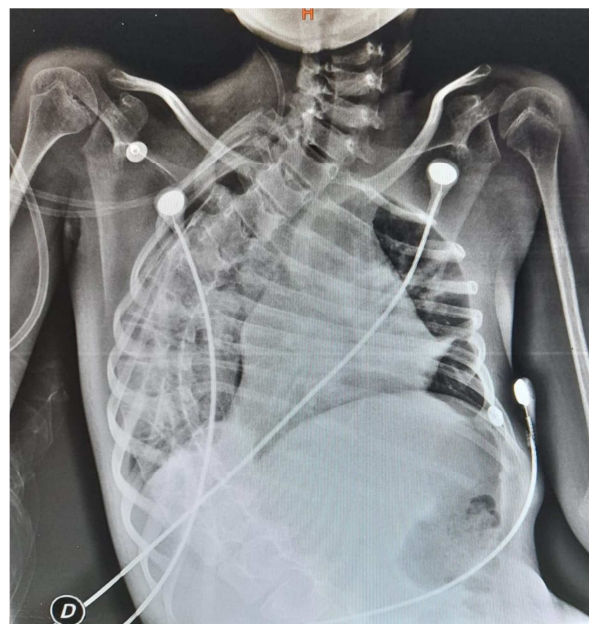


Table 1. 10-year-old female. Carrier of muscular dystrophy. Severe COVID-19 with digestive, respiratory and cardiac manifestations. Evolution of complementary studies, clinical manifestations and administered treatment.

[illegible]

	Domicile	Local hospital second level of care			Intensive Therapy Unit	Moderate care
CK-MB (U/L)						33
Images		Rx Tx: HTx right consolidation	TC Tx: consolidation and right HTx pleural effusion			
Clinical manifestations	Dry cough	Abdominal pain, vomiting, shock CN oxygen Glucose serum Bicarbonated serum Ceftriaxone	Abdominal pain, work of breathing	Abdominal distension Polypnea increase	Clinical improvement	
Treatment			Salbutamol Hydrocortisone	Methylprednisolone Vancomycin CNAF	VNI BiPAP IECA HBPM	AAS

CRP¹: C-reactive protein. PCT: procalcitonin. VES: erythrocyte sedimentation rate. LDH: lactate dehydrogenase. PCR²: polymerase chain reaction. CK-T: creatine kinase. CK-MB: creatine kinase MB. N%: percentage of neutrophils. L%: percentage of lymphocytes. LVEF: left ventricular ejection fraction. CXR: chest x-ray. HTx: hemithorax. CT Tx: chest tomography. CN: nasal cannula. CNAF: high flow nasal cannula. NIV: non-invasive ventilation. BiPAP - Bi-level positive airway pressure. ACEI: angiotensin converting enzyme inhibitor. LMWH: low molecular weight heparin. ASA: acetylsalicylic acid.

She persisted with tachycardia, intense abdominal pain, and short breathing, without fever. Blood gases: respiratory acidosis with hypercapnia. A high-flow nasal cannula was placed. Vancomycin was associated. She received 6 doses of hydrocortisone and 1 dose of methylprednisolone for suspected severe COVID-19 pneumonia.

She was admitted to the intensive care unit (ICU). NIV with double-level positive pressure was required for respiratory improvement. Troponins increased to 662.6 ng / L. RT-PCR for SARS-CoV-2 on day 14 was negative. Hemodynamics remained stable. Electrocardiogram: sinus tachycardia. Echocardiogram: moderate cardiomegaly, LVEF 48%, mild pericardial effusion Treatment: angiotensin converting enzyme inhibitors and low molecular weight heparin (isocoagulation). She did not receive vasoactive drugs. Troponin decreased to 206.7 ng/L on day 17.

Remained in the ICU for 72 hours, and discharged from hospital after 12 days, on the 21st day of illness, with decreased inflammatory markers, negative troponins, and normal echocardiogram. Vasodilators and anticoagulants were suspended, acetylsalicylic acid was indicated. SARS-CoV-2 antibodies were positive 29 days after diagnosis.

3. Discussion

The clinical case presented was a COVID-19 disease with myocarditis, pericarditis and pneumonia in a girl with underline disease (merosin deficient congenital muscular dystrophy) with chronic lung disease.

The pediatric population represents 2% to 5% of confirmed cases of SARS-CoV-2 infection [4]. In reports of the Centers for Disease Control and Prevention of the United States, in February 2021, 1.9% of the cases were children between 0 and 4 years old, and 9.4% between 5 and 17 years [8].

Approximately 3% of children with COVID-19 require treatment or critical care [2, 9]. A review that analyzed 7780 cases in children, severe forms included: 42 (0.54%) ventilatory assistance, 19 (0.24%) shock, 11 (0.14%) MIS-C,

8 (0.10%) myocardial injury without MIS-C criteria, and 7 (0.09%) died [9].

The risk in children with comorbidities of suffering severe COVID-19 is not well established [9]. It's described that carriers of cardiac, respiratory, or immunological disorder, are more susceptible to develop severe disease [5].

Cardiac involvement is reported in the course of SARS-CoV-2 infection, in acute phase or with MIS-C [4, 10]. Up to 34% of the children admitted to the ICU in Spain had cardiac involvement, the majority with MIS-C criteria [4].

This communication presents a patient with severe chronic lung disease, carrier of myopathy, without heart disease, who had a severe form of COVID-19. She presented with shock, elevated inflammatory markers and cardiac involvement, between days 10 and 14 of infection, in apyrexial, without criteria for MIS-C. Elevated troponins, moderate cardiomegaly, decreased LVEF, and the presence of pericardial effusion elucidate the cardiac injury.

This clinical presentation of COVID-19 with rapid resolution of the cardiac and lung affection in children with underlying diseases is reported. The girl didn't meet criteria for MIS-C.

The heart is the second target organ for SARS-CoV-2 virus, after the lungs. Cardiac involvement without MIS-C criteria is described. It can manifest with markers of myocardial injury or with structural and functional damage [11]. It's proposed that cardiac injury can be produced by: viral replication in the myocardium, secondary to systemic inflammatory response, or respiratory failure and myocardial stress in the setting of severe disease [6, 10, 11]. The severity will depend on the extent of damage and levels of inflammatory mediators. In published reviews, improvement in LVEF is observed together with a decrease in troponins and interleukin-6 [11].

In the review published in February 2021 by Feldstein et al, clinical characteristics and outcome of patients under 21 years of age with severe COVID-19 and MIS-C are compared. Cardiac involvement was observed in both groups, more frequently in those who met MIS-C criteria [12]. In patients

with severe COVID, depress LVEF was observed in 5.4% of patients that underwent echocardiography evaluation [12].

Our patient presented non-severe and reversible myocardial dysfunction, with recovery of LVEF and troponin values, associated with a decrease in inflammatory markers.

Patients with severe SARS-CoV-2 infection present immune dysregulation, with an imbalance between host response and virus evasion mechanisms [13]. The kinetics of the immune response and the triggering of pro-inflammatory pathways lead to a phenomenon of "hyperinflammation" or "cytokine storm" [13].

Early diagnosis and prompt initiation of anti-inflammatory treatment is crucial for the success, speed, and recovery of cardiac involvement [4].

This patient received treatment with hydrocortisone and methylprednisolone, which could have influenced her evolution. Due to their anti-inflammatory action, corticosteroids are recognized as adjuvants for the cytokine storm associated with COVID-19. Observational studies show inconclusive results and moderate clinical benefit [13].

Regarding its genetic disease, the variety of muscular dystrophy that it presents can associate cardiac anomalies, but when it is installed, it is irreversible [14].

4. Conclusions

This patient presented a severe COVID-19, with reversible cardiac involvement, with LVEF recovery and normalization of injury markers after 21 days of confirmed infection.

Understanding the role of inflammation in the pathogenesis of this entity allows the early recognition of symptoms and the opportunity of treatment, which conditions the patient's outcome.

Case reports contribute to the knowledge of severe SARS-CoV-2 infection, and cardiac involvement in children. This highlights the need to advance in primary prevention by vaccines in the pediatric population.

Declaration

The authors declare that they have no conflicts of interest.

Authors' Contribution

Emilia Alonso Zurmendi, Participation: Conception, Execution, Writing, Analysis and Critical Review. Federica Badía Ferrari, Participation: Conception, Execution, Writing, Analysis and Critical Review. Maren Karina Machado Echeverría, Participation: Conception, Execution, Writing, Analysis and Critical Review. Mariangel Ospitaleche Rosas, Participation: Conception and Execution. María Catalina Pirez García, Participation: Conception, Execution, Writing, Analysis and Critical Review

Acknowledgements

Octavio Ramilo MD for his contribution in the discussion

of this case, the understanding of this pathology and review of the bibliography.

References

- [1] COVID-19 epidemiological report. Update to June 15, 2021. General Directorate of Health. Epidemiological division. Health Surveillance Department. Ministry of Public Health. Available in: <https://www.gub.uy/ministerio-salud-publica/comunicacion/noticias/informe-epidemiologico-COVID-19-actualizado-3-junio-2021#>.
- [2] Guo CX, He L, Yin J-Y, Meng X-G, Tan W, Yang GP, et al. Epidemiological and clinical features of pediatric COVID-19. *BMC Medicine*. 2020; 18: 250.
- [3] Hoanga A, Choratha K, Moreirab A, Evansa M, Burmeister-Mortona F, Burmeistera F, et al. COVID-19 in 7780 pediatric patients: A systematic review. *EClinicalMedicine*. 2020; 24: 100433.
- [4] Sanna G, Serrau G, Bassareo PP, Neroni P, Fanos V, Marcialis MA. Children's heart and COVID-19: Up-to-date evidence in the form of a systematic review. *Eur J Pediatr*. 2020; 179: 1079–1087. <https://doi.org/10.1007/s00431-020-03699-0>.
- [5] Valverde et al. Acute Cardiovascular Manifestations in 286 Children With Multisystem Inflammatory Syndrome Associated With COVID-19 Infection in Europe. *Circulation*. 2021; 143: 21–32. DOI: 10.1161/CIRCULATIONAHA.120.050065.
- [6] Rodriguez-Gonzalez M, Castellano-Martinez A, Cascales-Poyatos HM, Perez Reviriego AA. Cardiovascular impact of COVID-19 with a focus on children: A systematic review. *World J Clin Cases* 2020; 8 (21): 5250-5283.
- [7] Tsankov BK, Allaire JM, Irvine MA, Lopez AA, Sauvé LJ, Vallance BA, et al. Severe COVID-19 Infection and Pediatric Comorbidities: A Systematic Review and Meta-Analysis. *Int J Infect Dis*. 2021 Feb; 103: 246-256. doi: 10.1016/j.ijid.2020.11.163. Epub 2020 Nov 20. PMID: 33227520; PMCID: PMC7679116.
- [8] Caforio ALP. Coronavirus disease 2019 (COVID-19): Cardiac manifestations in adults. En: UpToDate, Post TW (Ed), UpToDate, Waltham, MA. (Consultado el 22 de febrero de 2021).
- [9] ACC Clinical Bulletin. COVID-19 Clinical Guidance For the Cardiovascular Care Team. Expert advisors: Mohammad Madjid, Scott D Solomon, Orly Vardeny. March 6, 2020.
- [10] Centers for Disease Control and Prevention, COVID-19 Response. Access to public surveillance data for COVID-19 cases, summary and limitations (version date: January 31, 2021).
- [11] Zeng JH, Liu YX, Yuan J, Wang FX, Wu WB, Li JX, et al. First case of COVID-19 complicated with fulminant myocarditis: a case report and insights. *Infection*. 2020; 48 (5): 773-777. doi: 10.1007/s15010-020-01424-5.
- [12] Wang D, Li S, Jiang J, Yan J, Zhao C, Wang Y, et al. Chinese society of cardiology expert consensus statement on the diagnosis and treatment of adult fulminant myocarditis. *Sci China Life Sci*. 2019; 62 (2): 187–202. <https://doi.org/10.1007/s11427-018-9385-3>.

- [13] Vabret N, Britton GJ, Gruber C, Hegde S, Kim J, Kuksin M, et al. Immunology of COVID-19: current state of the science. *Immunity* 2020; 52: 910-41. doi: 10.1016/j.immuni.2020.05.002.
- [14] Nguyen Q, Lim KRQ, Yokota T. Comprensión actual y tratamiento de la patología del músculo cardíaco y esquelético en la distrofia muscular congénita con deficiencia de cadena de laminina- α 2. *Appl Clin Genet*. 2019; 12: 113-130. <https://doi.org/10.2147/TACG.S187481>.
- [15] Feldstein LR, Tenforde MW, Friedman KG, Newhams M, Billig Rose E, Dapul H, et al. Characteristics and Outcomes of US Children and Adolescents With Multisystem Inflammatory Syndrome in Children (MIS-C) Compared With Severe Acute COVID-19. *JAMA*. 2021 Feb 24. doi: 10.1001/jama.2021.2091.