

## Case Report

# Rare Cause of Facial Nerve Palsy (Petrous Apex Cholesteatoma)–Case Report and Review of Literature

Rauf Ahmed, Owais Makhdoomi, Omar Mohammad Shafi, Faheem Khalid\*

Department of ENT and HNS, Government Medical College, Srinagar Jammu & Kashmir, India

### Email address:

Drfaheem35376@gmail.com (F. Khalid)

### To cite this article:

Rauf Ahmed, Owais Makhdoomi, Omar Mohammad Shafi, Faheem Khalid. Rare Cause of Facial Nerve Palsy (Petrous Apex Cholesteatoma)–Case Report and Review of Literature. *Clinical Neurology and Neuroscience*. Vol. 3, No. 1, 2019, pp. 1-5. doi: 10.11648/j.cnn.20190301.11

Received: January 9, 2019; Accepted: April 1, 2019; Published: May 11, 2019

**Abstract:** The petrous apex is a pyramid-shaped structure that is formed by the medial portions of the temporal bone. It is obliquely positioned within the skull base, with its apex pointing anteromedially and its base located posterolaterally. The petrous apex is bounded by the inner ear structures laterally, the petro-occipital fissure medially, the petrosphenoidal fissure and ICA anteriorly, and the posterior cranial fossa behind. Given its location, the petrous apex is susceptible to multiple pathologic processes which may be Inflammatory, developmental, vascular, benign and malignant lesions. We present a rare case of a 39 year old Male who presented with unilateral facial nerve palsy and sensorineural hearing loss and was then diagnosed as petrous apex Cholesteatoma. Patient was treated surgically by Transcholear translabrynth technique.

**Keywords:** Cholesteatoma, Facial Nerve Palsy, Petrous Apex

## 1. Introduction

The petrous apex is a pyramid-shaped structure that is formed by the medial portions of the temporal bone. Petrous apex is anatomically a complex structure due to its medial location in the skull base and its intimate relationship to other clinically important structures including the cavernous sinus, Dorello canal, and Meckel cave. The petrous apex represents a unique intersection between the suprahyoid neck and the intracranial compartment. Hence, the petrous apex is susceptible to a variety of pathologic processes. Clinical presentations of these lesions, therefore, can be quite variable and depend largely on involvement of numerous intimately adjacent intra- and extra cranial structures, especially the cranial nerves. Besides clinical examination of the patient, different radiological investigations help us in definite diagnosis of a specific lesion.

## 2. Case Report

A 39 year old Male presented with complaints of Decreased hearing Left ear for 2 years, Inability to close left eye for 6 months and Tinnitus left ear for 6 months. He noticed left sided facial asymmetry 6 months back, which progressed to

complete facial nerve palsy. At the time of presentation patient had no systemic disease. On general examination, the patient had grade IV facial nerve palsy (Figure 1). Taste Sensation and lacrimation on ipsilateral side was decreased. Schirmer's test done showed less than 5 on schirmer's strip. Examination of other cranial nerves was normal. On otoendoscopic examination, patient had Grade 1 retraction on left side and the right ear was normal. (Figure 2) Pure tone audiogram done showed profound Sensorineural hearing loss in Left ear. (Figure 3) Patient had no significant past history. Routine hematological tests were within the normal limits.

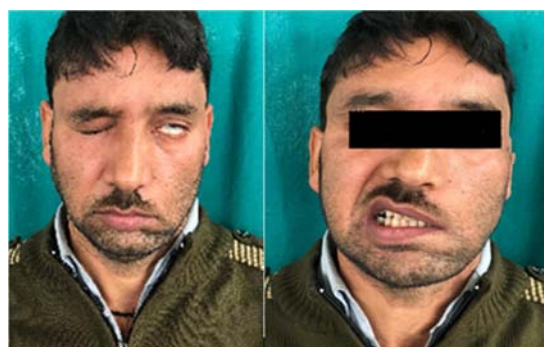

Figure 1. Facial nerve Palsy.

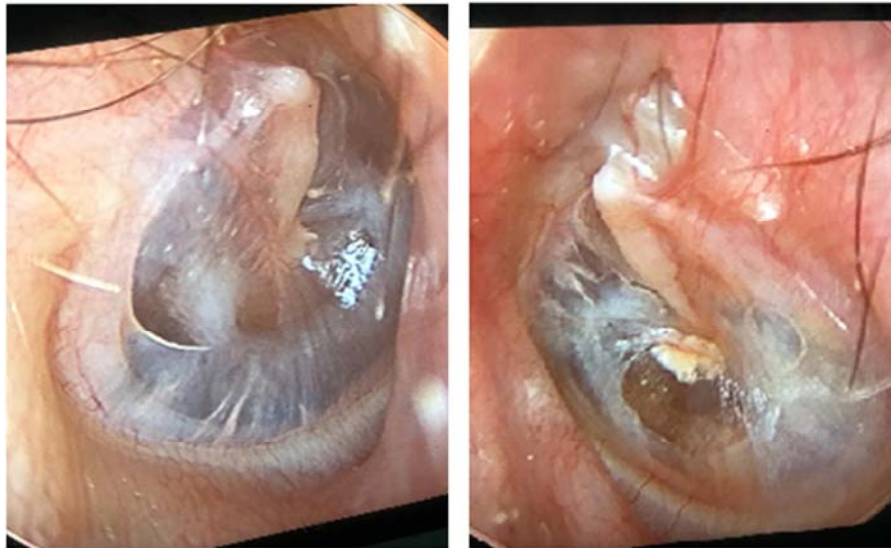


Figure 2. Right Ear Otoendoscopic view Left Ear.

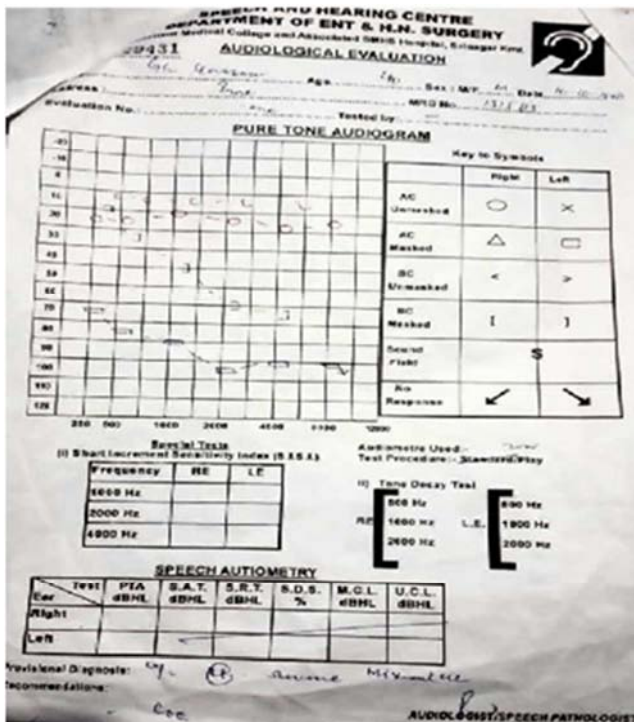
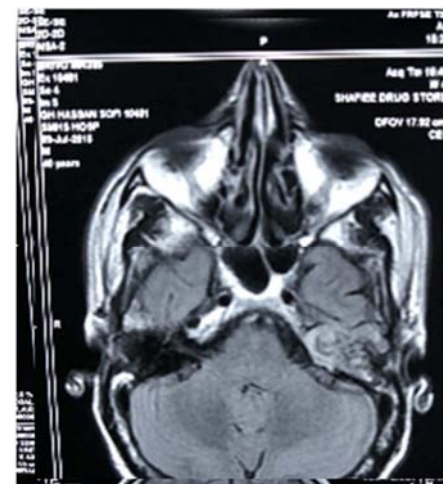


Figure 3. Pure Tone Audiometry.

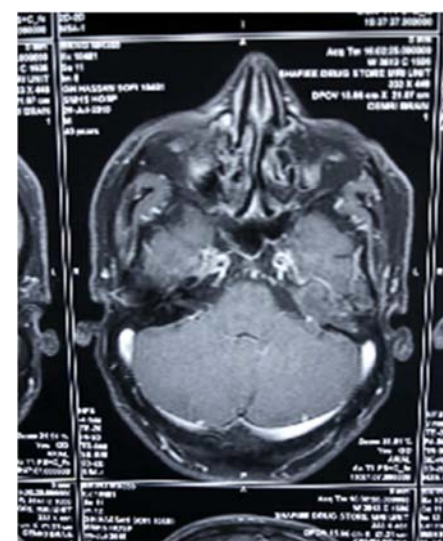
### 3. Investigations

Radiographic investigations were carried out to confirm type and extent of the lesion.

CEMRI was done which showed evidence of 32\*20\*13 mm expansile soft tissue lesion involving petrous part of Left Temporal bone with no significant post contrast enhancement. Lesion was causing erosion of tegmen tympani, posterior cortex of Petrous bone, head of malleus, body of incus and extending into internal auditory canal, vestibule, middle turn of cochlea and facial nerve canal. No enhancement was seen on T1 post contrast.



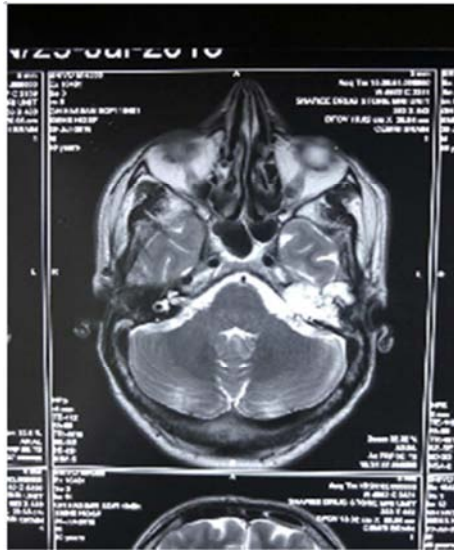
T1 NON CONTRAST



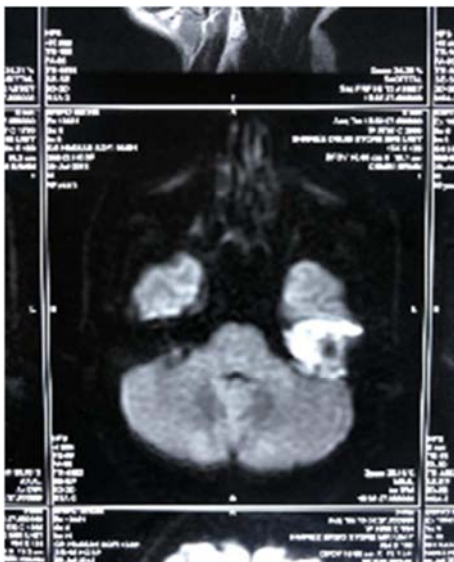T1 POST CONTRAST (NO ENHANCMENT)

Figure 4. Contrast Enhanced MRI.





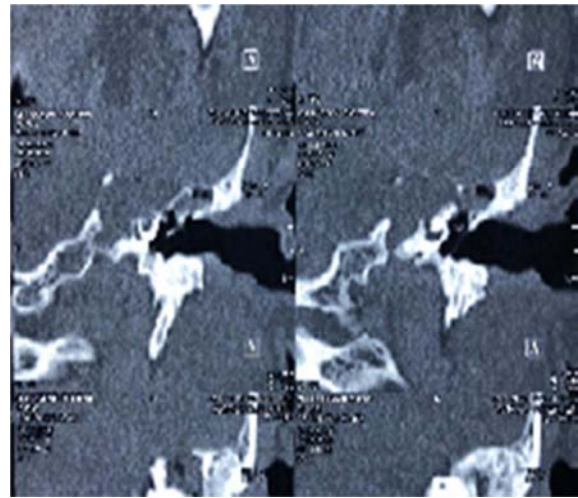
T2



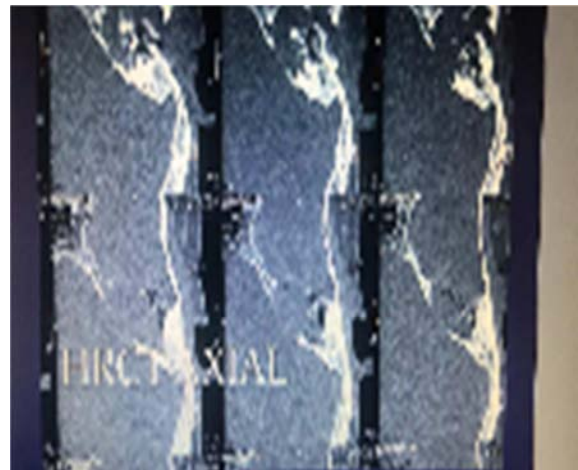
DWI IMAGE

Figure 5. T2 and DWI imaging.

HRCT Temporal bone was done which showed lesion involving petrous part of temporal bone on left side extending through epitympanum causing erosion tegmen tympani, head of malleus and body of incus.



CORONAL VIEW



AXIAL VIEW

Figure 6. HRCT Temporal bone.

Table 1. Imaging features of petrous apex lesions.

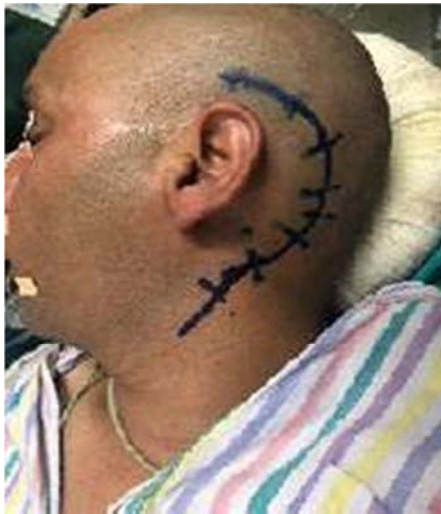Petrous apex lesion	MRI T1 W	MRI T2W	Other MRI Features	CT
Schwannoma	Isointense to brain	Hypo or Hyperintense	Homogenous enhancement	Expansile, minimally erosive, isodense
Mucocele	Isointense or hyperintense (depends on protein conc)	Hyperintense	Peripheral enhancement	Destroyed septa
Chondrosarcoma	Isointense	Hyperintense	Avid enhancement	Destroys bone, Ring and arc appearance
Cholesteatoma	Hypointense	Hyperintense	No enhancement, DWI shows restricted diffusion	Smooth erosion of bone

## 4. Treatment

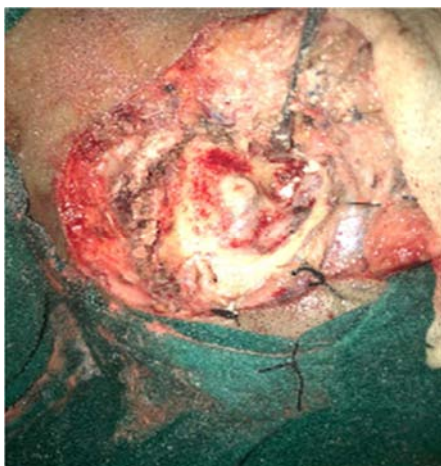Surgical removal of the petrous apex Cholesteatoma was done. Transchochlear translabyrinthine approach was followed. Cul de sac closure was done. Bills Island was created. (Figure 6, 7) Cholesteatoma was seen eroding Tegmen plate, and going

deep to sigmoid sinus plate. It was also seen reaching deep to anterior wall close to carotid artery, Eustachian tube, root of zygoma, and was seen reaching to trautmans triangle and petrous apex over posterior fossa dura. Facial nerve was seen to be non viable in labyrinthine segment. All the efforts were taken towards complete surgical removal of Cholesteatoma. Obliteration of the cavity was done using abdominal fat. Post

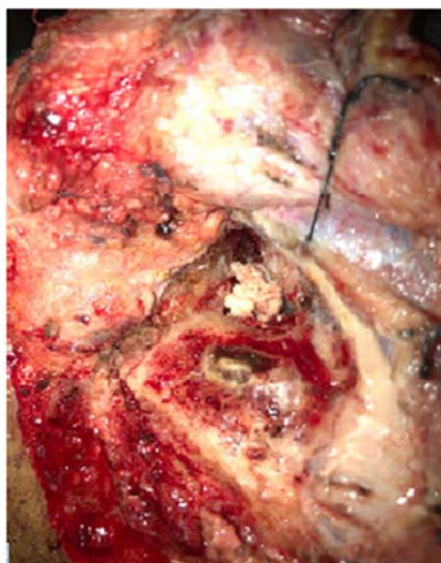operatively patient was relieved of tinnitus. Facial paralysis and hearing didn't improve and was same as pre operative. Histopathology was suggestive of Cholesteatoma.



**Figure 7.** Shows site of Incision.



**Figure 8.** (Bills island).



**Figure 9.** Intra op findings.

## 5. Discussion

Congenital Cholesteatoma of petrous apex is rare. Cholesteatoma of petrous apex has two different origins, congenital, and acquired. Congenital Cholesteatoma is believed to arise from squamous cell rest. [1] In fetal life there is a close relation of tympanic ring with internal auditory canal that makes migration of external canal ectoderm possible. 83-94% presents with sensorineural hearing loss and 20-25% presents with lower motor neuron facial paralysis. Imaging techniques have critical roles on management and surgical outcome of petrous apex Cholesteatoma. Computed Tomography and MRI are the best modalities for definition of petrous apex lesions, differential diagnosis or making a decision for surgical approach and to see the recurrences. On temporal bone CT, there is a smooth expansile lesion of the petrous apex. The central portions of the lesion shows no calcification or bony matrix. On MRI, Cholesteatoma typically is hypo intense on T1, hyper intense on T2, And intermediate in signal on FLAIR images (12). Diffusion restriction is reported to be characteristic of this lesion. After contrast administration, there may be subtle peripheral rim enhancement. [2, 3] Diffusion-weighted imaging is useful in diagnosis of Cholesteatoma, as the lesions often show restricted diffusion, a feature that can be particularly beneficial in detection of recurrent Cholesteatoma after surgical resection. Pandya *et al* [4] described some points that must be taken into considerations when treating patient with petrous apex Cholesteatoma. These are

- i Complete eradication of the disease
- ii Preservation of facial nerve function
- iii Prevention of CSF leakage and meningitides; and
- iv Cavity obliteration.

(10) Hearing preservation is not the primary aim of treatment after radical removal of Cholesteatoma. Tran mastoid Tran labyrinthine approach with or without Tran cochlear approach is the basic surgery for removal. However these approaches are insufficient to remove Cholesteatoma situated deep in petrous apex and adherent to middle cranial fossa dura so middle cranial fossa approach is advised for such cases. [5] Despite use of different surgical techniques, recurrence is still a big problem. The most important reasons for this problem are incomplete removal of Cholesteatoma because of critical structures like dura, facial nerve, carotid artery etc. Therefore, an endoscopic examination with 30 degree and/or 45 degree endoscopes should be done after removing the Cholesteatoma in terms of residual Cholesteatoma. [6, 8, 9] Generally, it is hard to preserve hearing level in transotic approach, Trans labyrinthine or Tran's cochlear approaches. The aim of complete eradication of disease necessitates sacrificing the labyrinth. When facial nerve is damaged in extensive Cholesteatoma of petrous apex, literature suggests even sacrificing official nerve which has residual function for complete eradication. [7, 10, 11]

## 6. Conclusion

It is hard to manage the Cholesteatoma located in petrous

part of temporal bone because of vital structures. So that, advanced imaging techniques are required for describing the pathology and planning the surgical approach. In addition, a proper classification depending on extent of pathology should be done before the surgery and patient should be informed about surgical outcomes.

## References

- [1] Torun F, Taficiolu A, Tuna H. Primary petrous apex Cholesteatoma: A case report. *Turk Neurosurg* 2004; 14: 28-32.
- [2] Connor SE, Leung R, Natas S (2008) Imaging of the petrous apex: a pictorial view *Br J Radiol* 81: 427-435.
- [3] Pisaneschi MJ, Langer B. Congenital Cholesteatoma and cholesterol granuloma of the temporal bone: role of magnetic resonance imaging. *Top Magn Reson Imaging* 2000; 11: 87-97.
- [4] Pandya Y, Piccirillo E, Mancini F, Sanna M (2010) Management of complex cases of petrous bone Cholesteatoma. *Ann Otol Rhinol Laryngol* 119 (8) 5d 14-525.
- [5] Achilli V, Danesi G, Caverni L, Richichi M. Petrous apex arachnoid cyst: A case report and review of the literature. *Acta Otorhinolaryngol Ital* 2005; 25: 296-300.
- [6] Mete I, Sebla C, Ahmet K. Petrous Bone Cholesteatoma: Classification, Management and Review of the Literature. *Glob J Oto*, 2018; 16(4): 555-945.
- [7] Komune S, Nakagawa T, Haruta A, Matsuda K, Tono T. Management of cholesteatoma in the petrous apex. *Skull Base Surg* 2000; 10: 47-51.
- [8] Danesi G, Cooper T, Panciera DT, Manni V, Cote DW (2016) Sanna classification and prognosis of cholesteatoma of the petrous part of the temporal bone: A retrospective series of 81 patients. *Otol Neurotol* 37(6): 787-792.
- [9] Sanna M, Pandya Y, Mancini F, Sequino G, Piccirillo E (2011) Petrous bone cholesteatoma: classification, management and review of the literature. *Audiol Neurotol* 16(2): 124-136.
- [10] Kim MJ, An YS, Jang MS, Cho YS, Chung JW (2014) Hearing and facial function after surgical removal of cholesteatomas involving petrous bone. *Clin Exp Otorhinolaryngol* 7(4): 264-268.
- [11] F. Banaz, I. Edem, D. Moldovan, S. Kilty, G. Jansen, F. Alkherayf: Chondrosarcoma in Petrous Apex: Case Report and Review. *J Neurol Surg Rep*. 2018 Oct; 79(4): PMC6193802.
- [12] Raghavan D, Thomas C. Lee, and Hugh D: Cholesterol Granuloma of the Petrous Apex: A 5-Year Review of Radiology Reports with Follow-Up of Progression and Treatment: *J Neurol Surg B Skull Base*. 2015 Aug; 76(4): 266-271.