

# Diagnosis and Therapy of Liquid Collections Under Ultrasound Control

Atanas Dimitrov Hilendarov, Alexandar Asenov Georgiev, Lyubomir Georgiev Chervenkov

Department of Diagnostic Imaging, Faculty of Medicine, Medical University, Plovdiv, Bulgaria

## Email address:

dr\_hill@abv.bg (A. D. Hilendarov), dralgeorgiev@gmail.com (A. A. Georgiev), lyubo.ch@gmail.com (L. G. Chervenkov)

## To cite this article:

Atanas Dimitrov Hilendarov, Alexandar Asenov Georgiev, Lyubomir Georgiev Chervenkov. Diagnosis and Therapy of Liquid Collections Under Ultrasound Control. *European Journal of Clinical and Biomedical Sciences*. Vol. 7, No. 5, 2021, pp. 81-85.

doi: 10.11648/j.ejcb.20210705.12

**Received:** November 11, 2020; **Accepted:** December 7, 2020; **Published:** November 17, 2021

---

**Abstract:** Purpose: We present our experience in the diagnosis, follow-up and planning therapy of thoracic, abdominal and retroperitoneal liquid collections in different emergency patients using conventional and interventional ultrasound. Material and Methods: The right and left oblique and poly positioning view was used in 235 patients (159 male and 76 female) for US examination to identify fluids in the thorax and peritoneal or retroperitoneal space. The examination was performed after the clinical survey with patients supine. Positive findings of US were compared with those provided by CT, punctures under US control or surgery. US machine supplied with linear and convex transducers, CT machine, needles and catheters were used. Results: 197 of all 235 US examined patients had fluid collections, confirmed by CT scan, surgery or clinical course. In 156 patients we performed FN diagnostic punctures under US control. There was 155 true-positives, 25 true-negatives, 5 false-positives and 2 false-negative results. Overall this demonstrated that ultrasonography has a sensitivity of 98.72%, specificity of 83.33% and accuracy of 96.25%. The PPV is 96.87% and the NPV – 92.59%. Conclusions: Our experience and literature reports support the opinion that US examination can and should be used as a primary method for diagnosis and follow-up of clinically suspected free and organised fluids in the thorax, abdomen and retroperitoneum.

**Keywords:** Thoracic, Abdominal and Retroperitoneal Liquid Collections, US Examination, CT Machine, Interventional Procedures

---

## 1. Introduction

The thoracic and abdominal traumas remains a challenge for the emergency team. Both false-positive and false-negative findings bear the risk of severe complications. The clinical problem is the poor reliability of the physical signs and symptoms that indicate the presence of visceral lesions and subsequent abdominal lesions, especially in intubated or comatose patients. Clinical evaluation allows the detection of external hemorrhage on antero-posterior chest x-ray and tube thoracostomy. They are sufficient to rule out significant hemothorax [1, 2]. The abdominal ultrasound (US) or diagnostic peritoneal lavage (DPL) may be inconclusive in evaluation of intraperitoneal free or encapsulated fluid collections. Nevertheless false positive cases with retroperitoneal hematoma can presented with leaks of the blood into peritoneal cavity. Multidetector computed tomography (MDCT) with contrast enhancement, offers a

complete imaging assessment of the thorax, abdomen and pelvis with the best sensitivity and specificity. The results are the best including for the injuries of thoracic, intra- and retroperitoneal organs, soft tissues and bones [3-5], but may be impossible for examination in patients unstable hemodynamically. The use of ultrasonography for sufficient identification of free and localized thoracic, intraperitoneal or retroperitoneal collections in patients with blunt and penetrating trauma has been well established over the past 25 years [6-10].

The aim of this report is to present our experience in the diagnosis, follow-up and initial planning therapy of thoracic and abdominal collections by using conventional and interventional ultrasound.


## 2. Methods and Materials

US examination to identify fluids in the thorax, peritoneal

or retroperitoneal space was used in 235 patients (159 male and 76 female) during a 7-year period. All US examinations are performed immediately after the clinical examination in the Department of Radiology with the patient on a supine position. Right and left oblique, transversal and multipositioned views was used to detect free and localized fluid collection in the thorax, peritoneal cavity and retroperitoneal space. Positive findings of the US examination were compared with those provided by computed tomography (CT), punctures under US control, laparoscopy or surgery.

The following materials and methods were used:

- 1) Ultrasonic equipment with linear, convex and biopsical transducers for guidance the interventional procedures.
- CT investigations and guidance were acquired using a MDCT scanner.
- 2) The "Chiba "needles 18, 20, 22, 23 G catheters pig-tail 7, 8F and angiographic guide wires (Figure 1a, b).



**Figure 1.** "Chiba "needles 18, 20, 22, 23G used for invasive procedures and Catheters pig-tail 7, 8F and angiographic guide wires.

- 3) A method for regulated automatic aspiration of liquid collections. The pressure can range within the limits of 40-100kPa.
- Methods of guiding the interventional procedures:
  - a. "Free-hand" biopsy and puncture method under US control.
  - b. US guiding method using biopsical transducer.
  - c. "Free-hand" method for biopsy, puncture and drainage

under CT control.

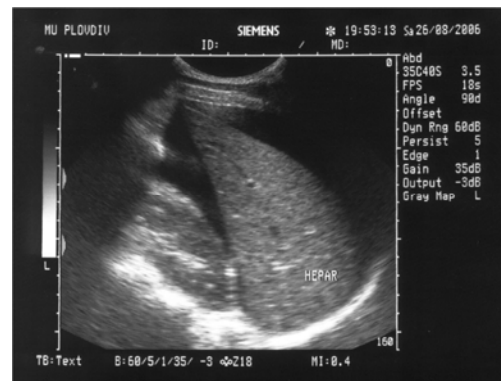### 3. Results

All US examinations were performed after the primary clinical examination of the patients.

One hundred and ninety-seven (83.82%) of all 235 patients examined ultrasonographically had fluid collection, which was verified by CT scan, tube laparoscopy or after surgery. Of all 197 patients 145% had blunt trauma and 52% - penetrating trauma.

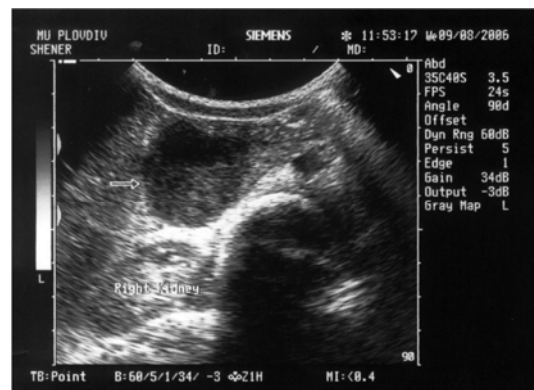On the other point of veaw, the US examinations of the patients were classified as:

1. Diagnostic examinations- performed in all 197 patients. Ten of the patients were excluded from the study because tube laparoscopy had been performed prior to US examination. Altogether 187% of all 197 US examined patients had fluid collections in thoracic and abdominal cavity (Figure 2).



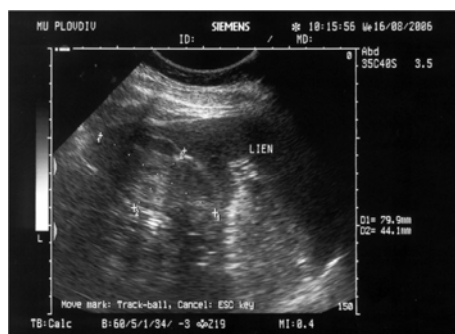**Figure 2.** US image. The free liquid in the abdomen (hemoperitoneum).

In 65 of patients hemoperitoneum was presented (Figure 2). In 42 cases the US examination reveiled localized haematomas, without clinical manifestation. They were discovered incidentally (Figure 3).



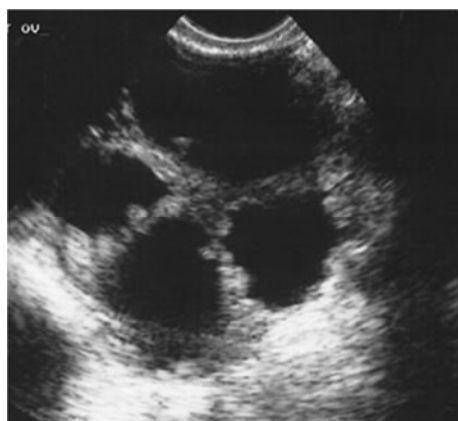**Figure 3.** US image. Localized liquid collections (haematoma).

Subcapsular bleeding were establish in 45 patients with blunt aldominal traumas witch needed emergent surgical intervention. (Figure 4).



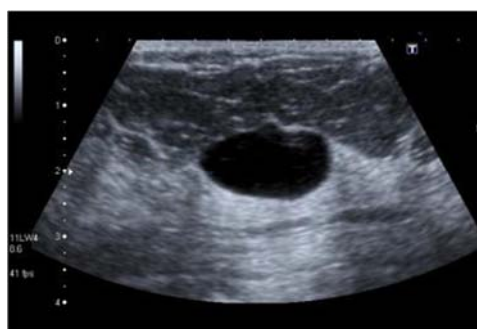**Figure 4.** US image of the patient with subcapsular haematoma of the spleen.

In 18 of all cases septated cystic lesions was presented and that provoked interventional (FNA and FNB) procedures for cytologic and if it is possible histologic investigation of taken tissue. The results was mucinous pancreatic cystic neoplasms. In these cases surgical interventions were performed to prevent cancerous degeneration of the lesions (figure 5).



**Figure 5.** US image of macrocystic pancreatic neoplasm.

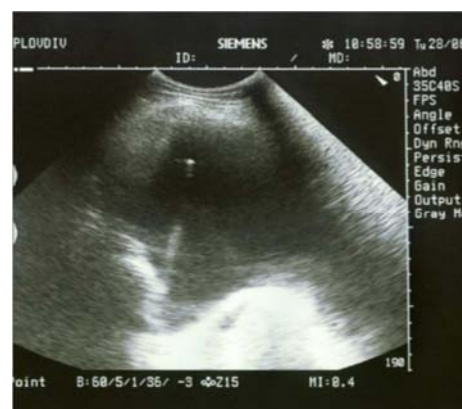Only in 5 patients observed the cysts of the mammary glands (Figure 6). The patients was examined due to lump palpated after trauma of the mammary gland.



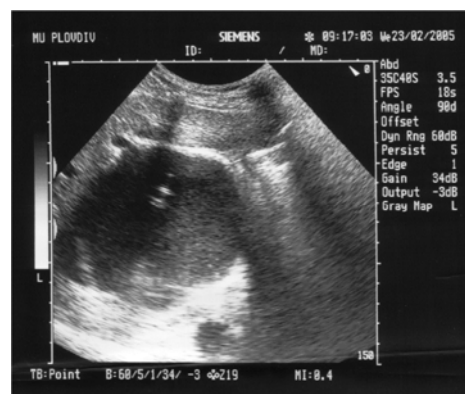**Figure 6.** US image of simple cyst of left mammary gland.

2. Diagnostic interventional procedures – FNP (fine needle punctures) under US control were performed in 97% of all patients with detected fluid in the thoracic, peritoneal cavity and retroperitoneal space. In 86% of them sufficient amount of liquid was obtained that favored diagnosis and allowed

planning of the following therapy. Hemoperitoneum during puncture under US control is shown on Figure 7.



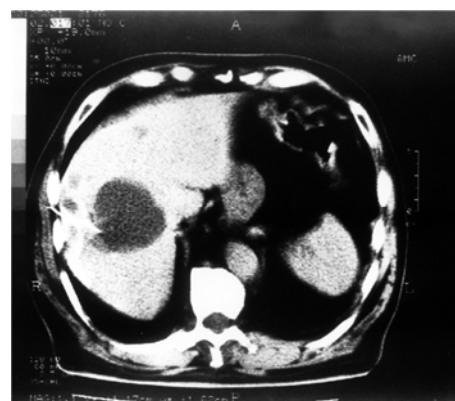a)



b)

**Figure 7.** a) Hemoperitoneum and b) haematoma during the puncture under US control.

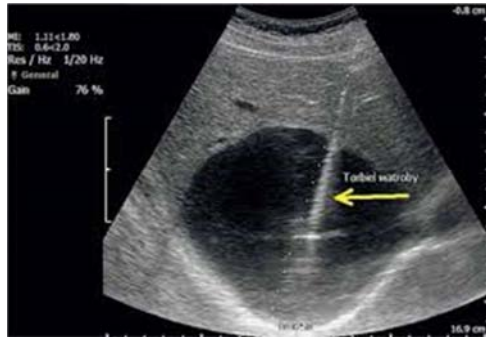Only in 5 cases with insufficient presentation of small amount of fluid and to define a safe percutaneous window allowing access to the collection for avoiding vascular structures and bowel loop, CT control was used. On Figure 8 hepatic abscess which is punctured under CT control is shown.



**Figure 8.** Patient with hepatic abscess drained under CT control.

In 6 other cases with abdominal abscesses a US control of the drainage procedures were used (Figure 9). Many authors comment that drainage procedures under US control help to

the interventionalist to visualize not only penetration of catheter in the abscess cavity as to control therapeutic process as well as to present proper position of catheter during the evacuation of the fluid and insertion of medications.



**Figure 9.** US image of hepatic abscess drained under US control.

Using non invasive US examination and FNP under US control of the patients with suspected thoracic, abdominal and retroperitoneal fluid we obtained the following results: There were 155 true positive cases, 25 true negative, 5 false positive and two false negative cases. Overall this demonstrated that ultrasonography has a sensitivity of 98.72%, specificity of 83.33% and accuracy of 96.25%. The PPV is 96.87% and the NPV – 92.59%.

These results demonstrated that ultrasonography can be used as a sensitive, specific and accurate diagnostic tool for detecting thoracic, abdominal and retroperitoneal liquid collections in clinically suspected patients. The speed and accuracy of US examinations with the possibilities to detect smaller amounts of fluid collections than the other imaging methods may be of benefit in early planning the treatment [12, 14, 15]. It is estimated that ultrasonography can detect a minimum of 15-20ml of liquid collections in the thoracic, peritoneal cavity and retroperitoneal space.

## 4. Discussion

Percutaneous drainage involves placement of an external drainage catheter into the organized liquid collection using real-time imaging guidance, usually with computed tomography (CT) or ultrasound (US) with fluoroscopy. Initial studies comparing surgical drainage to percutaneous drainage found both procedures to be efficacious. However, more recent comparative studies have generally favored percutaneous drainage, with some studies even demonstrating a mortality benefit [1, 2, 3, 16]. Percutaneous drainage has also recently been compared to endoscopic drainage. A recent study directly comparing percutaneous vs endoscopic management retrospectively. This study found equal technical success rates and adverse events rates between the techniques, but a decreased re-intervention rate, a shorter hospital stay, and a decreased number of follow-up abdominal imaging studies among patients drained endoscopically.

## 5. Conclusions

The choice of clinical strategy is often decisive for outcome of treatment. The most crucial decision in a patient with trauma is to find and to treat primarily the source of hemorrhage. Our protocol emphasizes abdominal US or DPL to determine the need of laparotomy. Laparotomy was mandatory when US showed more than 1 cm of fluid strip or fluid in two or more spaces. This approach has been validated in prospective clinical series [10, 11] and no patient of our series required emergency operative intervention for hemorrhage after a negative US.

Ultrasonography has high diagnostic performance in the screening of patients with blunt trauma. Abdominal and thoracic US is a useful and valuable diagnostic tool in these patients. Because of its high negative predictive value, we recommend that clinical follow up is adequate for patients whose US results are negative for organ injury.

Our experience and literature reports support the opinion that US examination should be used as a first method for diagnosis, follow-up and planning the therapy for free and organized fluids, as well as to control of the invasive diagnostic and therapeutic procedures.

## References

- [1] Phillips Perera, Josh Ennis, Geoffrey Schultz, Sarah Williams Ultrasound for Detection of Ascites and for Guidance of the Paracentesis Procedure: Technique and Review of the Literature, January 2014, International Journal of Clinical Medicine 05 (20): 1277-1293 DOI: 10.4236/ijcm.2014.520163.
- [2] Joel Cho, MD RDMS RDCS, Trevor P. Jensen, MD MS, Kreegan Recommendations on the Use of Ultrasound Guidance for Adult Abdominal Paracentesis: A Position Statement of the Society of Hospital Medicine Published Online Only January 2, 2019. doi: 10.12788/jhm.3095 | 10.12788/jhm.3095.
- [3] Joel Cho, MD RDMS RDCS, Trevor P. Jensen, MD MS, Kreegan 29 Intra-Abdominal Fluid Collections, 2020, 10.1055/b-0038-1629002.
- [4] Brian C Allen, Huiman Barnhart, Mustafa Bashir, Christopher Nieman, Steven Breault, Tracy A Jaffe Diagnostic accuracy of intra-abdominal fluid collection characterization in the era of multidetector computed tomography, Am Surg. 22 Feb; 78 (2): 185-9.
- [5] Osvaldo Chiara, Stefania Cimbanassi, Fabio Castelli, Rosario Spagnolo, Paolo Girotti. Protocol-driven approach of bleeding abdominal and pelvic trauma. World J Emerg Surg. 2006; 1: 17.
- [6] Yao DC, Jeffrey RB, Jr, Mirvis SE, Weekes A, Federle MP, Kim C, Lane MJ, Prabhakar P, Radin R, Ralls PW. Using contrast-enhanced helical CT to visualize arterial extravasation after blunt abdominal trauma: incidence and organ distribution. Am J Roentgenol. 2002; 178: 17–20.
- [7] Mullinix AJ, Foley WD. Multidetector computed tomography and blunt thoracoabdominal trauma. J Comput Assist Tomogr. 2004 Jul-Aug; 28 Suppl 1: S20-7.

- [8] Eastridge BJ, Starr A, Minei JP, O'Keefe GE, Scalea TM. The importance of fracture pattern in guiding therapeutic decision making in patients with hemorrhagic shock and pelvic ring disruption. *J Trauma*. 2002; 53: 446–451.
- [9] M. Valentino, C. Sera, G. Zironi, C. De Luca, P. Pavlica, and L. Barozzi. Blunt Abdominal Trauma: Emergency Contrast-Enhanced Sonography for Detection of Solid Organ Injuries. *Am. J. Roentgenol.*, May 1, 2006; 186 (5): 1361-1367.
- [10] B. C. Lee, E. L. Ormsby, J. P. McGahan, G. M. Melendres, J. R. Richards. The Utility of Sonography for the Triage of Blunt Abdominal Trauma Patients to Exploratory Laparotomy. *AJR* 2007; 188: 415-421.
- [11] M. Christie-Large, D. Michaelidesand, S. James. Focused assessment with sonography for trauma: the FAST scan Trauma, April 1, 2008; 10 (2): 93-101.
- [12] E Azoulay. Diagnosis and management of pleural effusions in critically III patients, PubMed, March 2005, *Revue des Maladies Respiratoires* 22 (1 Pt 1): 71-9.
- [13] Cassia Lemos Moura, Priscila Pulita Azevedo Barros, Cristiane Mota Oliveira, Rogerio Colaiácovo, Juliana Marques Drigo, Augusto Pincke Cruz Carbonari, Tercio de Campos, Lucio Giovanni Batista Rossini, Minimally invasive endoscopic treatment of necrotizing pancreatitis: A case report with images and review of the literature, *Rev. Assoc. Med. Bras*. Vol. 63 no. 3 SãoPaulo Mar. 2017 <http://dx.doi.org/10.1590/1806-9282.63.03.207>
- [14] Manuela Stoicescu, The surprise of diagnosis of a fluid collection around the spleen: Case report, 5<sup>th</sup> International Conference and Exhibition on Surgery & ENT Alicante, Spain, *Surgery Curr Res* 2016, 6: 6 (Suppl) <http://dx.doi.org/10.4172/2161-1076.C1.026>
- [15] Redden MD, Chin TY, van Driel ML (March 2017). "Surgical versus non-surgical management for pleural empyema". *Cochrane Database Syst Rev*. 3: CD010651. doi: 10.1002/14651858.CD010651.pub2. ISSN 1469493X. PMC 6464687. PMID 28304084.
- [16] Ji Young Bang and Shyam Varadarajulu. Endoscopic ultrasonography-guided drainage of postoperative abdominal fluid collections: What should we do to improve outcomes? *Digestive Endoscopy* 2015; 27: 727–728 doi: 10.1111/den.12492.