



Subtle Activities of Specific Plain Subtalar Joint May Account for Non-injured Ankle Pain: A Case Report

Shenxing Du^{1,*}, Lihong Wei²

¹Department of Rehabilitation, Dongyang People's Hospital, Dongyang City, China

²Department of Orthopedics, Dongyang People's Hospital, Dongyang City, China

Email address:

dsx0221@gmail.com (Shenxing Du)

*Corresponding author

To cite this article:

Shenxing Du, Lihong Wei. Subtle Activities of Specific Plain Subtalar Joint May Account for Non-injured Ankle Pain: A Case Report.

International Journal of Biomedical Engineering and Clinical Science. Vol. 7, No. 4, 2021, pp. 91-95. doi: 10.11648/j.ijbecs.20210704.15

Received: November 14, 2021; **Accepted:** December 1, 2021; **Published:** December 9, 2021

Abstract: Current clinical practice focuses on discovering injuries and then formulating treatment plans. But some injuries have nothing to do with symptoms, including pain, let alone those situations where there is no injury. The ankle, especially the subtalar joint, has a high rate of variation, so the subtle activities of subtalar joint are exactly important in patients who have biomechanical issues, especially in the condition that all check-ups are normal. This paper presented a case report of a 16-year-old teenager who was a professional basketball player in local senior high school. The pain appeared in both of his soles and ankles as long as he played basketball and disappeared immediately after the exercise since his childhood. All the routine tests involving MRI and ultrasound were normal. No impingement condition was found. 3D dynamic reconstruction combined with 3D continuum model was performed. The specific plain subtalar articular surfaces were revealed. The treatment involving dynamic fixation via rigid tape and training lasted for 4 weeks. Before the treatment, the right talus was more stable than the left one ($\Delta(\text{norm})=0.5126$), and the calcaneus was the other way around ($\Delta(\text{norm})=0.6280$). The differences of degrees of freedom between two sides decreased significantly ($\Delta(\text{norm})=0.0833, 0.000$) after treatment. Besides, the steep and tone of both sides of talus and calcaneus revealed relative rotation and translation which indicated that the movement of subtalar joint trended to the balance of stability and mobility. This patient improved his athletic ability and got pain free immediately after the first treatment. Moreover, the pain didn't appear during the 12-month follow-up. Therefore, we conclude that based on our treatment which focused on the reduction of the subtle activities of subtalar joint, we support that the subtle activities of variable subtalar joint may influence the athletic abilities and cause some symptoms. Therefore, the importance of bone shape which is the chief culprit of abnormal mobility shall be taken seriously. Moreover, in the case calculation based on the mathematical model, stable calcaneus and flexible talus make the better balance of stability and mobility and are necessary for available exercises.

Keywords: Biomechanical Phenomena, Ankle, Anatomic Variation, Mathematics, Conservative Treatment

1. Background

Current clinical practice focuses on discovering injuries and then formulating treatment plans. But some symptoms have nothing to do with injuries, including pain, let alone those situations where there is no injury. The ankle, especially the subtalar joint, has a high rate of variation, so the subtle activities of subtalar joint are exactly important in patients who have biomechanical issues, especially in the condition that all check-ups are normal. As far as

biomechanical phenomena, the in-vivo measurement of joint dynamic motion is important for understanding the impacts of surgical procedures and the effects of conservative treatments. However, it is difficult to accurately determine three-dimensional (3D) bone motion in vivo due to the unreliability or misery to directly attach skin or bone-mounted markers [3]. Both plantar pressure and gait analysis deal with the interarticular relationship while moving [1, 4, 7, 9, 10, 12, 14]. However, the subtle differences of the intraarticular relationship mostly get less attention. 3D to 2D image registration technique (3D-2D IRT) is the registration

of 3D joint models which are obtained from computed tomography (CT) to one or more 2D fluoroscopic videos. It can help us easily in-vivo measure the joint dynamic motions using their own bones while avoiding using available cadaveric experimental data and analyze the intraarticular motions. Nevertheless, analysis of position data only (not involving process) is insufficient [11]. It is of cardinal importance to design experiments which are guided by appropriate theoretical approaches so that essential modelling parameters can be confined or even identified [8].

This case uses a 3D continuum model (continuous transformation matrix (CTM)) to capture the intraarticular motions of a patient who has a specific plain subtalar joint and remodel. Using mathematical models can evaluate patients' conditions more explicitly and find out underlying problems which may not come into current practitioners' eyes.

2. Case Presentation

The patient who was 16 years old was a professional basketball player in local senior high school. The pain appeared which was evaluated via Visual Analogue Scale (VAS) in both of his soles and ankles as long as he played basketball (also any sport involving run and jump) and disappeared (VAS: 0) immediately after the exercise since his childhood. The pain on the left (VAS: 5) is slightly heavier than the right (VAS: 4). No swelling, tender points, and limited range of motion were found. All the routine tests involving MRI and ultrasound were normal. No impingement condition was found out through 3D dynamic reconstruction via 3D-2D IRT under weight-bearing. Whereas the specific plain subtalar articular surfaces were revealed through 3D CT

image reconstruction (Figure 1). There was a wide variation in the results of the subtle activities of his subtalar joint before the conservative treatment. The treatment involving dynamic fixation via rigid tape which was guided by the results of 3D continuum models and training lasted for 4 weeks. This patient improved his athletic ability and got pain free immediately after the first treatment. Moreover, the pain didn't appear during the 12-month follow-up. The movements of the talus and calcaneus were calculated in this case (Table 1) (Figures 2-9). As all the bone coordinate system (BCS) data are relative to the world coordinate system (WCS), we transform the data to set the tibia's BCS as the new WCS for comparison. All the calculations were performed by using MATLAB R2019b (MathWorks, USA).

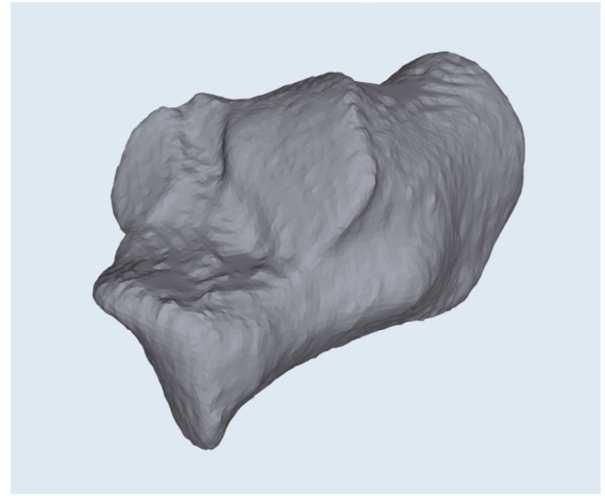


Figure 1. The upper surface of the calcaneus through 3D CT image reconstruction.

Table 1. BCSs of talus and calcaneus relative to BCS of tibia at 0 degree and 25 degrees of dorsiflexion before and after the treatment.

		X Translation	Y Translation	Z Translation	X Rotation	Y Rotation	Z Rotation	norm(T)
Before								
0 degree								
Talus	R	-0.1	1	-3	-3	-15	10	
	L	-0.1	2	-3	3	-14	10	
Calcaneus	R	-5	3	-6	0	0	5	
	L	-5	3	-6	0	0	5	
25 degrees of dorsiflexion								
Talus	R	0.3	0.7	-2	-3	0	10	1.7047
	L	0.3	0.6	-2	3	0	10	2.2173
Calcaneus	R	0	-2	-4	10	35	45	7.4821
	L	1	-2	-4	-13	38	45	6.8541
After								
0 degree								
Talus	R	-0.1	2	0	-3	-10	10	
	L	-0.1	2	0	3	-10	10	
Calcaneus	R	-5	3	-6	0	0	0	
	L	-5	3	-6	0	0	0	
25 degrees of dorsiflexion								
Talus	R	0.3	1	2	-3	0	10	2.6491
	L	0.3	0.8	2	3	0	10	2.7324
Calcaneus	R	-3	0	-4	0	10	20	4.3528
	L	-3	0	-4	-1	10	20	4.3528

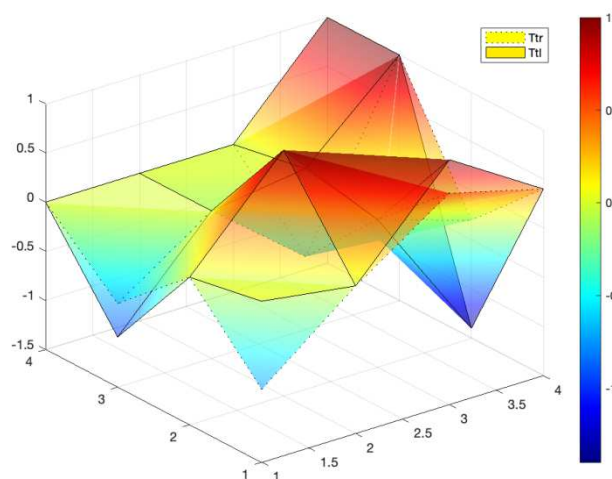


Figure 2. Graphical illustration of CTM of right (Ttr) and left (Ttl) sides of talus before the treatment.

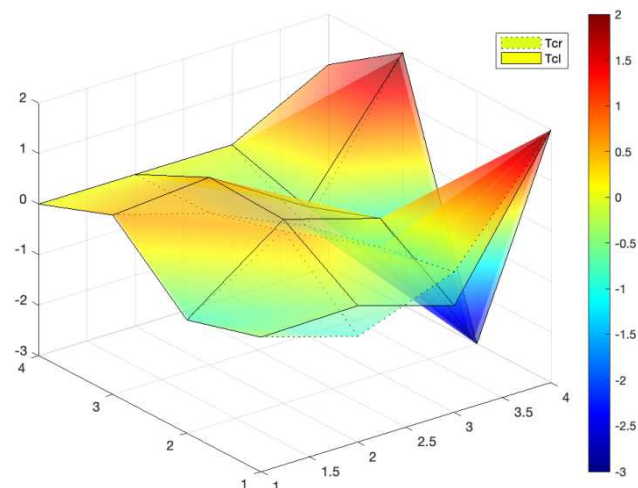


Figure 5. Graphical illustration of CTM of right (Tcr) and left (Tcl) sides of calcaneus after the treatment.

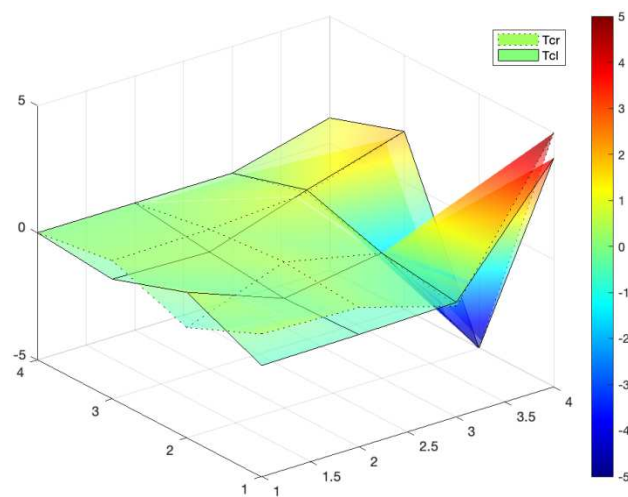


Figure 3. Graphical illustration of CTM of right (Tcr) and left (Tcl) sides of calcaneus before the treatment.

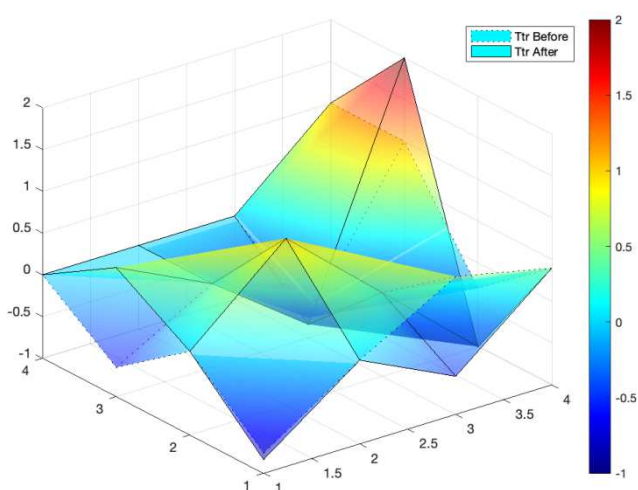


Figure 6. Graphical illustration of CTM of right side of talus before and after the treatment.

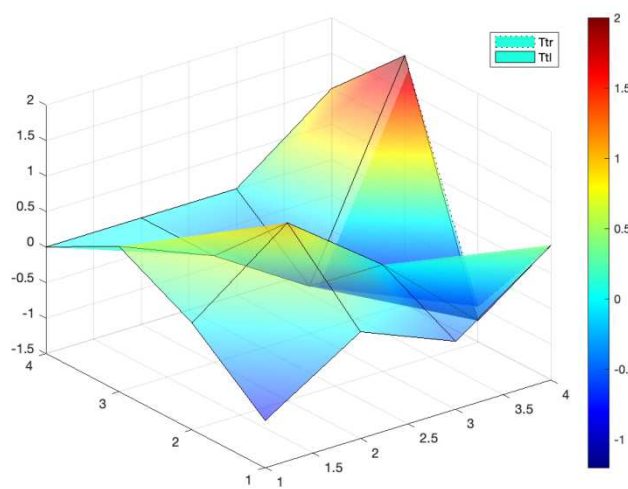


Figure 4. Graphical illustration of CTM of right (Ttr) and left (Ttl) sides of talus after the treatment.

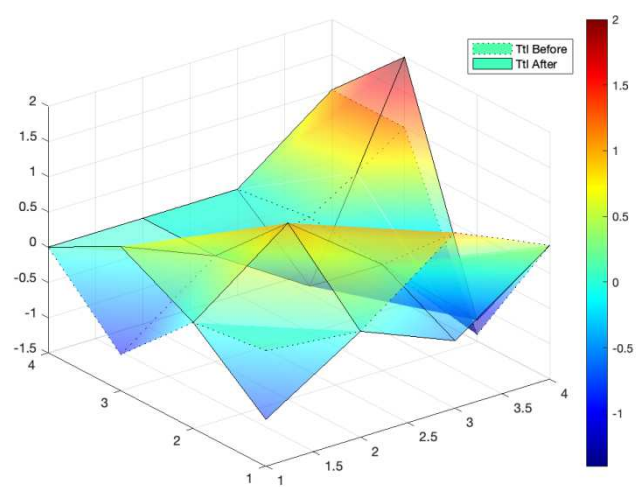


Figure 7. Graphical illustration of CTM of left side of talus before and after the treatment.

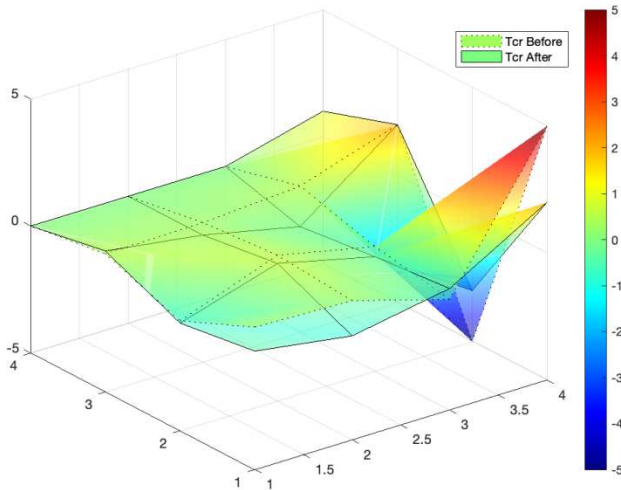


Figure 8. Graphical illustration of CTM of right side of calcaneus before and after the treatment.

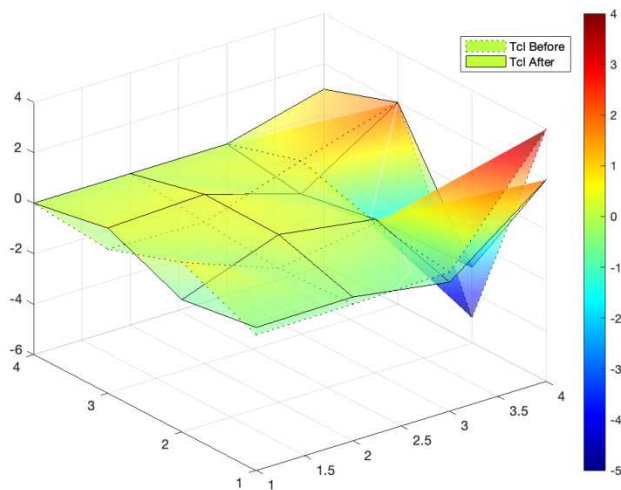


Figure 9. Graphical illustration of CTM of left side of calcaneus before and after the treatment.

3. Discussion

At the beginning, we considered it as plantar fasciitis (PF). PF is generally caused by aseptic inflammation of the tendon or fascia of the foot [6, 16]. To date, it has been demonstrated that this condition is not characterized by inflammation but rather by noninflammatory degenerative changes of the plantar fascia that cause microscopic tears when it inserts into the calcaneus [15]. This condition is better referred to as fasciopathy or fasciosis [2, 5, 13]. Plantar fasciitis is characterized by pain at the bottom of the heel and along the medial border of the plantar fascia. The pain is usually aggravated in the morning, with the first step after getting out of bed or after prolonged sitting (non-weight bearing) [15]. Based on the above characteristics, we excluded PF. Therefore, our treatment focused on the reduction of the subtle activities of subtalar joint and didn't include the rehabilitation against PF.

Before the treatment, the right talus was more stable (less degrees of freedom (DoFs)) than the left one

($\Delta(\text{norm})=0.5126$) (Figure 2), and the calcaneus was the other way around ($\Delta(\text{norm})=0.6280$) (Figure 3). It may support the heavier pain on the left. More contact areas (Figures 4, 5) showed the differences of DoFs between two sides decreased significantly ($\Delta(\text{norm})=0.0833, 0.000$) after the treatment. It indicates that even if there were slight differences in the movement of the talus on both sides, as long as the rotation of the calcaneus was stable, the pain would disappear. After the treatment, both sides of talus showed steeper and less gentle tone (Figures 6, 7) which means less stable, while it revealed more anterior rotation and more superolateral translation. On the contrary, both sides of calcaneus showed less steep and gentler tone (Figures 8, 9) which means more stable, while it revealed more anterior, and less everted and abducted rotation and less anterolateral translation. It indicates that the movement of subtalar joint trended to the balance of stability and mobility.

4. Conclusions

Based on our treatment which focused on the reduction of the subtle activities of subtalar joint, we support that the subtle activities of variable subtalar joint may influence the athletic abilities and cause some symptoms. Therefore, the importance of bone shape which is the chief culprit of abnormal mobility shall be taken seriously. Moreover, in the case calculation based on CTM, stable calcaneus and flexible talus make the better balance of stability and mobility and are necessary for available exercises.

List of Abbreviations

- Three-dimensional (3D)
- 3D to 2D image registration technique (3D-2D IRT)
- Computed tomography (CT)
- Continuous transformation matrix (CTM)
- Visual Analogue Scale (VAS)
- Bone coordinate system (BCS)
- World coordinate system (WCS)
- Plantar fasciitis (PF)
- Degrees of freedom (DoFs)

Declaration

Ethics approval and consent to participate: Ethical approval was not sought for the present study because written informed consent was obtained from the patient of this case report and any accompanying images. A copy of the written consent is available for review by the Editor-in-Chief of this journal.

Availability of Data and Material

Data transparency.

Competing Interests

The authors declare that they have no conflict of interest.

Funding

This research received no specific grant from any funding agency in the public, commercial, or not-for-profit sectors.

Acknowledgements

The authors gratefully acknowledge Wenchang Miao (Gottfried Wilhelm Leibniz Universität Hannover, Germany) and Yuan Wang (Net Ease Research Institute, Hangzhou, China) for technical advice on post-processing of the data and our colleague Xinhao Chen (Department of Radiology) for providing guidance on radiation safety as well as assessment of radiation exposure and dosage.

References

- [1] Cao W, Yu H, Meng Q, Chen W, Li S. Plantar pressure analysis of above-knee amputee with a developed microprocessor-controlled prosthetic knee. *Acta Bioeng Biomech.* 2018; 20 (4): 33-40. PMID: 30821287.
- [2] Cleland JA, Abbott JH, Kidd MO, et al. Manual physical therapy and exercise versus electrophysical agents and exercise in the management of plantar heel pain: a multicenter randomized clinical trial. *J Orthop Sports Phys Ther.* 2009; 39 (8): 573- 585. doi: 10.2519/jospt.2009.3036.
- [3] Dennis DA, Mahfouz MR, Komistek RD, Hoff W. In vivo determination of normal and anterior cruciate ligament-deficient knee kinematics. *J Biomech.* 2005; 38 (2): 241-253. doi: 10.1016/j.jbiomech.2004.02.042.
- [4] Haddas R, Ju KL, Belanger T, Lieberman IH. The use of gait analysis in the assessment of patients afflicted with spinal disorders. *Eur Spine J.* 2018; 27 (8): 1712-1723. doi: 10.1007/s00586-018-5569-1.
- [5] Hyland MR, Webber-Gaffney A, Cohen L, Lichtman PT. Randomized controlled trial of calcaneal taping, sham taping, and plantar fascia stretching for the short-term management of plantar heel pain. *J Orthop Sports Phys Ther.* 2006; 36 (6): 364-371. doi: 10.2519/jospt.2006.2078.
- [6] Li L, Yang L, Yu F, et al. 3D printing individualized heel cup for improving the self-reported pain of plantar fasciitis. *J Transl Med.* 2018; 16 (1): 167. doi: 10.1186/s12967-018-1547-y.
- [7] Li W, Xu S, Liu Y, Zhou Y, Qu L, Yang X. Application of Static Characteristics of Plantar Pressure Distribution in the Assessment of Knee Joint Injury. *Zhongguo Yi Liao Qi Xie Za Zhi.* 2018; 42 (6): 395-399. doi: 10.3969/j.issn.1671-7104.2018.06.002.
- [8] Menzel A. A fibre reorientation model for orthotropic multiplicative growth. Configurational driving stresses, kinematics-based reorientation, and algorithmic aspects. *Biomech Model Mechanobiol.* 2007; 6 (5): 303-320. doi: 10.1007/s10237-006-0061-y.
- [9] Miura N, Nagai K, Tagomori K, et al. Plantar pressure distribution during standing in women with end-stage hip osteoarthritis. *Gait Posture.* 2020; 76: 39-43. doi: 10.1016/j.gaitpost.2019.10.026.
- [10] Mueske NM, Öunpuu S, Ryan DD, et al. Impact of gait analysis on pathology identification and surgical recommendations in children with spina bifida. *Gait Posture.* 2019; 67: 128-132. doi: 10.1016/j.gaitpost.2018.10.003.
- [11] Nasser A, Khataee H, Bryant AL, Lloyd DG, Saxby DJ. Modelling the loading mechanics of anterior cruciate ligament. *Comput Methods Programs Biomed.* 2020; 184: 105098. doi: 10.1016/j.cmpb.2019.105098.
- [12] Petraglia F, Scarcella L, Pedrazzi G, Brancato L, Puers R, Costantino C. Inertial sensors versus standard systems in gait analysis: a systematic review and meta-analysis. *Eur J Phys Rehabil Med.* 2019; 55 (2): 265-280. doi: 10.23736/S1973-9087.18.05306-6.
- [13] Renan-Ordine R, Albuquerque-Sendín F, de Souza DP, Cleland JA, Fernández-de-las-Peñas C. Effectiveness of myofascial trigger point manual therapy combined with a self-stretching protocol for the management of plantar heel pain: a randomized controlled trial. *J Orthop Sports Phys Ther.* 2011; 41 (2): 43-50. doi: 10.2519/jospt.2011.3504.
- [14] Scharnweber B, Adjami F, Schuster G, et al. Influence of dental occlusion on postural control and plantar pressure distribution. *Cranio.* 2017; 35 (6): 358-366. doi: 10.1080/08869634.2016.1244971.
- [15] Shashua A, Flechter S, Avidan L, Ofir D, Melayev A, Kalichman L. The Effect of Additional Ankle and Midfoot Mobilizations on Plantar Fasciitis: A Randomized Controlled Trial. *J Orthop Sports Phys Ther.* 2015; 45 (4): 265-272. doi: 10.2519/jospt.2015.5155.
- [16] Xu R, Wang Z, Ma T, Ren Z, Jin H. Effect of 3D Printing Individualized Ankle-Foot Orthosis on Plantar Biomechanics and Pain in Patients with Plantar Fasciitis: A Randomized Controlled Trial. *Med Sci Monit.* 2019; 25: 1392-1400. doi: 10.12659/MSM.915045.