

The Use of Hypochlorous Acid in the Healing of a Diabetic Foot Ulcer

Hendrik Roos

Trifectiv (Pty) Ltd, Stellenbosch, South Africa

Email address:

labs@trifectiv.com

To cite this article:

Hendrik Roos. The Use of Hypochlorous Acid in the Healing of a Diabetic Foot Ulcer. *International Journal of Biomedical Engineering and Clinical Science*. Vol. 8, No. 4, 2022, pp. 53-56. doi: 10.11648/j.ijbecs.20220804.13

Received: November 28, 2022; **Accepted:** December 23, 2022; **Published:** December 29, 2022

Abstract: There is a need for use of an antiseptic in wound care in individuals with diabetes mellitus where wounds can be infected with multiple drug resistant (MDR) pathogens in planktonic or biofilm forms. The antiseptic and appending wound dressing regimen should be non-toxic to cells and offer a simple yet effective solution to treat infection. An essential component of wound care is to debride wounds and the health care provider should consider the role of dressing type in assisting with debridement. The case studies describe the successful treatment of a diabetic foot ulcer (DFU) with a pharmaceutical grade hypochlorous acid (HOCl) solution in a 70-year-old female, and in a 45-year-old male, both with Type 1 diabetes mellitus. HOCl is an effective antiseptic against drug sensitive, as well as multiple drug resistant pathogens, has anti-biofilm properties and demonstrate inflammation modulation, which assist with healing. Both cases responded well to daily dressings of surgical gauze saturated with HOCl and retained with crepe bandage. The case representations suggest that satisfactory results can be obtained with conservative management of DFU. Patients can be treated at home using simple, yet effective gauze dressings saturated with pharmaceutical grade HOCl. Home treatment, monitored by the health care provider saves time and cost and improves patient compliance and quality of life.

Keywords: Diabetic Foot Ulcer (DFU), Biofilm, Healing Through Secondary Intention, Hypochlorous Acid, Trifectiv® Plus Wound & Burn Care, Infection, Inflammation, Debridement

1. Introduction

Diabetic patients are prone to develop foot ulcers (DFUs) due to the lack of neurological sensation, impaired microvascular circulation, and poor immune responses [1]. Ulceration frequently leads to infection, which could be the immediate cause for amputation [2]. The spectrum of infections in diabetics ranges from superficial cellulitis to chronic osteomyelitis. These infections are difficult to treat because poor circulation limits oxygen, nutrient and antibiotic delivery whilst also limiting access for phagocytic cells [3]. Most of the antiseptics currently used in wound care are cytotoxic, such as sodium hypochlorite, povidone iodine, chlorhexidine, and peroxide, which may interfere with the healing process [4, 5]. Sterile saline, often applied as a wound cleansing solution or as part of a dressing regime, though not cytotoxic, does not eliminate pathogens and therefore does not provide any antiseptic properties. HOCl solution is an effective nontoxic antiseptic agent that cleanses and disinfects the

wound without damaging healthy tissue. It is useful for diminishing the pathogen burden and preventing the risk of long-term morbidity associated with amputations [1].

2. Study Case Presentation

2.1. Case 1

2.1.1. Patient History

The patient is a 70-year-old female with a 10-year history of diabetes, who progressed into Type-1 diabetes for the last five years. From the time of becoming insulin-dependent, there were periods of poor glycaemic control, evident as sensory loss in both distal lower extremities. A DFU had been present on the medio-plantar aspect of the first metatarsal aspect of the right foot for 31 months. Seven months prior to presentation, the patient underwent surgical debridement. According to the patient, the wound did not heal after the surgery. She applied various topical ointments

including povidone iodine, fucidic acid, mupirocin, and neomycin sulphate intermittently before and after surgery.

2.1.2. Wound Progress

In the area of previous debridement, the patient presented with a round 4 cm diameter necrotic wound. There was no odor or visible discharge from the wound. The area around the wound was inflamed. The patient requested treatment at her residence as she did not have the means to travel to a treatment facility.

Day 1: Washing the wound with lukewarm water and liquid soap (without actives) removed remnants of previously used antiseptics. A gauze dressing, wetted with hypochlorous acid (HOCl) 380 mg/L (available as Trifectiv® Plus Wound & Burn Care) was applied onto the wound and retained with a crepe bandage. Instructions were given to the patient on how to apply the dressing and retention bandage.

Day 2 - 60: Daily dressing changes revealed necrotic tissue on the gauze. The presence of necrotic tissue on the gauze

indicated successful wet to moist wound debridement. Steady debridement was observed throughout the treatment period. The patient sent photographs of her wound every second day. This allowed the responsible health care professional to monitor the wound progress and advise the patient.

Day 60: In addition to daily dressings, the patient was educated on the principles of off-loading the wound. The health care professional visited the patient at home and instructed her on the process of gentle removal of calloused skin on and around the wound with a foot file. Weekly visits to the patient with inspection of the wound assisted with satisfactory progression until the wound was completely healed.

Day 65. Wound area was sufficiently offloaded. The patient was instructed to visit an appropriate health care professional for correct padding and shoe adjustments, as well as to obtain instructions on how to inspect her feet daily for any injuries.

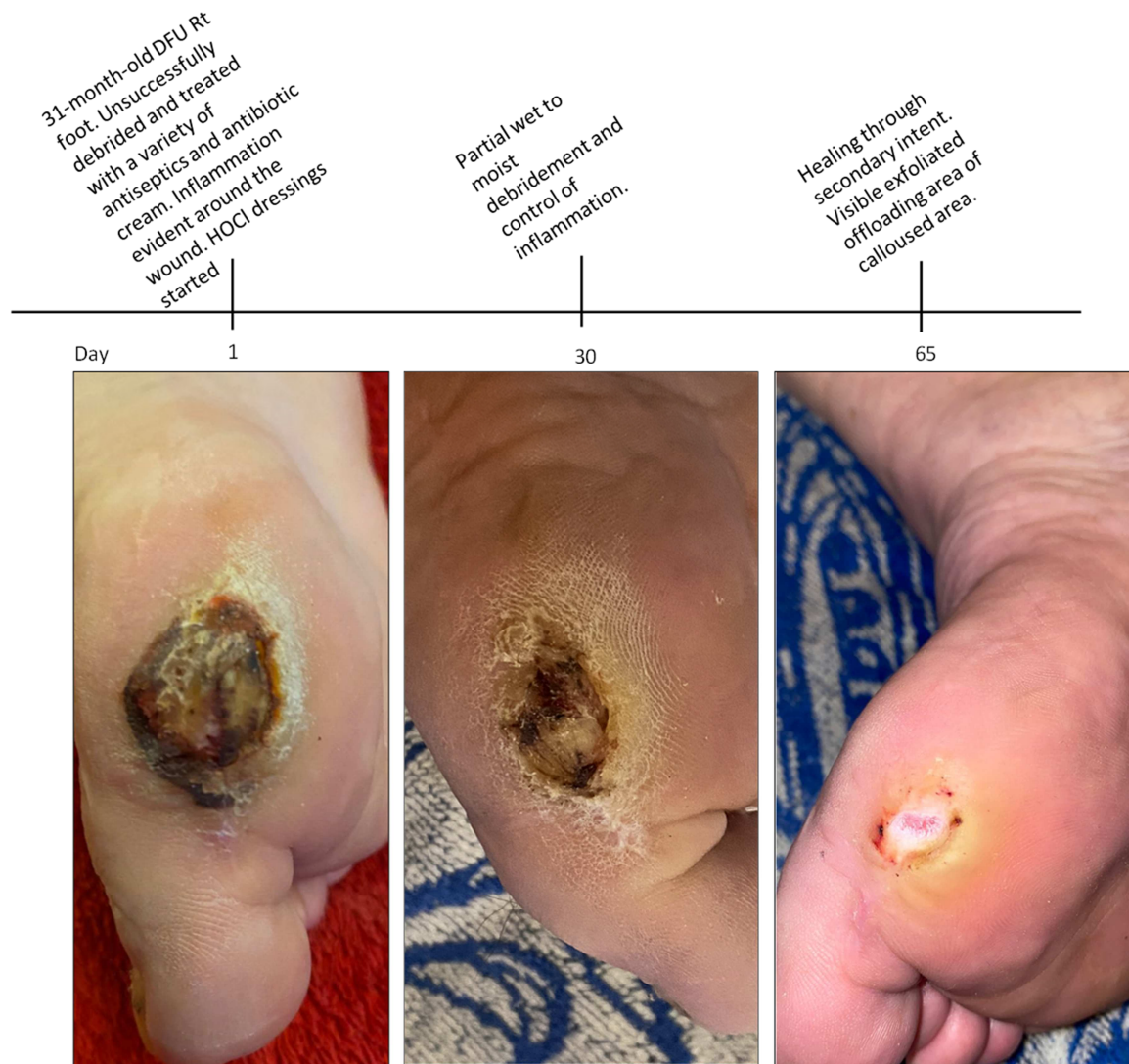


Figure 1. Treatment of diabetic foot ulcer using hypochlorous acid dressings. A 70-year-old diabetic female presented with a diabetic foot ulcer (DFU) measuring 4 cm diameter on the medio-plantar aspect of the 1st metatarsal head of the right foot. This wound was unsuccessfully treated with previous debridement and a variety of antiseptics and antibacterial agents. Daily HOCl-wetted gauze dressing retained with crepe bandage was instrumental in the removal of necrotic tissue, and to heal the wound. Healed wound showing offloaded area after 65 days.

2.2. Case 2

2.2.1. Patient History

A 45-year-old diabetic male presented with a 7-year history of a DFU measuring 5 cm x 3.5 cm on the medio-plantar aspect of the right foot, between the 1st metatarsal head and the proximal phalanges of the big toe. The patient had a 15-year history of Type-1 diabetes. The wound was previously unsuccessfully treated with a variety of antiseptics (iodine, betadine, chlorhexidine, fucidic acid) and the patient received multiple courses of antibiotics. Surgical debridement was unsuccessful to completely remove all necrotic tissue. The patient reported that the surgical debridement resulted in a larger wound.

2.2.2. Wound Progress

The wound was washed with lukewarm water and liquid soap (without actives) to remove remnants of previously used antiseptics. A gauze dressing, wetted with hypochlorous acid (HOCl) 380 mg/L (available as Trifectiv[®] Plus Wound &

Burn Care) was applied onto the wound and retained with a crepe bandage. Instructions were given to the patient on how to apply the dressing and retention bandage.

Daily dressing changes revealed necrotic tissue on the gauze, indicating successful wet to moist wound debridement. Steady debridement was observed throughout the treatment period. The patient sent photographs of his wound as well as the gauze dressing every second day. This allowed the responsible health care professional to monitor the wound progress and advise the patient.

Daily HOCl dressings demonstrated satisfactory wound progress after 28 days. Wound exudate diminished during the first four days of dressings, with concomitant reduction in wound inflammation. During the following 24 days conservative wet to moist gauze debridement was successful in removing all necrotic material from the wound bed, with no need for surgical intervention. Due to the patient relocating, no further follow-up was possible after 28 days.

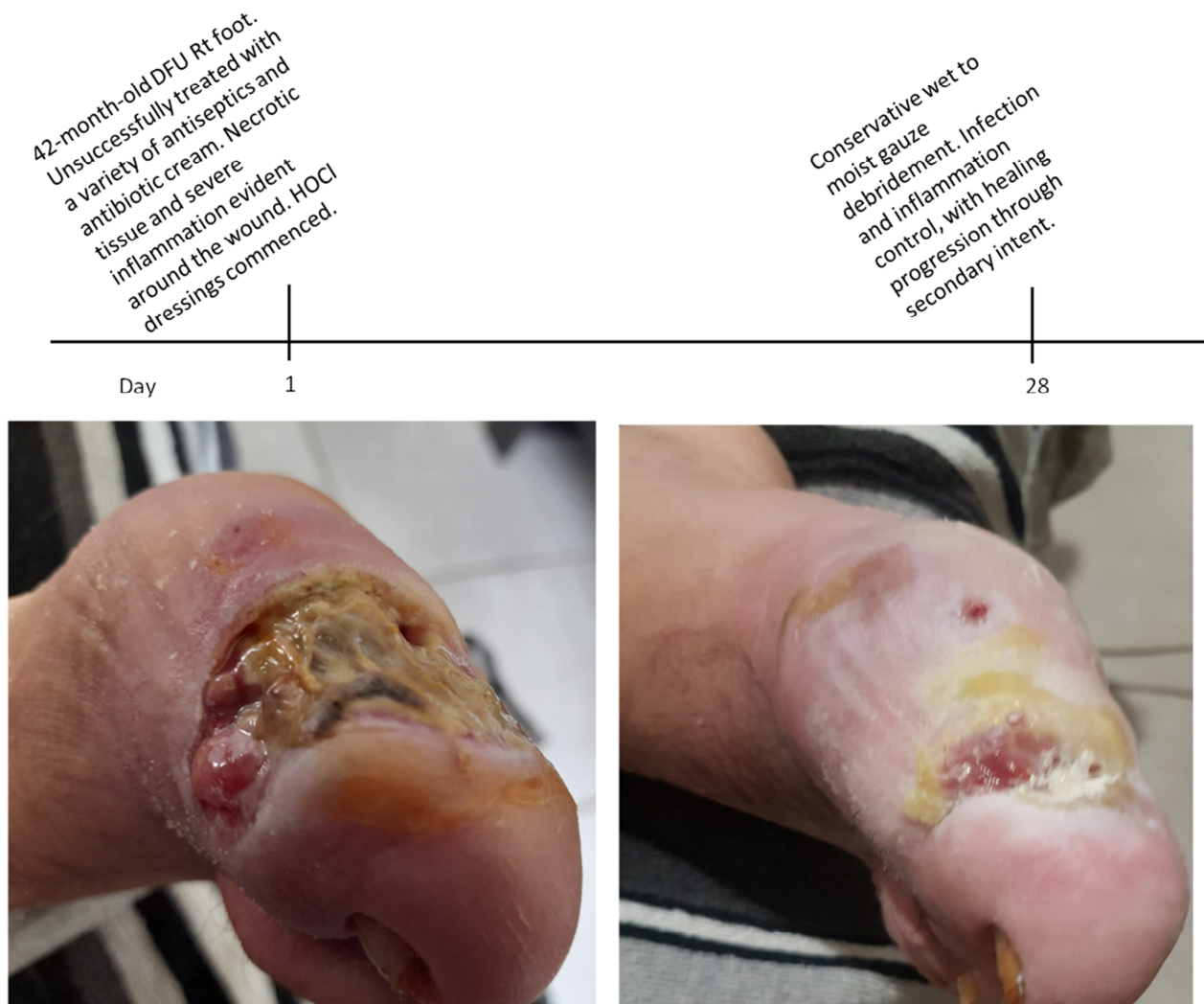

Figure 2. Treatment of diabetic foot ulcer using hypochlorous acid dressings. A 45-year-old diabetic male presented with a diabetic foot ulcer (DFU) measuring 5 cm x 3.5 cm on the medio-plantar aspect of the right foot, between the 1st metatarsal head and the proximal phalanges of the big toe. This wound was previously unsuccessfully treated with a variety of antiseptics and antibacterial agents. Daily HOCl-wetted gauze dressing retained with crepe bandage demonstrated satisfactory healing after 28 days. Due to the patient relocating, no further follow-up was possible.

3. Discussion

Comprehensive treatment of individuals suffering from diabetic foot ulcers (DFU's) should include appropriate surgical or other forms of debridement, aggressive broad spectrum antimicrobial administration in the case of systemic sepsis, the management of co-morbidities, glycemic control and vascular assessment [1].

The use of antiseptics in DFU's is often controversial [6] due to their concomitant cytotoxic effect. Wound treatment should aim to alleviate symptoms, promote healing, and avoid lower extremity amputation [6].

HOCl solutions are more effective in infection and inflammation (erythema) control, as well as odor reduction and cause less skin affection when compared to conventional antiseptics (chlorhexidine, honey, 3% hydrogen peroxide, povidone and cadexomer-iodine, and Dakin solution) in the treatment of DFU's [7]. Patients with diabetes have a higher risk of developing serious infections [8]. It is therefore advantageous to have an antiseptic that is not only effective against planktonic, biofilm and multiple drug-resistant pathogens, but also has no cytotoxicity against the healthy cells that are responsible for healing of the ulcer. Trifectiv® Plus used herein complies with these requirements and promoted healing [10, 11]. Debridement of DFU is regarded as an intervention that accelerates ulcer healing and may reduce complications including amputations, infections, and poor quality of life, which have serious public health and clinical implications [12]. HOCl-wetted gauze successfully treated this DFU with daily wet-to-moist debridement dressings, retained with a crepe bandage. Wet HOCl dressings assist with softening and removal of necrotic material, including dead biofilm [9]. Conservative wet to moist gauze debridement is safe and effective with minimal risk to the wound [13]. There is also significant reduction in the volume of exudate when using HOCl compared to other antiseptics, which is related to the control of inflammation and the bradykinin response [14]. Allowing the patients to be treated at home hold many advantages, e.g., it is more convenient, secure and less expensive than treatment from primary or secondary healthcare institutions and provides for an improved quality of life [15].

4. Conclusion

In these case study presentations, HOCl appears to be effective as a potent DFU antiseptic agent with anti-inflammatory and debridement properties. It is inexpensive, easy to use, safe, reduces odor and pain, as well as exudate. It is also not painful to apply, assisting in an elevated level of patient compliance. Based on *in vitro* studies, the antimicrobial activity of HOCl appears to be effective against MDR pathogens, which is a rising problem in the clinical environment, including DFU's. Clinicians should consider HOCl as a wound care product in the treatment of DFU's.

Conflict of Interest

H Roos: Co-founder of Trifectiv (Pty) Ltd, Stellenbosch,

South Africa.

ORCID: <https://orcid.org/0000-0002-2482-5395>

References

- [1] Martinez de Jesus FR, Ramos-De la Medina A, Remes-Troche JM, et al. Efficacy and safety of neutral pH super oxidized solution in severe diabetic foot infections. *Int Wound J*. 2007; 1742-481.
- [2] International Working Group on the Diabetic Foot. International consensus on the diabetic foot. Maastricht: International Working Group on the Diabetic Foot, 1999.
- [3] Raymakers JT, Houben AJ, Van Der Heyden JJ, Tordoir JH, Kitslaar PJ, Schaper NC. The effect of diabetes and severe ischemia on the penetration of ceftazidime into tissues of the limb. *Diabet Med* 2001; 18: 229-34.
- [4] Fowler E, Vesely N, Pelfrey M, Jordan S, Amberry T. Wound care for persons with diabetes. *Home Health Nurse* 1999; 17: 437-44.
- [5] Nakae H, Inaba H. Effectiveness of electrolyzed oxidized water irrigation in a burn-wound infection model. *J Trauma* 2000; 49: 511-4.
- [6] Dumville JC, Lipsky BA, Hoey C, Cruciani M, Fison M, Xia J. Topical antimicrobial agents for treating foot ulcers in people with diabetes. *Cochrane Database Syst Rev*. 2017; 6 (6): CD011038. Published 2017 Jun 14. doi: 10.1002/14651858.CD011038.pub.
- [7] Senneville E. Antimicrobial interventions for the management of diabetic foot infections. *Expert Opin Pharmacotherapy* 2005; 6: 263-73.
- [8] DG Armstrong et al. Expert recommendations for the use of hypochlorous solution: Science and clinical application. *Ostomy Wound Management* (2015) 61: 5, 1-20.
- [9] Mekaw, M., & Kamal, A. Randomized Clinical Trial: The Efficacy of Hypochlorous Acid on Septic Traumatic Wound. *Journal of Education and Practice* ISSN 2006; 2222-1735, Vol. 5.
- [10] <https://trifectiv.com/251120-mrsa-results/>;
<https://trifectiv.com/mdr-results/>
- [11] <https://trifectiv.com/antiviral-report/>
- [12] Dayya D, O'Neill O, Habib N, et al. Debridement of diabetic foot ulcers: public health and clinical implications – a systematic review, meta-analysis, and meta-regression *BMJ Surgery, Interventions, & Health Technologies* 2022; 4: e000081. doi: 10.1136/bmjst-2021-000081
- [13] Debridement Procedures for Managing Diabetic Foot Ulcers: A Review of Clinical Effectiveness, Cost-effectiveness, and Guidelines [Internet]. Ottawa (ON): Canadian Agency for Drugs and Technologies in Health; 2014 Sep 15. PMID: 25411677.
- [14] Robson, M. C. Bacterial degradation of growth factors. *J Appl Res*, 2003; 4: 30-35.
- [15] Gajarawala SN, Pelkowski JN. Telehealth Benefits and Barriers. *J Nurse Pract*. 2021 Feb; 17 (2): 218-221. doi: 10.1016/j.nurpra.2020.09.013. Epub 2020 Oct 21. PMID: 33106751; PMCID: PMC7577680.