

# Considerations on the Use of Lumina-Porous® Biomaterial in Maxillary Sinus Floor

Douglas Rangel Goulart<sup>1</sup>, Luciana Asprino<sup>1</sup>, Márcio de Moraes<sup>1</sup>, Claudio Ferreira Nóia<sup>2,\*</sup>

<sup>1</sup>Department of Oral Diagnosis, Piracicaba Dental School, University of Campinas, Piracicaba, Brazil

<sup>2</sup>Dentistry Department, University of Araras, Araras, Brazil

## Email address:

douglasgoulart@fop.unicamp.br (D. R. Goulart), asprino@fop.unicamp.br (L. Asprino), mmoraes@fop.unicamp.br (M. de Moraes), claudionoiia@uniararas.br (C. F. Nóia)

## To cite this article:

Douglas Rangel Goulart, Luciana Asprino, Márcio de Moraes, Claudio Ferreira Nóia. Considerations on the Use of Lumina-Porous® Biomaterial in Maxillary Sinus Floor. *International Journal of Biomedical Materials Research*. Vol. 3, No. 1, 2015, pp. 1-4.

doi: 10.11648/j.ijbmr.20150301.12

---

**Abstract:** Maxillary sinus floor augmentation procedure, aka sinus floor lift surgery, stand out within the universe of bone reconstruction given that the maxillary sinus is a closed cavity with favorable nutrition, which enables the use of biomaterials alone. Therefore, this study aimed to report and discuss the technical and biological peculiarities of Lumina-Porous® biomaterial alone in the maxillary sinus by describing a sinus lift case which presented with little remaining bone. After the graft incorporation period two implants were installed in the grafted area to provide proper patient rehabilitation.

**Keywords:** Bone Graft, Biomaterial, Predictability

---

## 1. Introduction

The loss of one or more teeth results in an imbalance between bone formation and bone resorption in the alveolar process, culminating in most cases in atrophies and alveolar bone defects in height, thickness, or a combination of both [1-2]. The posterior maxilla is no exception to this bone loss rule as it presents with peculiarities typical of the maxillary sinus [3].

After the posterior maxilla teeth are lost the maxillary sinus often increases its size through a process called pneumatization, which routinely results in not enough bone height for installation of dental implants, therefore requiring reconstructive surgery [2-3].

Due to peculiarities such as favorable nutrition and the fact that it is a closed sinus cavity not subjected to periosteum pressure, the maxillary sinus stands out as a unique entity within the universe of bone reconstruction surgery. Furthermore, these features afford a high degree of predictability when grafting the region [4-5].

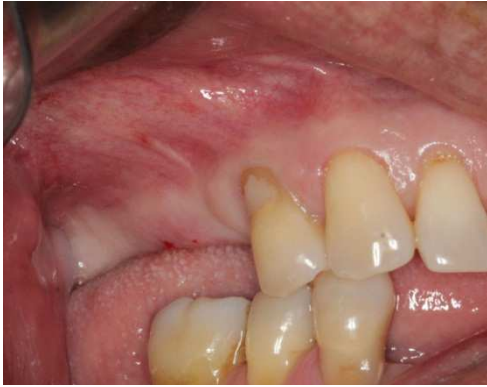As a result, surgical bone reconstruction in this region has evolved in recent years, and nowadays the use of autogenous grafts is virtually unnecessary and hardly ever performed at all [4].

Today, the use of biomaterials alone to perform maxillary sinus augmentation has been successfully reported in the scientific literature [2-5]. However, many professionals still question certain technical details of the procedure.

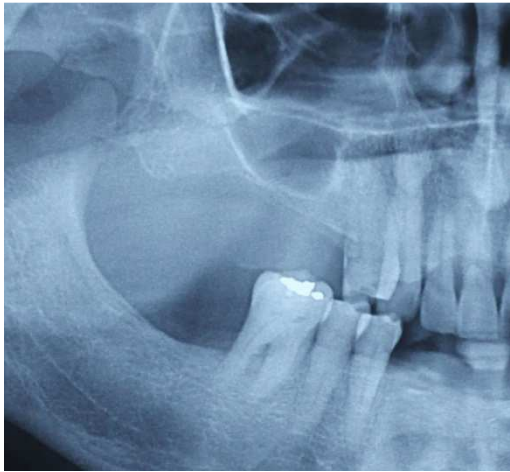
Given the above, the aim of this study was to report a clinical case involving a technique that makes use of Lumina-Porous® biomaterial in the maxillary sinus, as well as demonstrate the properties of the material in light of the results achieved.

## 2. Case Report

J.A., a 61-year-old male patient, presented of the Piracicaba Dental School, Campinas State University (FOP/Unicamp), for placement of dental implants. Patient history revealed missing teeth in the posterior maxilla for several years, and the use of a removable partial denture in the region. Clinical and radiographic examination indicated the need to rehabilitate teeth 15 and 16. In addition, bone height as far as the maxillary sinus floor was 1 mm, with good bone thickness in the region (Figures 1 and 2).



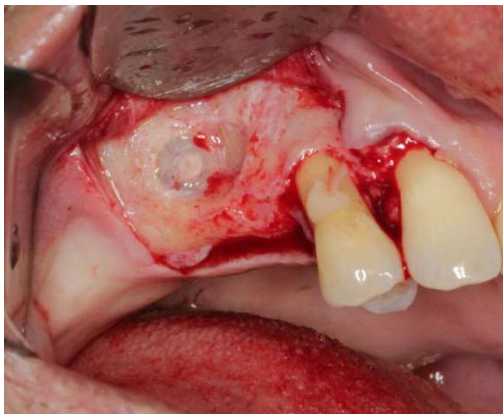
**Figure 1.** Initial photograph showing missing teeth, and good bone thickness in the region.



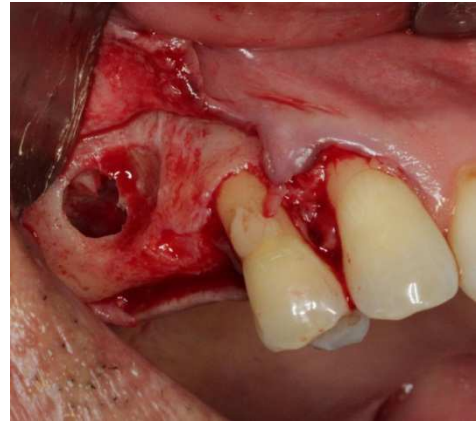
**Figure 2.** Partial view of panoramic radiograph showing missing teeth 15 and 16, and bone height of 1 mm as far as the maxillary sinus floor.

The proposed treatment plan consisted of bone graft using Lumina-Porous® biomaterial (Critéria, São Carlos/SP) and subsequent placement of dental implants.

The surgery was initiated with an incision and mucoperiosteal detachment in the region of teeth 13 and 14 and absence of teeth 15 and 16. Thereafter, an access window was opened to reach the floor of the maxillary sinus and detach the sinus membrane (Figures 3 and 4).

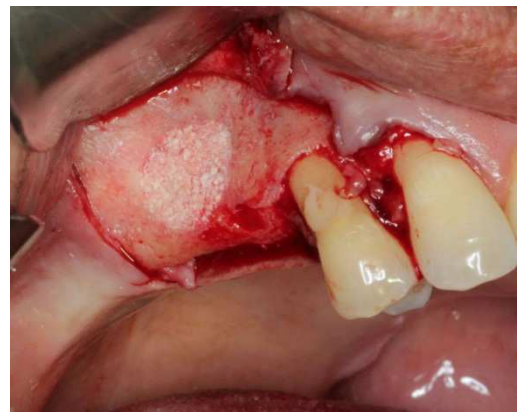

**Figure 3.** After incision and mucoperiosteal detachment a bone window was opened in the anterior wall of the maxilla to allow access and detachment of the sinus membrane.

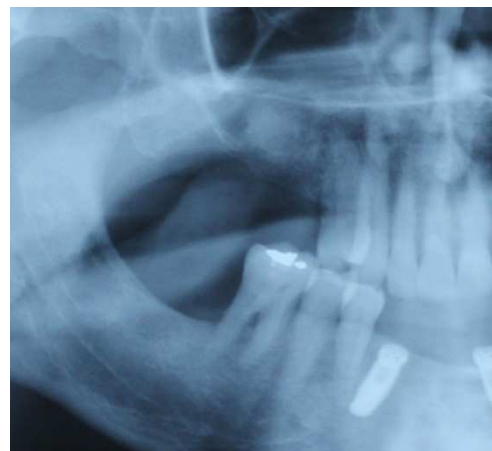

**Figure 4.** Space obtained after detachment of sinus membrane.

In continuing the surgical procedure, Lumina-Porous® (Critéria, São Carlos/SP) was manipulated with 0.9% saline (JP Indústria, Ribeirão Preto/SP), followed by careful placement of this mixture in the space created after detachment of the sinus membrane. The procedure was then finished by suturing with silk thread 3-0 (Johnson & Johnson do Brasil). Special care should be exercised to ensure that the material fills up the maxillary sinus so as not to compress it either too much or too little (Figures 5 and 6).

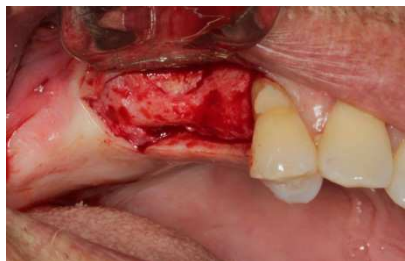

**Figure 5.** Proper filling of maxillary sinus with Lumina-Porous biomaterial. Complete filling of the cavity can be observed.

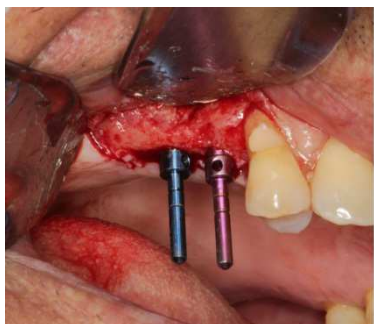

**Figure 6.** Partial view of panoramic radiograph showing proper filling of the maxillary sinus. As can be seen, the amount of material placed in the sinus was neither excessive nor insufficient.

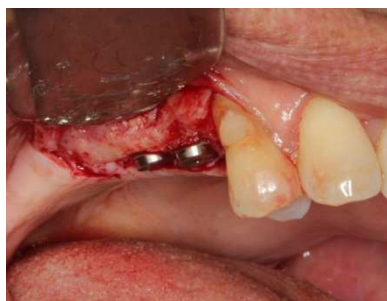After a 7-month period surgery was performed to place the implants in the grafted area. After careful mucoperiosteal detachment one can observe an excellent incorporation of the biomaterial, allowing the installation of two 4.0x11.5 implants (Titamax Neodent, Curitiba/PR) with 35 Ncm lock (Figures 7, 8, 9 and 10).



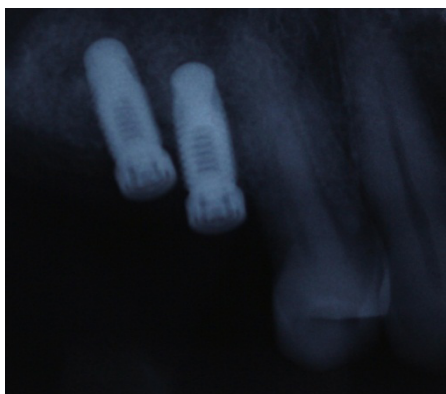**Figure 7.** Mucoperiosteal detachment for implant placement. Noteworthy in the figure is an excellent incorporation of the biomaterial in the region of the window created in the first surgery.



**Figure 8.** Parallel pins showing proper milling.



**Figure 9.** Placement of dental implants. At this time the 35 Ncm implants were locked.



**Figure 10.** Periapical radiograph showing dental implants in place.

### 3. Discussion

Modern implant dentistry aims to restore the patient's masticatory and phonetic functions while providing comfort and aesthetics despite the presence of other conditions such as atrophy, disease or injury in the stomatognathic system [6-8]. Accordingly, oral rehabilitation with dental implants is seen as a valid procedure given that it is predictable, long lasting and effective for the treatment of single-unit, partially or totally edentulous patients. However, certain clinical situations often emerge which make this type of rehabilitation very challenging, requiring more complex surgical techniques such as bone grafting [9-12].

Scientific evidence reveals that maxillary implant success depends on the quantity and quality of available bone. Moreover, bone grafts have the ability to readjust atrophic ridges and afford a success rate similar to what is achieved in non-reconstructed areas [1,3,5,16,18].

Favorable nutrition and the fact that a closed sinus cavity is not influenced by the periosteum enabled maxillary sinus lift surgery to advance enormously in recent years, evolving from a period in which the placement of autogenous bone was an essential factor for success to the present day, where basically only biomaterials are used for this purpose [4-5].

In this clinical case, despite the fact that only 1 mm of bone remained, maxillary sinus floor lift was performed using Lumina- Porous® biomaterial, and 7 months thereafter two implants were installed with 35 Ncm lock. These results are in agreement with those found in the literature [3-5] and demonstrate the effectiveness and safety of using this biomaterial alone in the maxillary sinus.

An important factor when using biomaterials in the maxillary sinus has to do with compaction [13-14]. Lumina-Porous® must fill the space neither excessively nor insufficiently.

Should it be compressed in excess, no blood clot is formed and therefore no repair process occurs. Thus, upon reopening the site for placing the implants one will find only an agglomeration of biomaterial. The implant might even be successfully locked but osseointegration is highly unlikely to occur.

Conversely, the opposite may occur if the material is insufficiently compressed and the amount of material placed is not enough to provide osteoconductivity. In this case there will be large areas of blood clots, which will eventually turn into loose connective tissue.

Therefore, placing an adequate amount of material, just enough to fill up the space that was created in the floor of the maxillary sinus in an appropriate manner is paramount for a successful procedure when using Lumina-Porous® biomaterial.

### 4. Conclusions

The use of Lumina-Porous® biomaterial in the maxillary sinus, even in cases where there is little bone remaining, can yield successful dental implant results, provided certain technical and biological criteria of the procedure are met.

## References

- [1] Nóia CF, Ferreira-Nóia C, Marques TR, Pinto JMV, Ortega-Lopes R. Influência do gênero e da idade no processo de reparo ósseo. Estudo radiográfico prospectivo em 30 pacientes. *Implantnews*. 2012; 9(6a-PBA):189-94.
- [2] Kuhl S, Gotz H, Brochhausen C, Jakse N, Filippi A, d'Hoedt B, et al. The influence of substitute materials on bone density after maxillary sinus augmentation. A microcomputed tomography study. *Int J Oral Maxillofac Implants*. 2012; 27(6):1541-6.
- [3] Kuhl S, Brochhausen C, Gotz H, Filippi A, Payer M, d'Hoedt B, et al. The influence of bone substitute materials on the bone volume after maxillary sinus augmentation. A microcomputed tomography study. *Clin Oral Invest*. 2013; 17(2):543-51.
- [4] Richart D, Slater JJ, Meijer HJ, Vissink A, Raghoobar GM. Maxillary sinus lift with solely autogenous bone compared to a combination of autogenous bone and growth factors or (solely) bone substitutes. A systematic review. *Int J Oral Maxillofac Surg*. 2012; 41(2):160-7.
- [5] Maiorana C, Beretta M, Batista Grossi G, Santoro F, Scott Herford A, Nagurski H, et al. Histomorphometric evaluation of anorganic bovine bone coverage to reduce autogenous grafts resorption: preliminary results. *Open Dent J*. 2011; 25(5):71-8.
- [6] Stabile GAV. Avaliação retrospectiva de oito anos dos procedimentos implantodônticos associados ou não a procedimentos reconstrutivos realizados na Área de Cirurgia Buco-Maxilo-Facial da Faculdade de Odontologia de Piracicaba. [dissertação]. Piracicaba (SP): Universidade Estadual de Campinas; 2006.
- [7] Pereira-Filho VA, Hochuli-Vieira E, Gabrielli MAC, Queiroz TP, Chávez OFM. Distração osteogênica mandibular para instalação de implantes: Relato de caso. *Rev Cir Traumatol Buco-Maxilo-Fac*. 2007; 7(1):51-58.
- [8] Rodríguez-Chessa JG. Tratamento de maxilas atroficas por meio de fixações zigomáticas. Análise retrospectiva de 03 anos, [tese]. Piracicaba (SP): Universidade Estadual de Campinas; 2009.
- [9] Nóia CF. Avaliação radiográfica prospectiva de alterações estéticas em pacientes submetidos à remoção de enxerto de mento [dissertação]. Piracicaba (SP): Universidade Estadual de Campinas; 2011.
- [10] Nóia CF, de Oliveira NK, Ferreira-Nóia C, Ortega-Lopes R, Mazzonetto R. Utilização da crista ilíaca nas reconstruções ósseas da cavidade oral: Relato de Caso. *Rev Dental Press Periodontia Implantol*. 2011; 5(2):74-82.
- [11] Acocella A, Bertolai R, Nissan J, Sacco R. Clinical, histological and histomorphometri cevaluation of the healing of mandibular ramus bone block grafts for alveolar ridge augmentation before implant placement. *J Cranio-Maxillo-Fac Surg*. 2010; 38(2); 22-30.
- [12] Ortega-Lopes R, Nóia CF, Chaves Neto HDM, Andrade VC, Cidade CPV, Mazzonetto R. Otimização em reconstrução total de maxila através da modificação estrutural do enxerto e diminuição do intervalo cirúrgico. *Implantnews*. 2012; 9(3):383-92.
- [13] Monje A, Monje F, Hernandez-Alfaro F, González-Garcia R, Suarez F, Galindo-Moreno P, et al. Horizontal bone augmentation using autogenous block brafts and particulate xenograft in the severe atrophic maxillary anterior ridges. *J Oral Implantol*. 2014; no prelo.
- [14] Cosso MG, de Brito RB Jr, Piattelli A, Shibli JA, Zenóbio EG. Volumetric dimensional changes of autogenous bone and the mixture of hydroxyapatite and autogenous bone graft in humans maxillary sinus augmentation. A multislice tomography study. *Clin Oral Implants Res*. 2014; 25(11):1251-5.