



Case Report

Congenital Nasal Dermoid Sinus Cyst in Children

Khalid Shreef^{1, 2, *}, Wael Hammad², Ahmed Nassar^{2, 3}, Ahmed Al-Azab², Ahmed Alawaji²

¹Department of Pediatric Surgery, Zagazig University, Zagazig, Egypt

²Department of Pediatric Surgery, Armed Forces Hospital Southern Region, Asser, Saudi Arabia

³Department of Dermatology and Venereology, Tanta University, Tanta, Egypt

Email address:

khshreef2013@gmail.com (K. Shreef)

*Corresponding author

To cite this article:

Khalid Shreef, Wael Hammad, Ahmed Nassar, Ahmed Al-Azab, Ahmed Alawaji. Congenital Nasal Dermoid Sinus Cyst in Children. *International Journal of Clinical Dermatology*. Vol. 1, No. 1, 2018, pp. 5-8. doi: 10.11648/j.ijcd.20180101.12

Received: May 2, 2018; **Accepted:** June 7, 2018; **Published:** June 28, 2018

Abstract: Background: Nasal dermoid sinus cyst is a rare congenital anomaly affecting approximately 1 in 20,000–40,000 live births. It is liable for infection and may communicate with the central nervous system. The treatment is complete surgical excision. Case history: Nine months old male presented by a pea-size fronto-nasal swelling over the nasal bridge since birth, gradually increasing in size with recent history of local redness and discharge. Sagittal CT of the skull showed osteolytic lesion at the fronto-nasal bone with eroded inner and outer tables. MRI showed no intracranial extension. Surgical excision was done by combined nasal and bicoronal incisions. A big abscess cavity was encountered at the fronto-nasal bone junction. The diagnosis of Nasal dermoid sinus cyst was confirmed by histopathology. The patient was followed in the outpatient clinic; MRI was done after one month. No recurrence was detected.

Keywords: Congenital Midface Anomalies, Nasal Dermoid, Fronto-nasal Swelling

1. Introduction

Nasal dermoid is a rare congenital anomaly affecting approximately 1 in 20,000–40,000 live births. [1, 2] Although it is quite rare, they are one of the more common congenital midline nasal masses identified in children. [3] Nasal dermoids usually present as a painless subcutaneous mass or pit often with a tuft of short, fine hair near the junction of nasal bones and upper lateral cartilages of the nose, also known as the rhinion. [4] Complicating features associated with nasal dermoids include sinus tracts, intracranial extension, and infections. It is liable for infection and may communicate with the central nervous system. The treatment is complete surgical excision. [2, 5] Imaging is required for surgical planning. CT scan is helpful to evaluate for any bony lacunae, patent foramen cecum, patent fonticuli, or bifid crista galli that might point to skull base involvement, and MRI is used to rule out an encephalocele, glioma, or other intracranial process. [6]

2. Case Report

Nine months old male was referred from dermatology clinic. The patient had a pea-size fronto-nasal swelling over the nasal bridge. The swelling was noticed since birth, gradually increasing in size with recent history of local redness and discharge. No past history suggesting intracranial infection or meningitis. On local examination; a small swelling about 0.5x0.5 cm was seen over the nasal bridge with hair tufts projecting through it. The overlying skin was mildly inflamed (figure 1). On palpation the lesion was non pulsatile, non-compressible, no visible discharge with normal midline nasal septum. No visible associated craniofacial anomalies. No positive family history. Sagittal CT of the skull showed osteolytic lesion at the fronto-nasal bone with eroded inner and outer tables, a small sinus tract and bifid crista galli suggesting a possible intracranial extension (figure 2). MRI was requested, it showed no intracranial extension (figure 3).

A combined nasal and bicoronal incisions was the approach of choice. Under general anesthesia, the bicoronal incision

was made with dissection of the anterior flap down to the root of the nose. A big abscess cavity was encountered at the fronto-nasal bone junction (figure 4). The cavity was full of yellowish purulent material and bone fragments. A culture swab for taken, abscess cavity was drained, the bone was curetted and filled with BioGlue. The sinus tract was cannulated with lacrimal probe through the external opening up to the internal one (figure 5), then the whole tract was completely excised from inside-out to avoid making large external scar.

The diagnosis of Nasal dermoid sinus cyst was confirmed by histopathology. The patient was followed in the outpatient clinic; MRI was done after one month. No recurrence was detected (figure 6, 7).

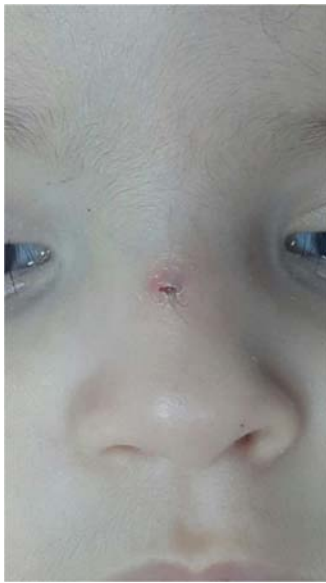

Figure 1. Pre-operative.

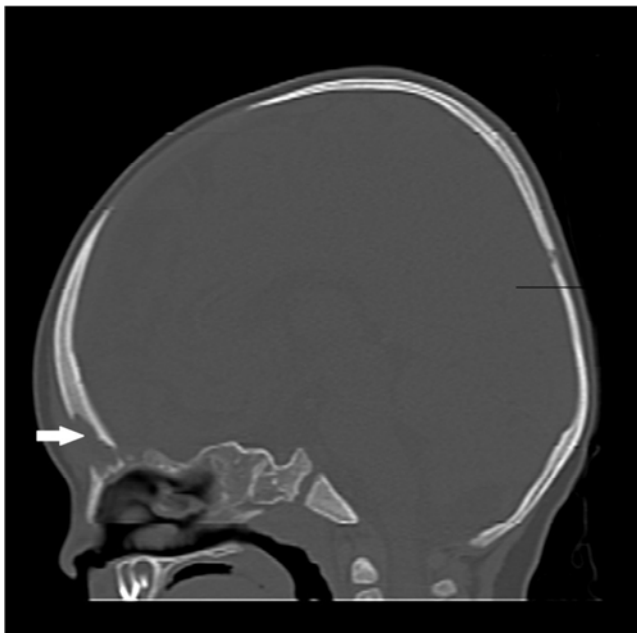


Figure 2. Sagittal CT of the skull showing osteolytic lesion at fronto-nasal Bone with eroded inner and outer tables.

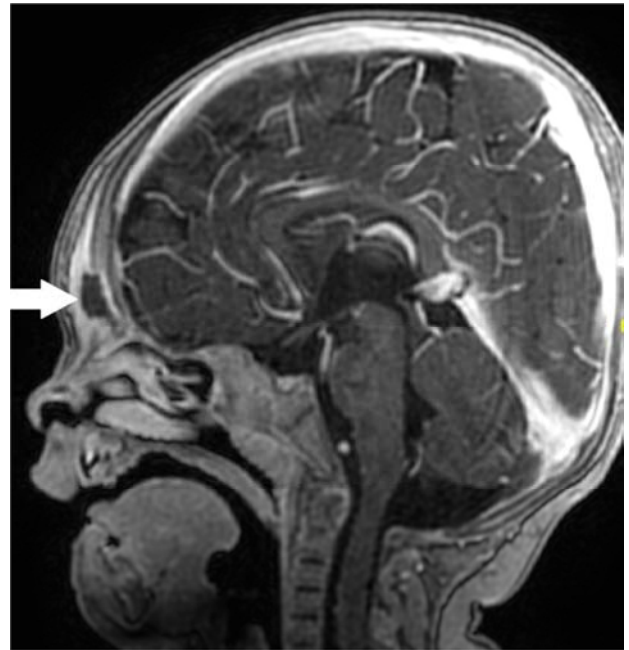

Figure 3. Mid sagittal T1 Post contrast MRI. Frontal bone osteolytic lesion with marginal enhancement (arrow). No intracranial extension.

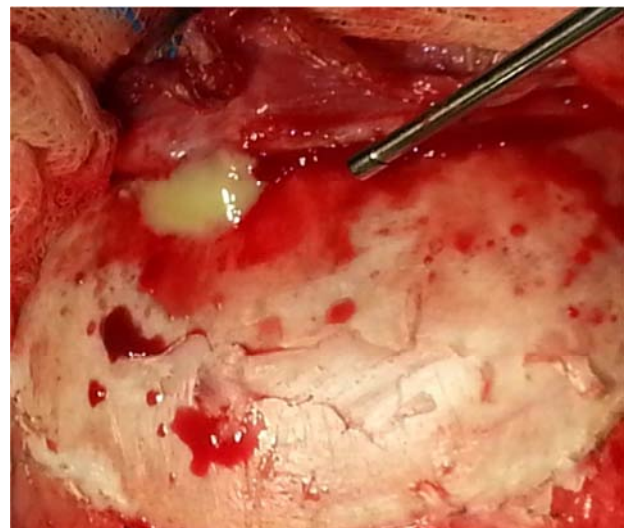


Figure 4. A big abscess cavity.

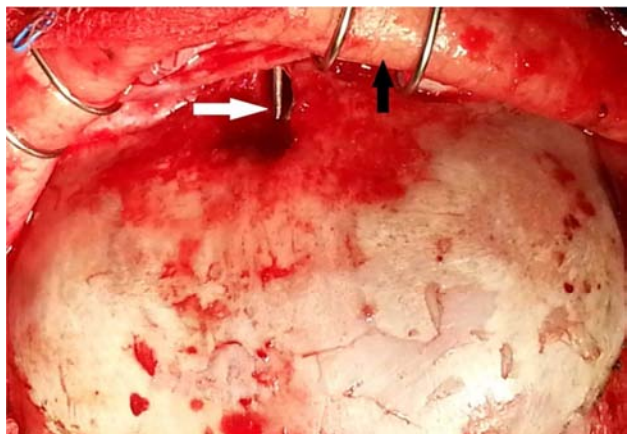


Figure 5. A probe in the internal end of the sinus (white arrow) after dissection of the anterior flap (black arrow).

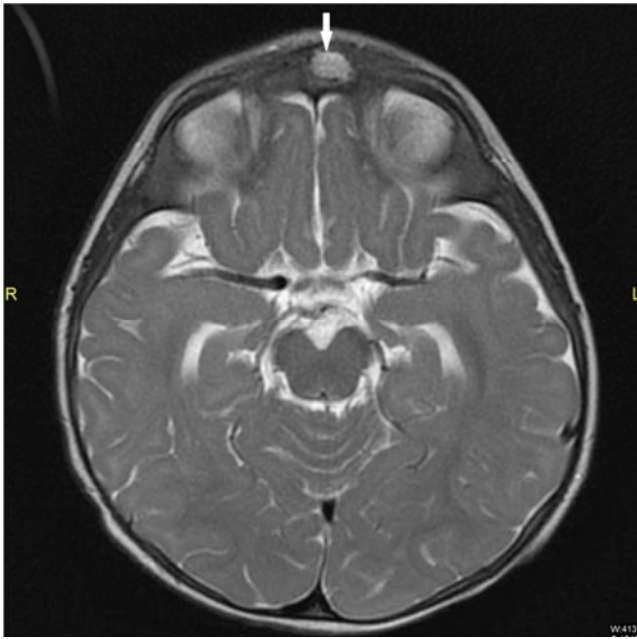


Figure 6. Post-operative axial T2 showing the BioGlue filling the abscess cavity.

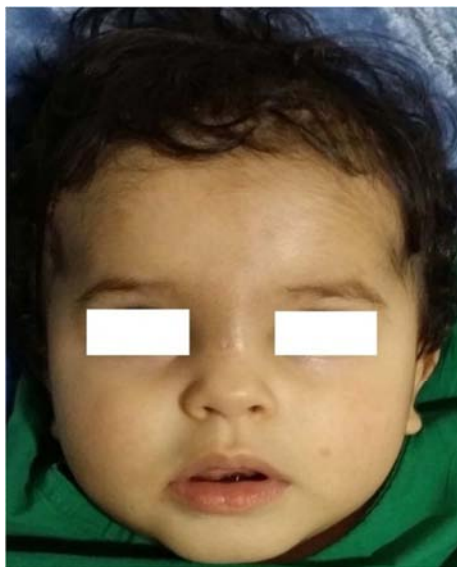

Figure 7. One month post-operative.

3. Discussion

Naso-frontal masses in pediatrics belong to a group of congenital midface anomalies (CMFA). [2] The CMFA result from faulty regression of the embryologic dural diverticulum from the prenasal space due to delayed closure of patent fonticulus nasofrontalis (a temporary gap at the junction of nasal and frontal bones). [7] Nasofrontal masses are usually manifest at birth but can appear at any age. Most patients present in infancy and early childhood. [7] The most common midline nasofrontal anomalies are: nasal dermoid or epidermoid, nasal encephalocele and nasal glioma. [8] A clear understanding of several features of nasal dermoid sinus cysts is critical to the diagnosis and management of this condition.

The nasal dermoid, unlike the other craniofacial dermoids, can present as a cyst, sinus or fistula. [9] The nasal dermoid cyst with hair containing sinus opening on the dorsum of the nose was first described in 1817. [10] the terminology has been confusing for long period until Sessions coined the term *nasal dermoid sinus cyst* (NDSC) to include all lesions containing ectoderm (stratified squamous epithelium) and mesoderm (adenexal structure) located in the nose. They represent less than 1% of all dermoids of the body. [11] NDSC are usually localized to the nasal dorsum but may occur less frequently in the nasal septum, glabella, tip, and columella. [12]. Progressive enlargement of the NDSC can cause skeletal deformity, local infection, meningitis and brain abscess. [9, 13] Presented with the need for excision, an consideration is how to best establish the true extent of the lesion so that an appropriate surgical plan is developed. The objective of imaging studies is to confirm the clinical diagnosis and to delineate any intracranial involvement if present. The complementary roles of CT and MRI appear well established in congenital midline nasal masses. [14] CT imaging is crucial for evaluation of the osseous involvement while MRI provides vital information about the intracranial extent and detailed tissue characterization. [15] Many children will require general anesthesia for adequate MRI evaluation, and the invasiveness of this procedure has been justified by improved planning by several authors [14] Surgical excision of NDSC remains the standard of care. Surgical strategy is determined by the presence or absence of intracranial extension and the presence or absence of a sinus tract. [2] In the absence of intracranial extension, a variety of extracranial techniques were employed. Excision and direct primary closure is the most straightforward and has the advantage of removing abnormal skin overlying a cyst or the opening of a sinus. Incisional wounds, particularly those oriented vertically, are well tolerated. Surgical scars generally settle well, and the surgeon has an opportunity to remove dysplastic or stretched skin over a sinus. Open rhinoplasty, either alone or combined with a direct excision, offers the opportunity to correct the position of the alar cartilages, which are often splayed by a lesion at the nasal tip. A sinus tract may be followed to the nasofrontal suture via an open rhinoplasty. Endoscopic approaches are useful for superficial lesions with no extension that lie in the glabellar region. The need for an exposed scar is avoided. [16, 17] However, if the NDSC has intracranial extension then a craniotomy is required. Various techniques have been described, removing all or part of the frontal bones via a coronal or subcranial approach. [14] The technique used in our case was a combined nasal and bicoronal incisions to approach both the intracranial and extracranial components of the NDSC. Debridement of necrotic, infected frontal bone was required to eliminate chronic osteomyelitis. This resolved successfully with antibiotics in the postoperative period. Few details exist in the literature about the rate of recurrence and other complications after treating nasal dermoid sinus cysts. In our case, no recurrence was detected during the follow up period.

4. Conclusion

Nasal dermoid sinus cysts are rare congenital midline nasal lesions. Some patients might have intracranial extension so that CT imaging is crucial for evaluation of the osseous involvement while MRI provides vital information about the intracranial extent and detailed tissue characterization and tailoring the definitive surgery. The gold standard for the treatment is surgical removal with complete excision of associated sinus and skin tract.

References

- [1] Moses MA, Green BC, Cugno S, et al. The management of midline frontonasal dermoids: a review of 55 cases at a tertiary referral center and a protocol for treatment. *Plast Reconstr Surg* 2015; 135: 187-96.
- [2] Vikram S, Sanjeev S, Amit K, Rajesh u. Nasal dermoid cyst with intracranial extension and an atretic dermal sinus tract. *Medical Journal of Dr. D. Y. Patil University*. 2012; 51: 47.
- [3] Zapata S, Kearns DB. Nasal dermoids. *Curr Opin OtolaryngolHead Neck Surg* 2006; 14: 406-11.
- [4] Reissis D, Pfaff M, Patel A, Steinbacher D. Craniofacial dermoid cysts. *YALE J Biol Med* 2014; 87: 349-57.
- [5] Klein O, Simon E, Coffinet L, Joud A, Ghetemme C, Marchal J-C. Nasal dermal sinus in children: A review based on a series of 6 cases. *Neurochirurgie*. 2014; 60 (1-2): 27-32.
- [6] Herrington H, Adil E, Moritz E, et al. Update on current evaluation and management of pediatric nasal dermoid. *Laryngoscope*. 2016; 126: 2151-60.
- [7] Fitzpatrick E, Miller RH. Congenital midline nasal masses: Dermoids, gliomas, and encephaloceles. *J La State Med Soc* 1996; 148: 93-6.
- [8] Hedlund G. Congenital frontonasal masses: Developmental anatomy, malformations, and MR imaging. *Pediatr Radiol* 2006; 36: 647-62; quiz, 726-7.
- [9] Rahbar R, Prerak S, Mulliken J, Carolin D, Antoni R, Atiyade P, Mark R, Margret A, Micheal R, Trevor J, Gerald B. The presentation and management of nasal dermoids. *Archive otolaryngeal head Neck Surgery*. 2003; 129: 464-472.
- [10] Sessions RB. Nasal dermoid sinuses: new concept and explanation. *Laryngoscope*. 1982; 92: 1-28.
- [11] Crawford JK, Webster JP. Congenital dermoid cysts of the nose. *Plast Reconstr Surg* 1952; 9: 235-260.
- [12] Hacker DC and Freeman J L. Intracranial extension of a nasal dermoid sinus cyst in a 56 year old man. In *Head & neck*. John Wiley & Sons, Inc, 1994; 16: 36 & 371.
- [13] Frassanito P, Tamburrini G, Caldarelli M. Brain Abscess and Unusual Nasal Pimple in a Child. *World Neurosurg* 2017; 101: 811. e5.
- [14] Will E., Chow W, Anthony D. and John G. Nasal Dermoid Sinus Cysts A retrospective Review and Discussion of Investigation and management. *Annals of Plastic Surgery* 2006; 57: 535-540.
- [15] Kennard C, Rasmussen J. Congenital midline nasal masses: Diagnosis and management. *J Dermatol Surg Oncol* 1990; 16: 1025-36.
- [16] . Bilkay U, Gundogan H, Ozek C, et al. Nasal dermoid sinus cysts and the role of open rhinoplasty. *Ann Plast Surg*. 2001; 47: 8-14.
- [17] Rohrich RJ, Lowe JB, Schwartz MR. The role of open rhinoplasty in management of nasal dermoid cysts. *Plast Reconstr Surg*. 1999; 104: 2163-2171.