



## Case Report

# Primary Osteogenic Sarcoma of the Breast: A Rare Breast Cancer Presentation in Malaysia

Fitreena Anis Amran<sup>1</sup>, Ikhwan Sani Mohamad<sup>2,\*</sup>, Maya Mazuwin<sup>2</sup>, Syed Hassan Syed Aziz<sup>2</sup>, Zaidi Zakaria<sup>2</sup>, Imran Abd Khalid<sup>3</sup>

<sup>1</sup>Advanced Medical and Dental Institute, Universiti Sains Malaysia, Pulau Pinang, Malaysia

<sup>2</sup>Endocrine and Breast Unit, Department of Surgery, Universiti Sains Malaysia, Kelantan, Malaysia

<sup>3</sup>General Surgery Department, Hospital Seberang Jaya, Pulau Pinang, Malaysia

## Email address:

ikhwansani@yahoo.com.my (S. M. Ikhwan)

\*Corresponding author

## To cite this article:

Fitreena Anis Amran, Ikhwan Sani Mohamad, Maya Mazuwin, Syed Hassan Syed Aziz, Zaidi Zakaria, Imran Abd Khalid. Primary Osteogenic Sarcoma of the Breast: A Rare Breast Cancer Presentation in Malaysia. *International Journal of Clinical Oncology and Cancer Research*. Vol. 2, No. 5, 2017, pp. 110-112. doi: 10.11648/j.ijcocr.20170205.13

Received: April 8, 2017; Accepted: August 10, 2017; Published: September 23, 2017

**Abstract:** Osteogenic sarcoma are malignant mesenchymal neoplasms in which the neoplastic cells produce osteoid and it is the commonest primary bone tumour. However, cases of extra-skeletal osteogenic sarcoma has been reported worldwide occurring in breast, colon and even myocardium Extra-skeletal sarcomas tend to occur in patient over 50 years old. Primary osteogenic sarcoma of the breast is very rare and accounted less than 0. 1% of breast cancer. This is a case of a 44-year-old lady who was diagnosed with primary osteogenic sarcoma of the breast and the difficulty encountered in managing it. The long-term prognosis is uncertain due to the small number of cases reported in the medical literature worldwide.

**Keywords:** Breast, Sarcoma, Bone, Neoplasm

## 1. Introduction

Breast cancer is the commonest female cancer in Peninsular Malaysia with 3525 cases reported in 2006 accounting for 16.5% of all cancer registration [1]. This data is almost the same as recorded in Penang state cancer registry 1996, suggesting at least 3500 cases occur annually in Malaysia [2, 3]. Commonly, breast cancer arises either from ductal or lobular cells of the breast tissue. The most common form of breast cancer is infiltrating ductal carcinoma. However, there are few uncommon types of breast cancers including sarcomas, myoepitheliomas and lymphomas.

Osteogenic sarcoma are malignant mesenchymal neoplasms in which the neoplastic cells produce osteoid and it is the commonest primary bone tumour [4]. However, cases of extra-skeletal osteogenic sarcoma has been reported worldwide occurring in breast, colon and even myocardium [5].

In contrarily to primary osteogenic sarcoma of the bone

which occurs mainly in children and adolescent, extra-skeletal sarcomas tend to occur in patient over 50 years old [6]. The most common type of breast sarcoma is Phyllodes Tumour or Cystosarcoma Phyllodes which occur in less than 10% of all breast cancer. Primary osteogenic sarcoma of the breast is extremely rare and accounted less than 0. 1% of breast cancer [7].

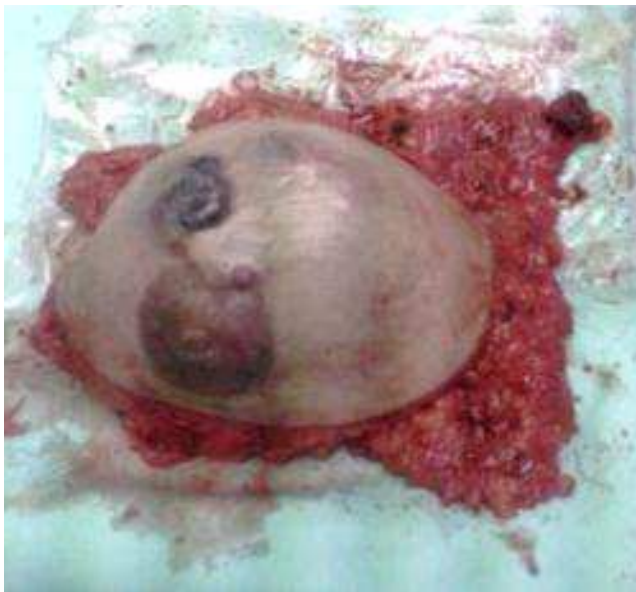## 2. Case Report

A 44-year-old lady presented to breast clinic with complaint of progressively increase in size of left breast lump for four months duration. The lump was painless. There was no nipple discharges or skin changes. No history of fever or constitutional symptoms. Other systemic review was unremarkable. She was single and nulliparous with no family history of breast cancer.

Physical examination revealed a huge left breast lump measuring 15x15cm involving both lower quadrant and upper outer quadrant. It was firm to hard in consistency with irregular surface and attached to the skin and underlying structure. However, no nipple retraction, nipple discharge or skin changes noted. No axillary lymph nodes felt. Our impression at that time was left breast carcinoma with clinical staging T4N1Mx. Core biopsy of her left breast was performed and was planned for mammogram of the right breast and CT thorax, abdomen and pelvis to rule out any metastases.

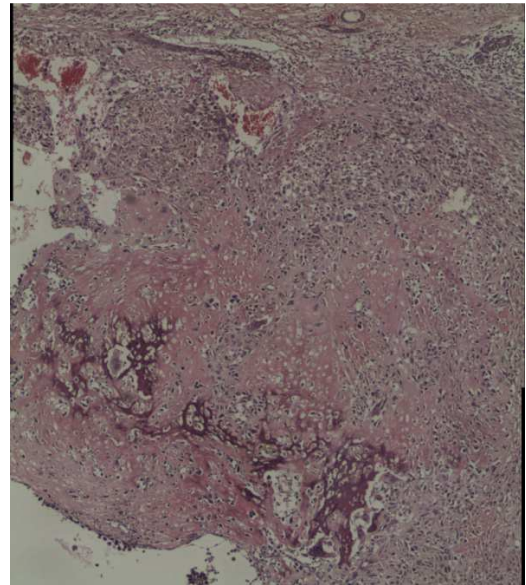
Her first left trucut biopsy reported as acute on chronic mastitis with no malignant changes. There was no mammogram done to her due to very large left breast mass. She was subjected to CT scan thorax, abdomen and pelvis. Her CT scan was reported as left breast carcinoma with liver metastasis. In view of her CT scan suggestive of breast carcinoma another core biopsy was repeated with a report of chronic inflammation. She was treated with a course of antibiotic.

However since her breast lump was increasing in size and causing pain to her she was advised and agreeable for left mastectomy with axillary sampling. Her provisional clinical diagnosis was left breast cancer with liver metastasis. Intraoperative findings were left breast mass which was fixed to pectoralis major. (Figure 1) Multiple breast satellite nodules and axillary lymph nodes were present. Left mastectomy with axillary clearance was performed.



**Figure 1.** Operative specimen: Left breast specimen with multiple satellite nodules and axillary lymph nodes.

On follow up, the histopathology reported as left breast osteogenic sarcoma with clear margins and no lymph nodes invasion. (Figure 2) She was then referred to oncology for further management.



**Figure 2.** Histology report: The tumors are spindle shaped to polygonal arranged in fascicles. They produce osteoid. There are many multinucleated osteoclastic giant cells and high mitotic activity. Nuclear pleomorphism was marked.

### 3. Discussion

Primary osteogenic sarcoma of the breast carcinogenesis is not well understood but few hypotheses have been suggested. Among the hypotheses suggested was overgrowth of totipotent mesenchymal cells of breast stroma and transformation of pre-existing breast lesion either from benign or malignant tissue [8]. Diagnosis of primary osteogenic sarcoma of the breast is only made once direct extension of an osteogenic sarcoma arising from the ribs or sternum excluded [8].

An accurate pre-operative diagnosis of osteogenic sarcoma from fine needle aspiration and trucut biopsy is unusual and only established postoperatively after full histopathology examination (HPE) of the breast; as occurred in this case report [9].

Dilemma occurring in managing this patient initially was that the HPE result from her first core biopsy suggestive of inflammatory reaction of the breast. This has delayed her treatment as further investigation need to be carried out and course of antibiotic was given. The decision of performing mastectomy was done after reviewing her CT scan report and due to the increasing of the breast mass size.

Her report showed clear margin which give a good prognosis with regard to local disease recurrence [10]. There was few axillary lymph nodes seen and axillary sampling for frozen section was done. Her histopathology report however revealed no positive nodes and no lymphovascular space invasion. Axillary clearance is not necessary as these tumours do not spread via the lymphatic route but spread through the blood vessel [10].

After operation, a confirmed case of malignancy should be assessed by oncologist for further chemo radiation treatment.

In this patient, the role of neoadjuvant chemotherapy is not advocated as the tissue biopsy did not suggest of malignancy. Even if it is suggestive of sarcoma on initial tissue biopsy, the role of neoadjuvant chemotherapy in downsizing the tumour size is unclear [11]. In primary osteogenic sarcoma of the bone, adjuvant chemotherapy with either doxorubicin, cisplatin or ifosfamide based regimes has increased the survival of primary bone sarcomas. However, there are no proven benefits to the use of these regimes in primary osteogenic sarcoma of the breast [11]. Nevertheless, the use of chemotherapy in metastases osteogenic sarcoma may be considered as occurred in this patient which her CT scan showed few liver lesions suggestive of metastases [1].

Osteogenic sarcoma is also an aggressive tumour with high risk of recurrence. Thus, chest wall irradiation (radiotherapy) is indicated. In view of it high recurrence rate, regular follow up and early detection of metastasis is needed [12].

#### 4. Prognosis

The long-term prognosis is uncertain due to the small number of cases reported in the medical literature worldwide. In a small scale study of 50 patients with primary breast osteosarcoma by Silver *et al*, the 5 year survival rates are only 38%. 28% of patients developed local recurrence and 41% distant metastases. Also noted from the study, haematogenous metastases most commonly occur to the lungs (80%), bone (20%), and liver (17%). Prognostic factors included tumour size, number of mitoses, presence of stromal atypia, histological subtype and resection margin involvement [7].

This patient only managed to undergo 3 cycle of chemotherapy and passed away after 7 month post-operative.

#### 5. Conclusion

Due to limited cases reported in Malaysia and worldwide regarding osteogenic sarcoma of the breast, the exact guidelines in managing this cancer is still vague. The roles of neoadjuvant and adjuvant chemotherapy still need to be improvised and analyzed.

#### References

- [1] Malaysian Cancer Statistics Data and Figure Peninsular Malaysia 2006, National Cancer Registry, Ministry of Health Malaysia 2006.
- [2] Management of Breast Cancer, Clinical Practice Guidelines Malaysia 2002.
- [3] Vital Statistics Malaysia. Kuala Lumpur: Department of Statistics 1999.
- [4] Robbins Basic Pathology, 7<sup>th</sup> Edition 2002.
- [5] Irshad K, Mann BS, Campbell H: Primary osteosarcoma of the breast. *Breast* 2003, 12:72-74.
- [6] Adem C, Reynolds C, Ingle JN, Nascimento AG: Primary breast sarcoma: clinicopathologic series from the Mayo Clinic and review of the literature. *Br J Cancer* 2004, 91:237-241.
- [7] Silver SA, Tavassoli FA: Primary osteogenic sarcoma of the breast: a clinicopathologic analysis of 50 cases. *Am J Surg Pathol* 1998, 22:925-933.
- [8] Ninomiya J, Oyama T, Horiguchi J, Koibuchi Y, Yoshida T, Iijima K, Yoshida M, Takata D, Iino Y, Morishita Y: Two cases of breast cancer with cartilaginous and osseous metaplasia. *Breast Cancer* 2005, 12:52-56.
- [9] Ogundiran TO, Ademola SA, Oluwatosin OM, Akang EE, Adebamowo CA: Primary osteogenic sarcoma of the breast. *World J Surg Oncol* 2006, 4:90.
- [10] McGowan TS, Cummings BJ, O'Sullivan B, Catton CN, Miller N, Panzarella T: An analysis of 78 breast sarcoma patients without distant metastases at presentation. *Int J Radiat Oncol Biol Phys* 2000, 46:383-390.
- [11] Temidayo O Ogundiran, Samuel A Ademola, Odunayo M Oluwatosin, Effiong E Akang, and Clement A Adebamowo Primary osteogenic sarcoma of the breast. *World J Surg Oncol* 2006; 4: 90.
- [12] Shabuddin Khan, Ewen A Griffiths, Nigam Shah, Srinivasan Ravi. Primary osteogenic sarcoma of the breast: A case report. *Cases Journal* 2008, 1:148.