



Case Report

Management of Facial Space Infection in a 9-Year-Old Child - A Case Report

Khaja Khalid Nawaz M.

Department of Oral and Maxillofacial Surgery, Dr.H. Gordon Roberts Hospital, Meghalaya, India

Email address:

khalidnawazm@yahoo.com

To cite this article:

Khaja Khalid Nawaz M. Management of Facial Space Infection in a 9-Year-Old Child - A Case Report. *International Journal of Clinical Oral and Maxillofacial Surgery*. Vol. 2, No. 1, 2016, pp. 1-4. doi: 10.11648/j.ijcoms.20160201.11

Received: March 2, 2016; **Accepted:** March 30, 2016; **Published:** May 10, 2016

Abstract: *Background:* Fascial space infections of the head and neck region are usually odontogenic in origin. An untreated or rapidly spreading odontogenic infections can be potentially life threatening. The present case report describes a patient with orofacial infections who required emergent incision and drainage in the oral and maxillofacial surgery OPD at our hospital. *Conclusion:* Fascial space infections of the head and neck region, though potentially life threatening, can be prevented by regular dental visits. Early recognition and treatment of the infections are necessary to prevent considerable morbidity and mortality, especially in younger patients where more care should be given for oral health. Successful results can be achieved for pediatric patients who can be treated with Incision and Drainage, removal of etiologic factor followed by a combo of three antibiotics.

Keywords: Fascial Space Infection, Incision and Drainage, Antibiotics, Extraction

1. Introduction

Dental disease is the underlying cause of most of inflammatory swellings which occurs either in or around the jaws. Inflammation may commence either at the root apices or gingival margins of erupted teeth, or in the soft tissues which surround and overlie the crown of an unerupted or partially erupted tooth. Inflammation around the apices of tooth root may result in the formation of pus. The pus tracks along the line of least resistance and perforates the bone at the site where it is thinnest and weakest and involves the surrounding soft tissues. Once the infection enters the tissues it may resolve, become localized or spread. These infections may range from superficial to deep neck infections [1]. The infections generally spread by following the path of least resistance through connective tissues and along facial planes. The infections can also spread to a site, distant to its origin causing considerable morbidity and occasionally death. In cases of acute odontogenic infection, the oral and maxillofacial surgeon needs to know whether the inflammatory process is in a stage of abscess formation, requiring primary evacuation of pus and administration of antibiotics or a cellulitis that can generally be treated with antibiotics alone [2].

2. Case Report

A nine-year-old female child reported to our oral and maxillofacial surgery outpatient department with a chief complaint of painful swelling in the right side of the face with difficulty in mouth opening and swallowing for the past two weeks. On extra oral examination, the swelling extends superiorly from malar prominence and inferiorly up to submandibular region. Medial extension is from corner of mouth and laterally extends till retromandibular region. The swelling is of size 10x10 cm. The skin over the swelling is erythematous, warmth and stretched with superficial necrosis. On intraoral examination the right lower deciduous molar was grossly decayed with tender on percussion. Intraoral periapical radiograph was taken in relation to right lower deciduous molar and it reveals the radiolucency involving pulp space. A provisional diagnosis of right buccal and submandibular space infection was given. Complete blood count was done, Hilton's method of Incision and drainage was performed under local anesthesia in relation to the right buccal space and submandibular space, a consistent pus discharge was present along with multiple locules. Corrugated rubber

drains were placed in buccal and submandibular spaces and sutured with 3-0 silk. Followed by incision and drainage, the right lower deciduous molar was extracted. The locules were sent for histopathological examination, Then the patient was started a combo of three antibiotics based on the body weight and age for a period of one week.

Injection. Augmentin IV 500mg BID

Injection. Amikacin IV 250 mg BID

Injection. Metrogyl 500 mg (100ml) - 35 ml TID

Irrigation with metrogyl and betadine were done in buccal and submandibular spaces on daily basis and once there was no evidence of pus discharge, the drains were removed. The infection and swelling was subsided after one week. Histopathological report showed fragments of adipose tissue displaying dense infiltrate of mononuclear cells and many foamy macrophages with interspersed neutrophilic aggregates. There is marked hyperemia and scattered hemorrhage suggestive of severe sub-acute inflammation. A complete blood count was done again; All the blood values were found to be within the normal range. Then the patient was discharged from the ward.

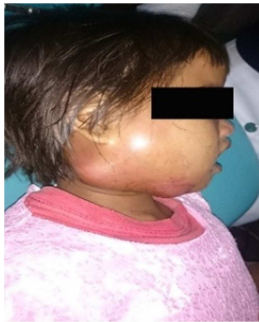

Figure 1. Pre operative.

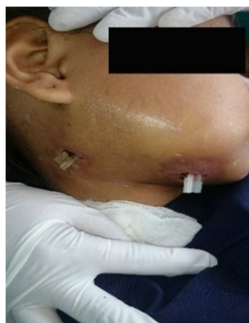

Figure 2. Intra operative.

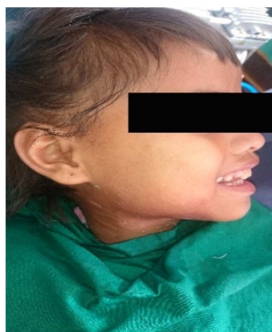

Figure 3. Post-op after 1 week.

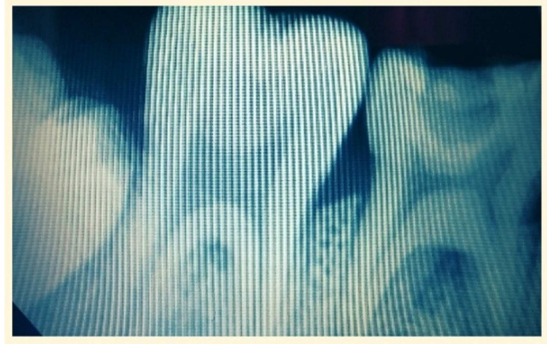


Figure 4. Pre operative radiograph.

Table 1. Pre op and post op blood counts.

Complete blood count	Values of complete blood count before the treatment	Values of complete blood count one week after the treatment
1.W BC	29.9/UI	12.2/UI
2.NEUTOPHILS	87%	70 %
3.LYMPHOCYTES	07%	20%
4.MONOCYTES	06%	08%
5.RBC	3.38 10 ⁶ /uL	3.44 10 ⁶ /uL
6.HGB	9.1 g/dL	9.1 g/dL
7.HCT	30.2 %	31.8 %
8.MCV	89.3 fL	92.4 fL
9.MCH	27.5 pG	26.5 pG
10.MCHC	30.8 g/dL	28.6 g/dL
11.RDW	13.1 %	13.3 %
12.PLATELET	237 10 ³ uL	498 10 ³ uL
13.EOSINOPHILS	0 %	02 %
14.BASOPHILS	0 %	0 %

3. Conclusion

Fascial space infections of the head and neck region, though potentially life threatening, can be prevented by regular dental visits. Early recognition and treatment of the infections are necessary to prevent considerable morbidity and mortality, especially in younger patients where more care should be given for oral health. Successful results can be achieved for pediatric patients who can be treated with Incision and Drainage, removal of etiologic factor followed by a combo of three antibiotics.

4. Discussion

The most important treatment of infections is removal of the offending source and proving path of drainage. Ancillary measures such as pharmacotherapy are aimed as supportive measures for the host, especially in cases of immune compromise. They are not meant to replace surgical intervention unless the infection is very early in its stages of development. Infections should be treated as soon as possible. No benefit is gained by waiting for an abscess to form, as this delay may carry consequences and may be potentially fatal. Due to the typical acidic pH of infected tissue, injected local anaesthetics, which are more alkaline, become ionized and therefore would not be able to cross the nerve membrane and provide profound anaesthesia. The use of nerve blocks as well

as adjunctive sedation may be beneficial in management of the apprehensive patient. Sound knowledge of the anatomy of the affected area, will ensure that the infection is treated appropriately, efficiently, while morbidity and complications are minimized. This will allow for optimal drainage of infection and avoidance of damage to vital structures.

Incision and drainage allows for decompression of infection, which will provide significant relief for the patient. It will also provide a portal for irrigation and placement of the drain. It only has to be deep enough to pass through the epithelium and underlying connective tissue. The subsequent blunt instrumentation will then explore all spaces including periosteal spaces. This method will prevent unnecessary injuries to the vital structures. Additionally, it allows for obtaining appropriate samples for culturing the offending microorganisms. More importantly, Incision and drainage alter the chemical environment to one that is more aerobic, thus less optimal for the more virulent anaerobic bacteria. successful management of odontogenic infections depends heavily upon changing the environment through decompression, removal of etiologic factor and by choosing proper antibiotic. Principles suggested by Topazian et al [3] were employed for incision and drainage in our case.

Even though, infection is a surgical disease, antibiotics have changed the way clinicians manage infections. These drugs are a crucial adjunct in appropriate treatment of patients. The cost of the antibiotic, spectrum of coverage as well as toxicity, and side effects are all-important considerations in the choice of antibiotic use. Antibiotics can be classified into two main categories; bacteriostatic and bactericidal. Penicillin is a bactericidal antibiotic with good oral absorption. It also has a good spectrum of coverage against the main oral virulent microflora. It is well tolerated by patients and has a low toxicity profile. Amoxicillin has a broader spectrum of coverage than penicillin, but it is an acceptable alternative. Its dosing regimen may lead to better compliance. In most of the studies, it is proven that all the anaerobic strains are sensitive to Metronidazole [4]. In our present case, empiric antimicrobial therapy was started to the patient, which consisted of intravenous Augmentin 500mg, BID. For serious anaerobic bacterial infections, intravenous Metronidazole 500 mg OD was infused as documented by Goodman and Gilman [5]. Dahlen has documented that in case of emergency, because resistance to Penicillin is increasing, Metronidazole or Amoxycillin Clavulanic acid may serve as alternative antibiotics. In case of Penicillin allergy, Metronidazole is the drug of choice [6]. Penicillin remains the drug of choice in the management of most odontogenic infections being reported with increasing frequency; however, if the infection fails to respond to the initial antibiotic choice, one must have a high index of suspicion that a resistant organism is involved [7].

Untreated or rapidly spreading odontogenic infections can be potentially life threatening secondary to airway compromise or septicemia. Trismus, a common feature of odontogenic infection, was seen in our patient, which is in contrast to the study of Bridgeman et al where 46 % of trismus was seen in his study. This clinical sign is commonly seen

when the infection involves the masticatory spaces [8].

Staphylococci are frequently associated with abscess formation. These microorganisms produce coagulase, an enzyme that is deposited which can cause fibrin deposition in citrated or oxalated blood. Streptococci are associated more often with cellulites, which produce enzymes such as streptokinase (fibrinolysin), hyaluronidase, and streptodornase. These enzymes break down fibrin and connective tissue ground substance, and lyse cellular debris, thus facilitating rapid spread of bacterial invaders. Although there are barriers, these are violated by the end products of the microorganisms and guide the infection to spread into deeper planes. An odontogenic infection spreads to fascial spaces because the anatomy of the fascial planes of the head and neck is such that it has an ineffective barrier to the spread of infection, and plays a vital role in the clinical localization of an abscess. The involvement of the facial planes by cellulitis, aids in the surgical drainage [9].

The basic beta lactum antibiotics are key antibiotics to be started for treating odontogenic infections as these infections are predominantly of gram-positive aerobes. Metronidazole or Tinidazole should not be just started because anaerobic microorganisms are normal flora of oral cavity; they should be started purely on the clinical presentation in the form of chronic abscess, massive cellulitis, presence of crepitus (gas), evidence of tissue necrosis, sloughing, presence of thick foul smelling pus. In our case there was presence of thick foul smelling pus, chronic abscess, skin necrosis which correlates with the study done by Kuriama et al [10].

The antibiotic susceptibility of the gram-negative microorganisms was seen predominantly with Amikacin. E. Coli and Klebsiella were found 100 % susceptible to Amikacin which correlates with our case [11]. The key issue here, which needs to be remembered, is that antibiotic alone cannot resolve odontogenic infection satisfactorily. Quick recovery of patients results with proper basic management comprising of early drainage decompression which is equally important. Therefore, with odontogenic infections it is always appropriate to always begin with the empiric antibiotic regimen with correlation to clinical presentation thinking of the most likely suspected microorganisms involved in the infections, which are usually the normal flora of the region, without forgetting the importance of early surgical intervention to reduce morbidity and complications. Once incision and drainage of fascial space abscess is performed, drain is placed and the wound is dressed which is changed several times over subsequent days and irrigated daily. Irrigation with saline and antibiotic solution has been reported to be effective in the elimination or reduction of infection [12].

References

- [1] Chandak R, Degwekar S, Bhowte RR et al. An evaluation of ultrasonography in the diagnosis of head and neck swellings. J Oral Maxillofac Res 2010; 40: 213-21.

- [2] Srinivas K, Sumanth K N, Chopra S. Ultrasonographic evaluation of inflammatory swellings of buccal space. *Indian J Dent Res* 2009; 20: 458-62.
- [3] Topazian RG, Goldberg MH, Hupp JR. *Oral and Maxillofacial Infections*. 4th ed. Philadelphia: WB Saunders; 2002. p. 99-213.
- [4] Quayle AA, Russell C, Hearn B. Organisms isolated from severe odontogenic soft tissue infections: Their sensitivities to cefotetan and seven other antibiotics, and implications for therapy and prophylaxis. *Br J Oral Maxillofac Surg* 1987; 25: 34-44.
- [5] Parker KL, Brunton LL, Lazo JS. Goodman and Gilman's *The Pharmacological Basis of Therapeutics*. 11th ed. New York: McGraw-Hill Companies; 2005. p. 1127-54.
- [6] Dahlén G. Microbiology and treatment of dental abscesses and periodontal endodontic lesions. *Periodontol* 2002; 28: 206-39.
- [7] Moenning JE, Nelson CL, Kohler RB. The microbiology and chemotherapy of odontogenic infections. *J Oral Maxillofac Surg*. 1989; 47: 976-85.
- [8] Bridgeman A, Wiesenfeld D, Hellyar A, Sheldon W. Major maxillofacial infections, An evaluation of 107 cases. *Aust Dent J*. 1995; 40: 281–288.
- [9] Grodinsky M, Holyoke MA. The fasciae and fascial spaces of the head, neck and adjacent regions. *Am J Anat*. 1938; 63: 367–408.
- [10] Kuriyama T, Nakagawa K, Karasawa T et al. Past administration of beta-lactam antibiotics and increase in the emergence of beta-lactamase-producing bacteria in patients with orofacialodontogenic infections. *Oral Surg Oral Med Oral Pathol Oral RadiolEndod*. 2000; 89: 186–192.
- [11] Inderdeep Singh Walia, Rajiv M Borle, Mehendiratta D et al. Microbiology and Antibiotic Sensitivity of Head and Neck Space Infections of Odontogenic Origin. *J Maxillofac Oral Surg*. 2014; 13(1): 16–21.
- [12] P. V. Nimonkar. Simple Manoeuvre to Help Irrigate the Fascial Space Infections. *J. Maxillofac. Oral Surg*. 2013; 12(1): 120.