



Restoration of the Atrophic Maxilla with Four Narrow and Ultrashort Implants

Rolf Ewers^{1,*}, Mauro Marincola², Vincent Morgan³, Paolo Perpetuini⁴, Florian Wagner¹, Rudolf Seemann¹

¹University Hospital for Cranio-Maxillofacial and Oral Surgery Medical University of Vienna, Vienna, Austria

²Implant Dentistry Center, University of Cartagena, Cartagena, Colombia

³Bicon Implant Institute, Boston, USA

⁴Dental Laboratory, Cisterna di Latina, Italy

Email address:

rolf@cmf-vienna.com (R. Ewers)

*Corresponding author

To cite this article:

Rolf Ewers, Mauro Marincola, Vincent Morgan, Paolo Perpetuini, Florian Wagner, Rudolf Seemann. Restoration of the Atrophic Maxilla with Four Narrow and Ultrashort Implants. *International Journal of Clinical Oral and Maxillofacial Surgery*. Vol. 4, No. 2, 2018, pp. 35-41. doi: 10.11648/j.ijcoms.20180402.11

Received: September 6, 2018; Accepted: October 9, 2018; Published: October 27, 2018

Abstract: Presented is a prospective cohort study of 72 calcium phosphate coated Bicon Integra-CP implants for 18 patients with pronounced class V and VI maxillary atrophy according to the classification of Cawood and Howell (1988) and treated with four ultrashort 4.0 x 5.0 mm locking taper implants. The patients were divided into three groups. For the first group, four 4.0 x 5.0 mm implants were placed. For the second group, two narrow 3.0 x 8.0 mm implants were placed in very thin anterior alveolar bone. For the third group, the alveolar bone in the premolar and molar region was too narrow and too shallow; therefore, 4.0 x 5.0 mm implants were placed in the maxillary tuberosities. All implants were restored with TRINIA, a metal-free fiber-reinforced hybrid resin CAD/CAM material. Two patients lost one implant each during the observation period, which were subsequently replaced successfully. The cumulative one-year patient-based implant survival rate (CSR) was 88.8%. The cumulative one-year implant-based survival rate was 97.2%. Since the patients with a failed implant were able to wear their prosthesis with only three implants while the replacement implants were being osseointegrated, this resulted in 100% prosthetic success. The good result allows the conclusion that the long-term use of four ultrashort and narrow locking taper implants reveal a comparable outcome to standard size implants with complex bone augmentations.

Keywords: Ultrashort Implants, Locking Taper or Conical Implants, Maxillary Atrophy, Maxillary Tuberosity Implants, Avoiding Sinus Lift Procedures, Avoiding Augmentation Procedures, Metal-Free Fiber-Reinforced Hybrid Resin Prosthesis, CAD/CAM Prostheses Fabrication

1. Introduction

The premature loss of maxillary molars usually leads to the most pronounced atrophy of the maxillary alveolar ridge and pronounced pneumatization of the maxillary sinus. [1] Since Tatum's presentation on the sinus lift [2], many methods for solving this problem have been established with excellent long-term success. [3-6] As more experience has been gained, the methods used have become more minimally invasive. [7-10] To avoid sinus lifts, we have been conducting a prospective cohort study in our hospital (since

2010) with ultrashort 4.0 x 5.0 mm or narrow 3.0 x 8.0 mm locking taper calcium phosphate-coated Integra-CP™ implants from Bicon (Boston/USA) in the atrophic maxilla. This prospective cohort study was approved by the Ethics Committee under No. EK 018/2011. This study was a bicentric cooperation between the University Hospital for Cranio-Maxillofacial and Oral Surgery and the CMF Implant Institute in Vienna. The basis of this prospective study was to examine whether short and narrow implants could be successful in clinical use without complex augmentation procedures. Additionally, a novel and revolutionary metal-

free, fiber-reinforced hybrid resin material (TRINIA™/Bicon) was used as the substructure of the implant-supported fixed prostheses, which were either cemented or retained by screw-detachable abutments.

2. Method

18 patients between ages 55 and 80 years old with pronounced class V and VI maxillary atrophy according to Cawood and Howell [11] were included in the study, taking into consideration the usual exclusion criteria and written consent. Patients with Biphosphonate therapy, heavy smokers (more than 10 cigarettes per day), pregnant women, and adolescents were excluded. All patients were treated with four 4.0 x 5.0 mm ultrashort locking taper Bicon implants. However, for some patients whose anterior alveolar bone was very thin, narrow 3.0 x 8.0 mm locking taper Bicon implants were used. [12, 13] For other patients, to avoid sinus lift and ridge splitting procedures, the implants were placed in the area of the maxillary tuberosities. [14]

3. Case Studies

The first case to be presented is a 69-year-old patient with extreme class VI [11] maxillary atrophy (Figure 1a) who previously would have been treated with a complex Le Fort I Horseshoe Osteotomy utilizing an iliac crest interpositional bone transplantation with intubation anesthesia. [15-17] In this case, since there was sufficient bone to place four 4.0 x 5.0 mm calcium phosphate-coated Bicon Integra-CP™ implants (Bicon LLC Boston, MA/USA), they were placed with local anesthesia in the area of teeth numbers 4, 7, 10 and 13 during a relatively short surgical procedure without any bone augmentations (Figure 1b).

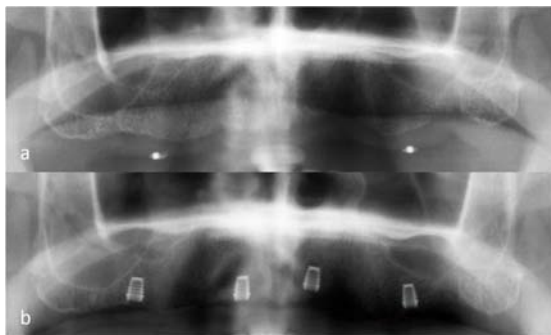


Figure 1. Enlarged sections of panoramic images of the 69-year-old patient with a resin splint and two small metal balls (a) and with four inserted 4.0 x 5.0 mm Bicon Integra-CP implants (b).

To facilitate the positioning of the implants, panoramic and tomographic images with small metal balls attached to a resin splint were taken (Figure 1a). The implants were uncovered after 6 months of healing. The osseointegration of Bicon implants occurs by intramembranous bone healing in accordance with the callus principle. [18] Impressions were made following the uncovering of the implants, and a few days later the prosthetic try-in of a wax teeth arrangement stabilized

by a single impression post was evaluated (Figure 2).

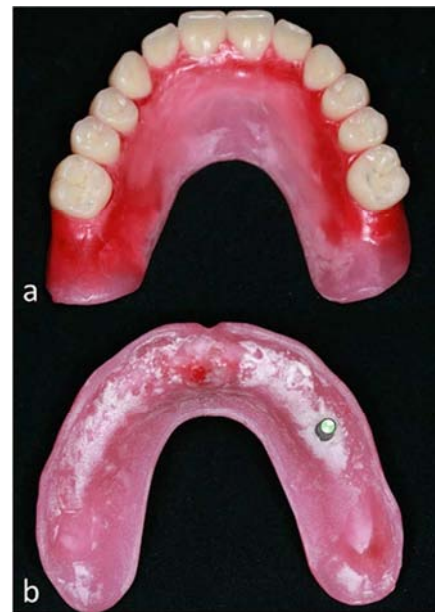


Figure 2. Wax teeth arrangement with a resin base (a). On the ridge side, the impression post is visible, which helps to orient and stabilize the prosthesis in an implant (b).

After the laboratory processes had been completed, the technician provided the aligned abutments on a plaster model for the cement-retained TRINIA prosthesis (Figure 3) Alternatively, fixed-detachable, or retentive telescopic prostheses could have been fabricated.

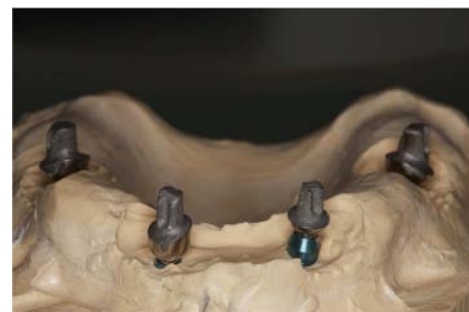

Figure 3. Four parallel aligned abutments on the stone model.

The TRINIA substructure (Figure 4) was fabricated by the Perpetuini dental laboratory (Cisterna di Latina/Italy) using a CAD/CAM method for the processing of a twelve-unit prosthesis (Figure 5).

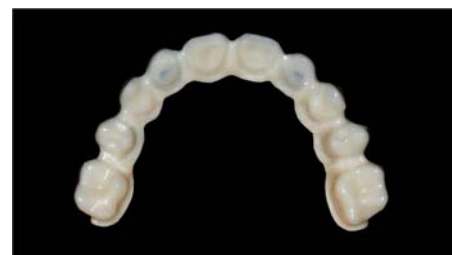

Figure 4. CAD/CAM metal-free fiber-reinforced TRINIA substructure.

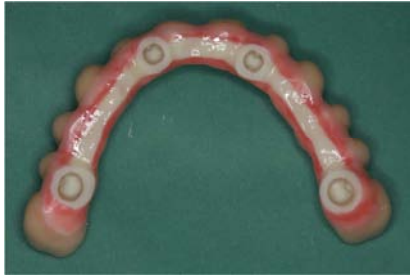

Figure 5. Ridge-side view of the TRINIA prosthesis with four bores into which the abutments will be cemented.

Figure 6 shows the completed prosthesis with the four abutments prior to their being inserted into the wells of their implants. Vaseline was applied to the bores of the TRINIA substructure to facilitate the removal of the prosthesis after the insertion of the abutments into their implant wells.

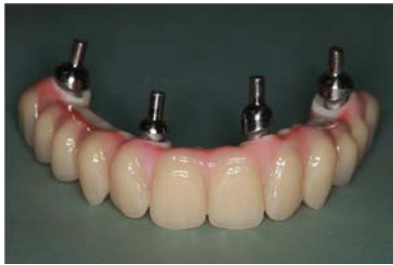

Figure 6. Completed TRINIA prosthesis with four abutments, which are to be seated and subsequently cemented into the bores of the prosthesis.

Figure 7. shows the initial try-in of the prosthesis prior to its cementation to the four definitively seated abutments (Figure 7).

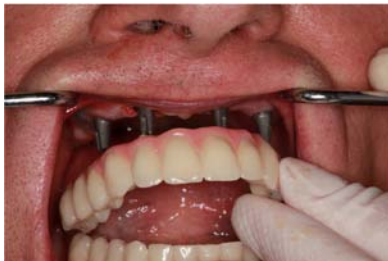

Figure 7. Initial try-in of the prosthesis prior to its cementation to the four abutments with temporary cement.

Figure 8 shows the facial view of the seated twelve-unit prosthesis. Figure 9 shows the palatal view of the enjoyable, palate-free prosthesis.

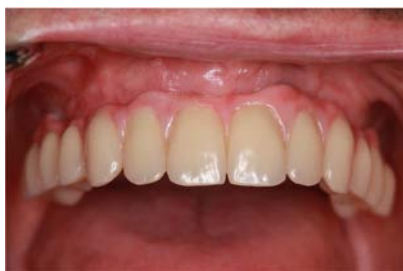

Figure 8. Facial view of the seated twelve-unit TRINIA prosthesis.

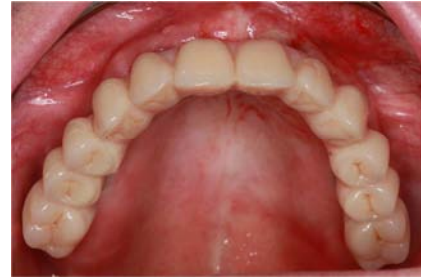

Figure 9. Palatal view of the seated twelve-unit prosthesis with a free palate.

Figure 10a shows the four abutments prior to the cementing and loading of the prosthesis, and Figure 10b shows the abutments after three years in function.

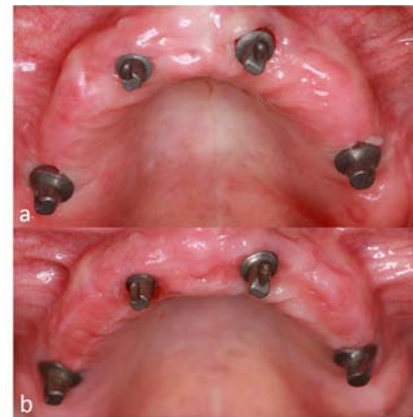


Figure 10. Intraoral view of four abutments to be cemented at the beginning of loading (a) and after three years in function (b).

Despite the availability of only minimal bone in this patient's atrophic maxilla, the use of four short implants provided the benefits of a palate-free fixed prosthesis with two minor surgical procedures. The panoramic radiograph taken at the beginning of the functional loading of the prosthesis reveals good osseointegration (Figure 11a), which remained unchanged after three years in function, as evidenced by no marginal bone loss (Figure 11b).

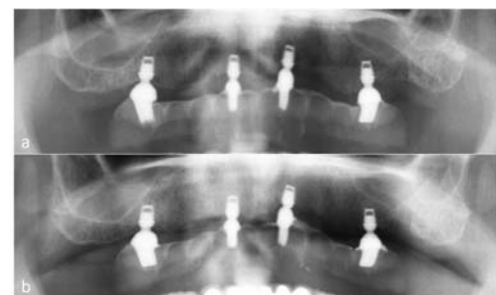


Figure 11. Enlarged sections of panoramic images with the cemented prosthesis at the start of loading (a) and after three years in function (b).

For the second group of patients, in addition to their pronounced class V-VI [11] maxillary atrophy in a vertical dimension, they also had a very narrow posterior and anterior alveolar ridge. For this reason, two narrow 3.0 x 8.0 mm Bicon Integra-CP implants were placed in the anterior region,

and alveolar ridge splitting procedures were performed after supra-periosteal preparation and prior to the insertion of two 4.0 x 5.0 mm Bicon Integra-CP implants posteriorly. The panoramic tomographic image illustrates the pronounced atrophy of the alveolar ridge with extreme pneumatization of this 69-year-old patient's sinuses (Figure 12a).

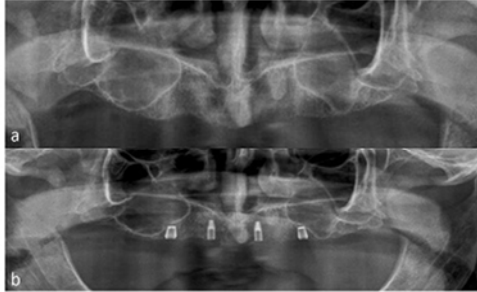


Figure 12. Enlarged sections of the panoramic images of a 69-year-old patient with extreme class V-VI maxillary atrophy [11] (a) and after the insertion of two 3.0 x 8.0 mm and two 4.0 x 5.0 mm well-positioned Bicon Integra-CP implants (b).

After a supra-periosteal mucosal preparation and the splitting and widening of the alveolar ridge, a 4.0 x 5.0 mm Bicon Integra-CP implant was placed into both premolar regions (Figures 13 a and b). [19]

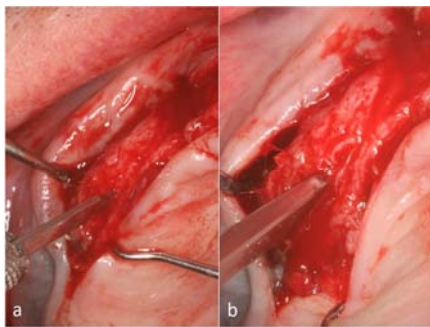


Figure 13. After a supra-periosteal mucosal preparation, the alveolar ridge was split and widened with a double-edged beaver knife"initially (a) and then with a narrow chisel (b).

Due to the very thin alveolar ridge in the anterior region, two narrow 3.0 x 8.0 mm Bicon Integra-CP implants were inserted (Figure 12b). After a healing period of six months, the implants were uncovered and an implant-level transfer impression was made (Figure 14).

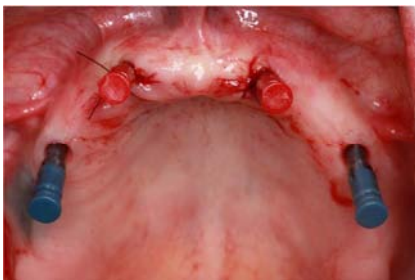


Figure 14. Intraoral view after the uncovering of the implants and insertion of two red (2.0 mm) and two blue (2.5 mm) impression posts with their corresponding impression sleeves.

To facilitate the alignment and seating of the abutments in their implant wells, a resin orientation and seating jig was used (Figure 15).

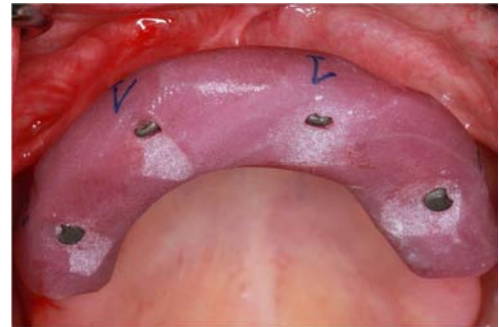

Figure 15. Palatal view of a resin orientation and seating jig, which was used to facilitate the positioning and seating of the abutments in their implant wells.

The panoramic image (Figure 16a) illustrates the very well-positioned implants with a cemented TRINIA prosthesis.

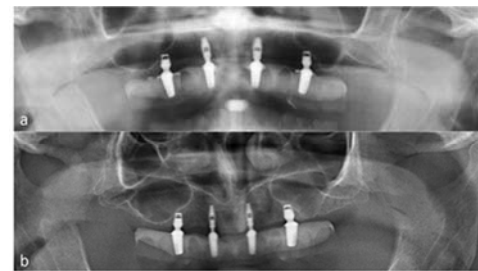


Figure 16. Enlarged sections of panoramic tomographic images after the cementation of the TRINIA prosthesis (a) and after four years in function without any radiologically detectable marginal bone loss (b).

A lateral cephalometric radiograph reveals the challenging restorative situation of the patient, who was also successfully treated with four mandibular Bicon implants (Figure 17).

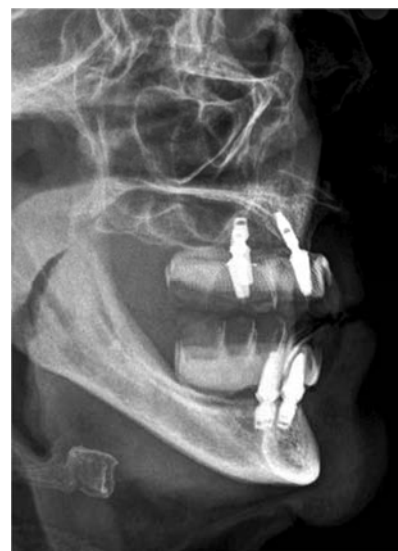

Figure 17. Lateral cephalometric X-ray with implant-supported and cement-retained maxillary and mandibular TRINIA prostheses.

With both TRINIA prostheses, a satisfactory occlusion (Figure 18) and an excellent functional and esthetic result were achieved (Figure 19) along with evidence of long-term stability over a four-year period (Figure 16b).

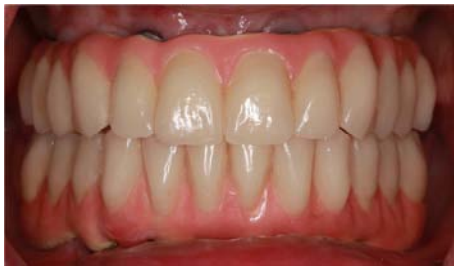

Figure 18. Image of occlusion of the maxillary and mandibular TRINIA prostheses, cemented on four implants.

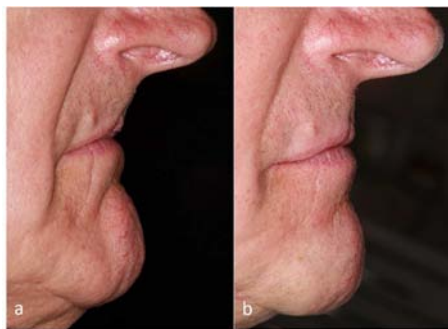


Figure 19. Lateral images before (a) and after (b) implant-supported maxillary and mandibular TRINIA prostheses.

In the third group of patients, atrophy of the alveolar bone and the pneumatization of the maxillary sinuses up to the canine region negated any implant placement without the very complex and risky insertion of zygomatic implants [20]; therefore, a 4.0 x 5.0 mm Bicon Integra-CP implant was inserted into each maxillary tuberosity. [14] For this 55-year-old female patient, the reformatted panoramic image of the computer tomogram reveals the pronounced maxillary atrophy and the missing bone in her premolar region (Figures 20 and 21a).

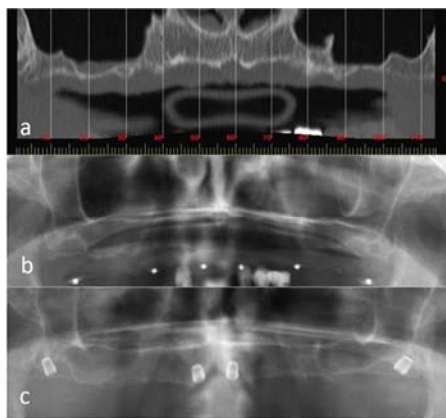


Figure 20. Reformatted CT panoramic image of a 55-year-old patient with extreme class VI maxillary atrophy [11]. Enlarged sections of panoramic radiographs before (a) and after (b) the implant insertion of 4.0 x 5.0 mm Bicon Integra-CP implants in the area of each maxillary tuberosity and in the anterior region.

Except for the initial pilot drilling, osteotomy preparation in the area of the maxillary tuberosity is usually performed manually with hand reamers and followed by a loose implant placement due to the very fatty and soft cancellous bone. [21, 22] (Figure 21a and Figure 21b).

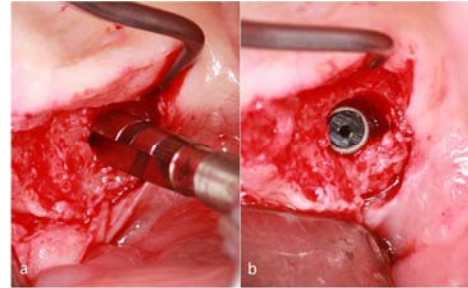


Figure 21. Osteotomy preparation with a 4.0 mm hand reamer (a) and a loosely placed 4.0 x 5.0 mm Bicon Integra-CP implant with a cut polyethylene healing plug is inserted into the implant well for the duration of the osseointegration period (b).

Despite the very fatty and soft spongiosa, [21, 22] the osseointegration of the implants, and the TRINIA prostheses with screw-retained fixed-detachable abutments [23] (Figures 22a to 23a) have been stable and without any need for any adjustments for over three years in function (Figures 23b and 24).

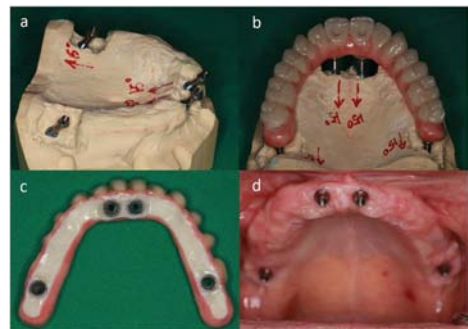


Figure 22. Screw-retained TRINIA prosthesis on fixed-detachable abutments. Four fixed-detachable abutments seated in implant analogs in a stone model (a). Fourteen-unit screw-retained TRINIA prosthesis on a stone model (b). Ridge-side view of TRINIA prosthesis with four titanium sleeves for screw fixation (c). Intraoral palatal view with four screw-retained fixed-detachable abutments after one year in function (d).

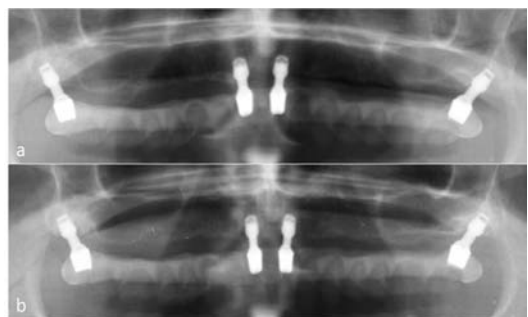


Figure 23. Enlarged sections of panoramic radiographs after screw fixation of the TRINIA prosthesis (a) and after three years in function without any radiologically detectable marginal bone loss (b).

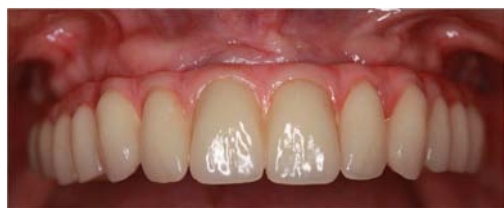

Figure 24. Intraoral view of the screw-retained TRINIA prosthesis after three years in function.

4. Results

For this study, 18 patients with 72 implants—12 women between ages 54.0 and 79.7 (66.9 ± 9.0) years old and 6 men between ages 61.4 and 76.5 (67.6 ± 5) years old—were treated and continuously monitored. The average observation period was 2.1 ± 0.9 years. Of the 72 implants, 56 were treated with 4.0×5.0 mm implants, 14 with 3.0×8.0 mm implants, and 2 with 5.0×8.0 mm implants. Twelve patients received four 4.0×5.0 mm implants, five patients received two 3.0×8.0 mm implants in the anterior region, and one patient received four 3.0×8.0 mm implants. In their mandibles, six patients had partial dentures, six had natural teeth, and six had full-arch fixed implant restorations. Two patients lost one implant each during the observation period (one 71-year-old and one 72-year-old patient before the start of loading). Both lost implants were replaced. The cumulative one-year patient-based implant survival rate (CSR) was 88.8%. [13] The cumulative one-year implant-based survival rate was 97.2%. [13] Since both patients with a failed implant were able to wear their prosthesis on only three implants during the osseointegration time of the replacement implants, this resulted in 100% prosthetic success.

5. Discussion

The aim of this study was to investigate the efficacy of treating patients with extreme maxillary atrophy without costly and time-consuming augmentation procedures by using ultrashort 4.0×5.0 mm and narrow 3.0×8.0 mm implants, which were restored with prostheses of metal-free CAD/CAM-produced fiber-reinforced hybrid resin material. The cumulative patient-based survival rate (CSR) was 88.8% after one year. The cumulative one-year implant-based survival rate was 97.2%. The survival rates are comparable to those of conventional long implants. This demonstrates that it is possible to treat highly atrophic maxillae with ultrashort and narrow implants using only four implants [23-25]. The results are comparable to studies by other authors. [26, 27] Furthermore, this study shows that restorations with a metal-free CAD/CAM-produced fiber-reinforced hybrid resin material do not lead to any complications. [23] Since both patients with a failed implant were able to wear their prostheses with only three implants during the osseointegration time of the replacement implants, prosthetic success was concluded to be 100%. These results are very encouraging, since the extreme maxillary atrophy only required the use of narrow implants with an alveolar ridge

splitting procedure or the placement of ultrashort implants with minor surgical procedures. Furthermore, the placement of implants in the tuberosities had excellent statistical results.

6. Conclusions

In consideration of the very difficult clinical situation of restoring highly atrophic maxillae in both the vertical and transverse dimensions, and the capability of avoiding extensive augmentation procedures, the long-term use of four ultrashort and narrow locking taper implants reveals good results comparable to standard size implants with complex bone augmentations. However, long-term results with this type of atrophy are still very limited. Prospective long-term studies with a larger number of patients and implants observed over a longer period of time are necessary to make a valid recommendation.

References

- [1] Wagner, F., Dvorak, G., Nemec, S., Pietschmann, P., Figl, M. & Seemann, R. A principal components analysis: How pneumatization and edentulism contribute to maxillary atrophy. *Oral Diseases* 2017 23: 55-61.
- [2] Tatum OH. Lecture presented to the Alabama Implant Congress. Alabama Implant Congress. 1976. doi:10.1111/cid.12136/full.
- [3] Boyne PJ, James RA. Grafting of the maxillary sinus floor with autogenous marrow and bone. *J Oral Surg.* 1980; 38(8):613-616.
- [4] Mellonig JT, Bowers GM, Bailey RC. Comparison of bone graft materials. Part I. New bone formation with autografts and allografts determined by Strontium-85. *J Periodontol.* 1981;52(6):291-296. doi:10.1902/jop.1981.52.6.291.
- [5] Tatum H. Maxillary and sinus implant reconstructions. *Dent Clin North Am.* 1986;30(2):207-229.
- [6] Ewers R. Maxilla sinus grafting with marine algae derived bone forming material: a clinical report of long-term results. *J Oral Maxillofac Surg.* 2005; 63(12):1712-1723. doi:10.1016/j.joms.2005.08.020.
- [7] Summers RB. A new concept in maxillary implant surgery: the osteotome technique. *Compendium.* 1994;15(2):152-154-6-158passim-quiz162.
- [8] Summers RB. The osteotome technique: Part 3--Less invasive methods of elevating the sinus floor. *Compendium.* 1994;15(6):698-700-702-4passim-quiz710.
- [9] Ali SA, Karthigeyan S, Deivanai M, Kumar A. Implant Rehabilitation For Atrophic Maxilla: A Review. *The Journal of Indian Prosthodontic Society.* 2014;14(3):196-207. doi:10.1007/s13191-014-0360-4.
- [10] Pérez-Martínez S, Martorell-Calatayud L, Peñarrocha-Oltra D, García-Mira B, Peñarrocha-Diogo M.: Indirect sinus lift without bone graft material: Systematic review and meta-analysis. *J Clin Exp Dent.* 2015 Apr 1;7(2):e316-9.

- [11] Cawood JI, Howell RA. A classification of the edentulous jaws. *Int J Oral Maxillofac Surg.* 1988 Aug;17(4):232–6.
- [12] Ewers R, Perpetuini P, Morgan V, Marincola M, Wu R, Seemann R. TRINIA™— Metal-free restorations. *Implants* 2017, 1:2-7.
- [13] Wagner F, Seemann R, Marincola M, Ewers R. Fixed, fiber-reinforced resin fixed prostheses on four short implants in severely atrophic maxillas: 1-year results of a prospective cohort study. *J Oral Maxillofac Surg.* 2018 Jun; 76(6):1194-1199. doi: 10.1016/j.joms.2018.02.001. Epub 2018 Feb 19.
- [14] Lopes LF, da Silva VF, Santiago JF Jr, Panzarini SR, Pellizzer EP. Placement of dental implants in the maxillary tuberosity: a systematic review. *Int J Oral Maxillofac Surg.* 2015 Feb;44(2):229-38.
- [15] Härle F, Ewers R. Die Hufeisenosteotomie mit Knocheninterposition zur Erhöhung des Knochenskammes: eine im Experiment steckengebliebene Operationsmethode. *Dtsch. Zahnärztl Z* 1980;35:105-107.
- [16] Yerit K, Posch M, Hainich S, Turhani D, Klug C, Wanschitz F, Wagner A, Watzinger F, Ewers R. Long-term implant survival in the grafted maxilla: results of a 12-year retrospective study. *Clin Oral Impl Res* 15:693-699, 2004.
- [17] Ewers R. Standard clinical Situations - 4.7 Edentulous Maxilla In: *Oral Implants – Bioactivating concepts* Editors: Ewers R, Lambrecht JT, Quintessenz Publ. Co. Chicago 2012:329-356
- [18] Lehrberg J, Coelho P. Biologic Response to Dental Implants In: *The Bicon Short Implant: A Thirty-Year Perspective* Editor Morgan VJ, Quintessenz Publ. Co. Chicago 2017:37-47.
- [19] Daher S, Ewers R, Cicconetti A. Ridge Splitting and the Split-Thickness Flap In: *The Bicon Short Implant: A Thirty-Year Perspective* Editor Morgan VJ, Quintessenz Publ. Co. Chicago 2017:81-198.
- [20] Aparicio C, Ouazzani W, Aparicio A, Fortes V, Muela R, Pascual A, Codesal M, Barluenga N, Franch M. Immediate/Early loading of zygomatic implants: clinical experiences after 2 to 5 years of follow-up. *Clin Implant Dent Relat Res.* 2010 May;12 Suppl 1:e77-82.
- [21] Blanco J, Suárez J, Novio S, Villaverde G, Ramos I, Segade LA. Histomorphometric assessment in human cadavers of the peri-implant bone density in maxillary tuberosity following implant placement using osteotome and conventional techniques: *Clin Oral Implants Res.* 2008 May;19(5):505-10.
- [22] Ewers R, Seemann R, De Witt T, Sarvan I, Coetzer M, Pisarik K. Atrophic Maxillary Ridges In: *The Bicon Short Implant: A Thirty-Year Perspective* Editor Morgan VJ, Quintessenz Publ. Co. Chicago 2017:199-213.
- [23] Ewers R, Marincola M, Perpetuini P, Seemann R, Morgan V, Wu R. Leichtgewicht im Praxistest-Restaurationen bei schwierigen Situationen und atrophien Kiefern: *Z Oral Implant.* 13: 1/17; 28-36.
- [24] Seemann, R., Jirku, A., Wagner, F. & Wutzl, A. (2017) What do sales data tell us about implant survival? *PloS One* 12: e0171128.
- [25] Neugebauer J, Vizethum F, Berger C, Bolz W, Bowen A, Deporter D, Ewers R, Fairbairn P, Felino A, Fortin T, Gowd V, Kern M, Kobler P, Konstantinovic V, Marincola M, Nickenig HJ, Özyuvaci H, Schmedtmann N, Zöller JE. Update: Kurze, angulierte und durchmesserreduzierte Implantate - Praxisleitfaden: 11. Europäische Konsensuskonferenz (EuCC). *BDIZ/EDI Konkret* 2016; 20: 88-90.
- [26] Felice P, Checchi L, Barausse C, Pistilli R, Sammartino G, Masi I, Ippolito DR, Esposito M. Posterior jaws rehabilitated with partial prostheses supported by 4.0 x 4.0 mm or by longer implants: One-year post-loading results from a multicenter randomised controlled trial. *Eur J Oral Implantol.* 2016 Spring; 9(1):35-45.
- [27] Pohl, V., Thoma, D. S., Sporniak-Tutak, K., Garcia-Garcia, A., Taylor, T. D., Haas, R. & Hammerle, C. H. (2017) Short dental implants (6 mm) versus long dental implants (11-15 mm) in combination with sinus floor elevation procedures: 3-year results from a multicenter, randomized, controlled clinical trial. *Journal of Clinical Periodontology* 44: 438-445.