



## Case Report

# Total Anomalous Pulmonary Venous Connection in a Teenage Patient

Papa Salmane Ba, Momar Sokhna Diop, Papa Amath Diagne, Ndeye Fatou Sow, Papa Adama Dieng, Amadou Gabriel Ciss, Mouhamadou N'Diaye

Department of Thoracic and Cardiovascular Surgery, CHU Fann, Dakar, Senegal

### Email address:

[mansalb@yahoo.fr](mailto:mansalb@yahoo.fr) (P. S. Ba)

### To cite this article:

Papa Salmane Ba, Momar Sokhna Diop, Papa Amath Diagne, Ndeye Fatou Sow, Papa Adama Dieng, Amadou Gabriel Ciss, Mouhamadou N'Diaye. Total Anomalous Pulmonary Venous Connection in a Teenage Patient. *International Journal of Cardiovascular and Thoracic Surgery*. Vol. 5, No. 4, 2019, pp. 69-71. doi: 10.11648/j.ijcts.20190504.12

Received: July 22, 2019; Accepted: August 23, 2019; Published: October 9, 2019

**Abstract:** Total anomalous pulmonary venous connection is usually seen and treated in childhood or in neonatal period in his obstructive type. Sometime it can be detected beyond the first decade. The objective of this case report is to give prove of the fact that it can be seen and treated in a teenager. We present a rare case of 15 years old boy who was admitted for supraventricular tachycardia with hypotension. Emergency electrocardiography showed atrial Flutter with a frequency of 225 beats/min. He complained from dyspnea state 2 at New York Heart Association functional classification before. The echocardiography showed a dilated coronary sinus in cardiac-type total anomalous pulmonary venous connection associated with a large atrial septal defect. Cardiac rhythm was normal after administration of Amiodarone. In cardiopulmonary bypass, an incision was made from the atrial septal defect to unroof the coronary sinus; a large pericardial patch was put to close the unroofing coronary sinus and let it in the left atrium. A De Vega tricuspid annuloplasty was done to reduce the tricuspid valve leak. The patient's postoperative course was uneventful and was discharged in day 9 after operation. Total pulmonary venous return can evolve until teenage if the atrial septal defect is large. Evolution is good after a complete repair.

**Keywords:** Atrial Septal Defect, Coronary Sinus, Total Anomalous Pulmonary Venous Connection, Unroofing Coronary Sinus, Pericardial Patch

## 1. Introduction

Total anomalous pulmonary venous connection (TAPVC) is a rare cardiac anomaly, occurring only in 1% to 3% of children born with congenital heart defects [1]. Few patients survive without surgical correction beyond the first decade [2]. Supracardiac variety accounts for 50% of all TAPVC patients [3]. Few cases were reported or small surgical series report surgical outcomes from patients with TAPVC presenting beyond the first decade of life. We describe a case of a cardiac type of Total anomalous pulmonary venous connection in a teenage patient.

## 2. Methods

### Case Presentation

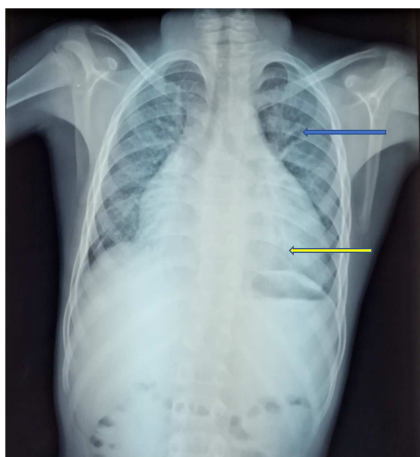
A 15 years old boy was admitted to our institution for supraventricular tachycardia with hypotension. Emergency

electrocardiography showed atrial Flutter with a frequency of 225 beats/min. Cardiogenic shock was diagnose and he was admitted at the intensive care unit. A bolus of amiodarone infusion and heparin was administered. Oral dose of amiodarone was begun. A second electrocardiography was done. Cardiac rhythm remains in Flutter 2/1 but with 75 beats/min.

In the past, the patient had usually dyspnea state 2 at New York Heart Association functional classification and headache.

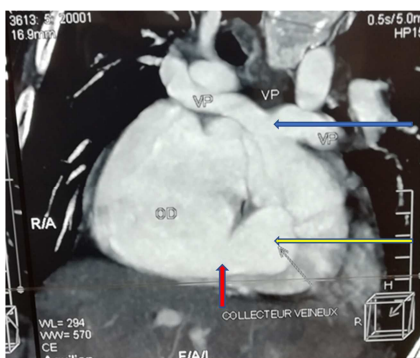
Physical examination after stabilization showed normal vital signs except cyanosis with room air oxygen saturation of 78%. Cardiac auscultation revealed soft systolic murmur at 2<sup>nd</sup> intercostal space in the left parasternal area.

A Chest X- Ray (figure 1) demonstrated cardiomegaly with and increased pulmonary vascular markings.

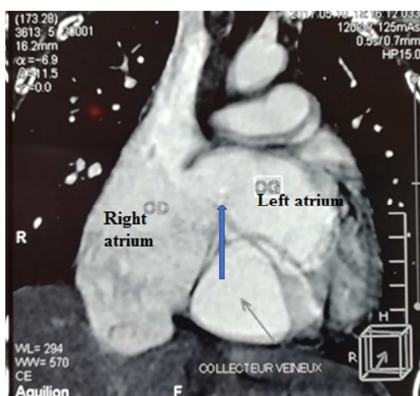


**Figure 1.** Cardiomegaly (yellow arrow) and increased pulmonary vascular markings (blue arrow).

Echocardiography showed dilated right ventricle and right atrium, a large secundum atrial septal defect (24 mm). Pulmonary veins from both lungs made a confluence pulmonary veins (CPV) posterior to the left atrium and went down into the coronary sinus which was dilated. A severe tricuspid valve regurgitation with severe pulmonary hypertension was founded. Systolic pulmonary pressure was 50 mm Hg. CT pulmonary angiogram showed the cardiac type of Total anomalous pulmonary venous connection with a large secundum atrial septal defect (24 mm), dilated right atrium (RA) (78 x 63 mm), and right ventricle (RV) (figures 2-3).



**Figure 2.** Cardiac type of TAPVC with Pulmonary veins (blue arrow) going into a large collector (yellow arrow) and coronary sinus (red arrow).



**Figure 3.** Cardiac type of TAPVC with a large secundum ASD (blue arrow).

The patient was admitted to the operating room two days after his admission in the intensive care unit. Cardiopulmonary bypass (CPB) was established through an aortic and bicaval cannulation and moderate hypothermia. The right atrium was incised. A large secundum atrial defect and a large coronary sinus were founded. Total anomalous pulmonary venous connection in his cardiac type associated with an atrial septal defect was confirmed. Tricuspid annulus was dilated. An incision was made from the atrial septal defect and the roof of the coronary sinus. A large pericardial patch was put to close the atrial septal defect and the unroofing coronary sinus letting it in the left atrium. A De Vega tricuspid valve annuloplasty was done to reduce tricuspid valve regurgitation.

### 3. Results

The patient's postoperative course was uneventful. Amiodarone infusion was stopped at the intensive care unit because of a normal sinus rhythm after surgical repair.

The patient was discharged from the intensive care unit on postoperative day 6 and discharged from the hospital on postoperative day 9. At 3-year follow-up, he is noncyanotic, asymptomatic, with a normal examination and normal pulmonary vein return in echocardiography.

### 4. Discussion

Total anomalous pulmonary venous connection (TAPVC) in particularly the cardiac type is rare and a few patients survive beyond the first decade [2]. However, Sachin Talwar in India described TAPVC in 98 patients older than ten years at the time of presentation and Xu-hua Jian in China reported 50% in 12 cases presented with total anomalous pulmonary venous connection [4-5]. In Total anomalous pulmonary venous connection (TAPVC) like our case, symptoms are usually dyspnea and supraventricular arrhythmia in his non obstructed form because of dilatation of right atrium, right ventricle and pulmonary overflow [6]. Co-morbidities included besides chromosomal abnormality, heterotaxy syndrome, developmental delay, gastroesophageal disease [7]. In this case, the patient suffered from atrial flutter which was reduced by Amiodarone infusion for rate control. We think that this patient survives until 15 years because of the large secundum atrial septal defect with a left to right shunt at the echocardiography. Echocardiography is helpful to diagnose a total anomalous pulmonary venous connection but angiocardiology is the gold standard for diagnosis and is helpful in the case of complex associated cardiac anomalies. But it must be done if necessary to avoid risks of radiation-induced chromosomal DNA damage and cancer [8-9]. Surgical repair is indicated at the time of diagnosis. Surgical management of cardiac type total anomalous pulmonary venous return usually is unroofing the coronary sinus and closing the atrial septum defect and unroofed coronary sinus orifice with an autologous pericardial patch during cardiopulmonary bypass [10-11]. It is the case of our

patient. However, Masaaki Yamagishi in Japan described an alternative approach for repair of total anomalous pulmonary venous connection to the coronary sinus without using a prosthetic patch or an autologous pericardium [12]. The postoperative follow up is generally uneventful as described in the literature but postoperative obstruction of the Pulmonary Veins can occur if the left atrium is too small in the mixed type of total anomalous pulmonary venous connection [13-14]. Late obstruction of pulmonary venous return is possible if the roof of the coronary sinus is not largely resected enough [15]. Our patient remains asymptomatic.

## 5. Conclusion

Total anomalous pulmonary return is rare in his cardiac type and our case is unusual by the fact that the patient is 15 years old. We can affirm that cardiac type of total pulmonary venous return can evolve until teenage if the atrial septal defect is large. Evolution is good after complete repair.

## Conflict of Interest Statement

There are no conflict of interest.

## References

- [1] Kirshbom PM, Myung RJ, Gaynor JW. Preoperative pulmonary venous obstruction affects long-term outcome for survivors of total anomalous pulmonary venous connection repair. *Ann Thorac Surg* 2002; 74 (5): 1616–1620.
- [2] Burroughs JT, Edwards JE. Total anomalous pulmonary venous connection. *Am Heart J* 1960; 59: 913–931.
- [3] Myung KP. Total anomalous pulmonary venous return. In: *Paediatric Cardiology for Practitioners*. 4th Edition, 2002, Mosby Inc., An imprint of Elsevier science, 11830 Westline Industrial drive, St. Louis, Missouri 63146, p-202-2.
- [4] Xu-hua Jian, Jinsong Huang, Yiqun Ding, Xue-jun Xiao, Min Wu, Ji-mei Chen, and Jian Zhuang. Surgical Outcome of Isolated Total Anomalous Pulmonary Venous Connection in Adults: A 14-Year Experience. *J Card Surg* 2012; 27: 736-739.
- [5] Sachin Talwar, Yatin Arora, Saurabh Kumar Gupta, Shyam Sunder Kothari, Sivasubramanian Ramakrishnan, Anita Saxena, and Shiv Kumar Choudhary. Total Anomalous Pulmonary Venous Connection beyond the First Decade of Life. *World Journal for Pediatric and Congenital Heart Surgery* 2019, 10 (2): 185-191.
- [6] Rahman MM, Sheikh MSI, Islam MS, Nawshin S, Khanum S, Saklayen G, Uddin J Total Anomalous Pulmonary Venous Connection (TAPVC) - A Case Report. *Ibrahim Card Med J* 2011; 1 (1): 59-61.
- [7] Brian Kogon, Jan Fernandez, Subhadra Shashidharan, Kirk Kanter, Bahaaldin Alsoufi. A 30-year experience with mixed-type total anomalous pulmonary venous connection: a word of caution *Cardiology in the Young* 2016: 1-7.
- [8] Aysel Turkvatan, Hasan Tahsin Tola, Pelin Ayyildiz, Erkut Ozturk, Yakup Ergul, Alper Guzeltas. Total Anomalous Pulmonary Venous Connection in Children: Preoperative Evaluation with Low-Dose Multidetector Computed Tomographic Angiography. *Tex Heart Inst J* 2017; 44 (2): 120-126.
- [9] Ping YW, Be TH, Jen HL et al. Significance of Pulmonary Venous Obstruction in TAPVR. *J Chin Med Assoc* 2004; 67: 331-335.
- [10] Jae Gun Kwak, Cheul Lee, Eun Young Choi, Jin Young Song, and Chang-Ha Lee. Dilated Unroofed Coronary Sinus Mimicking CorTriatriatum in Cardiac-Type Total Anomalous Pulmonary Venous Connection. *J Cardiac Surg* 2012 Sep; 27 (5): 621-623.
- [11] Matthew D Files, and Brian Morray. Total Anomalous Pulmonary Venous Connection: Preoperative Anatomy, Physiology, Imaging, and Interventional Management of Postoperative Pulmonary Venous Obstruction. *Seminars in Cardiothoracic and Vascular Anesthesia* 1-9.
- [12] Masaaki Yamagishi, Keisuke Shuntoh, Akiyuki Takahashi, Takeshi Shinkawa, Takako Miyazaki, Nobuo Kitamura. Intra-atrial rerouting by transference of the posterior left atrial wall for cardiac-type total anomalous pulmonary venous return. *J Thorac Cardiovasc Surg* 2002; 123: 996-9.
- [13] Sachin Talwar, Shiv Kumar Choudhary, Srikrishna Reddy, Anita Saxena, Shyam Sunder Kothari, Rajnish Juneja, Balram Airan. Total anomalous pulmonary venous drainage beyond childhood. *Interactive CardioVascular and Thoracic Surgery* 2008; 7: 1058–1061.
- [14] Deborah Y Ho, Brian R White, Andrew C Glatz, Christopher E Mascio, Paul Stephens Jr, Meryl S Cohen. Postoperative Obstruction of the Pulmonary Veins in Mixed Total Anomalous Pulmonary Venous Connection. *Pediatric Cardiology* 2018; 39: 1489–1495.
- [15] Fawwaz R. Shaw, M. D. 1 and Jonathan M. Chen, M. D. 2. Surgical Considerations in Total Anomalous Pulmonary Venous Connection. *Seminars in Cardiothoracic and Vascular Anesthesia* 1–6.