

Supine Mini Percutaneous Nephrolithotomy a Substitute to Prone Mini Percutaneous Nephrolithotomy for the Management of Renal and Proximal Ureteric Calculi

Bhalaguru Iyyan*, Puvai Murugan, Shree Vishnu Siddarth, Krishna Mohan Boopathy Vijayaraghavan

Department of Urology, PSG Hospital, Coimbatore, India

Email address:

drbhalaguru@yahoo.com (Bhalaguru Iyyan)

*Corresponding author

To cite this article:

Bhalaguru Iyyan, Puvai Murugan, Shree Vishnu Siddarth, Krishna Mohan Boopathy Vijayaraghavan. Supine Mini Percutaneous Nephrolithotomy a Substitute to Prone Mini Percutaneous Nephrolithotomy for the Management of Renal and Proximal Ureteric Calculi. *International Journal of Clinical Urology*. Vol. 7, No. 2, 2023, pp. 34-39. doi: 10.11648/j.ijcu.20230702.12

Received: March 12, 2023; **Accepted:** June 5, 2023; **Published:** July 27, 2023

Abstract: *Goal:* We aimed to compare the outcome of Mini Percutaneous nephrolithotomy (M-PCNL) performed using our modified supine position with standard prone M-PCNL for renal and proximal ureteric calculi. *Materials and Methods:* A prospective study between March 2020 to June 2022, including 202 patients undergoing Mini-PCNL was included in this study: 136 patients (160 renal units) underwent in M-PCNL in the modified supine position (Iyyan's position) and were compared to 66 patients undergoing Mini-PCNL in the prone position. The stone size was assessed by Non Contrast computed tomography scan (NCCT) of kidney, ureter, and bladder (KUB). The surgical outcomes of anesthesia time, surgical time, radiation dose, radiation time, stone free rate, length of stay in hospital and post-operative complications were compared. Chi-square and t-tests were used. *Results:* Total of 202 patients were registered, 136 patients of supine miniperc PCNL and 66 patients of prone miniperc PCNL. Out of 202 patients 130 patients were male and 72 were female. The mean age (in years) in Supine M-PCNL was 40.62 ± 1.60 while in prone M-PCNL it was 38.61 ± 71 . The mean operative time (minutes) was 45.31 ± 72 in Supine M-PCNL and 72.22 ± 16 in Prone M-PCNL. Complete stone clearance was seen in 133 patients in supine M-PCNL versus 60 patients in prone M-PCNL. There were no major complications in both the groups. The mean post-operative hospital stay (days) was 2.6 in supine M-PCNL versus 4.1 in prone PCNL. Stone clearance rate were higher in Supine M-PCNL. *Conclusions:* Modified supine M-PCNL has significantly less anesthesia time, less surgical time, less radiation time and dose, less hospital stay and higher stone-free rate compared with prone M-PCNL in our series.

Keywords: Renal Calculi, Percutaneous Nephrolithotomy, Prone Position, Modified Supine Position (Iyyan's Position) Stone Free Rate

1. Introduction

Percutaneous nephrolithotomy (PCNL) is advocated as the therapy of choice for large renal calculi (>20 mm) and also for smaller stones (10–20 mm) of the lower calyceal stone and proximal ureteric calculi [1]. The traditional prone position for PCNL is recommended by a majority of endourologists [2] due to amiability in the anatomy of the kidney, procedure, wide surface area for choice of puncture and more direct approach to the kidney [3]. However, the prone position is associated with several anaesthetic, surgical

and rational disadvantages compared to supine position. Even though PCNL is the option in treatment of renal and proximal calculi more than 2 cm. Standard PCNL has dreadful complication like hemorrhage even in experienced hands due to wider diameter of the fascial dilators and Amplatz used. To minimize the incidence of hemorrhages, Mini Percutaneous nephrolithotomy (M-PCNL) was first initiated by Jackman in pediatric group in 1988 followed by ultra M-PCNL, micro M-PCNL and supra M-PCNL.

M-PCNL has been introduced in the market in view of smaller diameter in the fascial dilators, nephroscope and Amplatz sheath [4]. Supine PCNL was introduced by Valdivia in 1987 and it has become popularized only after 1998 with the series of 557 patients. Our modified supine position (Iyyan's position) that combines a tilted supine position with ipsilateral leg straight and opposite leg in lithotomy with two small jelly bolster, one below the flank another under the hip joint provides the additional benefit of allowing simultaneous retrograde access to the upper tracts using flexible ureteroscopy. This enables a dual approach to large staghorn calculi and proximal ureteric stones potentially reducing the operative time, trauma to the patient and increasing the stone free rate. Mini-PCNL has not only been used for the removal of small lower calyceal stones, but for the treatment of large impacted proximal ureteric calculi and staghorn calculi as well.

The term Mini perc PCNL was first described by Jackman in 1998 for renal calculi in children using 13 Fr access Sheath. Mini perc should be used more specifically in access Sheath of size 14 – 20 Fr. Ultra Mini perc PCNL was first described by Desai et al 2013 using access sheath of 11-13 Fr with 6 Fr nephroscope. Micro PCNL was first reported in 2011 by Desai using 4.8 Fr renal access sheath. Mini micro PCNL is recent modification of micro PCNL introduced by Sabnis in 2013 using 8 Fr metallic sheath [4]. Decreasing the size of the access sheath decreases the damage to the renal parenchyma and hence decreases the risk of renal bleeding.

2. Materials and Methods

A prospective study was conducted on 202 patients undergoing M PCNL where 136 patients (160 renal units) underwent M-PCNL in the modified supine position and was compared to 66 patients in the standard prone position from March 2020 to June 2022 at our institution. Institutional Review Board approval obtained from the PSG institute of medical sciences and research Institutional human ethics committee (Ref number: PSG/IHEC/2022/Appr/Exp/152). All patients with renal stones and proximal ureteric calculi size more than 2 cm were included in this study.

2.1. Exclusion Criteria

- 1) Patient with abnormal urinary tract like pelvic kidney, horseshoe kidney
- 2) Patient with skeletal malformation
- 3) Patients with urosepsis
- 4) Patient with single kidney
- 5) Pediatric patients (< 15 years old)
- 6) Pregnancy with renal calculi

2.2. Preoperative Evaluation

Detailed medical history, physical examination, complete blood count, renal function test, serum biochemistry, coagulation profile, serology tests and urine culture were assessed. All patients were evaluated by Non contrast computed tomography of kidney, ureter and bladder (NCCT-

KUB). Third generation cephalosporin's was given as antibiotic prophylaxis to all patients. All patients had sterile urine culture prior to procedure.

2.3. Supine Mini-PCNL Technique

Supine tubeless M-PCNL was done under spinal anesthesia. Initially, in the lithotomy position, Cystoscopy was performed and a 5 Fr ureteric catheter was deployed into the renal system under a C-arm intensifier. The patient was then positioned in a modified supine position (Iyyan's position) as shown in Figures 1 & 2. Two small jellies bolster one under the flank to obtain a mild rotation of about 10-15 degrees and another under the hip joint was placed. The ipsilateral arm was adequately protected and left lying over the thorax. The ipsilateral leg was kept straight and the contralateral leg flexed and abducted at the hip, and flexed at the knee. The pelvicalyceal system (PCS) was opacified by injecting non-ionic water-soluble contrast (Iohexol) and the desired calyx was selected for the initial puncture. Using an 18 G needle, the puncture was done under fluoroscopic guidance. 0.032 hydrophilic guide wire was introduced into the PCS and gradually deployed into the ureter. Tract dilatation was done using a single-step 18 Fr Teflon dilator and then a 20 Fr amplatz sheath with 18 Fr mini nephroscope was introduced into the renal system. Using Pneumatic lithoclast, stones were fragmented. The large fragments were expelled by the Bernoulli phenomenon with intermittent removal of the nephroscope out of the amplatz sheath. Using Fluoroscopy and nephroscopy stone clearance was assessed (Figure 3). 5 Fr 26 cm Double JJ stent was deployed into the renal system once good clearance was achieved. All patients received 20 ml of 0.25% Ropivacaine with 0.5 Microgram/kg bodyweight Dexmedetomidine for tract block. Nephrostomy tract Infiltration is done by inserting a 23 gauge spinal needle up to the renal capsule under fluoroscopy guidance along the amplatz sheath at 6 and 12 O'clock positions. The Amplatz sheath was removed under the vision once there is no active bleeding in the PCS and the PCN tract closed using 2-0' Non-absorbable Monofilament sutures. No Nephrostomy tube was deployed into the renal system once good clearance was achieved. Compressive dressing was applied at the surgical site (Figure 4).

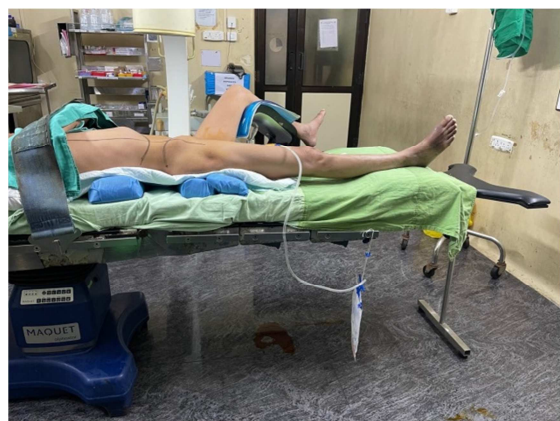

Figure 1. Modified Supine Position - Iyyan's position.

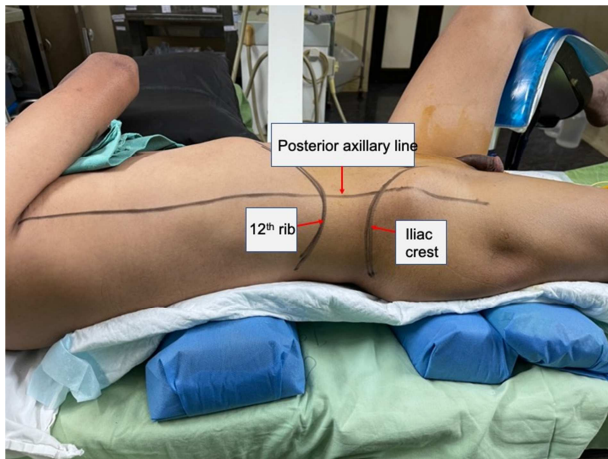


Figure 2. Surface marking for supine mini-percutaneous nephrolithotomy using Modified supine position- Iyyan's position.

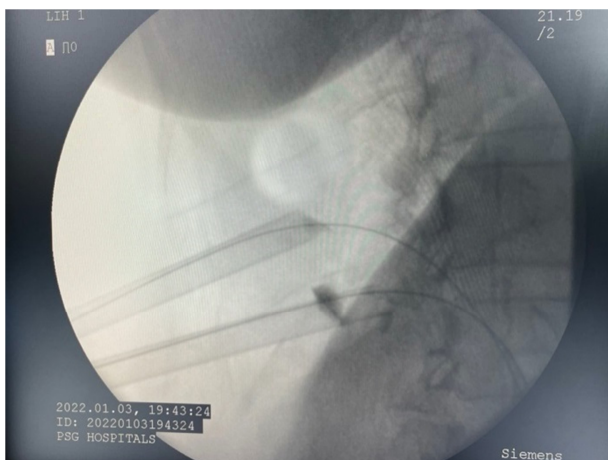


Figure 3. Amplatz introduced into renal system over a guide wire by single step dilatation in two tracts.

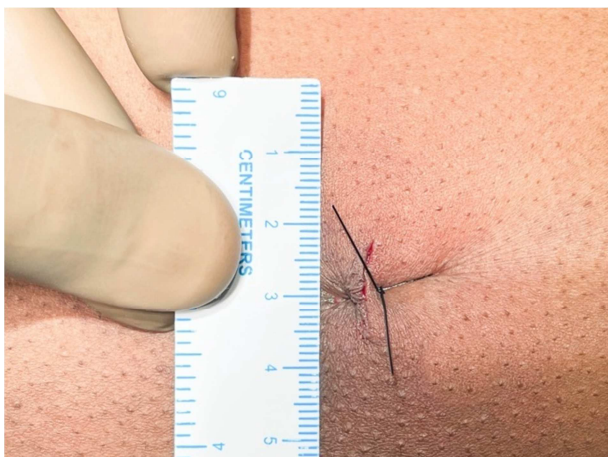

Figure 4. Sutured wound of supine mini-percutaneous nephrolithotomy puncture site.

2.4. Prone Mini-PCNL Technique

M-PCNL was performed in prone position under general anesthesia. Before prone positioning, cystoscopy was done to deploy 5-Fr ureteric catheter into the Pelvicalyceal system. Contrast media (Iohexol) was injected into the ureteric

catheter to identify the pelvicalyceal anatomy. Percutaneous puncture was made under fluoroscopic guidance of the desired calyx using 18G needle. Once the needle was confirmed in the desired calyx, 0.032 thermo guide wire was inserted into the pelvicalyceal system or some time down to the bladder under fluoroscopy. Tract dilatation was done using a single-step 18 Fr Teflon dilator and then a 20 Fr amplatz sheath with 18 Fr mini nephroscope was introduced into the renal system. Using Pneumatic lithoclast stones were fragmented and good clearance achieved. Clearance was checked under fluoroscopy and nephroscopy. 5 Fr 26 cm Double JJ stent was deployed into the renal system. Track infiltration was done using 0.25% of Bupivacaine with 23-Gauge spinal needle at 6-o'clock and 12-o'clock position for post-operative analgesia. Amplatz sheath was removed at the end of the procedure once there is no bleeding in the PCS tract and PCS tract was closed using 2-0' Non- absorbable Monofilament sutures. No Nephrostomy tube was deployed into the renal system. Compressive dressing was applied at the surgical site.

Measured data included radiation dose, radiation time, stone free rate, patient body mass index (BMI), stone size, operative time, length of stay in hospital and postoperative complications.

The data was analysed by SPSS ver.22.0 (SPSS Inc., Chicago, IL, USA) using chi-square and t-tests. A p-value less than 0.05 were considered statistically significant.

3. Results

Total of 202 patients were operated for M- PCNL out of these 136 patients (160 renal units) underwent modified supine M-PCNL and 66 patients underwent prone M-PCNL. The mean age group of these patients in both the groups was 40.6 +/- 10.60 and 72.22+/- 16 years. The male to female ratio in both the groups were similar. Patient who underwent modified supine M-PCNL had higher mean BMI (32.0 kg/m²). Stone size, location and composition in both the groups were similar. All the prone M-PCNL patients were operated under general anesthesia and modified supine PCNL patient were operated under spinal anesthesia. The mean operative time (includes anesthesia, ureteric catheter positioning, puncture time radiation time) for supine M-PCNL was 45.3+12 while for prone M-PCNL was 72.22+16 minutes.

Hematological & Biochemical parameters in both the groups were similar. Patient Characteristics, stone Characteristics and puncture site are shown in Tables 1 & 2 Mean operative time, radiation time and radiation doses were significantly lower in modified supine M-PCNL compared to prone M-PCNL. Majority of these patients in both groups had lower calyceal puncture. Four patients required two puncture in supine M- PCNL and six patients required two puncture in prone M- PCNL. All patients in both the groups underwent tubeless M-PCNL (No Nephrostomy tube only DJ stent deployed).

Table 1. Patient characteristics.

Characteristic	Modified supine position	Prone position
No. of renal units	160	66
No of patients	136	66
Sex		
Male	82	48
Female	54	18
Age (years)	40.60 ±10.60	38.6±7.1
Body mass index (kg/m2)	32.0±9.1	26.0±7.1
Stone burden (mm)	24.6±11.2	23.2±10.2

Table 2. Stone Characteristics and puncture sites.

Variable	Modified supine (n=160)	Prone (n=76)
Puncture site		
Lower calyx	124	48
Middle calyx	30	12
Upper calyx	6	6
Stone location		
Renal pelvic calculi	42	18
Lower calyx calculi	38	14
Middle calyx calculi	24	08
Upper calyx calculi	06	04
Multiple calyceal stones	39	04
Partial staghorn	08	12
Complete staghorn	3	6
Multiple Puncture	4	6

Values are presented as number (%).

NA, not applicable

Table 3. Surgical Outcomes.

Variable	Modified supine position	Prone position
Operative time (Anaesthesia, Positioning, puncture, Radiation) (min)		
Length of hospitalization (D)	2.1+2.6	3.0+3.1
Stone free rates (%)	98.12	90.9
Radiation time (min)	9.8 min	16 min
Radiation dose (mSv)	70	96
Post op complications		
Urosepsis	3	5
Blood transfusion	4	8
Urinary leakage	01	01
Pseudo-aneurysm	02	01
Residual stones	03	06
Auxiliary procedures	03	06

Values are presented as mean±-standard deviation unless otherwise indicated

Clinically significant residual fragments (CSRF) are defined as stone size > 4 mm following percutaneous procedure on NCCT KUB. CSRF were seen in three patients in modified supine M-PCNL and six patients in prone M-PCNL. Stone clearance in modified supine M-PCNL was 98.12% and in prone M-PCNL was 90.3%. All the nine patients underwent flexi Ureterscopy and Laser lithotripsy as an ancillary procedure to get complete stone clearance. 22 patients had postoperative pain which was more than 15 in the Smiley face score in supine M-PCNL group and 31 patients had pain in Prone M-PCNL.

The mean drop in the hemoglobin was significantly lower in supine M- PCNL (3 patients) compared to Prone M-PCNL (8 patients). None of these patients had pleural, colonic or pelvicalyceal injuries. Four patients had packed red cell

blood transfusion in supine group and eight patients in prone groups. Two patients underwent selective renal artery angioembolization for pseudoaneurysm in supine mini perc PCNL. Both the patient had emphysematous pyelonephritis prior to percutaneous procedure. One patient had selective renal artery angioembolization for pseudoaneurysm in prone M-PCNL. Five patients developed fever > 38 C for 72 hours in prone M-PCNL and three patients in supine M- PCNL, which was managed with Intravenous antibiotics.

Assets and Liabilities of Supine M-PCNL

Assets:

- 1) Refinements in anesthetic management: Better access to the patient for cardiovascular and pulmonary management, less risk of injury to cervical spine, tracheal compression Musculo-skeletal complications and ocular damage. Improved ventilator-associated parameters in obese patients, decrease fluid absorption particularly in patients with compromised cardiovascular stature, there by reduces systemic bacterial infection. Decreased cardiac output venous status and thrombo-embolic events are all recognized complications of prone PCNL, which are not seen in supine PCNL.
- 2) Improvements in patient positioning and less operative time: No need to reposition the patient after urethral and ureteric catheter placement. Single draping and same position is used throughout the entire procedure.
- 3) Decreased radiation exposure and improved ergonomics of fluoroscopy: The surgeon can work comfortably by sitting throughout the procedure. Surgeons' hands are not directly exposing under C- arm. C-arm can be move freely not in succeed the nephroscopy.
- 4) Decreased intrarenal pressures: Angulations of the amplatz sheath during supine PCNL is towards the floor therefore results in increased drainage of fluids and stone fragments from the kidney there by decreasing the intrarenal pressure.
- 5) Simultaneous bilateral endoscopic procedure:
- 6) Modified Valdivia position provides simultaneous manipulation of antegrade and retrograde approaches to pelvicalyceal system. Increase the stone free rates of M-PCNL while decreasing the need for additional punctures.
- 7) Decrease pyelovenous back flow with results in decreased in absorption of irrigation in supine M-PCNL.
- 8) Decline slope of the access tract promotes the spontaneous of exist stone fragments.
- 9) Single-session bilateral supine M-PCNL under spinal anesthesia has been shown to be safe and feasible in our institution.

Liabilities:

- 1) Hyper mobility of the kidney: applying gentle abdominal pressure by the surgeon's hand to reduce the mobility during puncture.
- 2) Longer percutaneous tract: Puncture will be more lateral that will Increase the tract length in supine PCNL hence

it may be useful to have longer length of rigid nephroscopy and Amplatz sheaths.

- 3) Colonic injury: Retro-renal or posterolateral position of the colon is more common and left rather than right side.

4. Discussion

Jackman implemented the first Mini- PCNL for renal calculi in an adult patient using a small access sheath (13 Fr) using pediatric cystoscopy in 1998. Valdivia *et al.* narrated the supine PCNL in 1987 with potential superiority in terms of ergonomics and the operation in regional anesthesia [5]. Earlier Valdivia described his supine PCNL by the placement of a 3-liter saline back beneath the patient's flank to improve exposure to the area where the percutaneous puncture is performed following this various positioning like complete supine, modified supine and lateral positions has been reported [6]. The incidence of retro-renal colon position in supine versus prone M-PCNL being 1.9% versus 10% respectively [7].

Supine PCNL employed a single positioning throughout the entire surgery, easy patient ventilation, protection of the patient from positional injuries, more convenient access to the patient by the anesthesiologist, an improved user-friendly surrounding to the endourologist (seated while during surgery), and an easy access to endoscopic combined intrarenal surgery (ECIRS) if needed. We found that the M-PCNLs performed in the modified supine position had a significantly higher stone-free rate than prone M-PCNL. Simultaneous antegrade and retrograde access which is an advantage of the modified supine PCNL's also gives dual access to large stag horn renal calculi as well as ureteric calculi provides better stone clearance in a single procedure [8]. A large group of study in supine M-PCNLs was done with no nephrostomies or completely tubeless, while the traditional prone M-PCNLs all had nephrostomies, which may delay discharge from hospital [9]. To our knowledge this is the largest prospective single centre study comparing standard prone PCNL with our modified supine position (Iyyan's position). Mini- PCNL has substantial advantage over standard PCNL in terms of less bleeding, less blood transfusion, high chance of tubeless PCNL and reduces hospitalization. We found that there was shorter operative time in the modified supine group compared to the prone group.

Supine M-PCNL also admit easier and faster access to the airway should the need for intubation arise. Conducting M-PCNL in the traditional prone position required the patient to be moved from a supine to a prone position, needing repositioning and re-draping together with staff rescrubbing and re-gowning which has added difficulties in obese patients, which are minimized in the modified supine position. Prone position is associated with increased risk of postoperative visual injury, direct pressure injuries and peripheral nerve damage, more so in obese patients [10].

Supine M-PCNL in obese patients, presenting with cardiopulmonary comorbidities has no such difficulties.

Obese patients, patients with a solitary kidney and patients with spinal deformities are unable to lie in the prone position in which supine M-PCNL has shown superior results [11, 12, 13]. No significant difference was noted in complication rates between supine and prone M- PCNL with respect to blood transfusion and Urosepsis [9]. Patients with uncontrolled diabetes, large stone burden, Urosepsis and impaired renal function have a high possibility of septic shock and require longer hospitalization time in both the groups [14]. Tubeless M-PCNL is apparently associated with shorter hospitalization and is hence cost effective [15]. In our institution during the last one decade most of the patients who underwent M- PCNL are tubeless that reduces the hospitalization and is more cost effective.

Ultra miniperc is the recent advance in PCNL, modified by Desai *et al* by using 3 Fr telescope in a 7.5 nephroscopy which is introduced into the renal system via the 11–13 Fr size amplatz sheath. The decrease in the size of the tract will reduce the renal damage and the risk of bleeding complications. Ultra miniperc is safe and effective for small renal stone less than 2 cm with good stone clearance rate and less hemorrhagic complications. Supine Ultra miniperc is the preferable option in treating the renal calculi in patients with compromised Cardiovascular and pulmonary status and in morbidly obese patients [16].

RIRS has its own superiority of minimal blood loss without renal injury, yet its higher cost, unable to use in diverticular calculi; narrowed infundibulum and maintenance of the flexible ureterorenoscopes are points of concern [17]. Simultaneous bilateral endoscopic surgery for bilateral renal stones is safe effective and minimal morbidity in which simultaneous flexible Ureteroscopy (f-URS) in one side and supine percutaneous nephrolithotomy (PCNL) in the other side. It has potential advantages of shorter operative time, reduced anesthesia, and reduced hospital time [18].

Mini PCNL is recommended for management of large renal stones in children and is a reasonable alternative for patients with small-to-medium-sized stones, to reduce morbidity associated with larger access tracts with less blood loss and shorter hospitalization [19]. Vaddi *et al* reported a case of supine PCNL in 9-month-old female baby who had renal pelvic and lower calyceal calculi and insisted the feasibility, safety and advantages of supine PCNL even in less than 1 year age group [20]. Gamal *et al* outlined that Pediatric supine PCNL is a safe and effective method for management of pediatric renal stones and carries the advantages of easy upper calyx access through the lower calyceal tract, low incidence of fluid absorption, hypothermia and easy anesthesia monitoring [21].

The limitations in this study were that the cases were not randomized, and therefore could introduce selection bias. The learning curve associated with the modified supine position, should also be considered as most surgeons were already familiar with the prone position for M-PCNL. All the M-PCNL's were done by the single surgeon, so possibility of bias was also there.

5. Conclusions

This prospective study which compares the modified supine M-PCNL with the standard prone M-PCNL demonstrates reduced operative time, length of hospital stay, increased stone-free rates and fewer complications and improves surgeon's user friendly system and anesthesiologist's access to the patient.

Conflicts of Interest

The authors declare that they have no competing interests.

References

- [1] Türk C, Knoll T, Petrik A, Sarica K, Skolarikos A, Straub M, et al. Guidelines on Urolithiasis. Arnhem (The Netherlands): European Association of Urology (EAU) 2013 [Google Scholar].
- [2] José G Valdivia, Roberto M Scarpa, Mordechai Duvdevani, Andreas J Gross, Robert B Nadler, Kikuo Nutahara, Jean J M C H de la Rosette, Croes PCNL Study Group. J Endourol. 2011 Oct 25 (10).
- [3] Miano R, Scoffone C, De Nunzio C, Germani S, Cracco C, Usai P, et al. Position: prone or supine is the issue of percutaneous nephrolithotomy. J Endourol 2010; 24: 931-8.
- [4] Anna wright, Nick rukin, and Bhaskar k. Somnani, et al Mini, ultra, micro' - nomenclature and cost of these new minimally invasive percutaneous nephrolithotomy (PCNL) techniques. Therapeutic advances in urology. April 2016; 8 (2). Pub med.
- [5] Valdivia-Uria JG, Lachares Santamaría E, Villarroya Rodríguez S, et al. Percutaneous nephrolithectomy: simplified technic (preliminary report) Arch Esp Urol. 1987; 40: 177–180.
- [6] Bach C, Goyal A, Kumar P, et al. The Barts 'flank-free' modified supine position for percutaneous nephrolithotomy. Urol Int 2012; 89: 365-8.
- [7] Hopper KD, Sherman JL, Luethke JM, et al. The retro renal colon in the supine and prone patient. Radiology 1987; 162: 443-6.
- [8] McCahy P, Rzetelski-West K, Gleeson J. Complete stone clearance using a modified supine position: initial experience and comparison with prone percutaneous nephrolithotomy. J Endourol. 2013; 27: 705–709.
- [9] Liu L, Zheng S, Xu Y, Wei Q. Systematic review and meta-analysis of percutaneous nephrolithotomy for patients in the supine versus prone position. J Endourol. 2010; 24: 1941–1946.
- [10] Atkinson CJ, Turney BW, Noble JG, Reynard JM, Stoneham MD. Supine vs. prone percutaneous nephrolithotomy: an anesthetist's view. BJU Int. 2011; 108: 306–308.
- [11] Fuller A, Razvi H, Denstedt JD, Nott L, Pearle M, Cauda F, et al. The CROES percutaneous nephrolithotomy global study: the influence of body mass index on outcome. J Urol. 2012; 188: 138–144.
- [12] Wang Y, Hou Y, Jiang F, Wang Y, Wang C. Percutaneous nephrolithotomy for staghorn stones in patients with solitary kidney in prone position or in completely supine position: a single-center experience. Int Braz J Urol. 2012; 38: 788–794.
- [13] Goumas-Kartalas I, Montanari E. Percutaneous nephrolithotomy in patients with spinal deformities. J Endourol. 2010; 24: 1081–1089.
- [14] Seitz C, Desai M, Häcker A, Hakenberg OW, Liatsikos E, Nagele U, et al. Incidence, prevention, and management of complications following percutaneous nephrolitholapaxy. Eur Urol. 2012; 61: 146–58.
- [15] Sofer M, Beri A, Friedman A, et al. extending the application of tubeless percutaneous nephrolithotomy. Urology. 2007; 70: 412–416.
- [16] Desai J, Solanki R. Ultra-mini percutaneous nephrolithotomy (UMP): one more armamentarium. BJU Int. 2013; 112: 1046–9.
- [17] Retrograde ureteroscopic intrarenal surgery for large upper ureteric and renal calculus. Indian J Urol. 2010 Jan-Mar; 26 (1): 46–49. M. Prabakaran.
- [18] Giusti G, Proietti S, Rodríguez-Socarrás ME, et al. Simultaneous Bilateral Endoscopic Surgery (SBES) for Patients with Bilateral Upper Tract Urolithiasis: Technique and Outcomes. Eur Urol 2018; 74: 810-5.
- [19] Nikolaos Ferakis and Marios Stavropoulos. Mini percutaneous nephrolithotomy in the treatment of renal and upper ureteral stones: Lessons learned from a review of the literature. Urol Ann. 2015 Apr-Jun; 7 (2): 141–148.
- [20] Chandra Mohan Vaddi, Paidakula Ramakrishna, Siddaliga Swamy, et al. Supine percutaneous nephrolithotomy in a 9-month infant: Urology Case Reports, 2021-01-01, Volume 34, Article 101424,.
- [21] W Gamal, E Moursy, M Hussein, A Mmdouh, A Hammady, M Aldahshoury. Supine pediatric percutaneous nephrolithotomy. J Pediatric Urol. 2015 Apr; 11 (2): 78. doi: 10.1016/j.jpuro.2014.10.012. Epub 2015 Mar 4.