

Case Report

Endoscopic Treatment of Ureterocele One Case at Military Hospital OBO

Smith Giscard Olagui^{1,*}, Dimitri Mbethe², Christelle Mézene², Adrien Mougougou², Gloire Allogho Mbouye², Mariette Nsa Bidzo², Fatou SY-Moutsinga¹, Jean Placide Owono Mbouengou¹, Eric Jacob Benizri³

¹Urology and Visceral Service, Military Instruction of Omar Bongo Ondimba Hospital, Faculty of Medicine, Urology Department University of Health Sciences, Libreville, Gabon

²Urology Department, Military Instruction of Omar Bongo Ondimba Hospital, Faculty of Medicine, Urology Department University of Health Sciences, Libreville, Gabon

³Urology Department of Nice, Nice Polyclinic, Surgery Department, Faculty of Medicine, University of Health Sciences, Nice, France

Email address:

golagui@icloud.com (Smith Giscard Olagui), mezenechristelle1@gmail.com (Christelle Mézene), dimitri.mbethe@yahoo.fr (Dimitri Mbethe), mougougouadrien@yahoo.fr (Adrien Mougougou), nsabidzomariette@gmail.com (Mariette Nsa Bidzo), gloirebriault@gmail.com (Gloire Allogho Mbouye), jpowono2@yahoo.fr (Jean Placide Owono Mbouengou), bj06@wanadoo.fr (Eric Jacob Benizri)

*Corresponding author

To cite this article:

Smith Giscard Olagui, Dimitri Mbethe, Christelle Mézene, Adrien Mougougou, Gloire Allogho Mbouye, Mariette Nsa Bidzo, Fatou SY-Moutsinga, Jean Placide Owono Mbouengou, Eric Jacob Benizri. Endoscopic Treatment of Ureterocele One Case at Military Hospital OBO. *International Journal of Medical Case Reports*. Vol. 1, No. 4, 2022, pp. 36-39. doi: 10.11648/j.ijmcr.20220104.11

Received: September 10, 2022; **Accepted:** October 12, 2022; **Published:** November 23, 2022

Abstract: *Introduction:* Ureterocele is a rare congenital malformation characterized by pseudo-cystic dilation of the lower extremity of the ureter. It is often discovered in neonates on antenatal ultrasonography which explains its rarity in adults and few publications concerning adult ureterocele. Its treatment is not unequivocal; it is indicated in the case of complicated or symptomatic ureterocele. Early decompressive treatment is advocated to reduce the risk of related renal and urinary tract damage. Endoscopic techniques of incision have been offered utilizing diathermic electrode. *Observation:* We report the clinical case of a 39-year-old man suffering from chronic low back pain not relieved by medical treatment. The ultrasound performed shows signs of ureteral obstruction of bladder origin. The cystoscopy made it possible to make the diagnosis of a voluminous right ureterocele, which will be treated by transurethral incision at the diathermic loop. The post-operative follow-up was simple. At 3 months, there was no vesico-ureteral reflux, no infection, no recurrence of the ureterocele. *Discussion:* It is a congenital malformation that affects several births. The etiology remains unknown, and the obstructive malformation theory is the most evoked. Its clinical symptomatology is non-specific. Its diagnosis is endoscopic, and the treatment is most often surgical depending on the type and its clinical presentation. *Conclusion:* The adult ureterocele is a rare entity, which must be recognized quickly in order to limit the serious consequences on the upper tract. diagnosis must be early. Its treatment is endoscopic, and vesico-ureteral reflux is the most frequent complication.

Keywords: Ureterocele, Endoscopic Resection, Endoscopic Meatotomy

1. Introduction

Ureterocele, a term first used by Stoeckel in 1907, designates a malformation characterized by a pseudo-cystic dilation of the lower end of the ureter, which can be uni or

bilateral [1]. The advent of antenatal ultrasound and the early management of the pathology has made this entity increasingly rare in adults, explaining the lack of publications concerning it. Low back pain and renal colic remain its main mode of revelation in adults. Diagnosis is mainly radiological

based on uroscanner (late stage) and/or endoscopy (urethrocystoscopy +/- ureteroscopy) [2].

As its treatment is not yet clearly codified, the fact remains that any symptomatic or complicated ureterocele must benefit from surgical treatment [1, 2]. Treatment depends on the site, the associated anomalies, and especially its dimensions [3]. Three attitudes of surgical treatment are possible: meatotomy, endoscopic resection and surgery by excision of the ureterocele followed by ureterovesical reimplantation. Endoscopic treatment has many advantages and deserves to be more widely used [3, 4]. A urethrocystography in the post-operative follow-up makes it possible to detect vesico-ureteral reflux [4, 5].

2. Observation

A 39-year-old patient, with no particular history, who had been complaining for 09 months of chronic right low back pain, poorly systematized, which evolved episodically in a non-febrile context. The clinical examination found this pain caused by the shock of the right lumbar region. The biological assessment was unremarkable. Abdominal ultrasound revealed right uretero-pyelocaliciei dilation, with no visible obstacle. The analgesic treatment of step I then step II, associated with non-steroidal anti-inflammatory drugs (NSAIDs) was instituted, without any real improvement. The urethrocystoscopy was performed as a complementary assessment. This examination revealed the existence of a large right ureterocele, 15 cm long axis (figure 1). Treatment was endoscopic surgery (figure 2 and figure 3). An endoscopic resection of the base of the ureterocele was performed, with continuous haemostasis on the slice of section. There was no lithiasis, the right ureteral meatus was visible and very gaping (figure 4). left ostium had also been seen during the intervention (figure 5). At the same time, a right and left diagnostic ureteroscopy was performed in search of an associated malformation. This additional examination was normal. A urinary catheter was left in place and removed on D3. The postoperative follow-up was simple. A postoperative consultation at 1 month and 3 month was unremarkable.

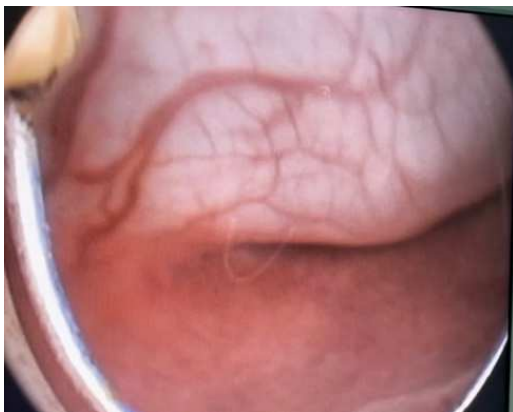

Figure 1. Right ureterocele cystoscopic view.

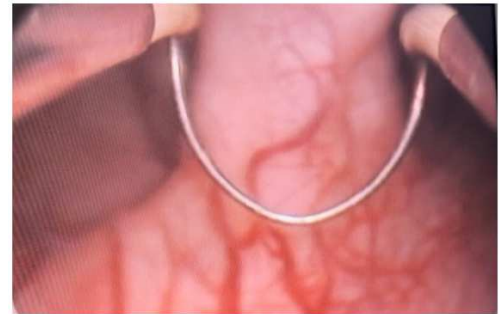

Figure 2. Start of endoscopic resection.

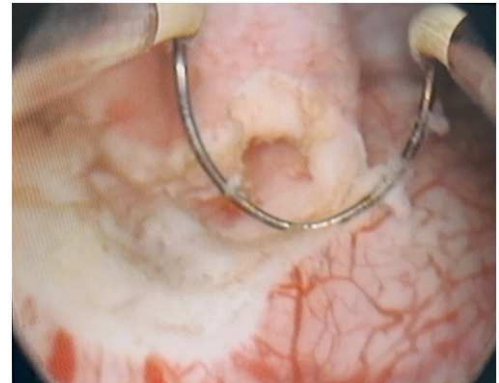


Figure 3. Endoscopic resection.

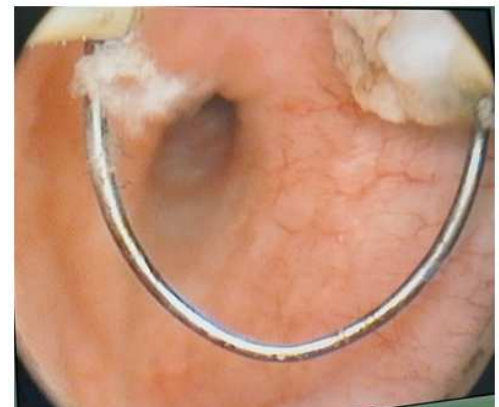


Figure 4. Right ureteral ostium visible after complete resection.

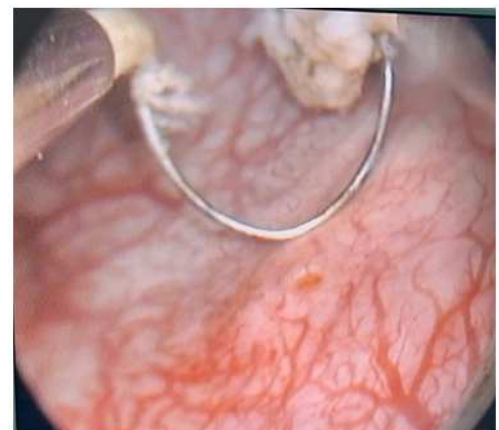


Figure 5. Left ureteral ostium.

3. Discussion

The ureterocele, described for the first time in the 17th century, corresponds to a dilation pseudocystic of the lower end of the ureter, very exactly of the sub mucous segment of the intravesical ureter. The dilation sits between the two muscle layers of the trine [1, 3]. It is a rare congenital malformation estimated at 114,000 births, which affects girls four to six times more than boys [3]. The etiology of ureteroceles remains unknown, however several theories have been proposed, the most retained are the theories obstructive and malformative theories [3].

Its frequency remains poorly estimated in our country. The follow-up of pregnancies, and especially the practice of antenatal ultrasounds between the 28th and the 32nd week of amenorrhea, makes it possible to improve the rate of discovery, and to organize a follow-up of the child [3, 5]. The average age of discovery varies from one region to another, depending on habits and methods of monitoring pregnancies. In adults, 39–40 years remains the age often described in the literature [2, 3]. Some authors describe a female predominance without being really demonstrated, this tendency is not found in all the series [2, 3]. The incidence of bilateral ureteroceles varies according to the authors: 2% for CALDAMO, 10% for BRUÉZIÈR and 23% in our series. The child's ureterocele occurs, according to Coplen, on ureteral duplicity in 80% of cases, and depends on the upper pyelon in 80 to 95% of cases [2]. Adult ureteroceles rarely occur on duplicity and are exceptionally extravesical [3]. Our patient had no other associated malformation including ureteral duplicity, verified by performing intraoperative ureteroscopy. A classification of ureteroceles was proposed by Bruziere and Bondonny, it remains the most used because simple, didactic, and adapted to therapeutic proposals [1, 4].

It includes 4 Type A: Intravesical ureterocele on simple ureter. Type B: Ectopic ureterocele on simple ureter. Type C: Intra-vesical ureterocele on ureteral duplicity.

Type D: Ectopic ureterocele on ureteral duplicity.

Our patient presented with an intravesical ureterocele on a simple type A ureter, without stasis stone. This form is the most frequent and explains the good tolerance and often moderate impact of ureteroceles in adults.

Clinically, adult ureterocele causes nonspecific symptoms related to complications. The repercussion on the upper apparatus is essentially of the obstructive type due to a terminal valve mechanism. The obstructive nature of a ureterocele is responsible for urinary stasis, which promotes the formation of urinary stones in situ and throughout the corresponding urinary tree [2, 3, 6]. Lower back pain and renal colic are the first warning sign, which represents 87% according to certain series, followed by micturition disorders and episodes of haematuria, generally of low abundance [2, 3, 7]. Contrary to the child whose fever remains the most frequent mode of discovery [2]. Chronic disabling low back pain in our patient was the reason for consultations, despite the Palliative II analgesic treatment associated with NSAIDs.

The morphological assessment is represented by the Uro – scanner, which establishes the diagnosis, by allowing the realization of the complete cartography of the urinary tree, by looking for the associated malformations, by looking for the calculations of urinary stasis, by evaluating the dilation of the high apparatus and the state of the renal parenchyma for prognostic purposes. Our patient only had an ultrasound, which showed significant dilation of the ipsilateral pyelocalicel cavities sur toute sa longueur, suggérant un obstacle vésicale.

In the absence of a complete preoperative imaging assessment, we carried out, to search for ureteral duplicity and a stasis calculation, we carried out a diagnostic ureteroscopy of the upper apparatus, which was normal.

The treatment of a ureterocele is indicated in all symptomatic or complicated forms, with the objectives of treating pain, preventing urinary tract infections, ensuring good drainage of the upper urinary tract, and preventing vesico-ureteral reflux, which remains the stake of any endoscopic treatment [8, 9]. Meatotomy should be considered the first-line treatment even in children where it allows rapid and effective decompression of the ureterocele, by making a short sloping incision preserving the posterior detrusor wall and respecting the valve mechanism provided by the mucosa. Inert which collapses under the effect of bladder filling, thus limiting the occurrence of vesico-ureteral reflux (VUR) [10, 11]. Endoscopic resection remains an endoscopic option, especially in the presence of ureteroceles > 3cm [12, 13]. It is constantly responsible for significant reflux, requiring surgical reimplantation [3, 14]. This is the surgical sequence that we established in our patient. We decided on an endoscopic resection given the volume of the ureterocele, the age of the young patient, the symptomatic nature and especially the impact on the kidney. Knowing that the therapeutic project has been explained to the patient, with the possibility of intervention in the event of the appearance of severe VUR. There is no reflux at 3 months in our patient on control urethrocystography (UCG). Monitoring will be done every 3 months. In view of the literature, the real incidence of reflux remains poorly documented and not consensual due to the non-systematic practice of UCG in postoperative follow-up [3, 15]. Wines and O'Flynn find results ranging from 10 to 50% in small series, while Chtourou reports a single case of VUR out of 20 (5%) [2, 3, 6].

Immediate excision of the ureterocele followed by reimplantation of the corresponding ureter remains the prerogative of complicated ureteroceles with significant upstream repercussions. Its efficacy is excellent, and complications are around 2%, mainly stenosis and reflux [12, 15]. Faced with an obstructive ureterocele with destruction of the renal parenchyma, total nephrectomy appears to be the only therapeutic option [13, 15].

In the absence of symptoms and complications, monitoring the ureterocele would be a logical approach [12, 13]. Long-term ultrasound monitoring is then necessary [9, 10].

4. Conclusion

Ureterocele is a congenital malformation whose treatment remains clearly non-standardised. Endoscopic treatment remains the one with less morbidity, but remains the one with a high rate of VUR. Endoscopic resection is interesting in a young subject with a large ureterocele, but it requires strict postoperative monitoring and regular checks in order to detect VUR, which must be treated.

References

- [1] BRUEZIERE J.: ureterocele - Technical Publishing - Encycl. Med. Chir. Kidney, genitourinary organ, 18158 C 10, 10-1990, 11p.
- [2] Sadiki R, Sadiq A, Tazi K, Koutani A, Hachimi M, Lakrissa A. Ureterocele in adults based on a series of 14 cases. *Prog Urol*. 2005 Apr; 15 (2): 231-7; discussion 237. French. PMID: 15999599.
- [3] Derouiche A, Belhaj K, Feki W, Zaafrani R, Chebil M. Place of endoscopic treatment of complicated ureteroceles in adults. *Prog Urol*. 2007 Nov; 17 (7): 1362-6.
- [4] Kurokawa T, Kabuto T, Matsuta Y, Aoki Y, Ito H, Yokoyama O, Oyama N. [Adult Male Ureterocele Detected by Urinary Frequency]. *Hinyokika Kyo*. 2017 May; 63 (5): 207-210. Japanese.
- [5] Oueslati A, Saadi A, Chakroun M, Zaghbib S, Bouzouita A, Derouiche A, Slama MRB, Ayed H, Chebil M. Endoscopic meatotomy in the treatment of ureterocele: results in adult patients. *Pan Afr Med J*. 2020 Aug 4; 36: 243.
- [6] Moore K, Bolduc S. Treatment of vesicoureteral reflux in adults by endoscopic injection. *Urology*. 2011 Jun; 77 (6): 1284-7.
- [7] Kajbafzadeh A, Salmasi AH, Payabvash S, Arshadi H, Akbari HR, Moosavi S. Evolution of endoscopic management of ectopic ureterocele: a new approach. *JUrol*. 2007; 177 (3): 1118-23.
- [8] Sharma A, Garg G, Sharma A, Kumar M, Sankhwar SN. Comparison of electrocautery versus holmium laser energy source for transurethral ureterocele incision: an outcome analysis from a tertiary care institute. *Lasers Med Sci*. 2021 Apr; 36 (3): 521-528.
- [9] Osipov, I B et al. "Kidney triplication with ectopic ureterocele: a case report" *BMC urology* vol. 20, 1 54. 13 May. 2020.
- [10] Pariente JL. Surgical and endoscopic treatment of ureteroceles in adults. *Encycl Med Chir Scientific and Medical Editions Elsevier SAS, Paris: Surgical techniques - Urology*. 2001.
- [11] Blanco M, Laguna M, Candelaria T, Salamida A, Vallejos J. Ureterocele [Ureterocele]. *Medicina (B Aires)*. 2022; 82 (3): 458.
- [12] Parmar KM, Sharma P, Mandal S, Kumar S. Ureterocele with impacted stone. *BMJ Case Rep*. 2020 Jul 8; 13 (7): e236301. doi: 10.1136/bcr-2020-236301.
- [13] Ruiz-Oslé S, Crespo-Atín V. Ureterocele habitado y doble sistema incompleto [Occupied ureterocele and incomplete double collecting system.]. *Arch Esp Urol*. 2020 Sep; 73 (7): 659-660.
- [14] Yoshimura A, Yamanaka K, Wakita T, Fukae S, Yoshida T, Kishikawa H. [Ectopic Ureterocele of Adult Male with Urination Difficulty: A Case Report]. *Hinyokika Kyo*. 2021 Aug; 67 (8): 381-384.
- [15] Sales FRD, Dourado GAC, Ribeiro ACM, de Holanda Madeira Barros H, Cristino DS, Castro AAG, Mesquita FJC. Case Report: Prolapsed Ureterocele-A Differential Diagnosis of Urethral Cysts. *Case Rep Urol*. 2020 Mar 18; 2020: 2490129.