

Myoepithelial carcinoma of the breast developed in an adenomyoepithelioma: A case report

Abdelilah Mouhsine^{1,*}, Ahmed Belkouch², ElMehdi Atmane¹, Redouane Rokhssi¹, Youssef Berrada¹, Lahcen Belyamani², M'barek Mahfoudi¹, Abdelghani El Fikri¹

¹Department of Radiology Military Hospital of Avicenna, Faculty of Medicine and Pharmacy, Marrakech, Morocco

²Emergency Department, Military Hospital of Instruction Mohamed V, Faculty of Medicine and Pharmacy, Rabat, Morocco

Email address:

abdelilahmouhsine@yahoo.fr (A. Mouhsine), belkouch1@gmail.com (A. Belkouch)

To cite this article:

Abdelilah Mouhsine, Ahmed Belkouch, ElMehdi Atmane, Redouane Rokhssi, Youssef Berrada, Lahcen Belyamani, M'barek Mahfoudi, Abdelghani El Fikri. Myoepithelial Carcinoma of the Breast Developed in an Adenomyoepithelioma: A Case Report. *International Journal of Medical Imaging*. Vol. 2, No. 5, 2014, pp. 109-111. doi: 10.11648/j.ijmi.20140205.13

Abstract: Myoepithelial carcinoma of the breast is a rare tumor. We present the case of 58 year-old female. No local or distant metastases were found. Mastectomy with axillary dissection was performed followed by chemotherapy and radiotherapy. Neither recurrence nor distant metastases were detected 12 months later. Clinical, radiological and macroscopic appearances of adenomyoepithelioma are not evocative. Diagnosis is based on histological and immunohistochemical studies. Treatment is not codified.

Keywords: Adenomyoepithelioma, Myoepithelial Carcinoma, Breast

1. Introduction

Myoepithelial, tumors usually located in the salivary glands (1), are very rare and often overlooked when located in the breast. They are characterized by the proliferation of both epithelial and myoepithelial cells (2). The histological diagnosis of these tumors is difficult at frozen section procedure; it is also during the final pathological exam. Immunohistochemical and / or ultrastructural techniques are usually needed to establish the final diagnosis. The first observation was reported by Hamperl in 1970 (3). We report a case that illustrates the diagnostic and therapeutic difficulties of these tumors.

2. Case Presentation

A 58 years old menopausal patient, noted the presence of a nodule in the right breast that had developed over three years, it was discovered by self-examination. This woman had no significant medical history and no family history of breast cancer.

Examination of the right breast objectified at the upper lateral quadrant a nodule measuring 12x 10 cm, painless, mobile on both superficial and deep planes, without cutaneous signs next to it or nipple discharge. Examination

of the left breast was normal. The lymph nodes were free. The rest of the physical examination was unremarkable.

Mammography showed a large hydric tone opacity occupying the upper lateral quadrant of the right breast with distinct limits (Figure 1 and 2). Breast ultrasound highlighted the same lesion as a hypoechoic image measuring 61x 38 mm within some tissular formations (Figure 3). The lesion was classified BI-RAD IV of the ACR classification.

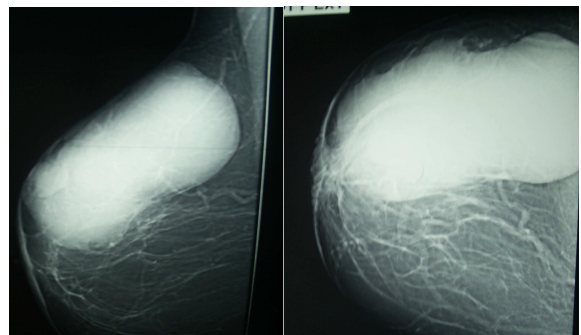


Figure 1 and 2. Mammography showing the opacity occupying the upper lateral quadrant of the right breast with distinct limits

Fine needle biopsy was negative. Histological examination of biopsy samples showed a proliferation of

two cellular contingents, myoepithelial cells with clear cytoplasm in dense layers surrounding the epithelial cells contingent with eosinophilic cytoplasm, the anisokaryosis was discreet. Mitotic ratio was three by field and areas of necrosis were observed. Immunohistochemical study showed that the first contingent reacted strongly with the PS100 and smooth muscle actin, the second reacted with cytokeratin. The proliferation index of KI67 was below 10%. The hormone estrogen receptors and progesterone were negative. Given these histological and immunohistochemical aspects, diagnosis of myoepithelial carcinoma developed in an adénomyoépithéliome was retained.

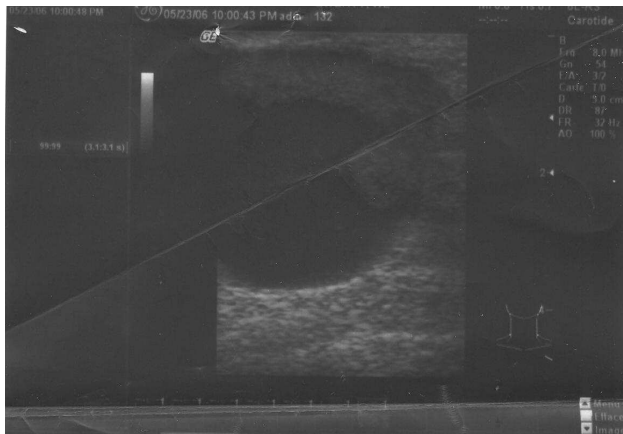


Figure 3. Breast ultrasound showing the same lesion measuring 61x 38mm within some tissular formations.

The search of metastases with chest radiography and abdominal and pelvic ultrasound was negative. Mastectomy with axillary dissection was performed; six lymph nodes removed were free of any tumor proliferation. Treatment was completed by FEC chemotherapy and radiotherapy. The patient is doing well with a drop of 12 months.

3. Discussion

Table 1. Classification of myoepithelial breast lesions as proposed by Tavassoli (4).

1.	Myoepitheliosis
a.	Intraductal
b.	Periductal
2.	Adenomyepithelial adenosis
3.	Adenomyoepithelioma
a.	Benign
b.	With malignant changes (specify the subtype)
c.	Myoepithelial carcinoma arising in an adenomyoepithelioma.
d.	Epithelial carcinoma arising in an adenomyoepithelioma
e.	Malignant epithelial and myoepithelial components
f.	Ssarcoma arising in adenomyoepithelioma
g.	Carcinosarcoma arising in adenomyoepithelioma
4.	Malignant myoepithelioma (myoepithelial carcinoma)

Myoepithelial breast tumors are a very rare entity, described for the first time in 1970 by Hamperl (3). It is characterized by the proliferation of both epithelial and myoepithelial cells (2). In 1991, Tavassoli (4) suggested

classifying these tumors according to their aggressive and malignant potential and subdivided them into three groups. In 2003, this classification was adopted by WHO (Table 1). The average age of onset is 60 years (1) as for our patient (58 years). The tumor size is very variable (1). No risk factors are reported for this type of tumors (5), as in our case.

The clinical findings in case of Myoepithelial carcinoma is usually a regular nodule, firm or hard (1) with rapid growth rhythm located in the lateral part of the breast (7), as for our patient.

The mammographic and sonographic aspects are not specific; however they can guide the diagnosis and give a precise assessment of the lesions before and after treatment (7). MRI appears promising. In our case, the lesion was classified BI-RAD IV ACR; motivating histological examination to assess its malignancy.

The myoepithelial carcinoma, developed in an adénomyoépithéliome, adopts the form of an epithelial cell proliferation constituted from two contingents:

- Cells with abundant cytoplasm, positive on the cytokeratin immunohistochemistry
- Myoepithelial fusiform cells made of clear cytoplasm, positive for S100 protein and smooth muscle actin, associated with signs of local invasion, cytonuclear atypia, necrosis and a high mitotic index (2).

The presence of adénomyoépithéliome structure with areas of necrosis, mitotic activity, anisokaryosis classified our case in the group of myoepithelial carcinoma developed in an adénomyoépithéliome.

Surgical management of this type of tumor is similar to the other breast cancers with wide tumorectomy or mastectomy associated with axillary dissection. The response to chemotherapy and radiotherapy is unknown (7). Local recurrences are possible especially after tumorectomy (1). Metastasis cases are reported in the literature (8).

4. Conclusion

Adenomyoepitheliomas of the breast are rare tumors with double cellular component: epithelial and myoepithelial. The positive diagnosis is difficult to establish; the clinical and radiological features are nonspecific. The development of these tumors is unpredictable. Further studies are needed to establish a diagnostic and therapeutic procedure.

References

- [1] Kdous M, Hachicha R, Gamoudi B, Rahal K, Le myoépithéliome du sein : Difficultés diagnostiques et thérapeutiques. A propos d'un cas. Gynéco. Obstét. Fertil. 2004 (32) : 42-45
- [2] Han B, Ichiro M, Misa N, Xiaojuan W, Takashi O, Yasushi N and al. Myoepithelial carcinoma arising in an adenomyoepithelioma of the breast: Case report with immunohistochemical and mutational analysis. Pathology International 2006; 56: 211-216

- [3] Hamperl H. The myoépithélial (myoépithélials cells). Normal state; regressive changes; Hyperplasia; Tumors. *Curr Topics Pathol* 1970; 53:161–220.
- [4] Tavassoli FA. Myoepithelial lesions of the breast: Myoepitheliosis, adenomyoepithelioma, and myoepithelial carcinoma. *Am J Surg Pathol* 1991;15:554–68.
- [5] Tavassoli FA, Devilee P, eds. World Health Organization Classification of Tumours: Pathology and Genetics of Tumours of the Breast and Female Genital Organs. Lyon: IARC Press, 2003; 87–8.
- [6] Adjenou KV, N'dakena K, Chapiron C, Arbion F, Asquier E, Tétékpor S, Brunereau L. Adénomyoépithéliome du sein : à propos d'une observation et revue de la littérature. *J.Le Sein*, 2004 14 (4) 313-317.
- [7] WOO EK, JAMES AD, MERCER J, ALLAN SM, HOWLETT DC. Myoepithelial carcinoma of the breast: a case report with imaging and pathological findings.
- [8] ROSS RJ, ROSENTHAL MA, GONZALES M. Metastatic myoepithelioma of the breast. *The British Journal of Radiology*, 2005; (78): 444–446.