

Static Renal Scintigraphy in Diagnosis of Pediatric Renal Pyelonephritis

Asmaa Hamdy Mohamed Dkhail^{1,*}, Samah Ahmed Ibrahim Radwan¹, Hossam Mostafa Gad², Hanan Mohamed Saleh El-Ahwal¹

¹Radiodiagnosis Department, Faculty of Medicine, Tanta University, Tanta, Egypt

²Radiology Department, Mansoura Urology and Nephrology Center, Mansoura University, Mansoura, Egypt

Email address:

asmaa.dkhail@gmail.com (A. H. M. Dkhail)

*Corresponding author

To cite this article:

Asmaa Hamdy Mohamed Dkhail, Samah Ahmed Ibrahim Radwan, Hossam Mostafa Gad, Hanan Mohamed Saleh El-Ahwal. Static Renal Scintigraphy in Diagnosis of Pediatric Renal Pyelonephritis. *International Journal of Medical Imaging*. Vol. 8, No. 4, 2020, pp. 106-113. doi: 10.11648/j.ijmi.20200804.17

Received: November 23, 2020; Accepted: December 4, 2020; Published: December 11, 2020

Abstract: Imaging of children who had symptoms and signs of pyelonephritis is aimed to diagnosis of renal injury and identification of risk factors for pyelonephritis that might be uncovered during imaging includes vesico- ureteric reflux (VUR). The purpose of this study was to determine the role of static renal scintigraphy in diagnosis of pediatric renal pyelonephritis and the value of single photon emission computed tomography (SPECT) in diagnosis. This study was carried out on 50 patients in Radiology Department at Mansoura Urology and Nephrology center and Radiology department at Tanta university hospitals. High grade vesicoureteric reflux "VUR" (grade IV & V) was detected in 70% of the cases. 42.8% of the cases had vesicoureteric reflux in both kidneys, 42.8% of the cases had VUR only on the left side and 14.2% of the cases had VUR on the right side. A statistical significance was found between grades of pyelonephritis and grades of vesico-ureteric reflux, so there was a strong association between high grade VUR and renal pyelonephritis. It was found that no significant difference was found as regard to the number of abnormal segments detected by static renal scintigraphy and SPECT imaging. Static renal scintigraphy is considered the gold standard for diagnosis of children with pyelonephritis and detection the risk of renal scarring due to recurrent infection. SPECT offers no statistically significant diagnostic advantage over static images for detection of cortical defects.

Keywords: Static Renal Scintigraphy, Pediatric Renal Pyelonephritis, Vesico-ureteric Reflux

1. Introduction

Urinary tract infections (UTIs) are common in infants and children affecting girls than boys and may result in serious complications, such as renal scarring, hypertension, and renal failure. Urinary tract infections are classified into lower tract and upper tract. UTI caused by ascending route (most common) and also through a hematogenous route. UTI can be caused by multiple organisms and gram-negative bacteria are most frequently identified. The *Escherichia coli* is the most common one [1, 2].

Renal pyelonephritis is diagnosed clinically in patients with a sudden onset of fever, flank pain, costo-vertebral angle tenderness, and microscopic evidence of urinary infection

[2].

The role of imaging in UTI is to detect children with a high risk for developing renal scarring, who need routinely screening and follow up [3].

Multiple imaging modalities like intravenous urography, ultrasound, computed tomography, and magnetic resonance imaging are used in diagnosis of UTI [4].

Dimercaptosuccinic acid (DMSA) is used as the radiopharmaceutical. Its cortical accumulation occurs only in functioning proximal tubule cells. After injection, DMSA is 90% protein bound and significantly accumulates in the cortex 2 hours after injection. Planar imaging is possible 2 to 4 hours after injection, while in patients with impaired renal function imaging may be delayed [5].

Many reports revealed the new advances in imaging

modalities that enabled faster acquisition compared in comparison with traditional methods. SPECT has the ability of acquiring data with appropriate image quality and decreased acquisition time and also of decrease radiation exposure. Acute pyelonephritis appears most often as a single or multifocal area of decreased uptake in the renal cortex without volume loss while chronic pyelonephritis cortical scar is usually associated with contraction and volume loss of the cortex [6, 7].

2. Patients and Methods

This prospective study included all patients who were suspected clinically to have renal pyelonephritis. Those patients referred to Radiology department at Mansoura urology and nephrology center and Radiology department at Tanta university hospitals from urology and nephrology department and outpatients from January 2019 to January 2020. This study included 50 patients with their age ranging from 1 month to 15 years. The study was approved from Research Ethical Committee.

2.1. Inclusion Criteria

Age group: pediatric age group.

Pediatrics with symptoms suggesting pyelonephritis e.g. (flank pain, high grade fever, leukocytosis, pyuria, positive urine culture).

Pediatrics with evidence of vesicoureteric reflux.

Recurrent urinary tract infection.

2.2. Exclusion Criteria

Adult age group.

2.3. Patients Were Subjected to the Following

2.3.1. Proper History Taking

Personal history, past history as regard having previous attack of urinary tract infection and reviewing the results of previous investigations including voiding cystourethrography, ultrasound, magnetic resonance urography and previous renal scan if present.

2.3.2. Clinical Examination

Including measurement of the patient's weight and height for proper estimation of injected dose of radionuclide.

2.3.3. Laboratory Investigation

Including renal function tests, urine analysis and urine culture.

2.3.4. Radiological Examination

Renal scintigraphy /single photon emission computed tomography.

2.4. Statistical Analysis

Statistical presentation and analysis of the present study was conducted, using the mean, standard deviation and chi-square test by SPSS V. 20. The used tests were: Chi-square

test, Monte Carlo correction, Linear correlation coefficient.

3. Results

All cases were subjected to voiding cystourethrogram. High grade vesicoureteric reflux VUR (grade IV & V) was detected in 35 out of 50 (70%) cases. 15 out of 50 (30%) cases showed no evidence of VUR. This will be demonstrated in table 1 and figure 1.

Table 1. Distribution of the studied cases according to vesicoureteric reflux (VUR).

Vesicoureteric reflux (VUR)	Number of patients	Percentage (%)
High grade VUR (grade IV & V)	35	70.0
Absence of VUR	15	30.0
Total number of cases	50	100

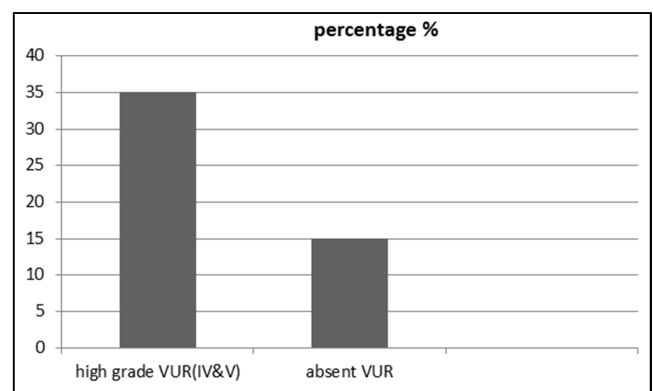


Figure 1. Distribution of the studied cases according to vesicoureteric reflux (VUR).

All cases were subjected to static renal scintigraphy to detect grade of pyelonephritis which based on uptake of radioactive tracer and number of cortical defects. Grade I pyelonephritis include decrease in radioactive tracer uptake or single cortical defect, grade II pyelonephritis include decrease in tracer uptake and single cortical defect and grade III pyelonephritis include two or more cortical defects. 6 out of 50 (12%) cases showed grade I pyelonephritis, 8 out of 50 (16%) cases showed grade II pyelonephritis and 36 out of 50 (72%) cases showed grade III pyelonephritis, as shown in table 2.

Table 2. Distribution of the studied cases according to the grade of pyelonephritis as shown on static renal scintigraphy.

Grade of pyelonephritis as shown on static renal scintigraphy	Number of patients	Percentage (%)
Grade I	6	12.0
Grade II	8	16.0
Grade III	36	72.0
Total number of patients	50	100

Three out of 6 (50%) cases who had grade I pyelonephritis as shown on static renal scintigraphy had high grade vesicoureteric reflux in voiding cystourethrogram. 7 out of 8 (87.5%) cases with grade II pyelonephritis and 25 out of 36 (69.4%) cases with grade III pyelonephritis had high grade

vesico-ureteric reflux. A statistical significance was found between grades of pyelonephritis and grades of vesico-ureteric reflux with ^{MC}p (<0.001), so there was a strong

association between high grade VUR and grade of renal pyelonephritis. This will be demonstrated in table 3.

Table 3. Correlation between pyelonephritis grades as shown on static renal scintigraphy and grade of vesico-ureteric reflux (VUR) as shown on voiding cystourethrogram.

	Pyelonephritis grades as shown on static renal scintigraphy						χ^2	^{MC} p
	Grade I (n= 6)		Grade II (n= 8)		Grade III (n= 36)			
	No.	%	No.	%	No.	%		
VUR								
High grade VUR (grade IV&V)	1	16.7	2	25.0	32	88.9	21.005	<0.001*
No VUR	5	83.3	6	75.0	4	11.1		

χ^2 : Chi square test; MC: Monte Carlo

P: p value for association between pyelonephritis grades as shown on static renal scintigraphy and grades of VUR

*: Statistically significant at $p \leq 0.05$

Twenty out of 50 cases (40 renal units) were subjected to single photon emission computed tomography (SPECT) for further evaluation of the cortical defect (s). Kidney was divided into three zones (upper, middle and lower). Zonal distribution of renal cortical defects in static renal scintigraphy and single photon emission tomography was done and linear correlation coefficient was calculated. Total number of cortical

defects detected on static renal scintigraphy in different renal segments on both kidneys was 77 while that detected by SPECT was 83. 89% of cortical defects with no significant difference was found as regard to number of affected segments detected by static renal scintigraphy and SPECT and linear correlation coefficient between them was ($r = 0.99$). This will be demonstrated in table 4 and figure 2.

Table 4. Zonal distribution of cortical defects in static renal scintigraphy and single photon emission tomography.

Renal segments	Numbers of scars detected on static renal scintigraphy	Numbers of scars detected on SPECT	Linear correlation Coefficient (r)
Left upper pole	23	25	0.99
Right upper pole	18	20	
Left lower pole	15	17	
Right lower pole	10	10	
Left mid zone	6	6	
Right mid zone	5	5	

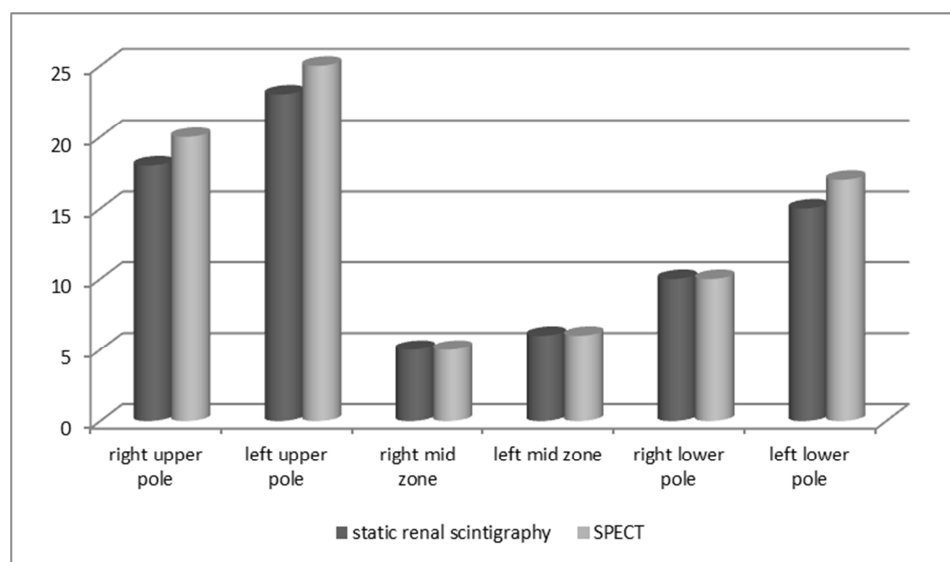
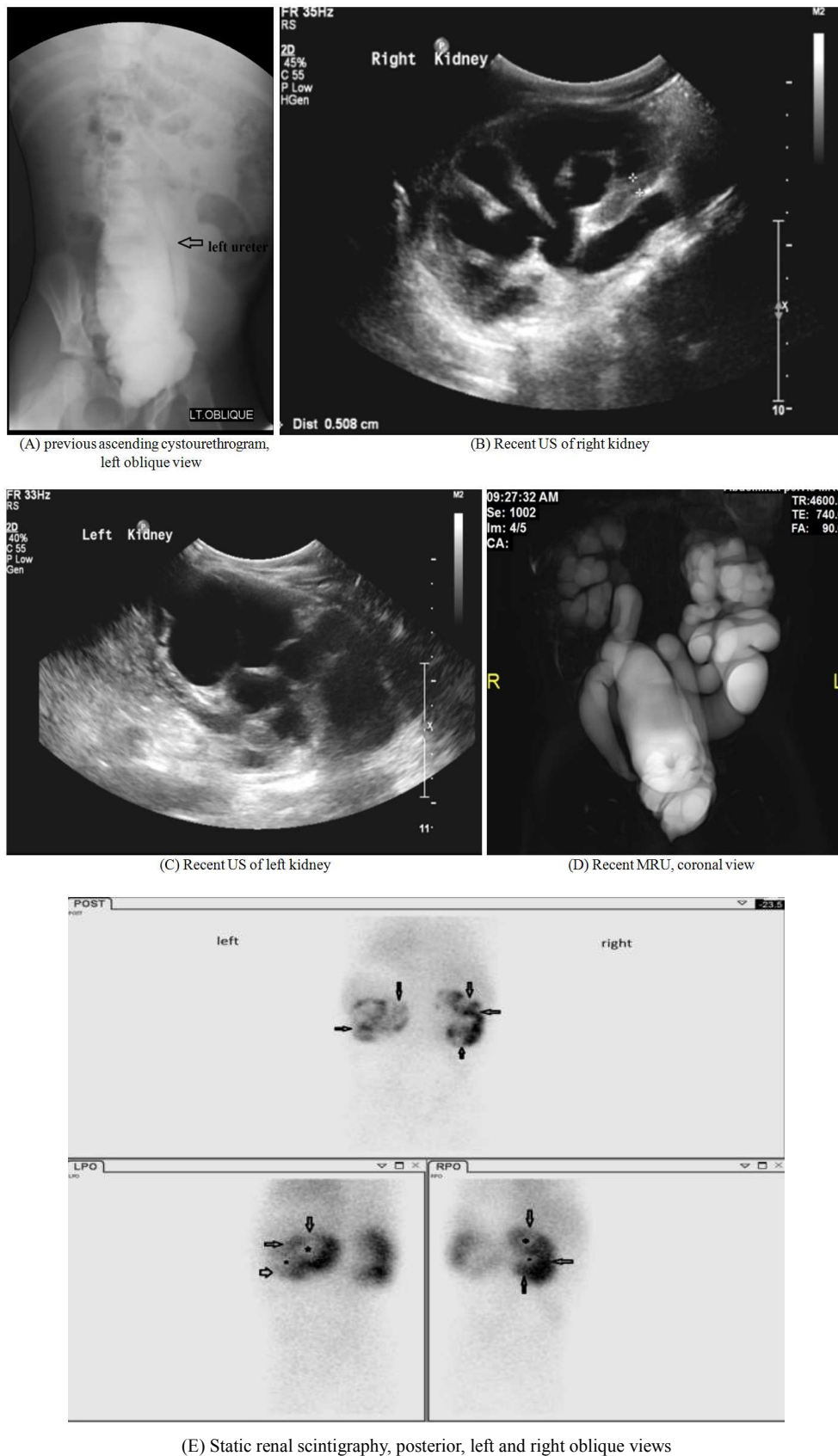


Figure 2. Segmental distribution of renal cortical defects in static renal scintigraphy and single photon emission tomography.

4. Cases

4.1. Case 1

A 7- year- old female child, presented clinically with bilateral loin pain, dysuria and fever. Creatinine level was high 1.1mg/dl (normal according to age up to 0.9mg/dl) and urine analysis was positive for leucocyte esterase test and urine culture revealed growth of *E. coli*.



(E) Static renal scintigraphy, posterior, left and right oblique views

Figure 3. Showed grade (III) VUR on the left side and a neurogenic bladder (A), bilateral marked dilatation of the pelvi-calyceal systems with thin parenchyma (B & C), in addition to dilatation and tortuosity of both ureters and a neurogenic bladder (D), bilateral decreased, non-homogenous radioactive tracer uptake (more on the left side), bilateral multiple cortical areas of photopenia (hollow arrows), medullary defects due to dilatation of the collecting systems (asterisks), and increased background activity, denoting chronic renal impairment (E).

Final diagnosis by static renal scintigraphy: Bilateral renal grade III pyelonephritis, bilateral marked hydronephrosis and chronic renal impairment.

4.2. Case 2

A 5- year- old female child, presented clinically with bilateral loin pain, fever and dysuria. Creatinine level was normal (0.8mg/dl) and urine analysis was positive for leucocyte esterase test.

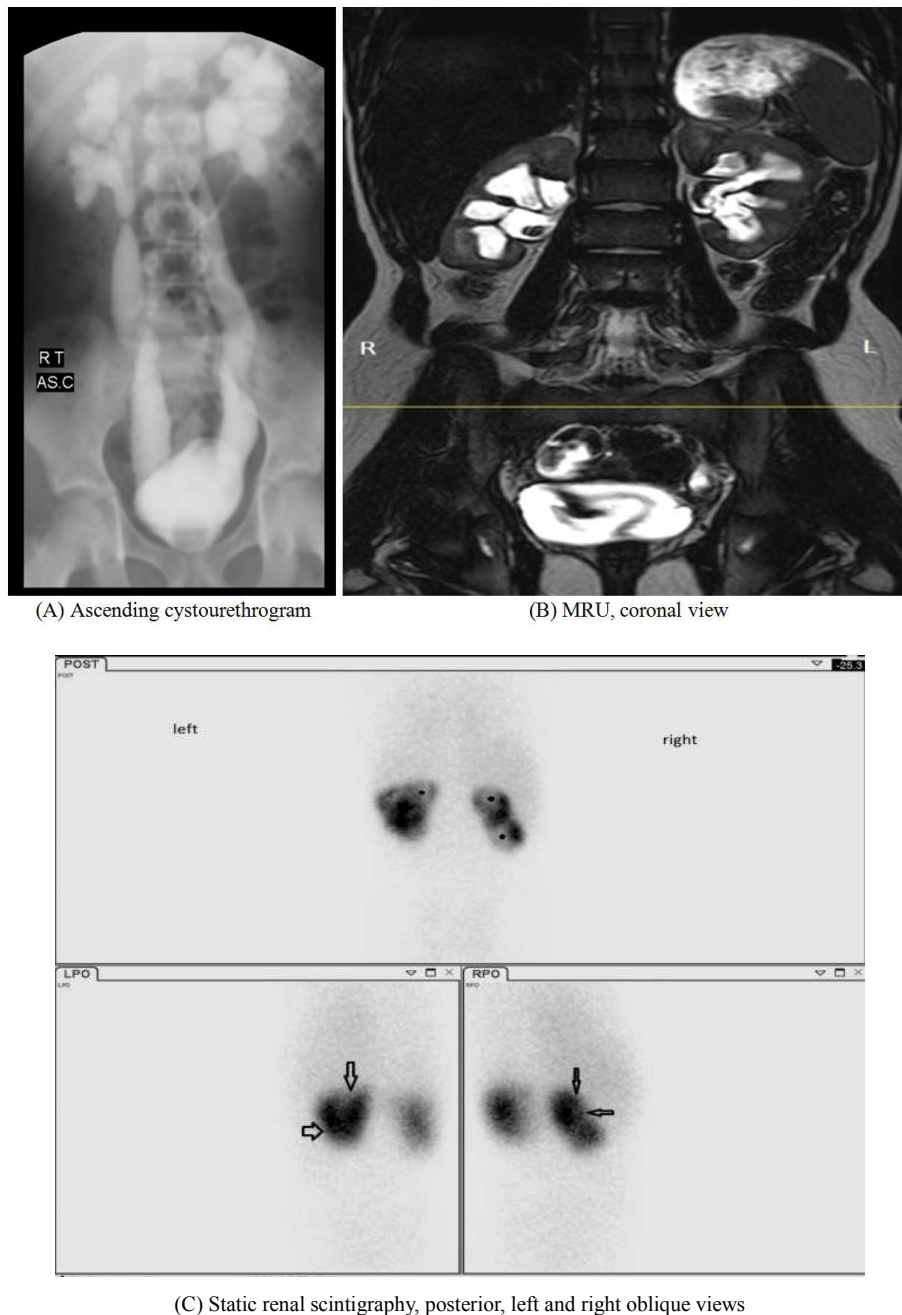


Figure 4. Showed bilateral grade (V) VUR (A), bilateral marked dilatation of the renal collecting systems (B), decreased the radioactive tracer uptake within the kidneys, with bilateral upper and mid zonal cortical photopenic areas (hollow arrows), and medullary photopenic areas, representing dilated collecting systems (asterisks) (C).

Final diagnosis by static renal scintigraphy: Grade III pyelonephritis of both kidneys with bilateral marked hydronephrosis.

4.3. Case 3

A 9- year-old female child, presented clinically with fever and bilateral loin pain. Creatinine level was normal (0.6mg/dl) and urine analysis was positive for leucocyte esterase test.

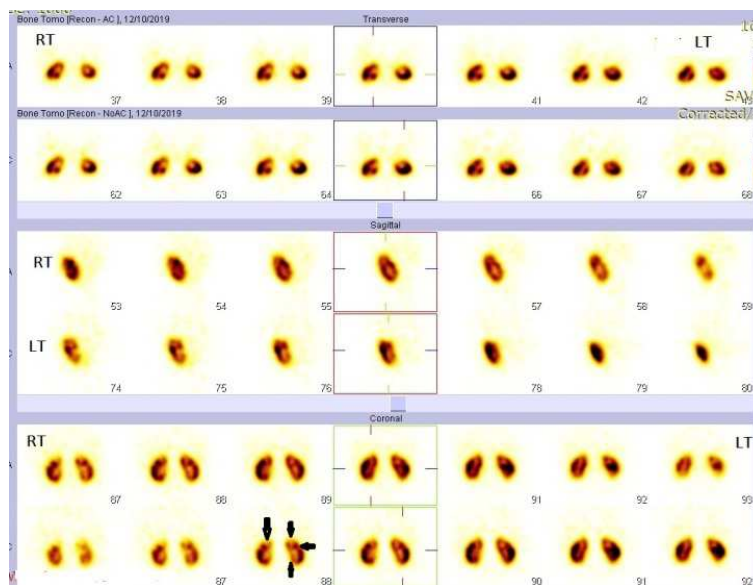
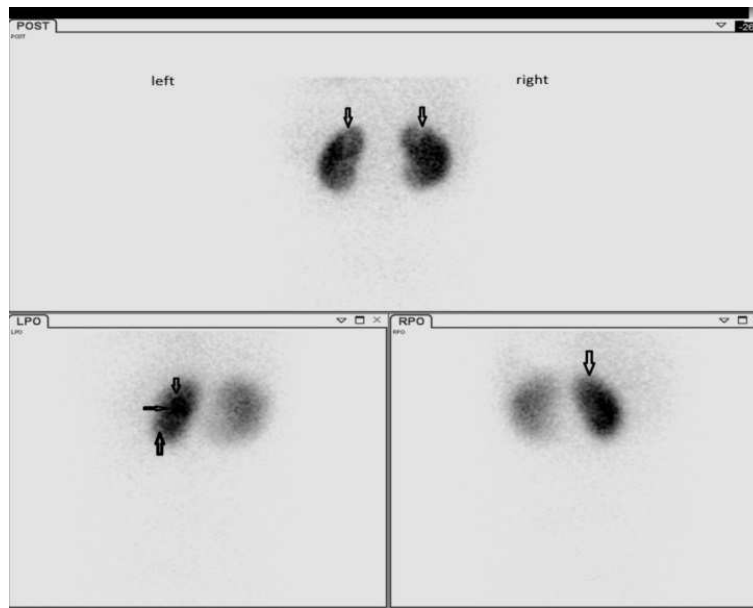
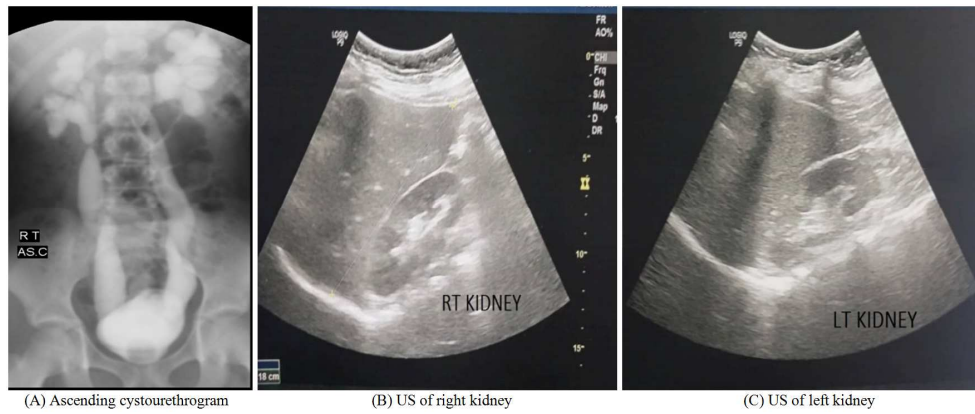


Figure 5. Showed bilateral renal grade (V) VUR (A), fullness of both renal collecting systems (B & C), decreased non-homogenous radioactive tracer uptake in the kidneys with bilateral upper polar and left mid and lower zone cortical defects (hollow arrows)(D), and no additional photopenic areas noted in the SPECT views (E).

Final diagnosis by static renal scintigraphy and SPECT: Grade II pyelonephritis of the right kidney and grade III pyelonephritis of the left kidney.

5. Discussion

Voiding cystourethrogram was done to assess grade of vesico-ureteric reflux (VUR). No reflux was detected in 15 out of 50 (30%) patients; high grade VUR (grade IV & V) was detected in 35 out of 50 (70%) patients. This agreed with *Snodgrass et al.* [8] who reported that high grade reflux (grade IV-V) is found in 339 out of 565 (60%) patients. Another study of *Ross et al.* [9] reported no reflux in 106 out of 200 (73.1%) patients and high grade reflux (grade IV & V) in 12 out of 200 (8.6%) patients. This discrepancy may be due to patient selection criteria.

In the present study, according to ultrasound and/or MRU findings, 14 out of 50 (28%) patients had atrophic changes, 18 out of 50 (36%) patients had mild to moderate hydronephrosis, 13 out of 50 (26%) patients had marked hydronephrosis and 5 out of 50 (10%) patients had both atrophic changes and hydronephrosis. This disagreed with *Kandur, et al* [10] who reported that 72 out of 148 (48.6%) patients had atrophic changes, 36 out of 148 (24.3%) patients had mild to moderate hydronephrosis, 30 out of 148 (20.3%) patients had marked hydronephrosis and 10 out of 148 (6.8%) patients had both atrophic changes and hydronephrosis. This disagreement may be attributed to difference in number of patients included in the studies.

Static renal scintigraphy was done. It was found that 6 out of 50 (12%) patients had grade I pyelonephritis on static renal scintigraphy, 8 out of 50 (16%) patients had grade II pyelonephritis and 36 out of 50 (72%) patients had grade III pyelonephritis. This agreed with *Tseng et al.* [11] who reported that 20 out of 142 (14.1%) patients had grade I pyelonephritis, 30 out of 142 (21.1%) patients had grade II pyelonephritis and 92 out of 142 (64.8%) patients had grade III pyelonephritis. Another study of *Cerwinka et al.* [12] found that 9 out of 25 (36%) patients had grade I pyelonephritis in static renal scintigraphy, 4 out of 25 (16%) patients had grade II pyelonephritis, 6 out of 25 (24%) patients had grade III pyelonephritis and 6 out of 25 (24%) patients had normal kidneys. This discrepancy may be due to the age range of both studies, the age range of the current study was 0.08-15 years while the age range of the other study was 0.25-143 months.

Correlation between pyelonephritis grades as shown on static renal scintigraphy and grade of vesico-ureteric reflux (VUR) in voiding cystourethrogram was done in this study. A statistical significance was found between grades of pyelonephritis and grades of vesico-ureteric reflux with ^{MC}p (<0.001), so increasing grade of VUR is associated with increase in the grade of pyelonephritis. This agreed with *Zhang et al.* [13] who high VUR group with ^{MC}p (<0.01) on their study carried on 523 patients.

In the current study, zonal distribution of renal cortical

defects detected on static renal scintigraphy and single photon emission tomography was studied in 20 out of 50 cases (40 renal units), no significant changes in the number of abnormal segments detected by planar and SPECT. Total number of cortical defects detected on static renal scintigraphy in different renal segments on both kidneys was 77 while that detected by SPECT was 83, 89% of cortical defects. Linear correlation coefficient between static and SPECT images was high ($r = 0.99$). This agreed with *Farghaly et al.* [14] whose study carried on 190 cases (380 renal units) and found that total number of cortical defects detected on static renal scintigraphy in different renal segments on both kidneys was 220 while that detected by SPECT was 225 with linear correlation coefficient ($r = 0.91 - 0.92$). The mismatching between static and SPECT images may return to renal impairment, high background activity or very small scars. Another study by *Kim et al.*, [15] who found that SPECT images offered statistically significant value over static renal scintigraphy for detection of cortical defects, SPECT images found more lesions in kidneys by 21% than static images.

6. Conclusion

Static renal scintigraphy is considered the gold standard for diagnosis of children with pyelonephritis and detection the risk of renal scarring due to recurrent infection. SPECT offers no statistically significant diagnostic advantage over static images for detection of cortical defects. The clinical presentation and laboratory investigations of renal pyelonephritis are non-specific.

References

- [1] Spasojević-Dimitrijeva B, Živkovi M, Stanković A, et al: The IL-6 -174G/C polymorphism and renal scarring in children with first acute pyelonephritis. *Pediatric Nephrology*. 2010; 25: 2099-2106.
- [2] Conway PH, Cnaan A, Zaoutis T, et al: Recurrent urinary tract infections in children: risk factors and association with prophylactic antimicrobials. *JAMA*. 2007; 298: 179-86.
- [3] Coulthard MG. Is reflux nephropathy preventable, and will the NICE childhood UTI guidelines help? *Archives of Diseases in Childhood*. 2008; 93: 196-209.
- [4] Nikolaidis P, Dogra VS, Goldfarb S, et al: ACR Appropriateness Criteria: Acute Pyelonephritis. *Journal of the American College of Radiology*. 2018; 15: 5232-5239.
- [5] Mandell GA, Egli DF, Gilday DL, et al: Society of Nuclear Medicine procedure guideline for renal cortical scintigraphy in children. *SNM Procedure Guidelines Manual* 2003; 24: 195-198.
- [6] Sheehy N, Tetraault TA, Zurakowski D, et al: Pediatric 99mTc-DMSA SPECT performed by using iterative reconstruction with isotropic resolution recovery: improved image quality and reduced radiopharmaceutical activity. *Radiology*. 2009; 251: 511-516.

- [7] Tsalkidis A, Gardikis S, Kambouri K, et al: (99m) Tc-DMSA scintigraphy diagnosing crossed renal ectopia with fusion in a three years old boy. *Hell Journal of Nuclear Medicine*. 2011; 14: 300-303.
- [8] Snodgrass WT, Shah A, Yang M, et al: Prevalence and risk factors for renal scars in children with febrile UTI and/or VUR: A cross-sectional observational study of 565 consecutive patients. *Journal of Pediatric Urology*. 2013; 9: 856-866.
- [9] Ross I, Jun Ahn H, Roelof B, et al: Sonographic assessment of the effect of vesicoureteral reflux and urinary tract infections on growth of the pediatric solitary kidney. *Journal of Pediatric Urology*. 2015; 11: 145. e2-145. e6.
- [10] Kandur Y., Salan A., Tuten F.: Correlation of ultrasonographical findings of hydronephrosis/ atrophy with 99m technetium-dimercaptosuccinic acid in childhood: A single-center experience from Turkey. *Urology annuals*. 2018; 10: 296-301.
- [11] Tseng M, Lin W, Lo W, et al: Does a normal DMSA obviate the performance of voiding cystourethrography in evaluation of young children after their first urinary tract infection?. *The Journal of Pediatrics*. 2007; 150: 96-109.
- [12] Cerwinka WH, Grattan-Smith JD, Jones RA, et al: Comparison of magnetic resonance urography to dimercaptosuccinic acid scan for the identification of renal parenchyma defects in children with vesicoureteral reflux. *Journal of Pediatric Urology*. 2014; 10: 344-351.
- [13] Zhang X, Xu H, Zhou L, et al: Accuracy of early DMSA scan for VUR in young children with febrile UTI. *Pediatrics*. 2014; 133: e30-e38.
- [14] Wein AJ, Kavoussi LR, Partin AW, et al: Pediatric urological imaging. In Martin AD., Pohl HG. *Campbell-Walsh urology* 11th edition. Elsevier. 2016; 126: 2909-2925.
- [15] Kim JE, Kim JS, Han JB, et al: Clinical usefulness of ^{99m}Tc-DMSA renal SPECT using high sensitivity-all-purpose collimator for pediatric patients. *JKCA*. 2014; 16:220-231.