

# The Pelvic Inlet and Outlet Radiographic View in Filipinos: A Retrospective Study of CT Scan Measurements and 3-Dimensional Computed Tomography Reconstructions

John Ricardo Buenacosa Chua, Joshua De Castro Unsay

Department of Orthopaedics, East Avenue Medical Center, Quezon City, Philippines

## Email address:

rick\_chua\_17@yahoo.com (J. R. B. Chua)

## To cite this article:

John Ricardo Buenacosa Chua, Joshua De Castro Unsay. The Pelvic Inlet and Outlet Radiographic View in Filipinos: A Retrospective Study of CT Scan Measurements and 3-Dimensional Computed Tomography Reconstructions. *International Journal of Medical Imaging*. Vol. 10, No. 2, 2022, pp. 16-21. doi: 10.11648/j.ijmi.20221002.12

**Received:** April 29, 2022; **Accepted:** May 12, 2022; **Published:** May 19, 2022

---

**Abstract:** Injuries to the pelvic ring pose a significant challenge requiring urgent multidisciplinary management. Adequate radiological evaluation is essential in assessing these injuries. The standard radiologic evaluation of the pelvis includes an AP, inlet, and outlet view. The inlet and outlet view are classically taught to be orthogonally taken with a 45-degree angulation from the anteroposterior plane. However, there is growing evidence that there is a significant individual variation within the population and these values need to be re-analyzed. This is a retrospective study done in a level I trauma center. A total of 110 patients (62 males and 48 females) older than 18, who had clinically indicated Computed Tomography (CT) scan done without any pelvic pathologies were included. A 3D Multiplanar reconstruction (MPR) and 3D reconstruction CT scans were derived from the DICOM images and various methods were used to analyze the ideal angulations based on the 2-Dimensional and 3-Dimensional images rendered. Mean and standard deviation were calculated for each angle measured with a comparison between gender and presence or absence of dysmorphic sacra. A correlational analysis was then done comparing the angles obtained on the sagittal CT scan from the 3D MPR and the ideal inlet and outlet angle from the 3D reconstructed images. The mean caudal angulation for the inlet view was  $31.448 \pm 7.25^\circ$  with no significant difference for the normal and dysmorphic sacrum and the mean cephalad angulation for screening for the ideal outlet view was  $38.39 \pm 6.96^\circ$  with individuals with dysmorphic sacra having an angulation  $5^\circ$  more than the normal group. The study re-evaluated the ideal screening inlet and outlet angulations in the Filipino population which demonstrated a mean of  $31^\circ$  of caudal angulation for the inlet view and a mean of  $38^\circ$  of cephalad angulation on outlet views.

**Keywords:** Pelvis, Pelvic Fracture, Inlet Angle, Outlet Angle, CT Scan 3D Reconstruction

---

## 1. Introduction

The pelvic ring is an osteo-ligamentous complex with the primary role of transmitting forces from the lower extremities to the axial skeleton. However, the bones themselves (the two innominate bones and the sacrum) confer little actual stability; instead, it is the ligamentous structures – the sacroiliac ligaments, the pubic symphysis and, to much lesser degrees, the sacrospinous, sacrotuberous, and iliolumbar ligaments that bear the critical role of making the pelvic ring one of the strongest osteo-ligamentous constructs in the human body [1].

Injuries to the pelvic ring are devastating, with high

morbidity and mortality brought about by this complex anatomy and biomechanics. The injuries themselves tend to be complex, as well. As such, proper evaluation of these injuries – via conventional radiographs and computed tomography (CT) scans – are essential for proper treatment planning [2, 3].

There are vast differences reported in the literature with regards to the angles to properly take accurate pelvis inlet and outlet views [4–6]. What is classically taught is a  $45^\circ$  caudal and cranial angulation for inlet and outlet views, respectively. Within the population there is a significant individual variation thus, these values need to be defined [7, 8]. Inadequate x-rays are usually the result of these frequent anatomical variations.

CT scans are a reliable way of assessing pelvic injuries, reaching 100% sensitivity in detecting and characterizing pelvic injuries [9]. Furthermore, studies have shown that measurements of anatomic structures using CT scan images fall within 0.3 mm of that structures' actual size in-situ. Because of this, CT scans have become the preferred method of assessing pelvic injuries [10]. A pre-operative sagittal CT reconstruction used in pre-operative planning of anticipating fluoroscopic inlet and outlet views are within 5° of variation [11].

Literature suggests that there are considerable variations and differences in the anatomy of the pelvis based on race and ethnicity [12-14]. Inclusion of the Filipino/Southeast Asian profile in these studies have not been attempted [6, 15, 16].

The purpose of this study is to define the ideal angulations for the inlet and outlet view for the Filipino population and to find out if there is a difference between the ideal angulations of these pelvic radiographs in the Filipino population compared to the studies published in prior papers for the American and Indian populations based on the study Peckmeszi, Ricci and Kurkura, respectively [6, 15, 16] using the data collection techniques used in these studies.

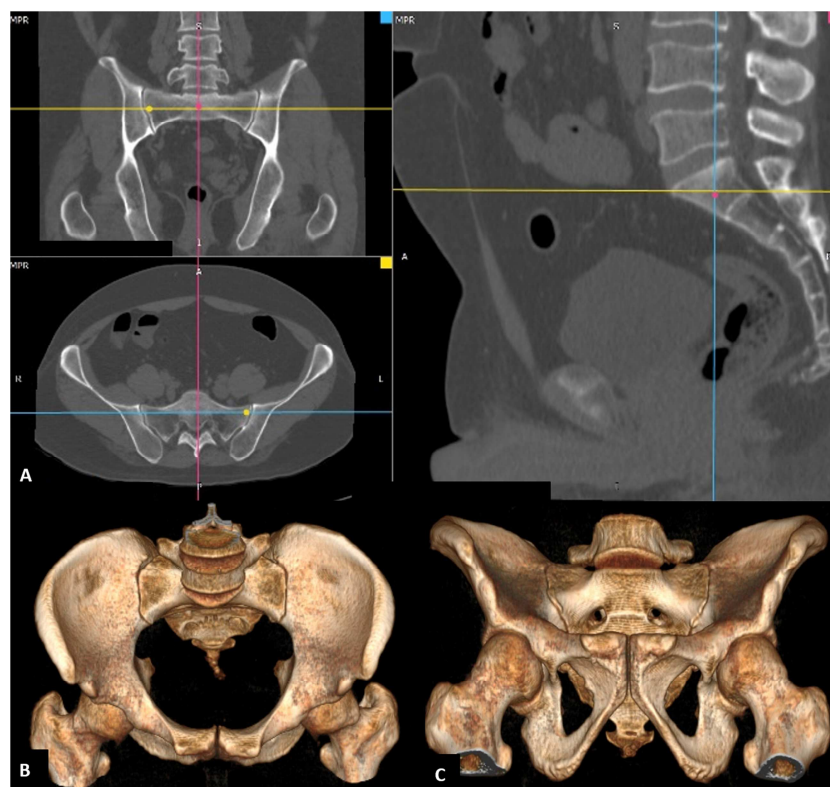
Another purpose of this study is to state the incidence of sacral dysmorphism among the Filipino population and to evaluate if there is a difference in beam angulation in obtaining the ideal inlet and outlet views as compared to the normal population.

The significance of the results of this study is for the benefit of hospitals and health care institutions without a CT scan, that with obtaining the average angulations for the

Filipino populations there would be less radiation exposure from repeated x-rays for taking the ideal view from the optimal angulation of the beam for the inlet and outlet views.

## 2. Materials and Methods

This retrospective study was carried out in a level 1 trauma center in the Philippines. The study included 110 patients (62 males and 48 females), all of legal age, with clinically indicated abdominal and pelvic CT scans, but without pelvic ring and acetabulum injuries from January 2021 to September 2021. All studies were performed with a Philips Brilliance 64 CT Scan Machine (Koninklijke Philips N. V. Connected Care, and Diagnosis & Treatment, Amsterdam, Netherlands). CT DICOM (Digital Imaging and Communications in Medicine, a standard, internationally accepted format to view, store, retrieve and share medical images) files were extracted and loaded onto a 3<sup>rd</sup> party software: RadiANT DICOM Viewer 2020.2.3 (64-bit) (Medixant, Poznan, Poland) where a 3D Multiplanar reconstruction (MPR) and a 3D reconstruction of the images were also done (Figure 1). The 3D MPR allows us to navigate these images on all planes (axial, coronal, and sagittal). The 3D reconstruction is a volume rendering of the Pelvis where the bones appear solid. The study used techniques derived from Pekmezci [6] for the 3D reconstruction inlet and outlet views and Ricci [15] for the sagittal CT measurements for obtaining the ideal inlet view and has employed a new technique in obtaining the ideal outlet view, based on the definition [6, 15].

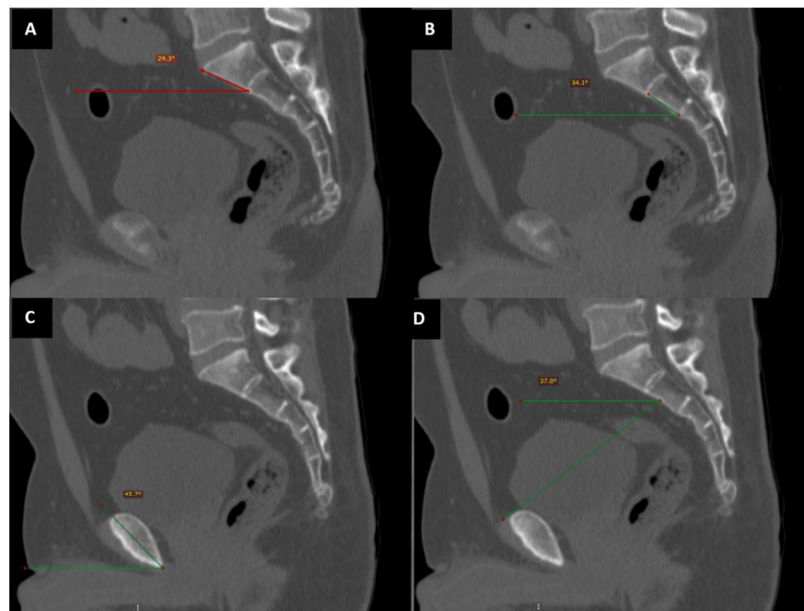


**Figure 1.** (A) 3D multi-planar reconstruction (MPR) demonstrates the apical, sagittal, and coronal CT in all planes (B) Inlet view on 3D reconstruction of the pelvis. (C) Outlet view on 3D reconstruction of the pelvis.

With the 3D reconstruction, images can be rotated in all planes of motion, with the starting point at 0° is assumed to be the position of the patient supine where AP radiographs are taken. These images were rotated 1 degree at a time in the sagittal plane to assess for the ideal screening inlet and outlet views. The ideal inlet view is defined where the sacral promontory is overlapped on the anterior aspect of the body of S1 and forms a dense cortical line [17–21]. The ideal outlet view is defined as a view where the pubic tubercles are just inferior to the S1 foramina, and the pubic symphysis is superimposed over the body of S2 [17–21].

Our study used the 3D MPR (Figure 1) to obtain a centralized sagittal view directly taken midline where the vertebral process is in line with the symphysis pubis. For the inlet angle, 3 methods based on the previous studies of Ricci and Karkhura were used utilizing perfectly centered sagittal

cuts on 3D MPR CT slices [15, 16]. For AS1 a line is drawn from the anterior cortical margin of S1 and is angled with a line drawn in the AP plane, the same is done for AS2 but this time it's drawn on the anterior cortex of S2. The third method evaluates the anterior aspect of the pelvis, because of the midline sacral cartilage, sagittal reconstruction CT slices are taken 1 cm lateral from the midline in each direction (Figure 2). The angle between the AP plane and these lines represents the amount of the caudal angulation of the inlet angle required to optimally profile these structures. The outlet angle is measured by a line that is tangent to the superior aspect of the pubic ramus (on either side) directed to the midline of the body of the S2 vertebra. Pearson's correlation coefficient was used to analyze data between sagittal CT-based angulations and the angulations taken from the 3D reconstructed CT scan for inlet and outlet views.



\*all lines in the AP plane are perpendicular to the table.

**Figure 2.** Sagittal CT cuts obtained with 3D MPR showing the measurements used to derive angulations for inlet and outlet views. (A) Method 1: line is drawn anterior to the cortex of S1 and angled to a line drawn in the AP plane. (B) Method 2: line is drawn anterior to the cortex of S2 and angled to a line drawn in the AP plane. (C) Method 3: a line bisects the bone adjacent to the pubic symphysis and another line in the AP plane. For the outlet view the method used is: (D) A line that is tangent to the superior surface of the pubic ramus directed to the midline of the S2 vertebra and is angled with a line in the AP plane.

### 3. Results

The CT scans of 48 women and 62 men were included in

this study. Their ages ranged from 18-76 years with a mean of 47 years. Forty-seven out of the 110 (42.7%) were noted to have dysmorphic sacra fulfilling any of the following [21, 22].

**Table 1.** Difference Between Dysmorphic and Normal Sacrum.

	Dysmorphic Sacrum	Normal
Upper Sacrum (Outlet view)	Collinear with the Iliac Crest	Caudal relative to the Iliac Crest
Sacral Ala	Obliquely shaped (pointing medially and cephalad)	Flat
Mammillary Processes	Present	Absent
First anterior sacral neural foramina	Larger, noncircular, misshapen, and Irregular	Uniform circular
Residual disk space between S1 and S2 (Outlet view or sagittal CT)	Present	Absent
Alar Slope (Outlet view)	More acute/steep	Less acute/steep
Tongue in groove sacroiliac articulation (Axial CT)	Present	Absent
Anterior cortical indentation (Inlet view)	Present	Absent

The remaining 63 out of 110 (57.3%) patients were within normal limits for pelvic morphology. The mean caudal angulation for screening for the ideal inlet view using 3D reconstruction images was  $31.448 \pm 7.25^\circ$  with no significant difference between normal and dysmorphic sacra in the ideal screening inlet angle ( $P=0.086$ ) [22-24].

The mean cephalad angulation for screening for the ideal outlet view using 3D reconstruction images was  $38.39 \pm 6.96^\circ$ . There was a significant difference in the values between dysmorphic sacra and non-dysmorphic individuals with a mean of  $41.09 \pm 7.3$  for the dysmorphic group and  $36.38 \pm 6$  for the non-dysmorphic group ( $P=0.0005$ ) having a difference of  $5^\circ$ .

Sagittal evaluations of the imaging of the pelvis for the inlet view using the anterior bodies of S1 and S2 had an average of  $24.6 \pm 9.4^\circ$  (4.6-60.9) and  $36.61 \pm 8.35^\circ$  (14.6-

65.7) respectively. The PR had an average of  $43.07 \pm 6.93^\circ$  (29-59.3). The average outlet angle which is defined by a line tangential to pubis symphysis directed to the body of S2 had an average of  $38.23 \pm 7.01^\circ$  (20.9-55.5).

Pearson's correlation coefficient showed poor correlation with AS1 to ideal inlet angulations based on 3D reconstruction images with an  $r=0.08$ . A moderate but still not ideal correlation with AS2 at  $r=0.52$ . a weak correlation with PR at  $r=0.33$  but showed a strong correlation for the average of AS1 and AS2 with  $r=0.82$  with a moderate correlation when PR average with the previous 2 variables (AS1 and AS2) with  $r=0.79$ .

For the ideal outlet angulation, the line tangent to the upper border of the pubic symphysis directed to the body of S2 had a very strong correlation to the ideal outlet angulation with  $r=0.93$ .

Table 2. Inlet Angle.

	Average (Pekmezci/Ricci /Karkhura)	SD (Pekmezci/Ricci /Karkhura)	Minimum (Pekmezci/Ricci et al.)*	Maximum (Pekmezci/Ricci et al.)*	95% CI (Pekmezci/Ricci et al.)*	Correlation with 3D recon images
Anterior to S1 (AS1)	25 (21/21/26)	9 (9/9)	5 (3/2)	61 (42/41)	22-26 (18-23/19-23)	0.09
Anterior to S2 (AS2)	36 (31/29/33)	8 (8/8)	14 (3/14)	66 (45/54)	35-38 (29-33/27-31)	0.52
PR	43 (37/36/41)	6 (6/6)	29 (18/23)	59 (51/47)	42-44 (36-38/35-38)	0.33
3D Inlet**	31 (24)	7 (8)	18.1 (8)	56 (43)	30-32 (22-26)	
Average of AS1 and AS2	31	7	17	57	29-32	0.82
Average of AS1, AS2, and PR***	35 (33)	5 (8)	22 (16)	57 (31)	34-36	0.79

Table 3. Outlet Angle.

	Average (Pekmezci/Ricci /Karkhura)	SD (Pekmezci/Ricci /Karkhura)	Minimum (Pekmezci/Ricci /Karkhura)*	Maximum (Pekmezci/Ricci /Karkhura)*	95% CI (Pekmezci/Ricci /Karkhura)*	Correlation with 3D recon images
Centered at the Body of S2****	38 (57/56)	7 (7/9)	21 (42/52)	56 (73/82)	37-40 (55-58)	0.93
3D Outlet**	38 (44)	7 (6)	21 (32)	57 (70)	37-40	

\*Minimum, maximum and Confidence interval not presented in the study of Karkhura et al.

\*\*Values in the 3D inlet and outlet CT scan reconstructions were only compared to the study by Pekmezci et al. data is not available for the study by Ricci et al.

\*\*\*Values compared to the study by Karkhura et al.

\*\*\*\*Values in Centered at the body of S2 are only compared to the study of Karkhura et al.

## 4. Discussion

Traditionally, well-taken Roentgenograms of the pelvis and acetabulum were required for the challenging task of evaluating pelvic and acetabulum fractures. The inlet view evaluates the abduction/adduction and anterior/posterior displacement of the pelvic ring. The outlet view evaluates vertical displacement and flexion/extension deformity of the pelvic ring. These views are usually obtained with the patient supine with the beam in the AP projection directed  $45^\circ$  caudad in the inlet view and  $45^\circ$  cephalad for the outlet view in the classic teaching [1, 17, 18, 21]. Many studies have updated this since [6, 15, 16].

Even with the advent of high-resolution CT-Scans as the preferred tools for evaluation of pelvic fractures, well-taken inlet and outlet views are still an essential part of their management. "Classic" inlet and outlet views are used extensively with C-arms during the intra-operative

evaluation of reduction, fixation, and implant placement. And in low-resource centers without ready access to CT-Scans, well-taken inlet and outlet views are usually the only tool available to properly assess and treat pelvic injuries. Inadequate x-rays would sometimes lead to missed injuries or a repeat of these radiographs exposing the patient to more radiation, causing delay, and incurring additional costs.

Pelvic incidence is defined as the angle between a line from the S1 endplate to the center of the femoral heads and a line perpendicular to the S1 endplate. These values range from  $30$  to  $80^\circ$  and are related to lumbar lordosis that affects the sacral slope [6, 25]. Pelvic tilt has a wide range and is specific for each patient. Therefore, the ideal inlet and outlet angulation are individualized for each patient. Which has proven to be obtained with a CT scan 3D reconstruction image as mentioned by Pekmeszi which can be rotated as 1-degree intervals, which was also used in this study. However it was also mentioned that not everyone would have the

software or a CT scan available, therefore it is still essential to describe adequate inlet and outlet angulations within the population used in screening radiographs [6].

Ricci et al. (15) recommended using 25° and 60° for the inlet and outlet views based on his study derived from the data of CT scans from normal subjects. In another study done by Pekmezci et al. [6] where they used 3D reconstruction imaging to obtain the ideal inlet view and compared it the previous study by Ricci of which they had the same recommendations with regards to the inlet view with 25° but recommended 45° for the outlet view stating that a 60° may be the ideal view for the true AP of the sacrum but it does not take into account the overlap of the anterior pelvis in that view.

In this study, the optimum angulation for obtaining ideal Inlet views is 31° and ideal outlet views 38° which is varied and is in line with the previous studies that inlet and outlet view are not orthogonal, which is also true in Filipinos, owing to a difference in pelvic anatomy between race and ethnicity [12-14]. Having no significant difference with dysmorphic and normal sacrum with regards to the inlet view and a 5° additional angulation for the outlet views for the dysmorphic sacra. The small sample size of this study also may have skewed some findings, such as the rather high proportion of patients - 47 out of 110 (42.7%) - that fall under the classification of "dysmorphic sacrum". Further investigation of this finding may be warranted, as it either indicates that many Filipinos have dysmorphic sacra, albeit clinically asymptomatic, or that the criteria for dysmorphism may need to be adjusted for certain ethnicities or populations. There is a lot of inter-observer differences in evaluating these owing to other studies under-reporting its incidence [22, 24, 26]. There was no significant difference with regards to the angulations between males and females which is consistent with other studies done [16].

The average angulation on sagittal CT for AS1 and AS2 appears to suggest a strong correlation for the ideal inlet view in our study and sagittal CT for centered on the body of the S2 vertebra for ideal outlet views suggesting a very strong correlation for ideal outlet views which may be useful for pre-operative evaluation for ideal inlet views. This would also be helpful in institutions without a CT scan as a lateral view of the pelvis could be a substitute in obtaining ideal screening angulations for inlet and outlet views of the pelvis. Obtaining ideal screening angulations would also lessen the time for repeated x-rays for the ideal inlet and outlet views both in the emergency and OR setting in institutions where CT scans are not available. Intra-operatively, positioning the C-arm using these measurements instead of the traditionally taught 45 degrees may significantly reduce OR time and radiation exposure.

There are some limitations to this study, the sample size is limited, which the variability within the population might be misrepresented. Another limitation is that this was taken by a single observer. All data taken are from non-injured pelvises taken in the supine position of which these positions might change especially in posterior pelvic fixations done in a prone or lateral position.

## 5. Conclusion

This study re-evaluated optimal inlet and outlet screening x-rays for the Filipino population which is 31° caudal angulation in the inlet view and 38° of cephalad angulation in the outlet view. There is a high incidence of sacral dysmorphism based on the study population comprising 42.7% of the study population. Inlet angulation of 31° caudal is the same for both normal and dysmorphic sacra. For the outlet angulation a 5° difference was seen with the higher recommended beam angulation of 41° for the sacral dysmorphism group and 36° for the normal group.

There is a significant difference in the comparison between ideal angulations for the Filipino population as compared to the American and Indian populations.

## Conflict of Interest

The authors declare that they have no conflicts of interest pertaining to this study.

## References

- [1] Buckley RE, Moran CG, Apivatthakakul T. AO Principles of Fracture Management Third Edition. 3rd ed. Davos Platz, Switzerland; 2017.
- [2] Tile M. Acute Pelvic Fractures: I. Causation and Classification. *Journal of the American Academy of Orthopaedic Surgeons*. 1996; 4 (3): 143–51.
- [3] Tile M. Acute Pelvic Fractures: II. Principles of Management. *Journal of the American Academy of Orthopaedic Surgeons*. 1996; 4 (3): 152–61.
- [4] McAndrew CM, Merriman DJ, Gardner MJ, Ricci WM. Standardized posterior pelvic imaging: Use of CT inlet and CT outlet for evaluation and management of pelvic ring injuries. *Journal of Orthopaedic Trauma*. 2014; 28 (12): 665–73.
- [5] Khurana B, Sheehan SE, Sodickson AD, Weaver MJ. Pelvic ring fractures: What the orthopedic surgeon wants to know. *Radiographics*. 2014; 34 (5): 1317–33.
- [6] Pekmezci M, Rotter P, Toogood P, Morshed S, Kandemir U. Reexamination of pelvic inlet and outlet images using 3-dimensional computed tomography reconstructions. *Journal of Orthopaedic Trauma*. 2014; 28 (6): 324–9.
- [7] Gusic N, Grgorinic I, Fedel I, Lemac D, Bukvic N, Gusic M, et al. Fluoroscopic iliosacral screw placement made safe. *Injury*. 2017; 48 (November): S70–2.
- [8] Ziran BH, Wasan AD, Marks DM, Olson SA, Chapman MW. Fluoroscopic imaging guides of the posterior pelvis pertaining to iliosacral screw placement. *Journal of Trauma - Injury, Infection and Critical Care*. 2007 Feb; 62 (2): 347–56.
- [9] Berg EE, Chebuhar C, Bell RM. Pelvic trauma imaging: a blinded comparison of computed tomography and roentgenograms. *The Journal of trauma* [Internet]. 1996 Dec [cited 2021 Nov 13]; 41 (6): 994–8. Available from: <https://pubmed.ncbi.nlm.nih.gov/8970552/>

- [10] Kim G, Jung HJ, Lee HJ, Lee JS, Koo S, Chang SH. Accuracy and reliability of length measurements on three-dimensional computed tomography using open-source osirix software. Vol. 25, *Journal of Digital Imaging*. 2012. p. 486–91.
- [11] Eastman JG, Chip Routt ML. Correlating preoperative imaging with intraoperative fluoroscopy in iliosacral screw placement. Vol. 16, *Journal of Orthopaedics and Traumatology*. 2015. p. 309–16.
- [12] Hoyte L, Thomas J, Foster RT, Shott S, Jakab M, Weidner AC. Racial differences in pelvic morphology among asymptomatic nulliparous women as seen on three-dimensional magnetic resonance images. *American Journal of Obstetrics and Gynecology*. 2005; 193 (6): 2035–40.
- [13] Handa VL, Lockhart ME, Fielding JR, Bradley CS, Brubaker L, Cundiff GW, et al. Racial differences in pelvic anatomy by magnetic resonance imaging. *Obstetrics and Gynecology*. 2008; 111 (4): 914–20.
- [14] Becker I, Woodley SJ, Stringer MD. The adult human pubic symphysis: A systematic review. *Journal of Anatomy*. 2010; 217 (5): 475–87.
- [15] Ricci WM, Mamczak C, Tynan M, Streubel P, Gardner M. Pelvic inlet and outlet radiographs redefined. *Journal of Bone and Joint Surgery - Series A*. 2010; 92 (10): 1947–53.
- [16] Yugal Karkhura. Radiological evaluation of pelvic inlet and outlet radiographic view in the indian population.pdf. *Journal of Clinical Orthopaedics and Trauma*. 2018. p. 334–7.
- [17] Browner BD, Jupiter JB, Krettek C. *SKELETAL TRAUMA: BASIC SCIENCES, MANAGEMENT, AND RECONSTRUCTION*, SIXTH EDITION. 2020. 1108–1195.
- [18] Chapman MW, James MA. *Chapman's Comprehensive ORTHOPAEDIC SURGERY* 4th Edition. 4th ed. New Delhi, India: Jaypee Brothers Medical Publishers (P) Ltd; 2019.
- [19] Tile M, Pennal GF. Pelvic disruption: principles of management. *Clinical Orthopaedics and Related Research*. 1980 Sep; (151): 56–64.
- [20] Pekmezci M, Kandemir U, Toogood P, Morshed S, Francisco S. Are conventional inlet and outlet radiographs obsolete in the evaluation of pelvis fractures? 2013.
- [21] Court-Brown C. *Rockwood fractures*. Eighth edi. Rockwood CA, Bucholz RW *Fractures in adults*. Philadelphia: Wolters Kluwer Health; 2015. 1: 679-737.
- [22] Miller AN, Routt MLC. Variations in sacral morphology and implications for iliosacral screw fixation. *Journal of the American Academy of Orthopaedic Surgeons*. 2012; 20 (1): 8–16.
- [23] Kaiser SP, Gardner MJ, Liu J. Implications for Safe Iliosacral Screw Placement. 2014.
- [24] Kaiser SP, Gardner MJ, Liu J, Routt MLC, Morshed S, Gardner M, et al. Anatomic determinants of sacral dysmorphism and implications for safe iliosacral screw placement Anatomic determinants of sacral dysmorphism and implications for safe iliosacral screw placement Disclosures : Other authors : none Anatomic determinants of s. 2010; 177 (1996): 1–4.
- [25] Boulay C, Tardieu C, Hecquet J, Benaim C, Mouilleseaux B, Marty C, et al. Sagittal alignment of spine and pelvis regulated by pelvic incidence: Standard values and prediction of lordosis. *European Spine Journal*. 2006; 15 (4): 415–22.
- [26] Weigelt L, Laux CJ, Slankamenac K, Nguyen TDL, Osterhoff G, Werner CML. Sacral Dysmorphism and its Implication on the Size of the Sacroiliac Joint Surface. *Clinical Spine Surgery*. 2019; 32 (3): E140–4.