

# White Cerebellum Sign After Ventriculo-Peritoneal Shunt Insertion: A Case Report and Review of the Literature

Serge Eddy Mba<sup>1,\*</sup>, Kazadi Kalangu<sup>1</sup>, Aaron Musara<sup>1</sup>, Dumisani Ndlovu<sup>2</sup>,  
Nathaniel Harunangoni Zimani<sup>1</sup>

<sup>1</sup>Department of Neurosurgery, University of Zimbabwe, Harare, Zimbabwe

<sup>2</sup>Department of Radiology, University of Zimbabwe, Harare, Zimbabwe

## Email address:

mbasedy@yahoo.fr (S. E. Mba), kazkal2003@hotmail.com (K. Kalangu), musaraaaron@zol.co.zw (A. Musara),

nat\_zima@yahoo.co.uk (N. H. Zimani), dndlovu@mweb.co.zw (D. Ndlovu)

\*Corresponding author

## To cite this article:

Serge Eddy Mba, Kazadi Kalangu, Aaron Musara, Dumisani Ndlovu, Nathaniel Harunangoni Zimani. White Cerebellum Sign After Ventriculo-Peritoneal Shunt Insertion: A Case Report and Review of the Literature. *International Journal of Neurosurgery*. Vol. 2, No. 2, 2018, pp. 31-34. doi: 10.11648/j.ijjn.20180202.13

Received: September 19, 2018; Accepted: November 7, 2018; Published: December 3, 2018

**Abstract:** White cerebellum sign a reversal of the normal gray/white matter densities and a relatively increased density of the thalami, brainstem and cerebellum; it is also known as dense cerebellum sign or reversal sign. On Computed Tomography, it is seen as hypodensity of the supratentorial brain with reverse increased attenuation of the cerebellum. This ominous sign is a poor prognostic indicator for patients with brain injury. We document a rare case of white cerebellum sign occurring in an eight year old girl who presented to the emergency department with signs of raised intracranial pressure following Ventriculo-peritoneal shunt revision. Our patient improved significantly after resuscitation with mannitol, she was discharged from hospital with an improved Glasgow Coma Score. Our case presents a new opportunity for management of patients with white cerebellar sign. Mannitol is an antioxidant that decrease  $H_2O_2$  by upregulating catalases. It is postulated to have played a role in the clinical improvement of our patient. In this review, only one other patient improved after developing a white cerebellar sign, the etiological factor was meningitis as in our case, and the patient had received osmotherapy as well. Mannitol seems to have a protective effect in patients who develop a white cerebellum sign following meningitis.

**Keywords:** Reversal Sign, Dense Cerebellum, Shunt Malfunction, Intracranial Pressure, Meningitis

## 1. Introduction

The white cerebellum sign is defined as diffusely decreased density of the cerebral cortical gray and white matter with a decreased or loss of gray/white matter interface; or a reversal of the normal gray/white matter densities and a relatively increased density of the thalami, brainstem and cerebellum[1].

This peculiar sign is a classic but rare radiological finding [2] that usually indicates irremediable brain insult and a poor prognosis [3].

We present a clinical case of a paediatric patient who came to the emergency department with signs of raised intracranial pressure after a shunt revision. It is the first time this ominous sign is observed after a shunt procedure.

## 2. Case Report

We report the case of an 8 year old female patient referred from a district hospital after being treated for meningitis.

Ventriculo-peritoneal shunt had been inserted at one year of age for congenital hydrocephalus; shunt was revised twice in the two subsequent years after shunt malfunction, one ventricular piece had been left in situ following shunt dislocation.

For the remaining five years, child was going to school and doing well until two days prior to presentation when she developed severe headaches, associated with vomiting and generalised tonic clonic seizures. She developed a fever (temperature of 38°C), blood and CSF (Cerebro-Spinal

Fluid) analysis sent for malaria parasites, microscopy culture and sensitivity, as well as other infection screen (toxoplasmosis, rubella, cytomegalovirus, herpes simplex...) were all normal except for a microcytic anaemia.

Saturating at 100% on oxygen per face mask, was apyrexial with a Glasgow Coma Scale (GCS) of 11/15 (E4 V2M5). She had global hypertonía and hyperreflexia.

During her hospital stay, she was given a course of intravenous mannitol, and transfused one unit of packed red cells.

Patient was given 20% mannitol at 0.25 g/kg intravenously as a stat dose, then 4 hourly for 24 hours, followed by 6 hourly for 24 hours. This was followed by  $^{1/2}$  Sodium Chloride solution titrated to keep the child urine output at 1ml/kg/hour.

After two weeks in the paediatric ward, patient improved significantly to a GCS of 13/15 (E4V3M6), headache had subsided and patient was discharged.

### 3. Discussion

Anoxic/ischemic injury to the brain may present with a variety of neuropathological abnormalities including neuronal necrosis, marmoration of basal ganglia and thalami, watershed infarcts, periventricular leukomalacia [1] and white cerebellar sign. The cerebellum and brainstem are however generally believed to be more resistant to hypoxic-ischemic insults as compared to supratentorial brain structures [4].

The reversal sign or white cerebellum sign is usually seen in severe head injury, birth asphyxia, drowning, status epilepticus, bacterial meningitis, encephalitis [5] and child abuse [1] but it has never been reported after VP shunt insertion or revision.

Symptoms and signs are often that of increased intracranial pressure including history of irritability, headache, vomiting, seizure and, neck rigidity, changed blood pressure and pulse rate, altered pattern of respiration, papilloedema on fundoscopic examination, all of which suggested intracranial hypertension [3-6].

The exact mechanism and pathogenesis remains unknown but there are several possible theories [1]

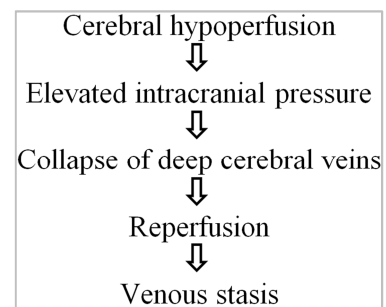
#### 3.1. Reperfusion Theory

During prolonged period of systemic hypotension and brain hypoperfusion, hypoxia is thought to limit ATP (Adenosine triphosphate) production and disrupt the sodium pump; the water influx causes white matter and cortical oedema, this leads to an increase in the intracranial pressure; the latter increases enough to at least partially occlude the subependymal veins and impede deep venous outflow. When the systemic hypotension is corrected, cerebral blood flow increases and this partial venous obstruction causes distension of the deep medullary veins. This venous distension produces the increased density of the cerebral white matter noted on CT [1, 3].

#### 3.2. Anoxia Theory

Anoxia and ischemia elevate brain glucose and cause preferential damage to the cerebral cortex and basal ganglia. Cortex and basal ganglia density decrease with consequential loss of grey white matter differentiation [2].

Bird *et al* looked with more depth at the pathophysiology of the reverse sign and the central theme is that of severe cerebral hypoperfusion, his proposed mechanism starts with cerebral hypoperfusion and ends with venous stasis (Figure 1).



**Figure 1.** Proposed mechanism for development of "reverse" oedema.

There are no specific tests to confirm a diagnosis of hypoxic brain injury but the finding of a white cerebellum sign on radiological imaging have a high predictive value. A computed tomography image will demonstrate the classical generalised hypodensity in the supratentorial hemisphere and hyperdense cerebellum and posterior fossa structures [1, 5, 12-13].

Other investigations to be considered are ABG (arterial blood gases)[13] to assess acid base status during treatment, serum electrolytes and renal function as these patients may develop syndrome of inappropriate anti diuretic hormone (SIADH) secretion.

Management of patients who have developed a white cerebellum sign is symptomatic and is directed at reducing intracranial pressure as well as reversing ischaemic injury. [11, 16].

Central to our management was the institution of a mannitol course; data from Schilte *et al.* indicate that an antiedematous agent such as mannitol can improve brain tissue oxygenation, possibly by limiting astrocyte swelling and restoring capillary perfusion [12]. It will also act as a free radical scavenger [17].

Despite treatment however the prognosis is usually poor [10, 13-15].

The white cerebellum sign has attracted the interest of many scientists over the years but is seldom discussed in the literature.

We reviewed six publications on the subject, three from the United States of America and three from India. Most are case reports with the largest report involving a retrospective analysis of twenty children with reversal sign on CT scan [1].

In his retrospective study, Han *et al* [1] highlighted various causes and risk factors for white cerebellar sign (Table 1).

**Table 1.** Causes of white cerebellum sign (Adapted from a retrospective series of 20 cases, Han 1989).

Causes of white cerebellar sign	Number of cases	%
Hypoxia/anoxia	9	45
Child abuse/non accidental head trauma	7	35
Trauma	2	10
Bacterial meningitis	1	5
Degenerative encephalitis	1	5

Paediatric patients represents the greater majority of case reports with only one case reported in a female adult with post-partum eclampsia [2].

Patients harbouring the white cerebellum sign are often critically ill mainly from hypoxic/anoxic insults and severe brain trauma with a sizeable number victim of child abuse [1] (seven patients in our review).

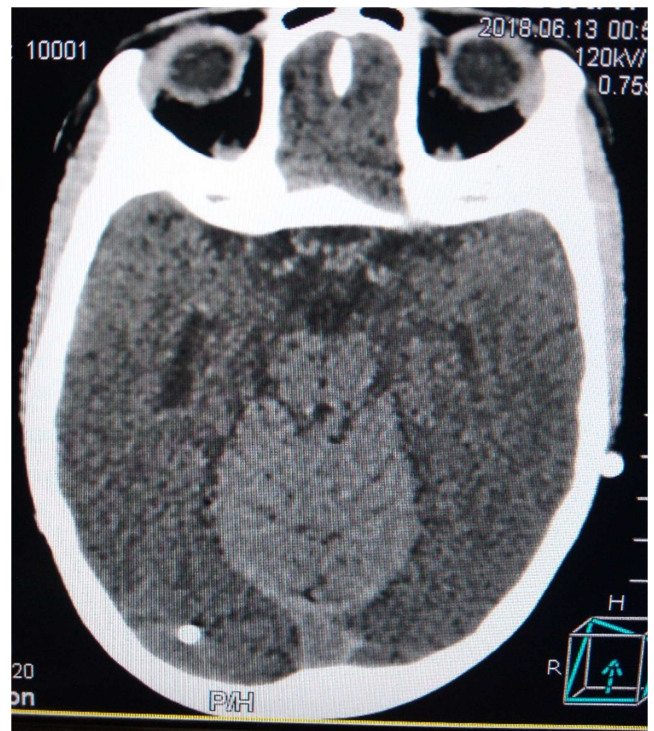
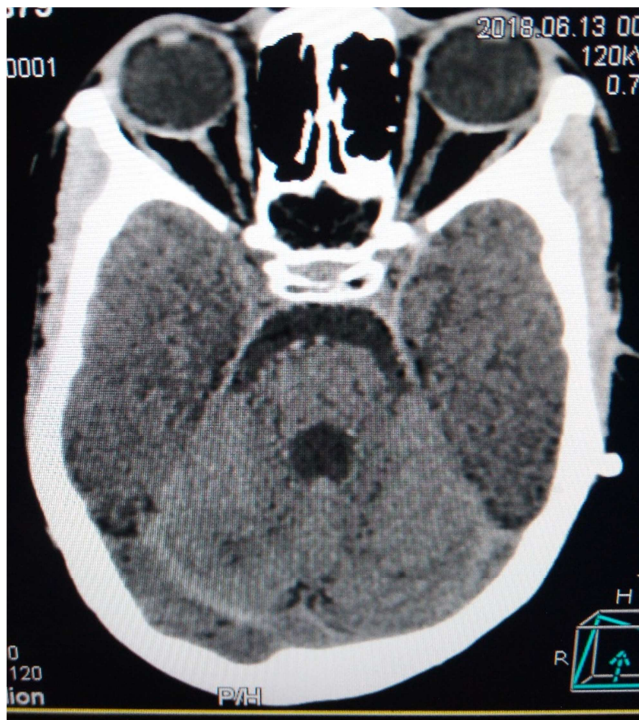Outcome of patients sheltering the white cerebellum sign are more likely to die (thirteen deaths) or have profound irreversible neurological deficit (thirteen patient in a

vegetative state) with only one report of a patient making a full recovery [7]. The review is summarised on Table 2

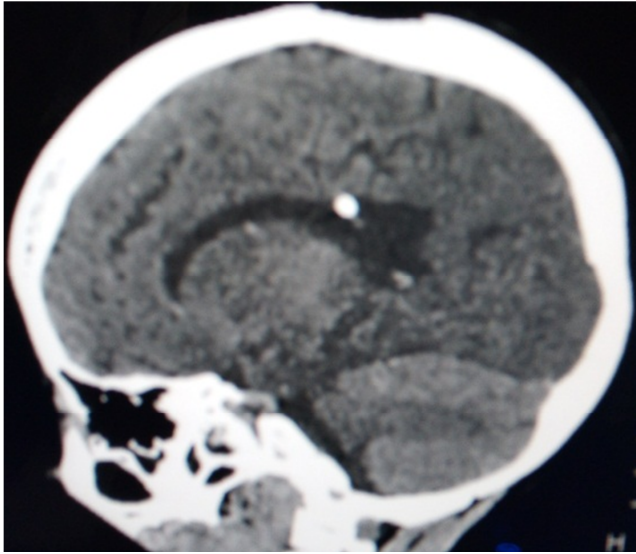
The experience with our case will suggest a role for free radical scavengers in the management of these patients. Mannitol may have played a role in the recovery of our patient; this is also in line with the findings of white cerebellum sign in patients with severe hypoxic ischaemic injuries where free radical formation is embedded in the cascade of events contributing to brain injury [8].

**Table 2.** Summary of published papers on white cerebellum sign.

STUDY	DEMOGRAPHICS	CAUSE/DIAGNOSIS	TYPE OF PAPER	OUTCOME
Han, 1989 (USA)	20 Paediatric patients 8 females, 12 males	Trauma: 9 (7 child abuses) Anoxia/Asphyxia: 9 Encephalitis: 2	Retrospective analysis	7 deaths 13 vegetative states
Bird, 1989 (USA)	3 paediatric patients 2 females, 1 male	Anoxia/asphyxia : 2 Seizure: 1	Case reports	3 deaths
Dwarakanath, 2006 (India)	Female paediatric patient	Trauma	Case report	1 death
Chalela, 2013 (USA)	Male paediatric patient	Meningitis	Case report	Good recovery
Malik, 2013 (India)	Adult female patient	Eclampsia	Case report	1 death
Bhoil, 2016 (India)	Male paediatric patient	Anoxia/asphyxia	Case report	1 death

**Figure 2.** Axial non contrast CT scan showing an enlarged fourth ventricle and white cerebellum( left) classical reversal sign/white cerebellum sign (right).





**Figure 3.** Sagittal non contrast CT scan showing white cerebellar sign and tip of VP shunt.

## 4. Conclusion

White cerebellar sign is an ominous sign of severe brain injury with dreadful outcome. It is still unclear how to manage or reverse the inauspicious outcome associated with the presence of this sign on CT scan.

This case is the first one described following a shunt procedure and add to the complication profile of shunt surgery. It is also one of the few cases of white cerebellum sign with a good outcome.

The experience of the case highlights the possible role played by mannitol as a necessary adjunct to head injury management protocol. Hypoxic injury seems to be the final common pathway for the development of a white cerebellum sign; it is therefore imperative that in managing those patients, an emphasis is placed on alleviating the brain swelling and the reperfusion injury that may ensue.

There is still a great amount of unknown factors that are yet to be elucidated, the prognosis has been very poor in the past and this has to guide the appropriateness of any surgical intervention as well as dictate the counselling provided to patients and relatives.

## Conflict of Interest

The authors declare no conflict.

## Abbreviations

VP Shunt: Ventriculo-Peritoneal Shunt  
GCS: Glasgow Coma Scale  
ATP: Adenosine Triphosphate  
CT scan: Computed Tomography Scan

## References

- [1] Han, B. K., et al. "Reversal Sign on CT: Effect of Anoxic/Ischemic Cerebral Injury in Children." *American Journal of Roentgenology*, vol. 154, no. 2, 1990, pp. 361–68, doi:10.2214/ajr.154.2.2105031.
- [2] Malik, Virender, et al. "'White Cerebellar Sign' in Immediate Postpartum Period." *Medical Journal Armed Forces India*, vol. 71, Elsevier Ltd, 2015, pp. S163–65, doi:10.1016/j.mjafi.2013.10.018.
- [3] Bird, C. Roger, et al. *Pathophysiology of "Reverse "Edema in Global Cerebral Ischemia*. no. February, 1989, pp. 95–98.
- [4] Huisman, T. A. G. M., et al. "The 'Dark Cerebellar Sign.'" *Neuropediatrics*, vol. 38, no. 3, 2007, pp. 160–63, doi:10.1055/s-2007-985909.
- [5] Shroff, Manohar M, and Govind B Chavhan. "Twenty Classic Signs in Neuroradiology: A Pictorial Essay." *Indian Journal of Radiology and Imaging*, vol. 19, no. 2, 2009, p. 135, doi:10.4103/0971-3026.50835.
- [6] Bhoil, Sabina, and Rohit Bhoil. "Reversal Sign: A Red-Flag in Emergency Departments." *Emergency Nurse*, vol. 23, no. 7, 2015, pp. 24–25, doi:10.7748/en.23.7.24.s26.
- [7] Chalela, Julio A., et al. "The White Cerebellum Sign: An under Recognized Sign of Increased Intracranial Pressure." *Neurocritical Care*, vol. 18, no. 3, 2013, pp. 398–99, doi:10.1007/s12028-013-9836-z.
- [8] Huang, Benjamin Y. "Brain Injury: Imaging OBJECTIVES; Hypoxic-Ischemic Brain Injury." *RadioGraphics*, vol. 28, no. 2, 2008, pp. 417–39, doi:10.1148/rg.282075066.
- [9] Jain, Saurabh. "White Cerebellar Sign - a Grave Prognostic Indicator." *Romanian Neurosurgery*, vol. 31, no. 3, 2017, pp. 344–45, doi:10.1515/romneu-2017-0056.
- [10] Dwarakanath, S., et al. *Case Report White Cerebellum Sign – A Case Report and Review of Literature*. 2018, pp. 22–23.
- [11] *White Cerebellum Sign: Red Flag in the Emergency*. Vol. 16, no. 5, 2018, p. 131213, doi:10.1148/rg.282075066.2.
- [12] Schilte, Clotilde, et al. *H 2212*. Vol. 43, no. 10, 2015, doi:10.1097/CCM.0000000000001137.
- [13] Krishnan, Prasad, and Siddhartha Roy Chowdhury. "White Cerebellum " Sign - A Dark Prognosticator. Vol. 5, no. 4, 2014, doi:10.4103/0976-3147.140015.
- [14] Maciel, Carolina B., et al. *The Neurohospitalist The Reversal Sign: An Ominous*. no. November, 2014, pp. 3–5, doi:10.1177/1941874414557081.
- [15] Pierce, A. *The Acute Reversal Sign: Comparison of Medical and Non-Accidental Injury Patients*. 1999, pp. 495–501.
- [16] Young, G. *Early CT Findings of Global Central Nervous System Hypoperfusion*.
- [17] *Free-Radical Scavenging Properties of Mannitol and Its Role as a Constituent of Hyaluronic Acid Fillers: A Literature Review*. 2016, doi:10.1111/ijlh.12426.