

# Cut Throat Injury Presenting As Emergencies in a Tertiary Care Hospital in India: A Retrospective Analysis

Rajat Jain<sup>1</sup>, Sandeep Kaushik<sup>2</sup>

<sup>1</sup>Neuro-Otology Unit, Department of Neurosurgery, Sanjay Gandhi Post Graduate Institute of Medical Sciences, Lucknow, India

<sup>2</sup>Ent Department, Government Medical College, Kannauj, India

## Email address:

dr.rrajatjain@hotmail.com (R. Jain), address-dockkaushik@gmail.com (S. Kaushik)

## To cite this article:

Rajat Jain, Sandeep Kaushik. Cut Throat Injury Presenting As Emergencies in a Tertiary Care Hospital in India: A Retrospective Analysis. *International Journal of Otorhinolaryngology*. Vol. 4, No. 2, 2018, pp. 35-38. doi: 10.11648/j.ijo.20180402.11

**Received:** April 23, 2018; **Accepted:** July 16, 2018; **Published:** September 12, 2018

**Abstract:** Anterior neck injuries are variable according to their extent, depth and cause. These can be intentional or accidental. The injuries may be penetrating or non-penetrating. Injury to certain anatomic structures (e.g. carotid or subclavian vessels) may be fatal in two thirds of cases. Management of injuries that penetrate the platysma depends upon the anatomic level of injury. A retrospective study of 30 cases of cut throat injury presenting as emergency were managed over a two year period from June 2010 to June 2012. They were analysed for details of age, sex, etiology, nature of injury and surgical procedures for management and their complications. A total of 30 cases of cut throat injuries were reviewed. 20 females, 10 males with age ranging from 5 to 60 years, mean age of 21.2 years. 13 cases were suicidal, 10 cases were attempted homicidal, 3 were from animal assault, 2 were as a result of road traffic accident and remaining 2 patients were due to fall on sharp object. Sharp knife was used in all cases of attempted suicide and 80% cases of human assault, while cow horn was the most common object involved in animal assault. Bullet was observed in two cases of gunshot. Four patients had pharyngocutaneous fistula, one developed tracheopharyngeal fistula, One developed wound dehiscence in post-operative period. Suicidal and homicidal wounds account for majority of the cases (76.66%). Cut throat injuries presenting as emergency differ in etiology, extent, and depth. Early intervention in the form of airway management and meticulous repair layer by layer is needed for surgical repair. Complications developed as a result of bad initial management & poor health of patients. Proper initial management & early repair of the 'cut-throat injury' reduces complications and post-operative morbidity. Post-operative follow-up for at least one year is needed to avoid delayed complications and hence morbidity.

**Keywords:** Cut Throat Injuries, Surgical Repair, Management, Complications

---

## 1. Introduction

Anterior neck injuries are variable according to their extent, depth and cause. These can be intentional or accidental [1, 2]. Injuries may be penetrating or non-penetrating, may be due to blunt trauma involving the soft tissues, cartilage, bones and neurovascular bundles or in combinations depending on the extent of the injury and force of impact. Injury wound may be superficial or deep and the causes are variable; road traffic accident, industrial accident, domestic accidents, sports, suicides or homicides using different objects. Approximately 5% to 10% of all trauma cases involve penetrating neck trauma, with multiple structures being injured in 30% of patients [3-5]. Difficulties in management are due to

complicated anatomy of neck, in which vital vascular, aerodigestive, and nervous system structures are present in small area. Thorough knowledge of the anatomy of the neck, physical assessment, and quick decision making, often is needed to prevent catastrophic airway, vascular, or neurologic complications. [3-5]. Overall mortality because of penetrating neck trauma is as high as 11% [3-5]. Injury to certain anatomic structures (e.g., the carotid or subclavian vessels) may be fatal in two thirds of cases [3-5]. The management of injuries to the neck that penetrate the platysma depends upon the anatomic level of injury [4-6]. Anatomically, the neck can be divided into three major zones in order to aid in the decision making for diagnostic tests and timing of surgery [4-6]. Zone I is below the cricoid including the thoracic inlet, it is treated as an upper thoracic injury and represents a dangerous area because

the vascular structures in this zone are in close proximity to the thorax. Zone I has a fairly high mortality rate of 12% [4]. Zone II is between Zones I and III, and is the area of controversy. It is the most frequently involved region (60% to 75%). Zone III is located above the angle of the mandible and is usually treated as head injury. This paper highlights pattern of anterior neck injuries presenting predominantly as cut throat emergencies to the department of otorhinolaryngology of a tertiary care hospital that were mainly in zone II in northern India and compares this pattern with other parts of the world.

## 2. Materials and Method

A retrospective study of 30 cases of cut throat injury presenting as emergencies that were admitted and managed over a two year period from June 2010 to June 2012. They were analysed for details of age, sex, etiology, nature of injury, surgical procedures and their complications. Patients were admitted in emergency department following trauma/assault, where preliminary assessment, basic resuscitative measures and medicolegal formalities were carried out. After informed consent, patients were taken to the operation theatre where the neck injuries were explored and repaired surgically. Twenty five cases were repaired under general anaesthesia while five were carried out under mild sedation with local infiltration with xylocaine/adrenaline preparation. Ryle's tube was inserted intraoperatively and postoperatively patients were placed on ryle's tube feeding for 7days, after being kept nil orally for first 24 hours. Oral liquid milk was given around the tube on the 8<sup>th</sup> post-operative day and if there was no evidence of leakage through the surgical area for 24 hours, ryle's tube was removed and patient put on graded fluid and semisolid diet for another

one week. Supportive treatment in terms of psychiatric assessment/treatment was carried out in known psychiatric cases before and after the patient was discharged from hospital.

## 3. Results

Total number of 30 cases of cut throat injury were analysed over the period of time. Out of them 20 were females and 10 were males with age ranging from 5 to 60 years with a mean age of 21.2years. The majority of the patients were from the 2<sup>nd</sup> to 4<sup>th</sup> decades (78.9%) of life with a peak at the 4<sup>th</sup> decade (31.6%). (Table 1)

*Table 1. Age range.*

Age Range (years)	Number of patients (%)
0-10	1 (3.33%)
11-20	6 (20.0%)
21-30	8 (26.66%)
31-40	9 (30.0%)
41-50	3 (10.0%)
51-60	3 (10.0%)
Total	30 (100%)

### Aetiology:

13 cases were of suicidal attempt with a past history suggestive of psychiatric disorder with irregular treatment, 10 cases were due to attempted homicidal assault, 3 were from animal assault like hitting by bull, 2 were as a result of road traffic accident and remaining 2 due to fall on sharp object (Table 2). Sharp knife was used in all cases of attempted suicide and 80% cases of human assault, while cow horn was the most common object involved in animal assault. Bullet was observed in two cases of gunshot, while fall on a sharp pointed object was responsible for the two paediatric cases (5years old).

*Table 2. Showing aetiology, age range & object used.*

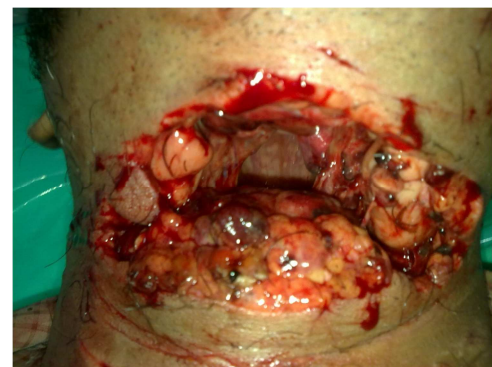Aetiology	Number of Patients (%)	Age Range (yrs.)	Mean Age (yrs.)	Object involved
Attempted suicide	13 (43.33%)	20-60	33.9	Knife (13)
Homicidal assault	10 (33.33%)	18-35	25.8	Knife (8); Gun (2)
Animal assault	3 (10.0%)	30-35	32.5	Cow horn
Road traffic accident	2 (6.66%)	35	35	Vehicle
Fall on sharp object	2 (6.66%)	5-6	5	Sharp object
Total	30 (100%)			

### Type and site of wounds:

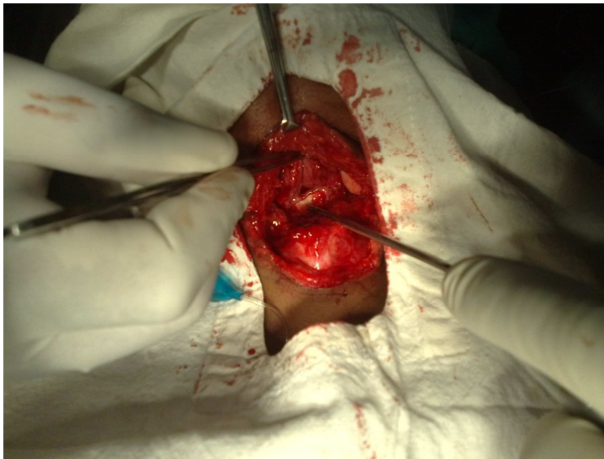Patients had open wounds exposing the hypopharynx, larynx or both.

Suicidal patients had horizontally positioned anteriorly placed incisional wounds which were deeper when compared to others. (figure 1).

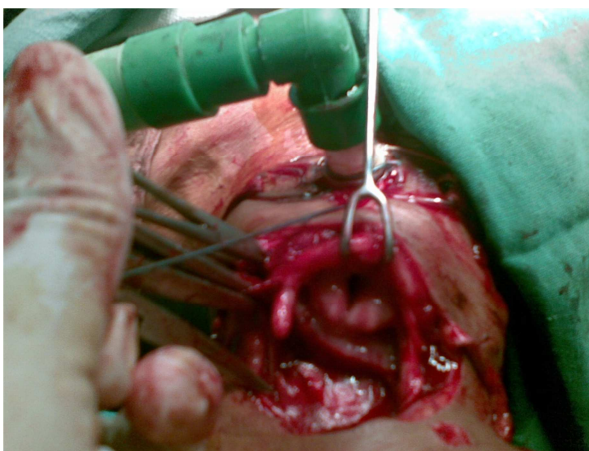
Homicidal cases had obliquely positioned incisional wounds that were more laterally placed in neck with multiple wounds indicating that the victim had engaged the assailant in self-defence. Restoration of normal pharyngeal and laryngeal architecture without compromise of food passage and airway was carried out through meticulous surgical repair of various tissue layers Fiureg 2, 3.



*Figure 1. Suicidal incision- horizontally positioned anteriorly placed.*



**Figure 2.** Restoration of laryngeal framework.



**Figure 3.** Restoration of laryngeal framework after tracheostomy.

Psychiatric evaluation and treatment where necessary was offered concurrently. Twenty three patients required a tracheostomy to prevent upper airway obstruction from severe laryngeal trauma/tissue edema. Only seven cases were repaired under sedation and infiltration with local anaesthesia.

#### Outcome:

All patients had excellent wound healing and restoration of normal anatomical structures without pharyngeal or laryngeal stenosis or any other significant post operative complications; except 6 patients (20%), out of which 4 developed pharyngocutaneous fistula, 1 with tracheopharyngeal fistula and 1 with wound dehiscence.

## 4. Discussion

Cut Throat injury presenting as emergency may be fatal if major blood vessels of the neck are involved, resulting in haemorrhage and hypovolaemic shock or if there is aspiration of blood or severe airway obstruction from edema and fractured laryngeal skeleton [1, 2, 3, 4, 5]. No casualty was observed during review of this article. If a cervical spine injury was suspected, neck stabilization and immobilisation was done as part of initial management. Management of the airway is first priority for all patients of cut throat injury. If

the airway is compromised, and there is significant bleeding or edema in the oral cavity or pharynx, the patient should undergo emergency tracheostomy. Tracheostomy was carried out in Twenty three patients out of the thirty (76.6%). Tracheostomy was carried out by Ezeanolue [7], Ladapo [1] and Okoye [2] in all their reported patients with cut throat injuries. Bhattacharjee and his colleagues performed tracheostomy in 15 out of the 26 cases in their study [8]. Iseh [12] et al did not agree to routine use of tracheostomy in all patients with cut throat anterior neck injuries. Exposed hypopharynx, larynx and trachea from cut throat injuries requires surgical repair layer by layer to restore the continuity of the aerodigestive tract so as to prevent complications. Adequate surgical technique is required to ensure that airway, laryngeal function (voice and protection of the lower airway) and food passages are adequately preserved or restored. Pharyngeal, hypopharyngeal and laryngeal mucosal lacerations should ideally be repaired early (within 24 hours) [9, 10]. Leopold recognised the need for early repair of laryngeal mucosa lacerations as it has an effect on both airway stenosis and on voice [9]. Data of article illustrates that in 10 patients (33.3%) hypopharynx was exposed, 8 patients (26.6%) presented to the hospital emergency 1 -2 days after injury. Poor socioeconomic background and remote residence in villages was the reason for delay in presentation to tertiary care center. These patients were perhaps managed in unsterile conditions in primary health centres due to which wounds were badly contaminated at the time of presentation. As a result 6 out of 30 (20%) developed complications. Significant glottic and supraglottic lacerations and displaced cartilage fractures need surgical approximation [9, 10]. Ezeanolue reported significant laryngotracheal stenosis as a long term morbidity suffered by two of the patients in his study [7]. No laryngotracheal stenosis was reported on follow up of 1 year in the article. In case of severe penetrating neck injuries from gun shots, endoscopy and computerised tomographic (CT) scan will differentiate between the patients that need only observation (small laceration, shallow laceration, undisplaced fracture) and those that require a thyrotomy or open fracture reduction and mucosal approximation [11]. A soft laryngeal stent may be needed for badly macerated mucosa. Complications like pharyngo-cutaneous fistula, tracheopharyngeal fistula must be prevented as much as possible while carrying out pharyngo-hypopharyngeal repair requiring meticulous approximation of the tissues. Use of ryle's tube and nil oral feeding for a minimum of 7 -9days is effective in preventing these complications. In pharyngo-cutaneous fistula, ryle's tube feeding must continue for as long as possible until the fistula closes on a conservative management. If the fistula persists for more than 6weeks, one must look for the possibility of presence of a foreign body, inadequate surgical technique, malnutrition or a concomitant underlying concealed malignancy especially in the elderly patients. Such cases may need flap closure using local, regional or distant flaps after excision of the fistula. One case of wound dehiscence was managed conservatively with regular

dressings of the wound and patient was kept on ryle's tube feeding. Proper psychiatric evaluation is essential in all cases of attempted suicide and homicide otherwise a repeat incidence may be fatal. Ladapo reported a case that was ready to commit suicide again if given another opportunity [1]. Bhattacharjee et al mentioned family troubles, psychiatric illness and poverty as the triggering factors in suicidal attempts [8]. All cases of suicidal attempts were known psychiatric patients who were on irregular medications [13]. The motives of homicide included political, family conflict, crimes like sexual assault, dacoity, land related disputes, etc. Animal attack with cow/bull horn occurred in 2 patients with significant damage to the anterior neck requiring surgical repair. It may be under reported in a tertiary health institution which receives apparently difficult cases being referred from periphery. Cattle is widely used both for domestic and commercial purposes and animal injuries sustained from cattle is a common feature in many rural areas that may not be brought to tertiary care center. Gunshot done for settling political scuffle was reported in two cases in this study while the two children in this study (5years) with cut throat injury were due to fall on a sharp object. Complications of Cut throat injuries could be classified as immediate, intermediate and delayed [1, 3, 4, 5, 11]. Immediate complications include respiratory obstruction from fractured hyoid bone, thyroid, cricoid or tracheal cartilages pushed posteriorly, slit base of tongue falling over the laryngeal inlet, edema or haematoma in or around the larynx, air embolism into the neck veins, profuse haemorrhage and hypovolaemic shock. Intermediate complications include respiratory obstruction due to surgical emphysema, non-specific infections like cervical cellulitis, perichondritis and or mediastinitis, tetanus and gas gangrene in contaminated wounds. Aspiration pneumonitis due to loss of laryngeal afferents or motor control. Tracheo-esophageal fistula, pharyngo-cutaneous, chyle or lymph fistula are the other intermediate complications. Delayed complications include aphonia, dysphonia or hoarseness, stenosis of the aerodigestive tract, aneurysmal formation or arterio-venous fistula, hypertrophic neck scar and psychological trauma.

## 5. Conclusion

Cut throat injuries presenting as emergency vary in etiology, extent, and depth. Early intervention in the form of airway control and meticulous closure layer by layer is needed for surgical repair. Suicidal and homicidal wounds account for majority of the cases (76.66%) in our study. Out of 30 patients, 4 (13.33%) had pharyngocutaneous fistula, 1 (3.33%) developed tracheopharyngeal fistula and 1 (3.33%)

developed wound dehiscence as post-operative complications. These complications developed as a result of bad initial management & poor health of patients. Proper initial management & early repair of the 'cut-throat injury' reduces complications and post-operative morbidity. Post-operative follow-up for at least one year is needed to avoid delayed complications and hence morbidity.

## References

- [1] Ladapo AA: Open injuries of anterior aspect of the neck. *Ghana Med Journal*; 1979; 4:182-6.
- [2] Okoye BC, Oteri AJ. Cut throat injuries in Port Harcourt. *Sahel Med Journ*; 2001; 4:207-209.
- [3] Kendall JL, Anglin D, Demetriades D. Penetrating neck trauma. *Emergency Medicine Clinics of North America*; 1998; 16:85-105.
- [4] Biffi WL, Moore EE, Rehse DH, Offner PJ, Franciose RJ, Burch JM. Selective management of penetrating neck trauma based on cervical level of injury. *American Journal of Surgery*; 1997; 174:678-82.
- [5] Demetriades D, Asensio JA, Velmahos G, Thal E. Complex problems in penetrating neck trauma. *Surgical Clinics of North America*; 1996; 76:661-83.
- [6] Bumpous JM, Whitt PD, Ganzel TM, McClane SD. Penetrating injuries of the visceral compartment of the neck. *American Journal of Otolaryngology*; 2000; 21:190-194.
- [7] Ezeanolue BC. Management of the upper airway in severe cut throat injuries. *African Journal of medicine and medical sciences*; 2001; 30:233-5.
- [8] Bhattacharjee N, Arefin SM, Mazumder SM, Khan MK. Cut throat injury: a retrospective study of 26 cases. *Banladesh Med Res counc*; 1997; 23:87-90.
- [9] Leopold DA: Laryngeal trauma, *Arch Otolaryngol*; 1983; 109:106-109.
- [10] Cherian TA, Rupa V, Raman R. External laryngeal trauma: analysis of 30 cases. *JLO*; 1993; 107:920-923.
- [11] Naaeder SB. The neck. In: Badoe EA, Archampong EQ and da Rocha-Afodu JT eds. *Principles and Practice of surgery including Pathology in the Tropics*, 3<sup>rd</sup> edition. Tema, Ghana: Ghana Publishing Corporation Publishers; 2000:339.
- [12] Iseh K. R. Fwacs, Obembe A. Fwacp. Anterior neck injuries presenting as cut throat emergencies in a tertiary health institution in north western Nigeria. *Nigerian journal of medicine.com/files/journals/1/articles/.../52-116-1-RV.doc*.
- [13] Zafarullah Beigh, Rauf Ahmad Management of cut-throat injuries Year: 2014 | Volume: 30 | Issue: 3 | Page: 268-271.