

Case Report

Gallbladder Volvulus: A Rare Case of Pre-operative Diagnostic Quandary

Kriti Mittal^{1,*} , Sagar Panthi² , Terrence Donahue¹ , Noubar Kevorkian¹ 

¹General Surgery, University of Connecticut Health, Hartford, USA

²General Surgery, BP Koirala Institute of Health and Sciences, Dharan, Nepal

Abstract

Introduction: Gallbladder volvulus (GBV) is a rare but critical condition characterized by torsion of the gallbladder on its mesentery. Prompt surgical intervention is crucial in preventing complications and improving patient outcomes. Despite advancements in imaging techniques, diagnosing GBV remains challenging due to its nonspecific clinical presentation and low preoperative detection rates. **Case Details:** This paper presents the case of a 79-year-old female presenting with symptoms suggestive of acute appendicitis and urinary tract infection. Imaging, including Computed Tomography (CT), ultrasound, (US) and magnetic resonance cholangiopancreatography (MRCP), were indicative of acute acalculous cholecystitis. Intraoperatively, a necrotic gangrenous gallbladder was encountered, resulting from GBV. **Discussion:** GBV poses diagnostic difficulties due to its variable presentation and low preoperative detection rates. Misdiagnosis poses significant risk of mismanagement, especially in the elderly and high risk populations, where non-operative management is attempted (antibiotics, percutaneous cholecystostomy, etc.) leading to increased morbidity and mortality. Therefore, high index of suspicion and correlation with imaging findings are crucial for accurate diagnosis. While various imaging modalities can assist in diagnosis, interpretation may be challenging, as demonstrated in this case. Surgical intervention, preferably through laparoscopy, is the cornerstone of treatment and offers favorable outcomes when performed promptly. **Conclusion:** In conclusion, GBV is a rare but potentially life-threatening condition that necessitates early recognition and surgical intervention. Despite challenges in diagnosis, a comprehensive clinical and radiological approach is crucial for timely management and optimal patient outcomes. Further research and awareness are warranted to enhance early diagnosis of this uncommon entity.

Keywords

Gallbladder Volvulus, Gallbladder Torsion, Floating Gallbladder, Acute Abdomen, Acute Appendicitis, Urinary Tract Infection (UTI)

1. Introduction and Background

GBV is a very rare cause of acute abdomen requiring immediate surgical attention. It occurs when the gallbladder is either completely ($>180^\circ$) or partially ($<180^\circ$) twisted around its longitudinal mesentery, based on which the presentation

differs [1, 2].

GBV is commonly reported among elderly females (female: male ratio of 5:1) in their 70s and 80s, and has been found to be associated with low body mass index (BMI)/thin

*Corresponding author: kmittal@uchc.edu (Kriti Mittal)

Received: 15 May 2024; **Accepted:** 31 May 2024; **Published:** 19 June 2024



Copyright: © The Author(s), 2024. Published by Science Publishing Group. This is an **Open Access** article, distributed under the terms of the Creative Commons Attribution 4.0 License (<http://creativecommons.org/licenses/by/4.0/>), which permits unrestricted use, distribution and reproduction in any medium, provided the original work is properly cited.

body habitus, or spinal deformities such as kyphoscoliosis, liver atrophy, significant weight loss, loss of visceral fat, and atherosclerotic cystic artery [1-3]. The clinical presentation of GBV is non-specific and often mimics other entities of acute abdomen such as acute cholecystitis, peptic ulcer disease, acute appendicitis, choledochal cysts, choledocholithiasis, nephrolithiasis, etc. [1, 2, 4].

Although advances in imaging are promising, they have not significantly contributed to differentiating GBV from other causes of acute abdomen. Preoperative diagnosis based on clinical findings and advanced imaging accounts for only 10-26% of patients presenting with GBV [2, 6]. The vast majority of cases are identified intra-operatively. Therefore, laparoscopic or open cholecystectomy remains the mainstay of diagnosis and treatment of GBV. Expedient cholecystectomy offers an excellent prognosis as delay in treatment may result in gallbladder necrosis, perforation, and bilious peritonitis accounting for an increase in mortality rate (5-6%) [1-4].

Here is a presentation of a case of a 79-year old female, who had an initial presentation mimicking that of acute appendicitis and urinary tract infection. She had imaging findings suggestive of acute acalculous cholecystitis. During cholecystectomy, the gallbladder was found to be volvulized, which was the cause of her symptoms.

2. Case Review

2.1. Clinical Presentation

A 79-year old Caucasian female, BMI 23.5 kg/m² with past medical history of hypertension, hyperlipidemia, atrial fibrillation on apixaban, and mild to moderate mitral regurgitation (MR) presented to an urgent care with three day history of progressive right lower quadrant pain radiating to the mid

abdomen. She had no episodes of fever, chills, nausea, vomiting, dysuria, burning or increased frequency of urination. Her vitals were within normal limits. On examination, she had right lower quadrant tenderness with rebound. Bloodwork showed leukocytosis (White Blood Cell $13.2 \times 10^9/L$ with neutrophilic predominance) and hyperbilirubinemia (total bilirubin 2.2 mg/dl) without transaminitis. Urinalysis showed pyuria suggestive of a UTI. With suspicion for acute appendicitis or complicated UTI, she was sent to the Emergency Department (ED) at an outside hospital (OSH) for further imaging.

2.2. Imaging

CT of the abdomen pelvis (Figure 1) showed a normal appendix, however, did reveal a distended gallbladder with wall thickening and pericholecystic inflammatory changes without distinct cholelithiasis, suggestive of acute acalculous cholecystitis (AAC). The biliary ductal system was diffusely dilated. For further diagnostic clarity, this was followed with an US of right upper quadrant, which showed a hydropic gallbladder with sludge, diffuse gallbladder wall thickening of up to 6 mm, and pericholecystic fluid consistent with acute cholecystitis. The common bile duct (CBD) was measured at 12.9 mm, with no distinct choledocholithiasis. She was transferred for further evaluation and management to the ED. Given the dilation of the CBD and concern for choledocholithiasis or biliary obstruction, an MRCP was pursued (Figure 2), which redemonstrated pericholecystic inflammatory changes, but no biliary obstruction or stricture. Given her reasonable cardiac risk, (a normal left ventricle ejection fraction, mildly depressed right ventricular function with RVEF 50%, and mild-mod MR on most recent cardiac imaging), decision was made to proceed with a laparoscopic cholecystectomy (LC) with cholangiogram.

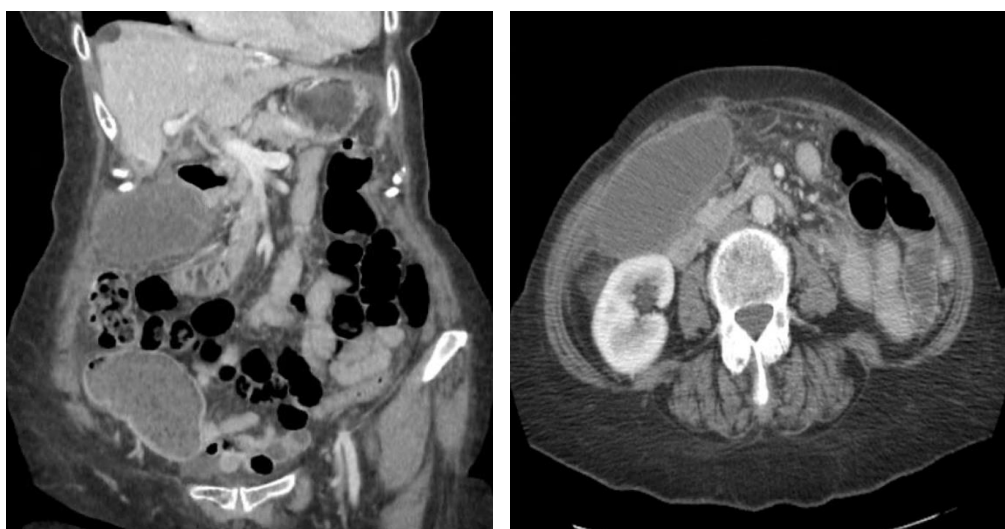

Figure 1. (CT Abdomen and Pelvis): Markedly distended gallbladder with wall thickening and pericholecystic inflammation. No definite gallstones. Mild to moderate intrahepatic biliary ductal dilation and enlargement of the common bile duct.

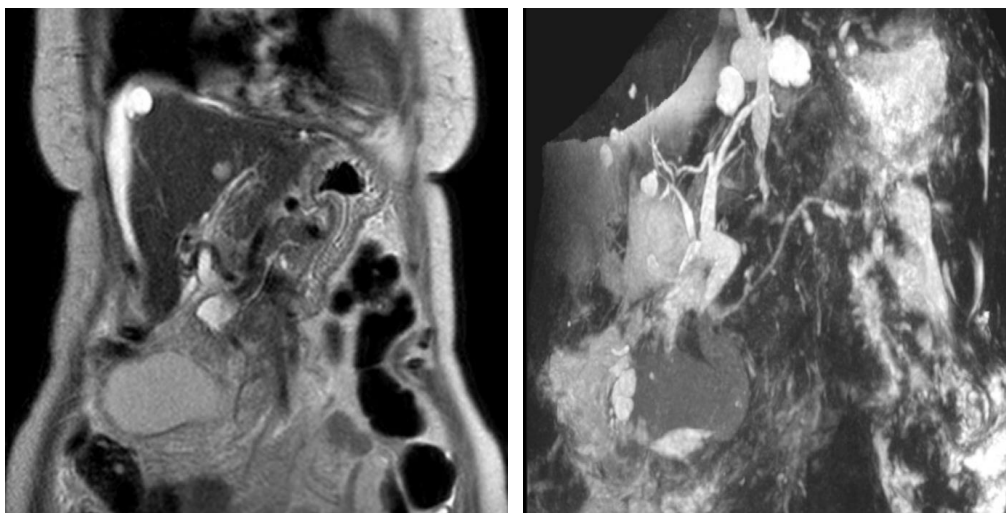


Figure 2. (MRCP): Mild free fluid adjacent to the liver and spleen consistent with ascites. Markedly distended and thick-walled gallbladder suggestive of acute cholecystitis. No definite intraluminal filling defects identified. The extrahepatic common bile duct does appear somewhat distended measuring a maximum of 11 mm. It tapers normally. No definite intrahepatic biliary dilatation. No intraluminal filling defects identified.

2.3. Operative Course

Upon laparoscopic entry into the abdomen, a gangrenous and necrotic gallbladder was immediately identified (Figure 3). It was edematous and markedly distended, occupying the majority of the right side of the abdomen. There were significant adhesions between the abdominal wall and the liver, which were lysed with electrocautery. The gallbladder was noted to have no attachments to the liver and was freely laying over the

abdominal bed. Given the significant dilation of the gallbladder, it was initially decompressed with return of 120 mLs of hydropic white bile. Upon elevation of the dome, the gallbladder was found to be pedunculated on a stalk and torsed 180 degrees, resulting in a complete volvulus. Detorsion failed to reverse the ischemic changes of the gallbladder, which remained gangrenous (Figure 4). The cystic duct and artery were circumferentially dissected, clipped, and safely transected. The gallbladder was exteriorized in an endo-catch bag.

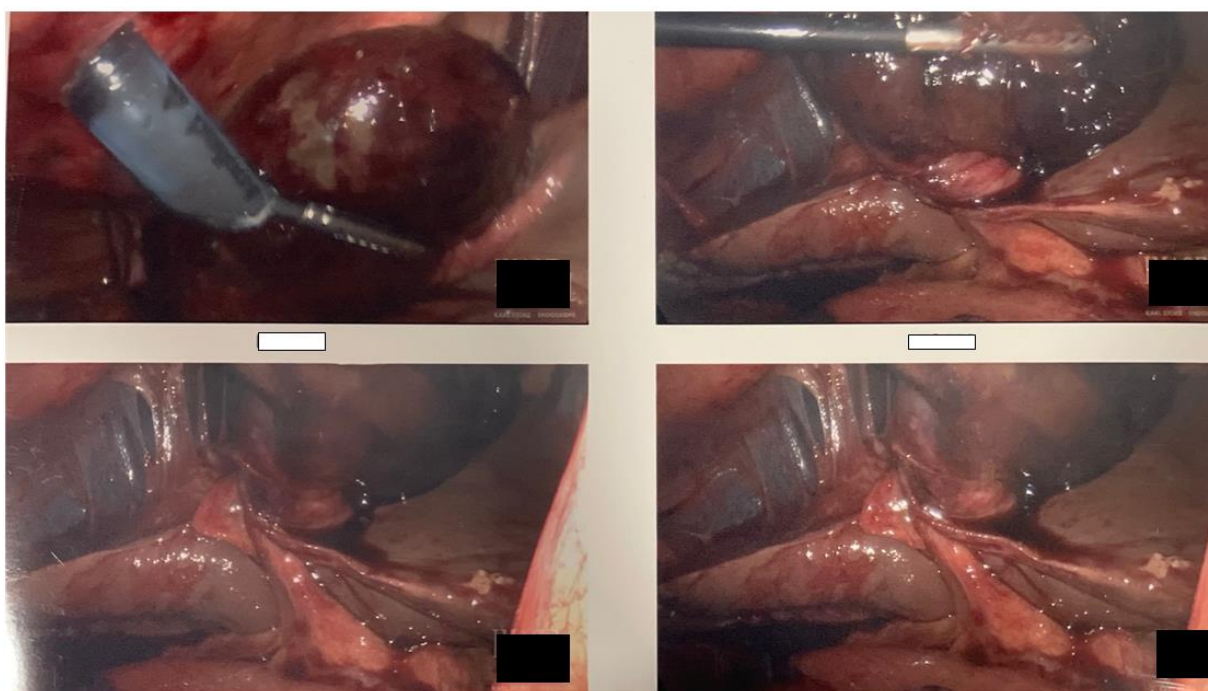


Figure 3. Gangrenous gallbladder pedunculated on its stalk and torsed 180 degrees.

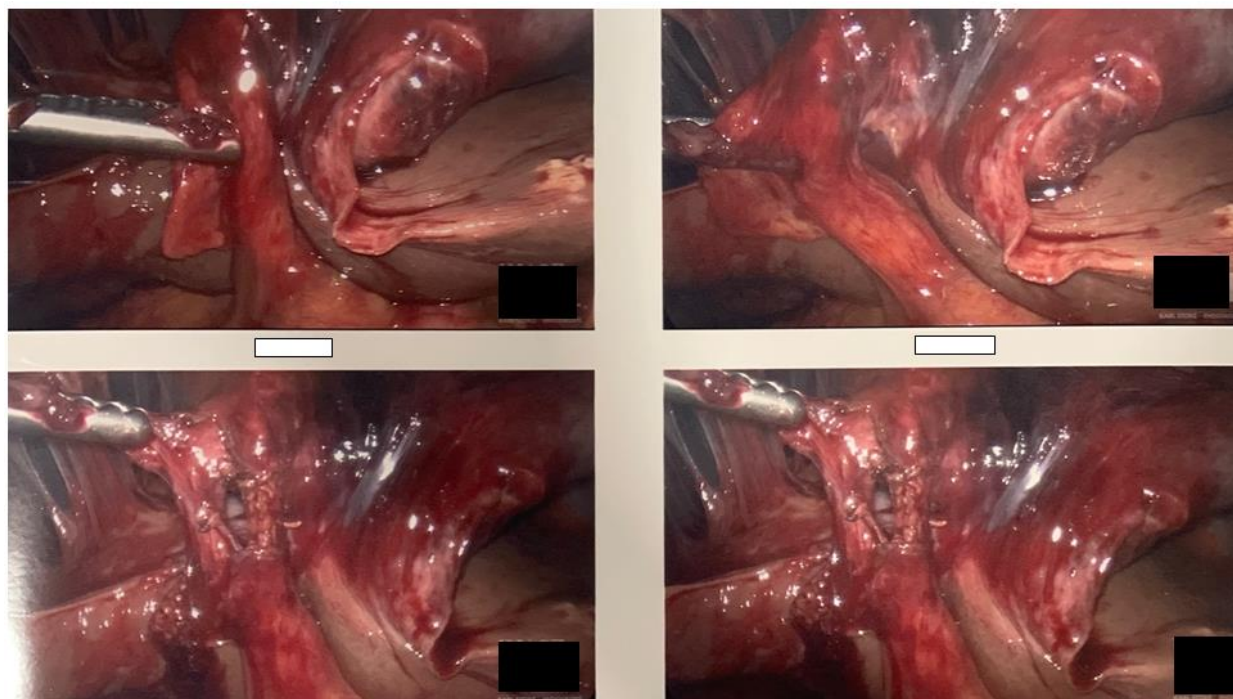


Figure 4. Necrotic gallbladder after detorsion.

2.4. Post-Operative Course

The patient had an uneventful recovery and experienced no post-operative complications. She tolerated a diet and was subsequently discharged on postoperative day 1. She was seen 2 weeks later in follow up and had continued to do well.

2.5. Pathology

The histopathology reported it as acute necrotizing cholecystitis with intraluminal blood clot. No choleliths or masses noted. Cystic duct was 0.9 cm in diameter. One benign 1.2 cm lymph node was present.

3. Discussion

Described as a “floating gallbladder” for the first time in 1898, only a few cases of GBV (approximately 500) have been reported to date [1, 2] with an estimated incidence of around 1 in 365,000 cases [3]. Though the precise etiology has not been entirely understood, anatomic abnormality of the gallbladder vascular pedicle, age related visceral loss accompanied by liver atrophy, elongation and thinning of the previously normal mesentery, torturous or atherosclerotic cystic artery, and lack of leverage of gallbladder to the liver have been considered some contributing factors of GBV [1-3].

Preoperative diagnosis of GBV could be challenging. Lau et al proposed “Triad of Triads” to identify a potential GBV. This comprised of clinical (elderly – usually females, thin habitus, spinal deformity), symptomatic (sudden onset, right upper

quadrant pain, early emesis) and physical findings (non-toxic presentation, right upper quadrant palpable mass, pulse-temperature discrepancy). This may not be uniform to all the GBV patients [5]. Similar is the case with this patient where only 3 out of 9 clinical parameters including elderly age (79 years)/female gender, sudden onset of symptoms and non-toxic appearance matched the “Triad of triads” for GBV diagnosis.

Moreover, the presentation with acute right lower quadrant pain radiating to the mid abdomen, right lower quadrant tenderness and rebound, leukocytosis on complete blood count, in addition to a positive urinalysis directed the differential diagnosis towards acute appendicitis or complicated urinary tract infection, which was the trigger for obtaining abdominal computed tomography [6]. Such presentation is quite rare for GBV and only four such cases have been previously reported in the literature [6-9]. Surprisingly, CT imaging showed a normal appendix with inflammatory changes around the gallbladder associated with hyperbilirubinemia and biliary dilatation suggestive of AAC and associated biliary obstruction. This was further worked up with US which confirmed the inflammatory changes and showed sludge suggestive of acute calculus cholecystitis. No sonographic features that would suggest GBV was noted. The MRCP obtained to further assess the CBD dilatation added to the dilemma, with no gallstones, sludge, or filling defects in the biliary tree. Despite a myriad of imaging, a definitive diagnosis could not be reached preoperatively.

Clinically, GBV and AAC are known to mimic each other. However, acute abdominal pain without other constitutional symptoms like fever, signs of sepsis, or jaundice added to a poor response to antibiotic therapy should raise suspicion for

GBV as part of the differential. Mere reliance on laboratory and imaging findings seem unrewarding in this case [4, 10], and could easily lead to missed diagnosis and associated morbidity.

A combination of imaging modalities including abdominal US, CT, hepatobiliary iminodiacetic acid (HIDA) scan, magnetic resonance imaging (MRI), MRCP, etc. are some of the initial investigative methods when suspecting gallbladder pathology. Preoperative identification of GBV accounts for only 10-26% of the cases presenting with GBV [2, 6]. Clear knowledge of specific imaging findings and its correlation with clinical signs and symptoms are key in pre-operative identification of this entity [3]. The “whirl sign” or “swirl sign” at the neck of the gallbladder with wall thickening might indicate volvulus at the cystic pedicle. An abrupt angulation at the Hartmann’s pouch gives rise to a “beak” sign distal to the fulcrum point. Change in anatomical position from vertical to horizontal can be seen on a contrast enhanced CT scan or MRCP [2, 11-15]. A “floating gallbladder” sign or “cystic duct knot” sign on US indicates a floating GB with v-shaped twisted cystic duct with echogenic nodular area near its neck [3, 4, 11, 16]. Enhanced signal intensities around the neck and the wall indicating possible necrosis or hemorrhage on MRCP; vascular compromise around the neck on color flow doppler; abnormal GB position and size with different intensities and distortions of the extrahepatic bile ducts and cystic duct caused by the cystic duct tractions on CT can be very useful in diagnosing a GBV preoperatively [1-4, 6, 11, 12, 16-18]. Although most of these imaging modalities were performed in this patient, the findings suggestive of acute necrotizing cholecystitis as suggested by the histopathology were not well observed. Hence, the correlation of these findings on the aforementioned imaging modalities may be needed if clinical suspicion of GBV is high.

As the preoperative diagnosis of GBV is challenging and delay in the diagnosis invites complications associated with increased mortality, the mainstay of management of GBV remains emergent cholecystectomy either via laparotomy or laparoscopy [1-4]. Although there is no definitive evidence on the outcomes of laparoscopy over laparotomy in GBV, laparoscopic cholecystectomy due to its minimally invasive nature and associated lower post-operative pain, complication rate, and shorter recovery time remains the preferred modality of management irrespective of the degree of torsion [1, 3]. During cholecystectomy in GBV, it is important to maintain decompression and detorsion along with creating the critical view of safety in order to prevent inadvertent iatrogenic vascular or biliary injury. This reduces the incidence of bile peritonitis, sepsis, further morbidity or mortality [1, 3, 4]. Moreover, thick adhesions from chronic inflammation might hinder safe laparoscopic dissection and development of the critical view of safety, resulting in conversion to open cholecystectomy for better in hopes of allowing a safer dissection [2, 11]. Although significant adhesions were noted during laparoscopy in the patient, the critical view of safety was

attained and open conversion was not necessary.

Attempted non operative management for acute calculous cholecystitis (ACC) or AAC could be appropriate in some high risk patients, such as severe ischemic cardiac disease, pulmonary disease, kidney disease, unstable atrial fibrillation, cerebrovascular disease, uncontrolled diabetes, malignancy, or debility due to severe sepsis [19-22]. Though standard guidelines recommend early LC (< 72 hours) for cases of ACC and AAC rather than non-operative measures, patients with presumed poor tolerance of emergency LC can be reasonable candidates for Percutaneous cholecystostomy tube (PCT) [1, 23, 24].

The pathophysiology of GBV is non-infectious but could quickly escalate into resultant infectious complications. It is important to note that percutaneous cholecystostomy is not only not recommended for the treatment of GBV, but it could also provide a false sense of security and lead to progression into gallbladder ischemia, necrosis, gangrene, perforation, peritonitis, multiple organ failure and even death [1]. With significant pre-operative diagnostic challenges, where nearly 75% of the cases remain misdiagnosed pre-operatively, it would not be uncommon to pursue non-operative management strategies in high risk patients, resulting in significant morbidity (16%) and mortality (5-6%) [1, 4]. Hence, early diagnosis and timely surgical treatment would significantly improve outcome [1-4, 6, 7, 11].

4. Conclusion

GBV is a rare and frequently misdiagnosed cause of acute abdomen requiring urgent surgical intervention. The pre-operative diagnosis of GBV remains challenging despite emergence of modern imaging technologies as seen in this patient. Inability to recognize GBV when encountered can direct a non-operative or percutaneous approach which would henceforth have very poor outcomes. A high index of suspicion is warranted in patients if findings are remotely suggestive of GBV. Diagnostic laparoscopy proved to be the mainstay of diagnosis for this patient. The literature on awareness of this rare clinical entity as well as the gold standard modality of diagnosis of GBV is limited making it a potential for further research.

Abbreviations

GBV	Gallbladder Volvulus
CT	Computed Tomography
MRCP	Magnetic Resonance Cholangiopancreatography
BMI	Body Mass Index
MR	Mitral Regurgitation
UTI	Urinary Tract Infection
ED	Emergency Department
OSH	Outside Hospital
CBD	Common Bile Duct

RVEF	Right Ventricular Ejection Fraction
HIDA	Hepatobiliary Iminodiacetic Acid
MRI	Magnetic Resonance Imaging
AAC	Acute Acalculous Cholecystitis
ACC	Acute Calculous Cholecystitis
LC	Laparoscopic Cholecystectomy
PCT	Percutaneous Cholecystostomy Tube

Author Contributions

Kriti Mittal: Conceptualization, Investigation, Resources, Writing – original draft, Writing- reviewing & editing

Sagar Panthi: Writing – original draft, Resources

Terrance Donahue: Conceptualization

Noubar Kevorkian: Conceptualization, Investigation, Supervision, Writing- reviewing & editing

Funding

This work is not supported by any external funding.

Data Availability Statement

The data supporting the outcome of this research work has been reported in this manuscript

Conflicts of Interest

The authors declare no conflicts of interest.

References

- [1] Keeratibharat, N., & Chansangrat, J. (2022). Gallbladder volvulus: A Review. *Cureus*. <https://doi.org/10.7759/cureus.23362>
- [2] Reilly, D. J., Kalogeropoulos, G., & Thiruchelvam, D. (2012). Torsion of the gallbladder: A systematic review. *HPB*, 14(10), 669–672. <https://doi.org/10.1111/j.1477-2574.2012.00513.x>
- [3] Pottorf, B. J., Alfaro, L., & Hollis, H. W. (2013). A clinician's guide to the diagnosis and management of gallbladder volvulus. *The Permanente Journal*, 17(2), 80–83. <https://doi.org/10.7812/tpp/12-118>
- [4] Mouawad, N. J., Crofts, B., Streu, R., Desrochers, R., & Kimball, B. C. (2011). Acute gallbladder torsion - a continued pre-operative diagnostic dilemma. *World Journal of Emergency Surgery*, 6(1), 13. <https://doi.org/10.1186/1749-7922-6-13>
- [5] Lau, W. Y., Fan, S. T., & Wong, S. H. (1982). Acute torsion of the gall bladder in the aged: A re-emphasis on clinical diagnosis. *ANZ Journal of Surgery*, 52(5), 492–494. <https://doi.org/10.1111/j.1445-2197.1982.tb06036.x>
- [6] Shah, N., Ballecer, E., Hanna, I., Levin, G., & Khalife, M. E. (2021). Gallbladder volvulus presenting as acute appendicitis. *Cureus*. <https://doi.org/10.7759/cureus.14484>
- [7] Bauman, Z., Ruggero, J., & Lim, J. (2015). Gallbladder volvulus presenting as acute appendicitis. *Case Reports in Surgery*, 2015, 1–4. <https://doi.org/10.1155/2015/629129>
- [8] Vedanayagam, M. S., Nikolopoulos, I., Janakan, G., & El-Gaddal, A. (2013). Gallbladder volvulus: A case of mimicry. *Case Reports*, 2013 (jan16 1). <https://doi.org/10.1136/bcr-2012-007857>
- [9] Rueda-Martínez, J. L., Cascales-Sánchez, P., Vázquez-Aragón, P., Serafín Valero-Liñán, A., & Prat-Calero, A. (2011). Gallbladder volvulus: Clinical presentation mimicking acute appendicitis of the elderly. *Revista Española de Enfermedades Digestivas*, 103(12), 656–657. <https://doi.org/10.4321/s1130-01082011001200011>
- [10] Nakao, A., Matsuda, T., Funabiki, S., Mori, T., Koguchi, K., Iwado, T., Matsuda, K., Takakura, N., Isozaki, H., & Tanaka, N. (1999). Gallbladder torsion: Case report and review of 245 cases reported in the Japanese literature. *Journal of Hepato-Biliary-Pancreatic Surgery*, 6(4), 418–421. <https://doi.org/10.1007/s005340050143>
- [11] Baig, Z., Ljubojevic, V., & Christian, F. (2021). The diagnostic dilemma of a gallbladder volvulus: An unusual case report and review of the literature. *International Journal of Surgery Case Reports*, 80, 105614. <https://doi.org/10.1016/j.ijscr.2021.01.108>
- [12] Miyata, T., San-nomiya, Y., Nagayama, T., Kin, R., Nishiki, H., Hashimoto, A., Fujii, Y., Miura, S., Kaida, D., Tomita, Y., Nakamura, N., Miyashita, T., Fujita, H., Ueda, N., & Takamura, H. (2022). Preoperative diagnosis of gallbladder torsion by magnetic resonance cholangiopancreatography: A case report. *Clinical Case Reports*, 10(2). <https://doi.org/10.1002/ccr3.5487>
- [13] Kalyanasundaram, S., & Fernando, S. (2022). Atypical presentation of cholecystitis with torsion of the gallbladder diagnosed preoperatively in an unusual location. *BJR|case Reports*, 8(1). <https://doi.org/10.1259/bjrcr.20210141>
- [14] Layton, B., Rudralingam, V., & Lamb, R. (2016). Gallbladder volvulus: It's a small whirl. *BJR|case Reports*, 2(3), 20150360. <https://doi.org/10.1259/bjrcr.20150360>
- [15] Sato, O., Kotani, T., Kanayama, T., Tokuda, B., & Yamada, K. (2023). Utility of hyperdense whirl sign for the diagnosis of gallbladder torsion. *Acta Radiologica Open*, 12(11). <https://doi.org/10.1177/20584601231218994>
- [16] Dasyam, A. K., Koo, J., Stahlfeld Miller, M., Sell, H. W., & Tublin, M. E. (2015). The cystic duct knot sign: Case report with description of a new ultrasound sign of gallbladder torsion. *Emergency Radiology*, 22(4), 445–447. <https://doi.org/10.1007/s10140-015-1331-8>
- [17] Matsubashi, N. (2006). Volvulus of the gall bladder diagnosed by ultrasonography, computed tomography, coronal magnetic resonance imaging and Magnetic Resonance Cholangio-Pancreatography. *World Journal of Gastroenterology*, 12(28), 4599. <https://doi.org/10.3748/wjg.v12.i28.4599>

- [18] Laydi, M., Charpentier, K., Paquette, B., & Heyd, B. (2017). Combined treatment of a gallbladder volvulus with a common bile duct obstruction. *Case Reports in Surgery*, 2017, 1–2. <https://doi.org/10.1155/2017/3906042>
- [19] Aroori, S., Mangan, C., Reza, L., & Gafoor, N. (2018). Percutaneous cholecystostomy for severe acute cholecystitis: A useful procedure in high-risk patients for surgery. *Scandinavian Journal of Surgery*, 108(2), 124–129. <https://doi.org/10.1177/1457496918798209>
- [20] Kirkegård, J., Horn, T., Christensen, S. D., Larsen, L. P., Knudsen, A. R., & Mortensen, F. V. (2015). Percutaneous cholecystostomy is an effective definitive treatment option for acute acalculous cholecystitis. *Scandinavian Journal of Surgery*, 104(4), 238–243. <https://doi.org/10.1177/1457496914564107>
- [21] Horn, Torben., Christensen, S. D., Kirkegård, Jakob., Larsen, L. P., Knudsen, A. R., & Mortensen, F. V. (2015). Percutaneous cholecystostomy is an effective treatment option for acute calculous cholecystitis: A 10-Year experience. *HPB*, 17(4), 326–331. <https://doi.org/10.1111/hpb.12360>
- [22] Walter, K. (2022). Acute cholecystitis. *JAMA*, 327(15), 1514. <https://doi.org/10.1001/jama.2022.2969>
- [23] Cao, A. M., Eslick, G. D., & Cox, M. R. (2015). Early laparoscopic cholecystectomy is superior to delayed acute cholecystitis: A meta-analysis of case-control studies. *Surgical Endoscopy*, 30(3), 1172–1182. <https://doi.org/10.1007/s00464-015-4325-4>
- [24] Morales-Maza, J., Rodríguez-Quintero, J. H., Santes, O., Hernández-Villegas, A. C., Clemente-Gutiérrez, U., Sánchez-Morales, G. E., Mier y Terán-Ellis, S., Pantoja, J. P., & Mercado, M. A. (2019). Percutaneous cholecystostomy as treatment for acute cholecystitis: What has happened over the last five years? A literature review. *Revista de Gastroenterología de México (English Edition)*, 84(4), 482–491. <https://doi.org/10.1016/j.rgmxe.2019.06.002>