


Case Report

Early Postoperative Cardiac Rehabilitation in LVAD Patients: A Case Report

Yi-qi Cao , Guo-qiang Zheng, Li-min Zhong, Ke-yi Chen, Gang Wang, Zhi-wei Mou*

Department of Rehabilitation, the First Affiliated Hospital of Jinan University, Guangzhou, China

Abstract

This study emphasizes the crucial role of early mobilization and proactive physical therapy for individuals undergoing left ventricular assist device (LVAD) therapy in the context of chronic or end-stage heart failure. Given the intricate medical complexities and prolonged hospitalizations inherent in this patient cohort, specialized cardiac rehabilitation (CR) strategies emerge as indispensable components in cardiovascular medicine. Detailed herein is a case study featuring a 62-year-old male patient who underwent LVAD implantation and participated in a 7-week cardiac rehabilitation program. The observed outcomes revealed substantial improvements in exercise capacity and muscle strength, assessed through standardized physical assessments. Importantly, echocardiographic evaluation demonstrated no adverse effects on left ventricular function. This case underscores the pivotal significance of early rehabilitation intervention during the postoperative phase, particularly in patients exhibiting stable vital signs and hemodynamics. The findings contribute to the refinement of tailored rehabilitation approaches for LVAD recipients, thereby fostering enhanced clinical outcomes and an elevated quality of life in this specialized patient population. The study underscores the critical importance of implementing early rehabilitation strategies in the holistic care paradigm for LVAD recipients, with potential implications for optimizing therapeutic protocols and improving long-term patient outcomes in the field of cardiovascular rehabilitation.

Keywords

Cardiac Rehabilitation, Left Ventricular Assist Device, Heart Failure, Physical Therapy

1. Introduction

The Left Ventricular Assist Device (LVAD) is an artificial blood pump that effectively takes over the pumping function of the left heart, redirecting blood flow and staying connected to an external control unit and battery via an abdominal transmission system [1]. The insertion of LVAD has emerged as a vital intervention for individuals in the advanced stages of heart failure, serving as a significant measure both while awaiting heart transplantation and as a

long-term alternative treatment [2, 3], the one-year survival rate following LVAD implantation is 82%, with the latest generation device, HeartMate [3], achieving an even higher one-year survival rate of 91.5% [4], it can even provide life support for patients for up to 14 years [1]. Hence, we report a successful case of CR following the implantation of an LVAD.

*Corresponding author: mouzhiwei@jun.edu.cn (Zhi-wei Mou)

Received: 5 February 2024; **Accepted:** 21 February 2024; **Published:** 29 February 2024



Copyright: © The Author(s), 2023. Published by Science Publishing Group. This is an **Open Access** article, distributed under the terms of the Creative Commons Attribution 4.0 License (<http://creativecommons.org/licenses/by/4.0/>), which permits unrestricted use, distribution and reproduction in any medium, provided the original work is properly cited.

2. Case Presentation

Chief complaints: A 62-year-old man was admitted to the cardiology department because of dizziness.

Patient's Recent Medical History: The patient presented six hours ago with an abrupt onset of dizziness while eating, accompanied by vomiting. Following vomiting, the patient reported chest tightness and profuse sweating, with no significant improvement in symptoms. An urgent electrocardiogram showed ST-segment depression in the inferior and precordial leads. The cardiac troponin level was 0.12 ng/ml, indicating a high probability of acute non-ST-segment elevation myocardial infarction. Subsequent examinations at an external hospital revealed diffuse narrowing of the right coronary artery, with approximately 70% stenosis and forward blood flow TIMI 3 grade. The left main coronary artery was occluded, with no forward blood flow (TIMI 0 grade).

The plan included left main artery recanalization. Postoperatively, diffuse narrowing of the anterior descending and circumflex branches was observed, with forward blood flow TIMI 2-3 grade. The patient experienced ventricular fibrillation after the procedure, necessitating repeated defibrillation and IABP insertion due to challenges in maintaining circulatory blood pressure. Given the complex hemodynamics, the patient was transferred to our hospital following ECMO insertion.

There is no significant past medical history or family history of note.

Clinical Diagnosis: 1. Acute Myocardial Infarction. 2. Cardiogenic Shock. 3. Coronary Artery Atherosclerotic Heart Disease, Killip IV Grade. 4. Malignant Arrhythmia (Ventricular Fibrillation). 5. Acute Respiratory Failure. 6. Acute Cardiogenic Pulmonary Edema. 7. Disseminated Intravascular Coagulation.

Table 1. The results of the patient's medical events and parameters.

Date	Medical Events and Parameters
March 20th	Tracheal intubation with VA-ECMO support; Blood pressure: 84/48 mmHg, HR: 90 bpm, Oxygen: 81%, EF: 12%
March 22nd	Blood pressure: 92-98/72-78 mmHg, HR: 84-88 bpm, EF: 24%
March 24th	Recommendation for coronary artery recanalization
March 25th	Coronary angiography and stent placement; ECMO support: Flow 2.5-2.6 L/min, Speed 2700 rpm
March 30th	VA-ECMO discontinued; Blood pressure: 112/65 mmHg, HR: 92 bpm, Oxygen: 100%
April 3rd	SBT with PS10, tracheal tube removal, cardiogenic shock, transferred for LVAD placement
April 4th	Dopamine: 8 ug/kg/min, Norepinephrine: 1.4 ug/kg/min, Levosimendan: 5 ml/h
April 6th	Tracheal extubation, rapid breathing, decreased oxygen saturation, reinserted tube
April 10th	LVAD insertion
April 11th	LVAD parameters: RPM: 2760, Flow: 5.4-6.2 L/min, HR: 115-125 bpm, MAP: 70-85 mmHg, Spo2: 96-99%, FIO2: 80%, PEEP: 5 mmHg, CO: 5.8-6.1 L/min, CI: 3.1-3.7 L/min.m ² , CVP: 6-8 mmHg, MPAP: 21-27 mmHg, PCWP: 15-19 mmHg

On April 12th, the second day after LVAD placement, rehabilitation treatment was initiated.

3. Rehabilitation Treatment

On the second day after the surgery, rehabilitation treatment was initiated. The vital signs were as follows: HR: 115-120 beats/min, MAP: 70-85 mmHg, Spo2: 96-99%, FIO2: 60%, PEEP: 5 mmHg, RR: 20 breaths/min, temperature: 38-38.3 degrees Celsius. The patient was in a sedated state and unable to follow instructions for movement. According to the plan from the University of Leuven, the patient is categorized as Level I, and the following rehabilitation treatments were administered:

1. Passive joint exercises for each limb - 20 minutes per session.
2. Bedside cycle ergometer - 5 minutes per session, passive mode, 20 revolutions per minute.
3. Neuromuscular electrical stimulation for all four limbs - 20 minutes per session.
4. Phrenic nerve electrical stimulation - 20 minutes per session.
5. Gradual elevation of the head of the bed (starting at 30 degrees) to reduce pulmonary complications.
6. Instructed nurses to turn the patient every two hours.

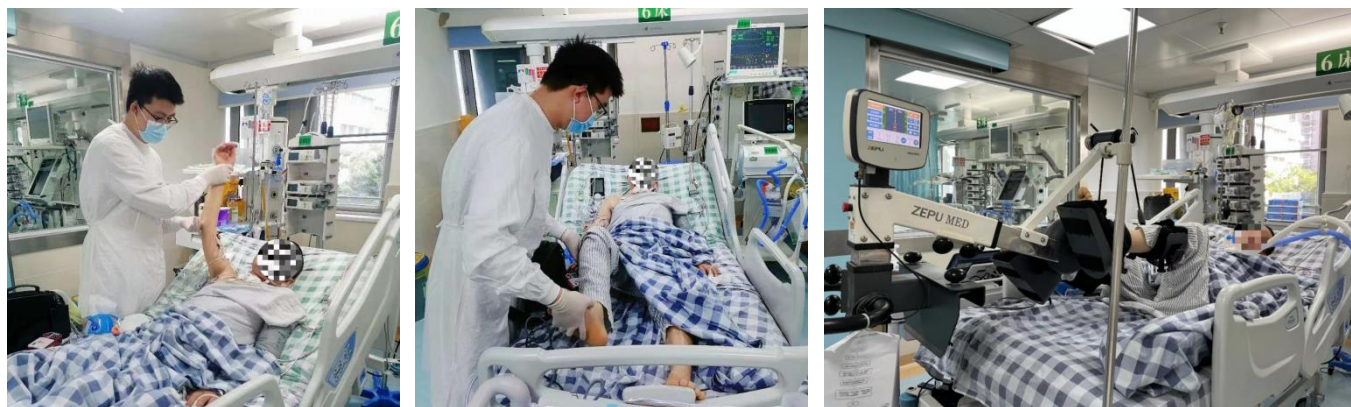

Figure 1. Record of the patient's recovery.

On April 15th, the patient was alert, able to follow instructions for movement, and vital signs were stable. The patient continued to receive assisted ventilation with the SIMV+PS mode, FIO₂: 45%, PEEP: 5 mmHg. According to the plan from the University of Leuven, the patient is categorized as Level II, and the following rehabilitation treatments were administered:

1. Limb muscle strength training - 30 minutes per session (Borg score between 11-14, heart rate < HR_{rest} + 20 beats/min, blood pressure < +20 mmHg).
2. Bedside cycle ergometer - 15 minutes per session, active and passive mode, 20 revolutions per minute, resistance: 1.
3. Neuromuscular electrical stimulation for all four limbs - 30 minutes per session.
4. Phrenic nerve electrical stimulation - 20 minutes per session.
5. Respiratory control training + respiratory muscle strength training + assisted coughing technique - 15 minutes per session.
6. Assisted sitting balance training - 5-10 minutes per session.
7. Instructed nurses to turn the patient every two hours.

On April 26th, the patient underwent a spontaneous breathing trial (SBT) and was able to be off the ventilator for 6 hours. Under monitoring, the patient could independently sit for 5-10 minutes. Additional exercises were introduced, including resistance band training for the limbs, sitting-to-standing training, and assisted standing with two people - 10 minutes per session (Borg score between 11-14, heart rate < HR_{rest} + 20 beats/min, blood pressure < +20 mmHg). On May 5th, another SBT was conducted, and the patient was able to be off the ventilator for 12 hours. On May 11th, the patient underwent another SBT and was able to be off the ventilator for 24 hours.

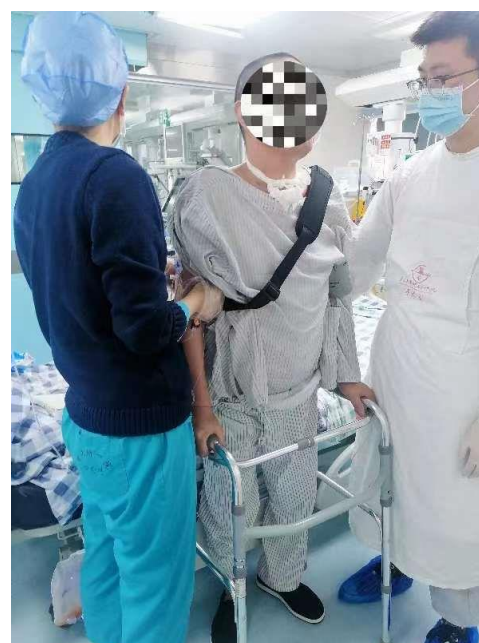

Figure 2. Record of the patient's recovery.

On May 15th, the tracheal tube was removed, and in addition to the existing training regimen, in-place stepping exercises were added: 20 steps per set, 3 sets. In the monitoring room, assisted by medical staff, short-distance walking for 5 meters was introduced (Borg score between 11-14, heart rate < HR_{rest} + 20 beats/min, blood pressure < +20 mmHg). On May 18th, the patient was transferred to a regular ward and could independently walk for 10 meters with the assistance of a walking frame. On June 1st, the patient was discharged from the hospital.

Table 2. The results of the patient's stage assessment.

Assessment	April 12th	April 15th	April 26th	May 15th
MRC	Not cooperative	Upper Limbs: 18 points Lower Limbs: 12 points Total: 30 points	Upper Limbs: 24 points Lower Limbs: 18 points Total: 42 points	Upper Limbs: 30 points Lower Limbs: 24 points Total: 54 points
S5Q	0 points	5 points	-	-
RASS	-2 points	0 points	-	-
IMS	Level 0	Level 2	Level 4	Level 6
BBS	Sit to Stand: 0 points Independent Sitting: 0 points Independent Standing: 0 points	Sit to Stand: 0 points Independent Sitting: 0 points Independent Standing: 0 points	Sit to Stand: 1 points Independent Sitting: 3 points Independent Standing: 0 points	Sit to Stand: 3 points Independent Sitting: 4 points Independent Standing: 3 points

S5Q: Standardized Five Questions; MRC: medical research council Scale; RASS: Richmond Agitation and Sedation Scale; IMS: ICU Mobility Scale; BBS: Berg balance scale

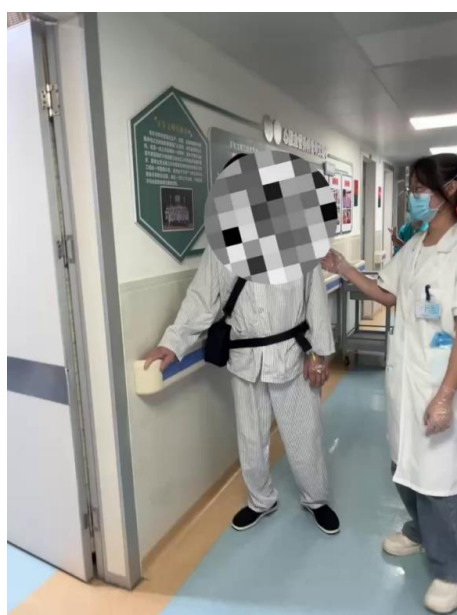

Figure 3. Before being discharged from the hospital, the patient demonstrated the ability to ambulate with minimal assistance.

4. Discussion

The implantation of LVADs has been shown to enhance cardiac output and sympathetic nervous system function in patients with heart failure, thereby improving cardiorespiratory function and quality of life; however, comparative analysis with the healthy population indicates that these improvements remain constrained [5-7]. Research indicates that exercise rehabilitation, as a central component of CR, contributes to the improvement of peak oxygen consumption, 6-minute walking test distance, muscle strength, functional independence, and quality of life in patients

post-LVAD implantation [8-10]. The European Society of Cardiology Heart Failure Association [11] has summarized recommendations for post-LVAD implantation exercise rehabilitation. It explicitly states that patients after LVAD implantation, due to the severity of their condition and the complexity of device management, require specific exercise rehabilitation strategies. Both domestic and international studies indicate that Phase I exercise rehabilitation can commence within the first 3 days post-LVAD implantation, specifically in the ICU. The initiation can occur as soon as the patient is awake and exhibits hemodynamic stability post-surgery [12-14]. For patients post-LVAD implantation during hospitalization, it is recommended to refer to the advanced intensive rehabilitation assessment and treatment plan from the University Hospitals Leuven Medical School [15]. In this case, rehabilitation treatment for the patient also commenced on the second day post-surgery during Phase I.

Post-LVAD implantation, both Phase I and Phase II exercise rehabilitation play crucial roles. In Phase I rehabilitation, early activities within the ICU primarily involve respiratory training and transitional exercises. Upon transfer to the ward, respiratory training continues, and exercise training, along with LVAD management-related education, commences. In this case, the patient primarily underwent Phase I rehabilitation during the hospital stay. After discharge, Phase II exercise rehabilitation is typically conducted at a rehabilitation center, gradually increasing the intensity of exercise training to further enhance physical function.

Functional and exercise capacity assessment is crucial in CR to objectively gauge patients' exercise tolerance. This evaluation plays a key role in risk stratification, planning therapeutic programs, individual training control, and ensuring follow-up and quality assurance in CR. It is indispensable for conducting safe and effective exercise training while offering insights into long-term prognosis. The results are

applicable in post-CR ambulatory follow-up exercise programs. Test protocols should adhere to contraindications for heart failure patients and specific abort criteria, encompassing device alarms, LVAD flow < 3l/min, bleeding, or oxygen saturation < 90%.

Aerobic endurance training is commonly conducted through individually tailored and monitored bicycle-ergometer sessions. To complement this, various aerobic exercises, particularly walking (within corridors, on treadmills, and in hospital surroundings, progressing to appropriate hikes), should be included. For patients with pronounced weakness or multiple health conditions, using a motorized exercise trainer is a suitable alternative.

Individuals with weakened muscular condition benefit from mild to moderate dynamic resistance training. Emphasizing the lower extremities is essential as these muscles play a key role in everyday stress tolerance and are often underdeveloped. Incorporating light-to-moderate strengthening exercises for the torso helps prepare the trunk musculature. Careful attention to post-sternotomy peculiarities is imperative, ensuring avoidance of excessive stretching and compression.

5. Conclusion

The prevalence of end-stage heart failure patients in need of LVAD is continuously rising. During their CR, it is imperative to prescribe suitable exercise routines and customize a workout plan for each stage of recovery. Commencing early intervention in rehabilitation becomes crucial when postoperative vital signs and hemodynamics stabilize, as it has proven benefits in reducing complications and fostering the recovery of cardiac function. Prompt adjustments in positioning play a role in diminishing pulmonary complications and improving the strength of the trunk and lower limbs. Vigilant monitoring of the patient's condition throughout the treatment process, with careful attention to intervention and pause indicators, is indispensable. In China, the postoperative exercise rehabilitation for individuals who have undergone LVAD implantation is currently in an exploratory stage, with a lack of specific rehabilitation protocols. It is recommended to look to the latest international recommendations and research for inspiration in developing future strategies. A comprehensive exercise rehabilitation plan for post-LVAD implantation should be formulated by incorporating established rehabilitation protocols designed for heart failure.

Abbreviations

LVAD: Left Ventricular Assist Device

SBT: Spontaneous Breathing Trial

CR: Cardiac Rehabilitation

Funding

This work was supported in part by Special Project of Chinese government for Science and Technology of Guangdong Province with grant No. 2019SKJ003 and KTP20190222; in part by Provincial Teaching Reform Project of Clinical Teaching Base of Undergraduate University of Guangdong with grant No.2021JD044; and Guangdong-Hong Kong-Macao Joint Innovation Project with grant NO. 2022A0505040007.

Conflicts of Interest

All the authors declare they have no conflict of interest.

References

- [1] Willemsen D, Cordes C, Bjarnason-Wehrens B, et al. [Rehabilitation standards for follow-up treatment and rehabilitation of patients with ventricular assist device (VAD)]. *Clin Res Cardiol Suppl.* Mar 2016; 11 Suppl 1: 2-49.
- [2] Stehlik J, Mountis M, Haas D, et al. Quality of life and treatment preference for ventricular assist device therapy in ambulatory advanced heart failure: A report from the REVIVAL study. *J Heart Lung Transplant.* Jan 2020; 39(1): 27-36.
- [3] Goldstein DJ, Meyns B, Xie R, et al. Third Annual Report From the ISHLT Mechanically Assisted Circulatory Support Registry: A comparison of centrifugal and axial continuous-flow left ventricular assist devices. *J Heart Lung Transplant.* Apr 2019; 38(4): 352-363.
- [4] Goldstein DJ, Naka Y, Horstmanshof D, et al. Association of Clinical Outcomes With Left Ventricular Assist Device Use by Bridge to Transplant or Destination Therapy Intent: The Multicenter Study of MagLev Technology in Patients Undergoing Mechanical Circulatory Support Therapy With HeartMate 3 (MOMENTUM 3) Randomized Clinical Trial. *JAMA Cardiol.* Apr 1 2020; 5(4): 411-419.
- [5] Mehra MR, Goldstein DJ, Uriel N, et al. Two-Year Outcomes with a Magnetically Levitated Cardiac Pump in Heart Failure. *N Engl J Med.* Apr 12 2018; 378(15): 1386-1395.
- [6] Eickmeyer SM, Barker KD, Sayyad A, Rydberg L. The Rehabilitation of Patients With Advanced Heart Failure After Left Ventricular Assist Device Placement: A Narrative Review. *Pm r.* Jan 2019; 11(1): 64-75.
- [7] Hildebrandt A, Willemsen D, Reiss N, Bartsch P, Schmidt T, Bjarnason-Wehrens B. Characteristics, Therapeutic Needs, and Scope of Patients With a Continuous-Flow Left Ventricular Device Entering Cardiac Rehabilitation: A RETROSPECTIVE ANALYSIS. *J Cardiopulm Rehabil Prev.* Mar 2019; 39(2): 91-96.
- [8] Yost G, Coyle L, Milkevitch K, Adair R, Tatoes A, Bhat G. Efficacy of Inpatient Rehabilitation After Left Ventricular Assist Device Implantation. *Pm r.* Jan 2017; 9(1): 40-45.

- [9] Kerrigan DJ, Williams CT, Ehrman JK, et al. Cardiac rehabilitation improves functional capacity and patient-reported health status in patients with continuous-flow left ventricular assist devices: the Rehab-VAD randomized controlled trial. *JACC Heart Fail.* Dec 2014; 2(6): 653-659.
- [10] Ganga HV, Leung A, Jantz J, et al. Supervised exercise training versus usual care in ambulatory patients with left ventricular assist devices: A systematic review. *PLoS One.* 2017; 12(3): e0174323.
- [11] Adamopoulos S, Corrà U, Laoutaris ID, et al. Exercise training in patients with ventricular assist devices: a review of the evidence and practical advice. A position paper from the Committee on Exercise Physiology and Training and the Committee of Advanced Heart Failure of the Heart Failure Association of the European Society of Cardiology. *Eur J Heart Fail.* Jan 2019; 21(1): 3-13.
- [12] Corrà U, Pistono M. Early mobilization in LVAD recipients: An obligatory step towards recovery. *Monaldi Arch Chest Dis.* Mar 27 2019; 89(1).
- [13] Seo YG, Park WH, Oh S, et al. Clinical outcomes of inpatient cardiac rehabilitation for patients with treated left ventricular assist device in Korea: 1-year follow-up. *J Exerc Rehabil.* Jun 2019; 15(3): 481-487.
- [14] Polastri M, Zagnoni G, Loforte A. Basic movements for postoperative exercise in patients with left ventricular assist devices. *Monaldi Arch Chest Dis.* Mar 20 2019; 89(1).
- [15] Sommers J, Engelbert RH, Dettling-Ihnenfeldt D, et al. Physiotherapy in the intensive care unit: an evidence-based, expert driven, practical statement and rehabilitation recommendations. *Clin Rehabil.* Nov 2015; 29(11): 1051-1063.