Cardiology and Cardiovascular Research
2026, Vol. 10, No. 4, pp. 130–136
https://doi.org/10.11648/j.ccr.20261004.14

Case Report

Pink Tetralogy of Fallot in an Older Child: A Case Report from the Cardiology Department of the National University Hospital Center of Cotonou

Chromoello Fustel Joao Sossa[1, *], Borelle Padonou Ladeyo[1], Serge Kassouin[1], Jean Jacques Ngoume[1], Joel Guirbai[1], Ornelle Vilome Hounkponou-Houssui[1], Tibaud Ebessa[1], Pascal Dabade[1], Karel Bile[1], L ópold Hou étondji Codjo[2]

[1]University Cardiology Clinic, National Teaching Hospital Hubert Koutoukou Maga of Cotonou, Cotonou, Benin
[2]Cardiology Department, Calavi International Hospital, Abomey-Calavi, Benin

Abstract

Tetralogy of Fallot is the most common cyanotic congenital heart disease, accounting for roughly 10% of congenital cardiac malformations. Its clinical presentation depends on the severity of right ventricular outflow tract obstruction, ranging from severe neonatal cyanosis to the rarer acyanotic ("pink") phenotype, which can delay diagnosis until later childhood in resource-limited settings. We report the case of a nine-year-old boy referred to the National Teaching Hospital Hubert Koutoukou Maga in Cotonou, Benin, for recurrent squatting during play and New York Heart Association (NYHA) class II exertional dyspnea evolving over one year, without resting cyanosis. Physical examination revealed a good general condition, resting peripheral capillary oxygen saturation (SpO_2) of 96% on room air, and a harsh, grade 4/6 systolic murmur loudest at the pulmonary area and radiating across the precordium. During a 6-minute walk test, SpO_2 dropped from 96% to 79% and normalized within three minutes of rest, reflecting dynamic exertional right-to-left shunting. Electrocardiography showed sinus rhythm at 100 beats per minute with right axis deviation (+110 °), while chest radiography revealed a normal cardiothoracic ratio, a slightly upturned apex, and normal pulmonary vascularity. Transthoracic Doppler echocardiography confirmed a regular Tetralogy of Fallot, demonstrating an 11 mm non-restrictive subaortic ventricular septal defect with a predominantly left-to-right shunt at rest, an overriding aorta (<50%), right ventricular hypertrophy (free wall thickness: 8.1 mm), and severe infundibular pulmonary stenosis (peak gradient: 100 mmHg). Laboratory tests excluded polycythemia (hemoglobin: 15.6 g/dL; hematocrit: 43%). Due to local unavailability of pediatric open-heart surgery, oral propranolol and iron/folic acid supplementation were initiated. At the 6-month follow-up, treatment was well tolerated with marked regression of squatting and dyspnea while awaiting surgery.

Keywords

Tetralogy of Fallot, Echocardiography, Surgery

*Correspondence: Chromoello Fustel Joao Sossa (fustelsossa@gmail.com)

Received: 11 November 2026; **Accepted:** 23 November 2026; **Published:** 24 November 2026

Copyright: © The Author(s), 2026. Published by Science Publishing Group. This is an **Open Access** article, distributed under the terms of the Creative Commons Attribution 4.0 License (http://creativecommons.org/licenses/by/4.0/), which permits unrestricted use, distribution and reproduction in any medium, provided the original work is properly cited.

1. Introduction

Tetralogy of Fallot is the most common cyanotic congenital heart disease [1]. It accounts for approximately 10% of all congenital heart defects. Worldwide, the incidence of this malformation is about 3 per 10,000 births, most frequently identified in children, affecting males and females equally [2]. In Quebec, the birth prevalence is 0.2 to 0.5 cases per 1,000 live births [1]. In Mali, between 2018 and 2021, Coulibaly et al. reported 100 cases of Tetralogy of Fallot hospitalized and/or followed up in the cardiology department of the Mother-Child University Hospital "Le Luxembourg," representing 10% of all congenital heart diseases and 41% of cyanotic heart defects [3]. In Benin, Adjagba et al. reported 7 cases diagnosed among 51 patients hospitalized and/or followed up for congenital heart disease at the CNHU-HKM (National Teaching Hospital Hubert Koutoukou Maga) between 2015 and 2018, corresponding to a prevalence of 13.4% [4].

Embryologically, it results from the underdevelopment of the subpulmonary infundibulum or an anterior and superior deviation of the conal (infundibular) septum, leading, as its name implies, to four anatomical abnormalities: a ventricular septal defect, pulmonary infundibular stenosis, dextroposition of the aorta (an overriding aorta), and right ventricular hypertrophy [2, 5].

The clinical presentation depends on the severity of the pulmonary infundibular stenosis. It is varied and generally consists of progressive cyanosis, often accompanied by hypercyanotic spells [6]. When the stenosis is severe, cyanosis is marked. When the stenosis is mild, cyanosis is minimal or even absent.

We report a case of pink Tetralogy of Fallot in an older child.

2. Case Presentation

2.1. Clinical Presentation

The patient, GMG, a nine-year-old boy, was first seen on October 5, 2022, following a referral from a local clinic for squatting and exertional dyspnea. Symptom onset reportedly occurred approximately one year prior, characterized by episodes of squatting during play or walking, associated with New York Heart Association (NYHA) class II exertional dyspnea and palpitations, without cyanosis.

Maternal history was unremarkable. Pregnancy and delivery were uneventful, with a normal birth weight. The patient had never been hospitalized or transfused. He is the second of five uterine siblings, including one stillbirth of unknown cause, while the remaining siblings are alive and in apparent good health. There was no known family history of congenital heart disease or reported genetic abnormalities.

On physical examination, the patient was in good general condition, weighing 22 kg for a height of 126 cm, corresponding to a body surface area of 0.88 m^2. He was acyanotic, with an oxygen saturation of 96% on room air. The palpebral conjunctivae were pink, and the sclerae were anicteric. Blood pressure was 106/68 mmHg in the right arm and 104/69 mmHg in the left arm. He was afebrile at 36.8 ℃, with a heart rate of 100 beats per minute and a respiratory rate of 26 breaths per minute (eupneic).

Cardiovascular examination revealed normal, well-heard, regular first (S1) and second (S2) heart sounds, accompanied by a harsh, grade 4/6 systolic murmur, loudest at the pulmonary area and radiating across the entire precordium. There were no signs of heart failure. During the 6-minute walk test, oxygen saturation on room air dropped from 96% at baseline to 79% at the end of the walk, returning to normal after approximately 3 minutes of rest.

2.2. Investigations

The electrocardiogram (ECG) showed a regular sinus rhythm at 100 beats per minute with right axis deviation at +110 degrees. There was no right ventricular hypertrophy or repolarization abnormalities (Figure 1).



Figure 1. *Twelve-lead electrocardiogram showing regular sinus rhythm at 100 beats per minute with right axis deviation (+110 °) and no right ventricular hypertrophy or repolarization abnormalities.*

On chest radiography, the cardiac silhouette showed a slightly upturned (supradiaphragmatic) apex, with normal left middle and right lower cardiac borders. Pulmonary vascularity was normal; there were no lesions of the bony thorax or pulmonary parenchyma (Figure 2).

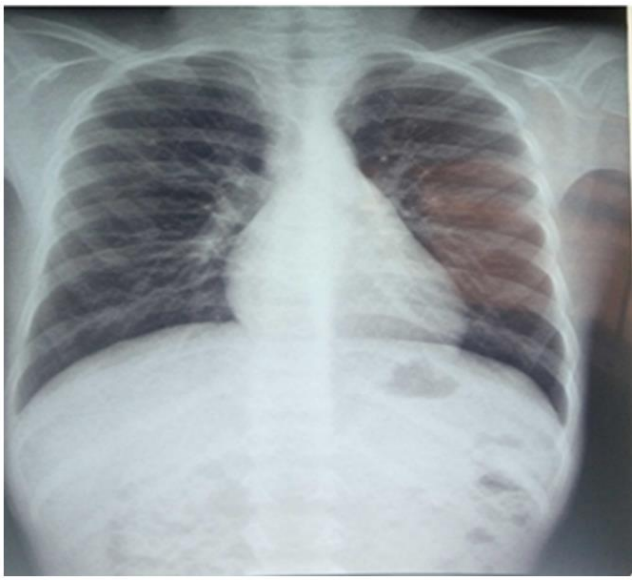

Figure 2. *Posteroanterior chest radiograph demonstrating a normal cardiothoracic ratio, a slightly upturned (supradiaphragmatic) cardiac apex, normal middle left and lower right cardiac borders, and normal pulmonary vascularity.*

Doppler echocardiography revealed a large, non-restrictive subaortic ventricular septal defect (VSD) measuring 11 mm (1.10 cm) in diameter with a bidirectional, predominantly left-to-right shunt at rest, an overriding aorta straddling the interventricular septum (<50% aortic override), a dilated right ventricle (RV) (RV/Left ventricle (LV) ratio = 1.11) with right ventricular hypertrophy (RV free wall thickness = 8.1 mm) and preserved RV systolic function (tricuspid annular S' velocity = 14 cm/s), as well as severe infundibular pulmonary stenosis generating a peak systolic pressure gradient of 100 mmHg. The pulmonary valve and main pulmonary artery branches were confluent and of normal caliber, confirming a

regular form of Tetralogy of Fallot. The left ventricle was normal in size and systolic function with a left ventricular ejection fraction (LVEF) of 70% (Figure 3).

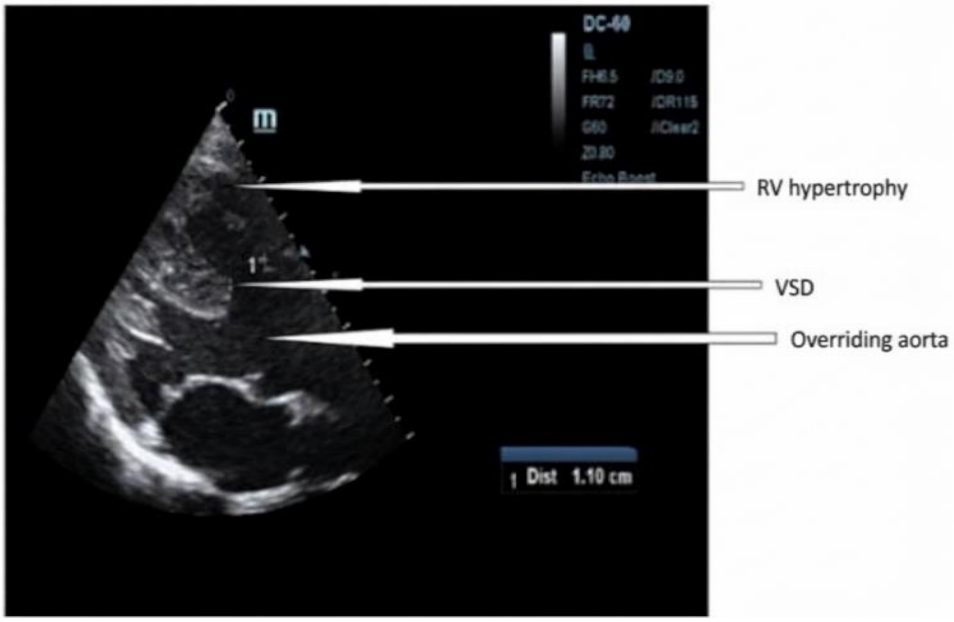

Figure 3. *Transthoracic Doppler echocardiography (parasternal long-axis view) showing the subaortic ventricular septal defect (VSD, 1.10 cm), overriding aorta, and right ventricular (RV) hypertrophy.*

Laboratory workup was unremarkable, including a complete blood count (CBC) showing no polycythemia (hemoglobin: 15.6 g/dL, hematocrit: 43%), C-reactive protein (CRP), renal function tests, serum electrolytes, HBsAg, anti-HCV antibodies, HIV serology, antistreptolysin O (ASO) titer, and TPHA/VDRL.

2.3. Management and Outcome

He was started on oral iron and folic acid supplementation (1 tablet daily) along with propranolol 40 mg (half a tablet daily), and is currently awaiting surgical management. Over the subsequent 6 months of follow-up, the treatment was well tolerated and resulted in a significant reduction in squatting episodes and exertional dyspnea.

Written informed consent was obtained from the patient's father for publication of this case report and any accompanying images.

3. Discussion

With an incidence of about 3/10,000 live births, tetralogy of Fallot accounts for about 10% of congenital heart diseases [2]. It appears to affect more boys than girls, as observed by Cobanoglu (USA) [7], Sarubbi (Italy) [8], Hakkou (Rabat, Morocco) [9], El Yandouzi (Fez, Morocco) [10], and Coulibaly [11]. Our patient was also male.

Screening is carried out at a young age and even prenatally in developed countries [12]. In Maghreb study series, Hakkou et al. in 2006 [9], Yandouzi et al. in 2012 in Morocco [10], and Abid et al. in 1993 (Tunisia) [13] reported, respectively, a mean age at diagnosis of 2 years 2 months and 2 years 3 months, which is clearly higher than that found in Western series by Need (USA) [14] and Guirgis [15], who reported mean ages of 4.9 months and 3.7 months, respectively. In Coulibaly's series [11] in Bamako in 2022, the mean age was five years. In our patient, the diagnosis was made at nine years of age, with symptoms evolving for one year. A cardiovascular examination could have revealed auscultatory abnormalities. This situation highlights the importance of early screening and the inadequacy of diagnostic strategies for serious but paucisymptomatic childhood conditions. In our clinical context, this unusually late diagnosis at nine years of age can be explained by both clinical and healthcare-system factors. Clinically, the patient's balanced resting hemodynamics preserved normal systemic oxygenation at rest, preventing overt cyanosis, digital clubbing, or failure to thrive that typically alert parents and primary care providers early in life. Contextually, the absence of routine fetal echocardiography and systematic neonatal pulse oximetry screening, combined with limited access to pediatric cardiology specialists in sub-Saharan Africa, often delays the detection of acyanotic or mildly symptomatic congenital heart defects until exertional limitations become noticeable in later childhood.

In tetralogy of Fallot, cyanosis is the most observed symptom. It manifests as dyspnea, squatting, syncope, and anoxic spells. In Coulibaly's series [11], it was observed in 79% of cases. This rate is comparable to those reported by Abid [13]

and Piechaud [16], who found cyanosis in 100% of cases, in contrast to Ben Khalfallah [17] and Alexiou [18], who observed 9% and 11% cyanosis, respectively, in their study populations. Cyanosis in our patient appears only during exertion. Our patient illustrates a "pink" (acyanotic) Tetralogy of Fallot, defined by the absence of resting cyanosis (resting peripheral capillary oxygen saturation (SpO_2) of 96%) and secondary polycythemia. Despite a peak infundibular gradient of 100 mmHg on echocardiography, baseline systemic vascular resistance (SVR) remained balanced with right ventricular outflow tract obstruction, maintaining a predominantly left-to-right shunt across the 11 mm ventricular septal defect at rest. During exertion, peripheral vasodilation lowers SVR while catecholamine surges induce dynamic infundibular spasm. This reverses the shunt to right-to-left, evidenced by desaturation to 79% during the 6-minute walk test, causing exertional dyspnea and compensatory squatting, which restores pulmonary blood flow by increasing SVR. At the extreme, infundibular spasm may be responsible for anoxic spells, which has not yet occurred in our patient. The occurrence of anoxic spells is an indication for urgent surgical management. In severe tetralogy of Fallot, cyanosis-related complications may include polycythemia and a brain abscess. These complications are absent in our patient due to the limited severity of the stenosis. However, they have been reported in Western series, owing to earlier diagnosis. [11]

Cardiac auscultation is dominated by the presence of a systolic ejection murmur of pulmonary stenosis. This murmur was present in our patient. Coulibaly [11] also reported the same murmur in 83% of cases. The intensity of the murmur varies according to the severity of infundibular pulmonary stenosis. Indeed, the more severe the stenosis, the weaker the murmur. In the absence of a murmur, the diagnosis of pulmonary atresia with an open septum is considered. [19]

Regarding paraclinical findings for the positive diagnosis of tetralogy of Fallot, several examinations are available today: transthoracic echocardiography, as well as pulmonary computed tomography (CT) angiography, magnetic resonance imaging, and cardiac catheterization [11]. Transthoracic echocardiography combined with Doppler, with its various modes, allowed confirmation of the diagnosis in our patient. It also makes it possible to determine the type of malformation, whether it is irregular, i.e., associated with multiple VSDs, coronary anomalies, and a branch stenosis of the pulmonary artery, or regular without these anomalies [11, 20]. In our patient, it was the regular form. Coulibaly [11] reported 68% regular form versus 32% irregular form in his study. This result is consistent with those of EL Yandouzi (Fez, Morocco) [10], Hakkou (Rabat, Morocco) [9], and Marino [21], who reported 55%, 63.9%, and 69.4% regular form, respectively, and differs from the 40% observed by Cobanoglu [7].

In tetralogy of Fallot, a chest X-ray shows a heart of normal size with an elevated apex, a concave mid-arc, and decreased vascularity [19]. In our patient, the heart size was normal, with a discretely supradiaphragmatic apex, a normal mid-arc, and normal vascularity. This is explained by the lax nature of the stenosis.

The electrocardiogram in our patient did not show right ventricular overload as described in the literature [19].

It is stated that, in the absence of surgical correction, the course of tetralogy of Fallot remains very severe, and very few patients reach the age of 10 or 20 years; the development of severe anoxic spells is fatal in the majority of cases. Indeed, Bertranou et al. reported that 15% of patients die in the first year of life, 50% within three years, and 75% within ten years [11]. Our patient, for his part, tolerated the malformation well because the pulmonary stenosis was not severe. Complete surgical repair remains the definitive treatment for Tetralogy of Fallot and is ideally performed in early childhood to prevent progressive right ventricular hypertrophy and arrhythmias. Because pediatric open-heart surgery is not yet locally available in our setting, medical therapy serves as an essential bridge while awaiting surgical evacuation. Oral propranolol was prescribed to prevent adrenergic-induced infundibular spasm and hypercyanotic spells, alongside iron and folic acid supplementation to avoid relative iron-deficiency anemia. Regular clinical and echocardiographic follow-up remains mandatory until definitive surgery is completed.

4. Conclusions

Tetralogy of Fallot is the most common cyanotic congenital heart disease. We report a case diagnosed in our practice at the CNHU-HKM in Cotonou. Doppler echocardiography remains a key diagnostic tool, and treatment remains surgical despite good tolerance under medical management.

Abbreviations

ASO	Antistreptolysin O
CBC	Complete Blood Count
CNHU-HKM	National Teaching Hospital Hubert Koutoukou Maga
CRP	C-reactive Protein
CT	Computed Tomography
ECG	Electrocardiogram
HBsAg	Hepatitis B Surface Antigen
HCV	Hepatitis C Virus
HIV	Human Immunodeficiency Virus
LV	Left Ventricle / Left Ventricular
LVEF	Left Ventricular ejection Fraction
NYHA	New York Heart Association
RV	Right Ventricle / Right Ventricular
SpO_2	Peripheral Capillary Oxygen Saturation
SVR	Systemic Vascular Resistance
TPHA	Treponema Pallidum Hemagglutination Assay
VDRL	Venereal Disease Research Laboratory
VSD	Ventricular Septal Defect

Author Contributions

Chromoello Fustel Joao Sossa: Writing – review & editing
Borelle Padonou Ladeyo: Writing – review & editing
Serge Kassouin: Writing – review & editing
Jean Jacques Ngoume: Writing – review & editing
Joel Guirbai: Writing – review & editing
Ornelle Vilome Hounkponou-Houssui: Writing – review & editing
Tibaud Ebessa: Writing – review & editing
Pascal Dabade: Writing – review & editing
Karel Bile: Writing – review & editing
Léopold Houénondji Codjo: Supervision, Validation

Data Availability Statement

The data is available from the corresponding author upon reasonable request.

Conflicts of Interest

The authors declare no conflicts of interest.

References

[1] Samuel B. Évaluation à long terme des différentes stratégies de prise en charge chirurgicale pour la correction de la tétralogie de Fallot [Long-term evaluation of different surgical management strategies for the correction of tetralogy of Fallot] [PhD thesis]. Sherbrooke (QC): Université de Sherbrooke, Faculté de Médecine et des Sciences de la Santé; 2021.

[2] Tetralogy of Fallot. Semin Thorac Cardiovasc Surg [Internet]. [cited 2020 Dec 15]. Available from: https://www.semthorcardiovascsurg.com/article/S1043-0679(15)00118-5/pdf

[3] Orphanet. Tétralogie de Fallot [Tetralogy of Fallot]. Encyclopédie Orphanet Grand Public; 2011.

[4] Adjagba PM, Kétoh MK, Bagnan Tossa L, Hounkponou M, Sonou A, Houénassi DM. Les cardiopathies congénitales syndromiques au CNHU-HKM de Cotonou, Bénin [Syndromic congenital heart diseases at the CNHU-HKM of Cotonou, Benin]. Tunis Med. 2020; 16(3): 169-76.

[5] Friedli B. Tétralogie de Fallot [Tetralogy of Fallot]. EMC-Cardiologie. 2010; 11-940-E-50. https://doi.org/10.1016/S1166-4568(10)50564-3

[6] Violeau M. Le « squatting »: une manœuvre spécifique lors d'un malaise chez un nourrisson porteur d'une tétralogie de Fallot [Squatting: a specific maneuver during a hypercyanotic spell in an infant with tetralogy of Fallot]. Ann Fr Med Urgence. 2015; 5(6): 342-3. https://doi.org/10.1007/s13341-015-0590-z

[7] Cobanoglu A, Schultz JM. Total correction of tetralogy of Fallot in the first year of life: late results. Ann Thorac Surg. 2002; 74(1): 133-8. https://doi.org/10.1016/S0003-4975(02)03619-6

[8] Sarubbi B, Pacileo G, Pisacane C, Ducceschi V, Iacono C, Russo MG, et al. Exercise capacity in young patients after total repair of tetralogy of Fallot. Pediatr Cardiol. 2000; 21(3): 211-5. https://doi.org/10.1007/s002460010041

[9] Hakkou J. Tétralogie de Fallot: étude épidémiologique (expérience du service de cardiologie B, à propos de 102 cas, 1997-2006) [Tetralogy of Fallot: an epidemiological study (experience of Cardiology Department B, based on 102 cases, 1997–2006)] [MD thesis]. Rabat: Université Mohammed V; 2006. No. 361.

[10] El Yandouzi A. Tétralogie de Fallot (à propos de 55 cas) [Tetralogy of Fallot (a report of 55 cases)] [MD thesis]. Fez: Université Sidi Mohamed Ben Abdellah, Faculté de Médecine et de Pharmacie; 2012. No. 043.

[11] Coulibaly B. Tétralogie de Fallot: aspects épidémio-cliniques, thérapeutiques et évolutifs [Tetralogy of Fallot: epidemiological, clinical, therapeutic, and evolutionary aspects] [MD thesis]. Bamako: Université des Sciences, des Techniques et des Technologies de Bamako; 2022.

[12] Iselin M. Cardiopathies congénitales [Congenital heart diseases]. EMC - Radiodiagnostic - Cœur-Poumon. 1999; 32-015-A-12.

[13] Abid A, Khayati A, Kalfat T. Anastomoses systémico-pulmonaires dans la tétralogie de Fallot [Systemic-to-pulmonary shunts in tetralogy of Fallot]. Tunis Med. 1993; 71: 475-8.

[14] Need LR, Powell AJ, del Nido P, Geva T. Coronary echocardiography in tetralogy of Fallot: diagnostic accuracy, resource utilization and surgical implications over 13 years. J Am Coll Cardiol. 2000; 36(4): 1371-7. https://doi.org/10.1016/S0735-1097(00)00862-7

[15] Guirgis H, Losay J, Serraf A, Planche C. Cure complète de la tétralogie de Fallot chez le nourrisson de moins de 6 mois [Complete repair of tetralogy of Fallot in infants under 6 months of age]. Arch Mal Coeur Vaiss. 1991; 84(5): 679-83.

[16] Piechaud JF, Delogu AB, Iserin L, Aggoun Y, Bonnet D, Sidi D, et al. Traitement palliatif de la tétralogie de Fallot par dilatation infundibulo-pulmonaire percutanée. Étude de 40 cas [Palliative treatment of tetralogy of Fallot by percutaneous infundibulo-pulmonary dilatation: a study of 40 cases]. Arch Mal Coeur Vaiss. 1994; 87(5): 573-9.

[17] Ben Khalfallah A, Annabi N, Ousji M. Évolution à long terme de la tétralogie de Fallot opérée [Long-term outcome of surgically repaired tetralogy of Fallot]. Tunis Med. 2004; 82(Suppl 1): 89-93.

[18] Alexiou C, Mahmoud H, Al-Khaddour A, Gnanapragasam J, Salmon AP, Keeton BR, et al. Outcome after repair of tetralogy of Fallot in the first year of life. Ann Thorac Surg. 2001; 71(2): 494-500. https://doi.org/10.1016/S0003-4975(00)02444-9

[19] Batisse A, Lévy M. Cardiologie pédiatrique pratique [Practical pediatric cardiology]. 3rd ed. Rueil-Malmaison: Wolters Kluwer France; 2008.

[20] Ségu éla PE. T étralogie de Fallot [Tetralogy of Fallot]. DIU R é-animation des Cardiopathies Cong énitales; 2018.

[21] Marino B, Digilio MC, Grazioli S, Formigari R, Mingarelli R, Giannotti A, et al. Associated cardiac anomalies in isolated and syndromic patients with tetralogy of Fallot. Am J Cardiol. 1996; 77(7): 505-8. https://doi.org/10.1016/S0002-9149(97)89345-9